

Full Length Research Paper

Disorders of sexual development in genetic pediatrics: Three different ambiguous genitalia cases report from Hospital Para el Niño Poblano, Mexico

Aparicio-Rodríguez J. M.^{1,9*}, Cuellar-López F², Hurtado-Hernández ML³, Barrientos-Pérez M⁴,
Reynoso de Mendoza S.⁵, Vargas-González R.⁶, Camacho-Gutiérrez S. F.²,
Marroquin-García I.³, Chatelain-Mercado S.⁷ and Sierra-Pineda F.⁸

¹Department of Genetics, Hospital para el Niño Poblano, México.

²Department of Urology and Pediatric Surgery, Hospital Para el Niño Poblano, México.

³Department of Citogenetics, Hospital Para el Niño Poblano, México.

⁴Department of Endocrinology, Hospital Para el Niño Poblano, México.

⁵Department of Neonatology, Hospital Para el Niño Poblano, México.

⁶Department of Pathology, Hospital Para el Niño Poblano, México.

⁷Department of Biotechnology, Universidad Autónoma Metropolitana, México.

⁸Department of Genetics, Hospital de la Mujer S.S.A. Puebla, Mexico

⁹Department of Estomatology, Benemérita Universidad Autónoma de Puebla México.

Accepted 15 October, 2010

Five pediatric patients with three different disorders of sexual development are reported in this study; the first three male patients (16 years, 4 years and 2 months old, respectively) were diagnosed as having diphallia. These 3 patients had real diphallia, well developed penises, urinarius meatus, and both testicles and one of the case, vessel duplication was reported by urology. All the patients have normal cytogenetic analysis, 46XY. The fourth patient was 2 years old, with hyperplasic clitoris, hyperpigmented tissue similar to labia major (large lips) and internal female organs identified as vagina, uterus and both ovaries. A chimera with two different cells lines [46,XX (48%) and 46,XY (52%)] by cytogenetic studies was reported. And the last child was 2 years 8 months old patient with chromosome translocation, between chromosome Y and 7 chromosomes t(7;Y). Hypospadias pene-scrotal, unilateral cryptorchidism, urinary meatus stenosis and malformed scrotum were diagnosed together with vessel duplication.

Key words: Ambiguous genitalia, diphallia, hypospadias, cryptorchidism, chromosome translocation and chimera.

INTRODUCTION

Disorders of sexual development (DSD), formerly termed intersex conditions, are considered as clinical events and an early genetic and clinical diagnosis is important in order to counsel parents on therapeutic options (Allen, 1976; Bernstein, 1981; Hughes et al., 2006; McLaren et al., 1984; Rosenfield et al., 1980; Walsh and Migeo,

1978). However, the problem of early gender assignment has been challenged by the results of clinical and basic science research, which show that gender identity development likely begins in the uterus, where the techniques for surgical genital reconstruction have been associated to psychological, interfamilial and social implications of gender assignment (Perez-Palacios et al., 1975; Watchel and Bare, 1981; Williams, 1981; Wilson et al., 1986), which in some cases becomes a real problem for surgical reconstruction. This study focuses on newborn genetic evaluation and the differential diag-

*Corresponding autor. E-mail: jmapar@prodigy.net.mx.

noses in children with DSD, including pediatric patients with three specific ambiguous genitalia cases: Diphallia, hypopadias and cryptorchidism, some of them are associated with chromosome aberrations as chimerism and translocation.

The first three patients in this study were diagnosed with diphallia, or penile duplication (PD), which is a medical condition where a male infant is born with two penises (Abdel, 1972; Carlos de la fuente et al., 2004; Del Vecchio et al., 1995; Kapoor and Saha, 1987; Kaufman et al., 1990; Maruyama et al., 1999; Melekos and Barbalias, 1986; Camacho-Gutierrez et al., 2004). It has been estimated that one out of 5 million live births in the United States results in a diphallial birth defect (Abdel, 1972).

When diphallia is present, a different kind of other congenital anomalies, such as renal, vertebral and ano-rectal duplication are observed. There is also a higher risk of spina bifida. Infants born with PD and its related conditions have a higher death rate from various infections associated with their more complex renal or colorectal systems. It is thought that diphallia occurs in the fetus between the 23rd and 25th days of gestation when an injury, chemical stress or malfunctioning homeobox genes (Thomas, 2005), hamper the proper functioning of the caudal cell mass of the fetal mesoderm as the urogenital sinus separates from the genital tubercle and rectum to form the penis. This rare condition has been documented in pigs and other mammals. (Camacho-Gutierrez et al., 2004; Villanova and Raventos, 1954). It is commonly mistaken that all sharks have this condition, but in reality they have a pair of "claspers", which serve a reproductive function.

The fourth patient presented a chromosomal Chimera. The phenotypic spectrum of 46,XX/46,XY chimeric patients is variable. It ranges from normal male or female genitalia to different degrees of ambiguous genitalia as in this study. Chimerism results from the fusion of two different zygotes in a single embryo (de Grouchy, 1980), whereas mosaicism results from a mitotic error in a single zygote.

It was observed by Lillian in 1998, the simultaneous presence of 46,XX and 46,XY cell lines in 0.24% of amniotic fluid cell cultures. True cases of chimerism have been reported (Hunter et al., 1982; Lawce, 1985; Freiberg et al., 1988; Amor et al., 1999; Yaron et al., 1999; Pinhas-Hamiel et al., 2002; Simon-Bouy et al., 2003; Chen et al., 2005). The first case of chimerism was reported by Gartler in 1962. Since then, very few cases have been studied using microsatellite markers, in order to identify the genetic mechanism involved. Here, we describe a phenotypical normal patient with ambiguous external genitalia (Figure 7) and a chromosome formula 46,XX/46,XY, chimera (Figure 8).

The fifth and last patient with ambiguous genitalia had a Y;7 chromosome translocation. The frequency of Y/autosome translocations in the general population is

not a rare event, approximately 1 in 2000 (Nielsen and Rasmussen, 1976; Powell, 1984; Gardner and Sutherland, 1996). Like any other chromosome, the Y chromosome can be translocated onto an autosome or a sexual chromosome, either in a balanced or unbalanced manner. Translocations between the Y and a non-acrocentric chromosome are not frequent and may involve any part of the Y chromosome (Smith et al., 1979), which often leads to an abnormal phenotype and infertility (Smith et al., 1979; Delobel et al., 1998; Goodfellow et al., 1985; Vogt et al., 1996; Vogt, 1999; Vigiúí et al., 1982). However, it has been reported that in Y/autosome translocation, the heterochromatic portion of Yq could be translocated to an acrocentric chromosome, (Hsu, 1994). These translocations have been observed in phenotypically normal individuals and reported in multiple families, indicating that fertility is usually not affected (Smith et al., 1979; Hsu, 1994; Cohen et al., 1981; Alitalo et al., 1988).

MATERIAL AND METHODS

Several studies were performed in 5 pediatric patients with ambiguous genitalia; in all cases, the karyotyping was carried out using blood after Giemsa Banding (GTG) banding of chromosomes with enzymes and stains that was performed according to national and international standard procedures on peripheral blood lymphocytes from all patients.

Cases 1, 2 and 3

The first three male patients were diagnosed with diphallia: 16 years (Figures 1A and B), 4 years (Figures 3A and B) and 2 months old (Figures 5A and B), respectively. All patients were diagnosed with real diphallia, well developed with urinarius meatus and both testicles. Subsequently, hormonal studies were performed by endocrinology and one of the case vessel duplication was observed by urology with pelvic ultrasounds. As such, all the patients underwent normal cytogenetic analysis, 46,XY (Figures 2, 4 and 6). karyotyping was carried out on blood after GTG banding. Pathology studies were also performed to the surgered penises.

Case 4

The fourth pediatric patient in this study was a 2 years old with ambiguous genitalia (Figure 7), which was also studied by endocrinology with sexual hormonal studies, urology with pelvic ultrasound. Genetic and cytogenetic studies reported two different types [46,XX (48%) and 46,XY (52%)] (Figure 8). It was observed in the patient karyotyping carried out using blood after GTG banding.

Case 5

The last pediatric patient in this study was a 2 years 8 months old patient with hypospadias and cryptorchidism (Figures 9 and 10) and was diagnosed by urology, hormonal studies performed by endocrinology. By genetic and cytogenetic studies, chromosome translocation between the sexual Y chromosome and 7 was observed, t(7;Y) (Figure 11) and was also carried out using blood after GTG.

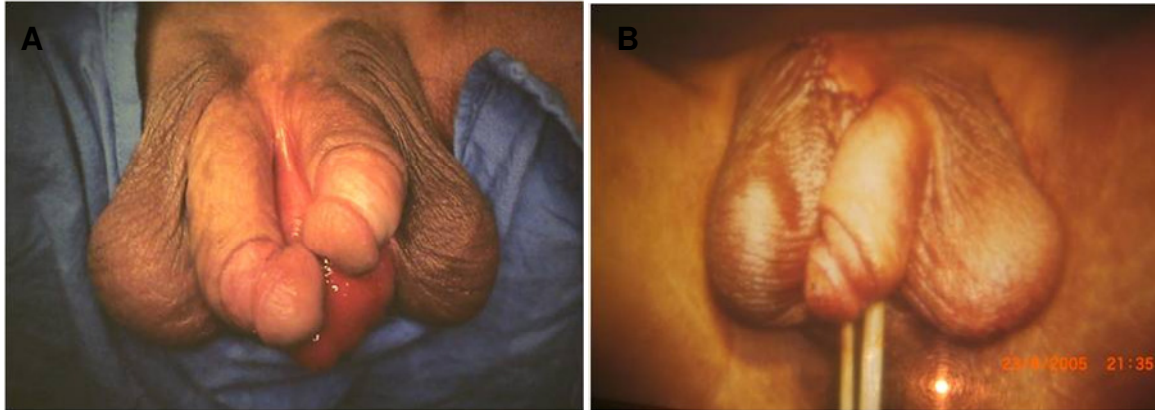


Figure 1. **A.** The sixteen years old patient was diagnosed with real diphallia, well developed penises with urinarius meatus, and both testicles, hormonal studies were performed by endocrinology and vessel duplication was observed by urology with pelvic ultrasounds. **B.** The best and well formed penis was left after surgery and his complex renal or colorectal systems were reconstructed.

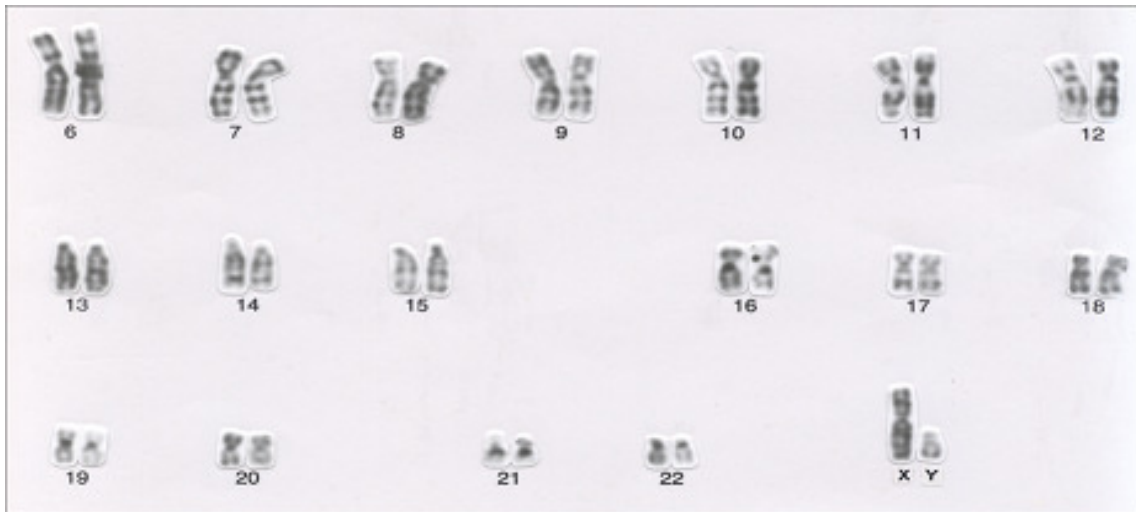


Figure 2. The 16 years old patient karyotype reported normal cytogenetic analysis, 46XY. karyotyping was carried out on blood after GTG banding.

Pelvic ultrasound studies were performed (Figure 12).

RESULTS AND DISCUSSION

Recently, the Lawson Wilkins Pediatric Endocrine Society, (LWPES, 2008) and the European Society for Pediatric Endocrinology, (ESPE, 2010) have published proposed changes to the nomenclature and definitions of disorders in which the development of chromosomal, gonadal, or phenotypic sex is atypical (Allen, 1976, Hughes et al., 2006). They proposed to change the nomenclature to reflect advances in our understanding of the pathophysiology of these sexual disorders in order to the help the affected patients concerned.

Previous terminology and revised nomenclature of disorders of sexual development (DSD) were based on new nomenclature: 1.-Sex chromosome DSD [46,XX/46,XY (chimeric, ovotesticular DSD)], 2.-46,XY DSD [Disorders of testicular development (complete and partial gonadal dysgenesis)] and other (severe hypospadias, cryptorchidism). (kaefer et al., 1999; Aarskog, 1971; Keenan, 1980).

In relation to embryology of sexual differentiation, the physical sex determination begins with genetic sex, where chromosomal sex determines gonadal sex. The type of gonad present determines the differentiation/regression of the internal ducts (that is, müllerian and wolffian ducts) that determines the phenotypic sex (Perez-Palacios et al., 1975; Sheehan et al., 1985).

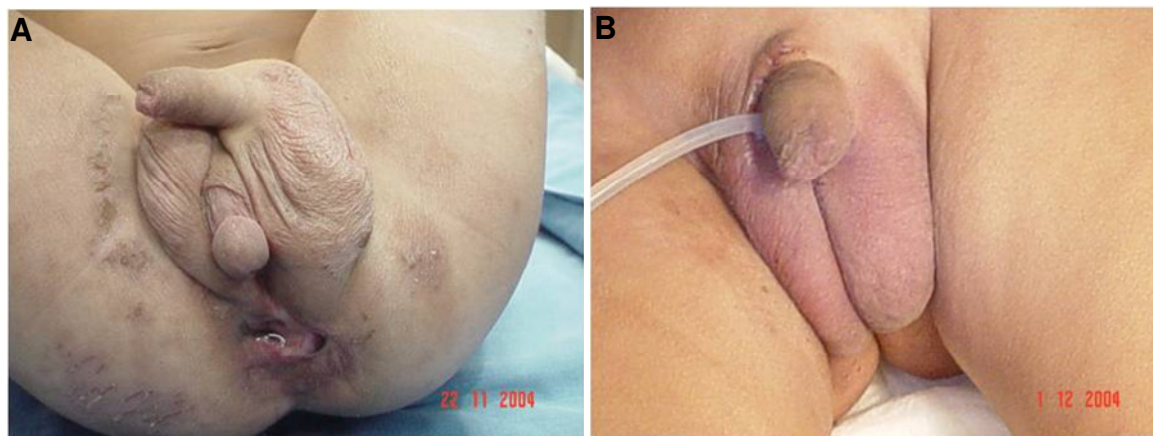


Figure 3. **A.** The four years old patient was diagnosed with real diphallia, well developed penises with urinarius meatus and both testicles, hormonal studies were performed by endocrinology. **B.** The best and well formed penis was left after surgery and his complex renal or colorectal systems were reconstructed.

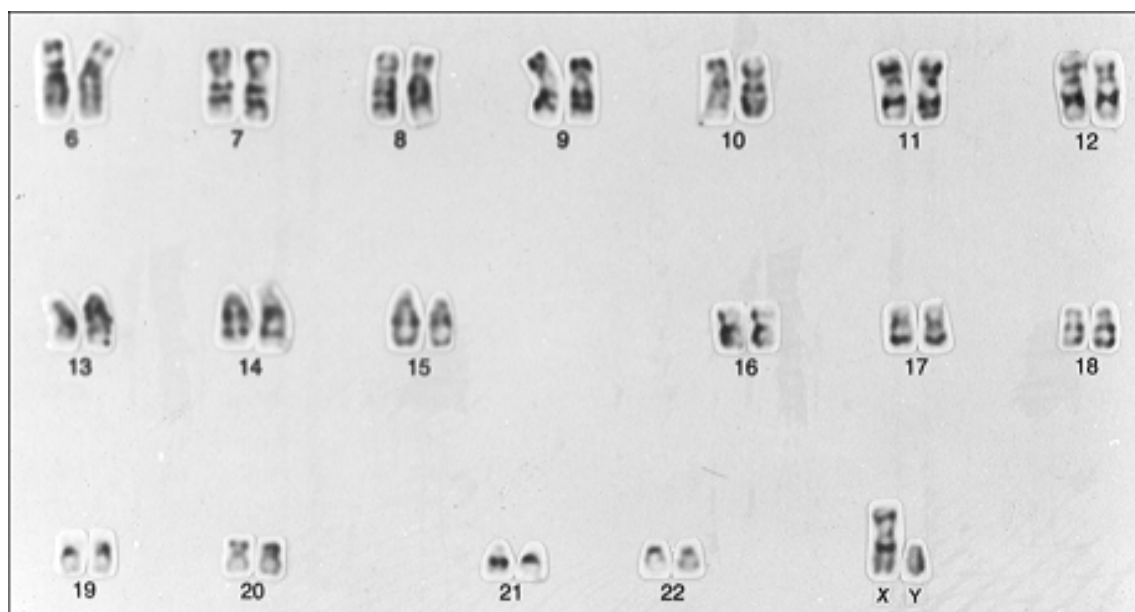


Figure 4. The four years old patient karyotype have normal cytogenetic analysis, 46XY. karyotyping was carried out on blood after GTG banding.

Gender identity is determined by both phenotypic appearance and the brain's prenatal and postnatal development as influenced by the environment. Gonadal differentiation is determined during the second month of fetal life. The information present on the short arm of the Y chromosome called testis-determining factor (TDF) is a 35-kilobase pair (kbp) sequence and there is also an area termed the sex-determining region of the Y chromosome (SRY) (Bernstein, 1981; McLaren et al., 1984; Wilson et al., 1986). When this region is absent or altered, the indifferent gonad develops into an ovary. The existence of patients with 46,XX testicular DSD, who

have testicular tissue in the absence of an obvious Y chromosome or SRY genetic material, requires other genes that are important to testicular development including other chromosomes: X chromosome (DAX1), 9q33 (SF1), 11p13 (WT1), 17q24-q25 (SOX9), and 19q13.3 (AMH) (Allen, 1976; McLaren et al., 1984; Wilson, 1972). In ambiguous genitalia, the internal ducts may be altered when testicular tissue is absent; the fetus morphologically begins and completes the internal sex duct development and external phenotypic development of a female. When testicular tissue is present, two produced substances appear to be critical for

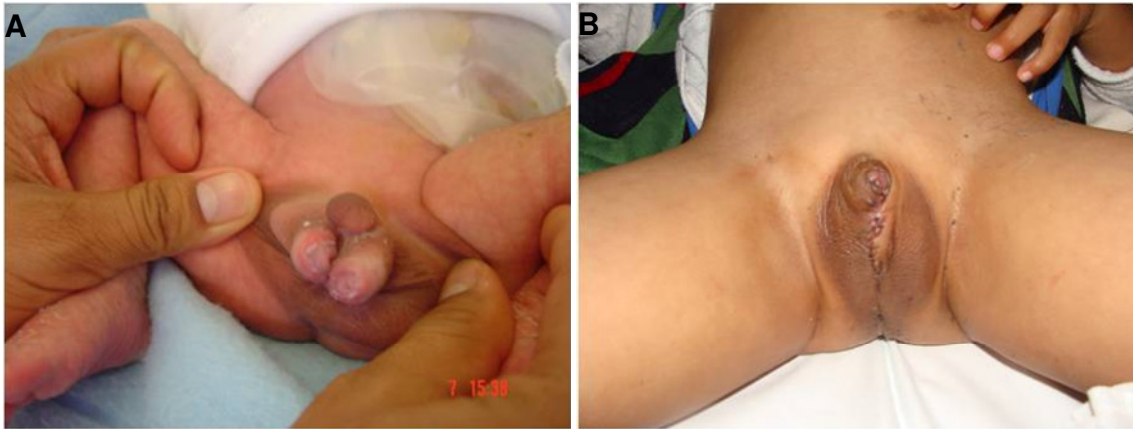


Figure 5. **A.** The two months old patient was diagnosed with real diphallia, well developed penises were observed although a upper protuberance was observed, and was thought to be a pseudotripallia. However by pathological studies a lipid content tissue was reported. With urinarius meatus, and both testicles, hormonal studies were performed by endocrinology. **B.** The best and well formed penis was left after surgery and his complex renal or colorectal systems were reconstructed.

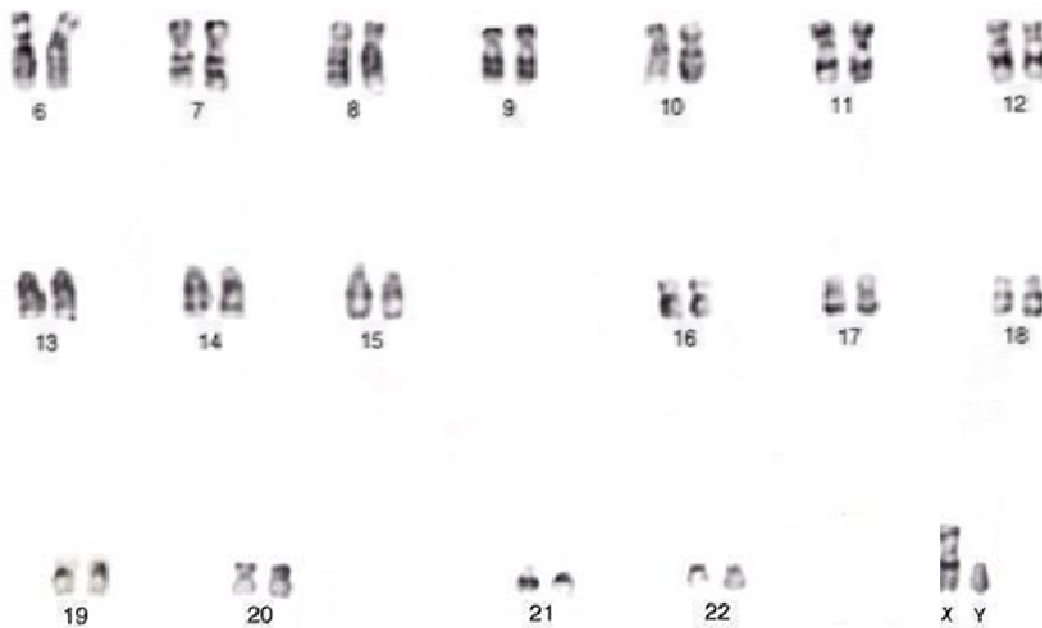


Figure 6. The two months old patient karyotype have normal cytogenetic analysis, 46XY. karyotyping was carried out on blood after GTG banding.

development of male internal sex ducts and an external male phenotype, namely, testosterone and müllerian-inhibiting substance (MIS) or AMH. The differentiations of external genitalia of both sexes are identical during the first 7 weeks of gestation. Without the hormonal action of the androgens testosterone and dihydrotestosterone (DHT), (Josso, 1971) external genitalia are psychically female. In the gonadal male, differentiation toward the male phenotype actively occurs in the next 8 weeks. This differentiation is moderated by testosterone, which is

converted to 5-DHT by the action of an enzyme, 5-alpha Imperato-McGinley et al., 1979; Saenger, 1981) present within the cytoplasm of cells of the external genitalia and the urogenital sinus. DHT is bound to cytosol androgen receptors within the cytoplasm and is subsequently transported to the nucleus, where it leads to translation and transcription of genetic material. These actions lead to normal male external genital development from primordial parts, forming the scrotum from the genital swellings, forming the shaft of the penis

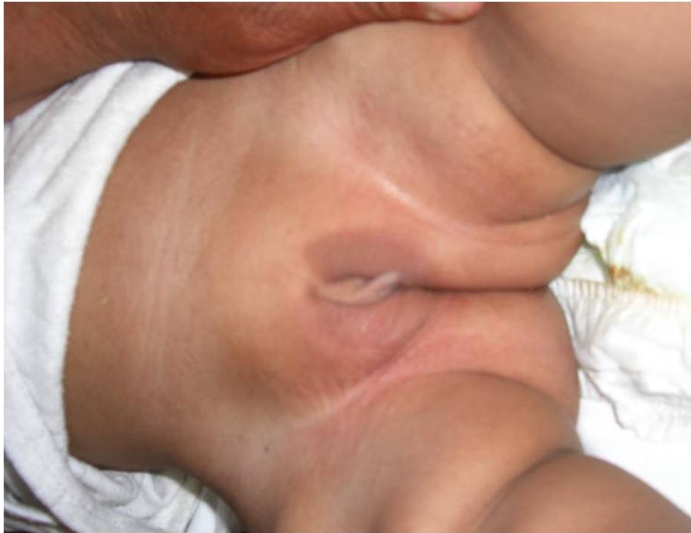

Figure 7. The two months old patient has hyperplastic clitoris, hyperpigmented tissue similar as labia majora (large lips) it was reported by genitography internal females organs were identify as vagina, uterus and both ovaries.

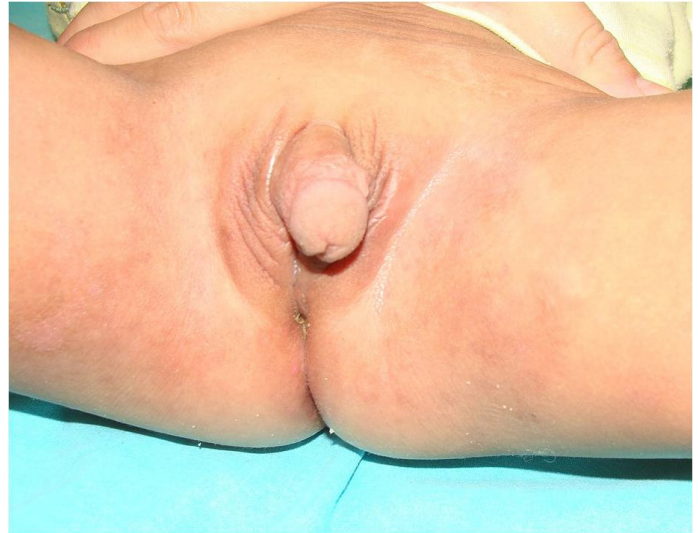

Figure 9. The last pediatric patient in this study was a 2 years 8 months old patient with hypospadias pene-escrotal, unilateral cryptorchidism, urinary meatus stenosis, and malformed scrotum.

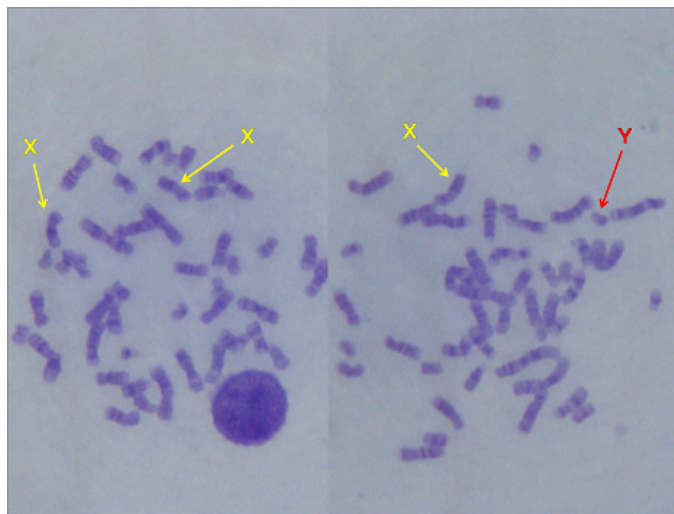


Figure 8. Karyotipe (50 metaphases) reported a chimera event with two different cell lines; 24 metaphases (48%); female 46 XX and 26 metaphases (52%); male 46XY was observed by chromosome studies, carried out on blood after GTG banding.

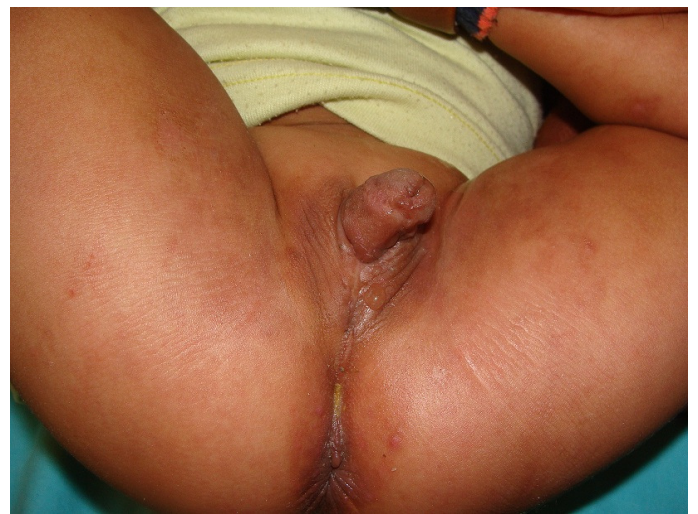

Figure 10. The last patient with hypospadias pene-escrotal, unilateral cryptorchidism, urinary meatus stenosis, and malformed scrotum, after surgery reconstruction.

from the folds, and forming the glands penis from the tubercle. The state develops from the urogenital sinus. Incomplete masculinization occurs when testosterone fails to convert to DHT. Mixed gonadal digenesis (MGD) is the second most common cause of DSD. Hypospadias occurs at a rate of 1 case per 300 live male births; in less than 1% of patients, hypospadias occurs with unilateral or bilateral cryptorchidism (Kaefe et al., 1999; Keenan, 1980). It should be diagnosed as DSD in patients with both hypospadias and cryptorchidism

(Figures 9 and 10) as in the last patient in this study with a Y;7 chromosome translocation (Figure 11). It is thought that diphallia occurs in the fetus between the 23rd and 25th days of gestation when an injury, chemical stress, or malfunctioning (Abdel, 1972; Carlos de la fuente et al., 2004; Del Vecchy et al., 1995; Kapoor and Saha, 1987; Kaufman et al., 1990; Maruyama et al., 1999; Melekos and Barbalias, 1986) homeobox genes hamper proper functioning of the caudal cell mass of the fetal mesoderm as the urogenital sinus separates from the genital tubercle and rectum to form the penis (Thomas, 2005).

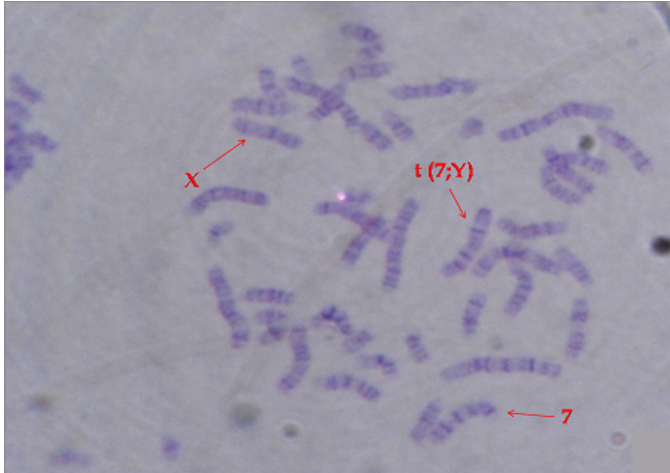


Figure 11. By genetics and cytogenetic studies chromosome were performed in the last patient, where translocation between the sexual Y chromosome and 7 was observed, $t(7;Y)$ it was also carried out on blood after GTG.

This rare condition has been documented in pigs and other mammals (Camacho-Gutierrez et al., 2004; Villanova and Raventos, 1954). It is commonly mistaken that all sharks have this condition, but in reality, they have a pair of "claspers", which serve a reproductive function.

The oldest patient was a 16 years old male with a true difallia (Figure 1, A and B), who was thought to be a female where both penises were confused to be part of female external genitalia, a difficult case where a multidisciplinary medical and psychological team had to work together with the patient in order to understand the real chromosomal and psychical sex. However, the sex orientation of this patient was that of a male, which was easier for him to accept all physical, surgical, clinical and psychological changes. Nevertheless, the patient still had her family, friends and society to affront as a new male human being. These psychosocial aspects are therefore, important for modern treatment of patients with ambiguous genitalia, which involves a team-oriented approach as mentioned before. This gender-assignment team should be as early as possible (new born) as both younger patients in this study (Figures 3 and 5), and usually involves neonatologists, geneticists, endocrinologists, surgeons, counselors, physiologists and ethicists (Hollowell, 1977). The goal is to provide appropriate medical support and counseling regarding care and therapy as in the case of the 16 years old patient. The topic of early gender reassignment is currently under debate. Moreover, Infants born with penis duplication and its related conditions have a higher death rate from various infections associated with their more complex renal or colorectal systems.

In relation to chimeric patients with a $46,XX/46,XY$ karyotype, only a small number have been reported in the

literature. In most cases, this condition has been diagnosed at birth, due to the presence of ambiguous external genitalia; however, in this study although genitals were not well developed (Figure 7), the cytogenetic diagnosis was done using two months old baby, since the family considered the baby as a normal female patient. According to Danon (1996), these cases account for about 13% of true hermaphrodites. The phenotype from these patients varies from normal male or female external genitalia (Froesch et al., 1983; Freiberg et al., 1988; Bromilow and Duguid, 1989) to different degrees of ambiguous genitalia (Fitzgerald et al., 1979; Farag et al., 1987; Poissonnier et al., 1987; Green et al., 1994; Siou et al., 1994; Sawai et al., 1994) as the patient in this study (Figure 7). Infertility in patients with $46,XX/46,XY$ results and normal genitalia have been observed in male patients (Watkins et al., 1981; Schoenle et al., 1983) and female (Bromilow and Duguid, 1989; Verp et al., 1992). In relation to the patient in this study with 48% $46,XX$ and 52% $46,XY$ from 50 metaphases in the performed karyotype (Figure 8), genitalia is considered as chimera rather than mosaic, even though a molecular analysis has not been provided. A mosaic contains genetically different cells originating from a single zygote. It results from a mitotic error during the first blastomeric division or at a later stage. Niu (2002) reported the first case of mosaicism proven at the molecular level in a hermaphrodite individual [$46,XX$ (39)/ $46,XY$ (9)]. Chimerism is a rare condition where cell lines originate from two distinct zygotes. Chimerism is thought to result from the fertilization of two oocytes by two sperms and subsequent fusion of two zygotes into one single embryo. This condition is called tetragametic chimera, confirmed with molecular studies by Green et al. (1994), Uehara et al. (1995), Bonthron (1997) and Strain et al. (1998). In conclusion, we report in this fourth patient a chimera with normal physical phenotype and ambiguous genitalia. However, in the future, polymorphic DNA marker analysis should be performed to distinguish chimera from mosaic and to determine the mechanism leading to $46,XX/46,XY$ chimera.

In the last case in this study, although the incidence of Y/autosome translocations is low (Nielsen and Rasmussen, 1976; Powell, 1984; Gardner and Sutherland, 1996), whereas involvement of non-acrocentric chromosomes often leads to infertility, in this study, all 20 observed metaphases in the last patient with $t(Y;7)$ GTG banding showed that the entire Y chromosome was translocated onto one of the chromosomes 7. The patient's father had a normal karyotype ($46,XY$), demonstrating that this was a *de novo* (Y;7) translocation (Figure 11). Our patient had normal development with normal phenotype. However, ambiguous genitalia was diagnosed by hypospadias pene-escrotal, unilateral cryptorchidism, urinary meatus stenosis, and malformed scrotum that needed urological surgery (Figures 9 and 10). The cytogenetic analysis of GTG banded chromo-

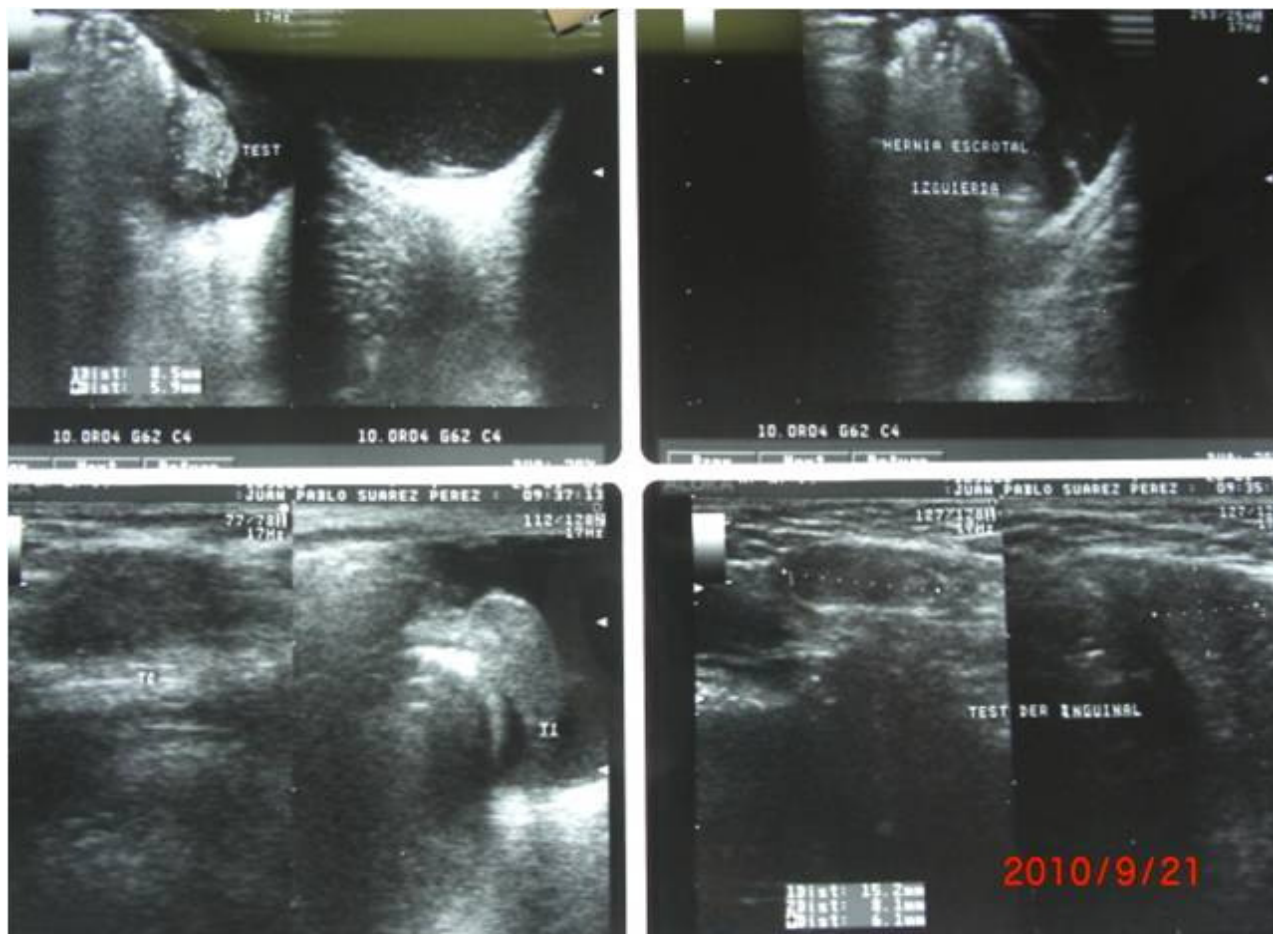


Figure 12. The last pediatric patient in this study was a 2 years 8 months old patient with hypospadias and cryptorchidism was diagnosed by urology with pelvic ultrasound studies.

some revealed a *de novo* (Y;7) translocation in all metaphase cells, where no cell mosaicism was reported (Figure 11). In the future NOR and FISH studies will be performed to detect the specific translocation breakpoints, since the patient was not taken any more by their parents to the hospital. In the present study, an abnormal segregation of the (Y;7) was found to be associated with external and internal genitalia alterations as mentioned before. Such chromosome translocation might interfere with normal Y genes specific for sexual development (Barros et al., 2001; Delobel et al., 1998; Rappold, 1993; Gabriel-Robez and Rumpler, 1990) and Y telomere deletion, which might occur during the fusion process with the autosomic chromosome 7. The selection of female embryos by pre implantation genetic diagnosis (PGD), which has become the method of choice to influence the gender of a future patient should be important. It might be considered at genetic counselling in this specific Y chromosome aberration.

Finally, in relation to mortality and morbidity, medical aspects of some other disorders of sexual development might be considered, where patients born with ambiguous

genitalia can represent a true medical and social emergency; as in the case of adrenogenital syndrome (CAH), (Amrhein et al., 1977; Bongiovanni, 1962), due to salt-wasting nephropathy that occurs in 75% of infants born with CAH, the most common cause of ambiguous genitalia, as in the pediatric hospital where this study was performed in Mexico.

Nevertheless all patients with DSD are multidisciplinary evaluated by endocrinology, urology, cytogenetics and genetics. DSD frequency might vary depending on their etiology, such as difallia, quimerism, or chromosome Y;7 translocation. However, congenital adrenal hyperplasia CAH is still the most common cause of ambiguous genitalia in the newborn (Dupont et al., 1977; Frasier et al., 1975).

The earlier the diagnosis is done, the best of the physical, sociological and psychological life for the patient, as the first 16 years old male patient with difallia in this study, who was thought by his family, friends and society to be a female patient. Some pediatric patients with DSD with a normal phenotype, the diagnosis could be missed. This might be an important issue where earlier

treatment is associated to a better quality of life for the patient.

ACKNOWLEDGMENTS

The authors would like to thank the Director of the Hospital Para El Niño Poblano, Dr. Sergio Ivan Assia Robles and the Director of the Faculty of Estomatology from the Autonomous University of Puebla, Mtro. Jorge A. Albicker Rivero, for their incondicional support.

REFERENCES

- Aarskog D (1971). Intersex conditions masquerading as simple hypospadias. *Birth Defects Orig. Artic. Ser.*, 7(6): 122-30.
- Abdel A (1972). Diphallia. *J. Urol.*, 108: 357.
- Alitalo T, Tiihonen J, Hakola P, la Chapelle A (1988). Molecular characterization of a Y;15 translocation segregating in a family. *Hum Genet.*, 79: 29-35.
- Allen TD (1976). Disorders of sexual differentiation. *Urology*, 7(4): 1-32.
- Amrhein JA, Klingensmith GJ, Walsh PC (1977). Partial androgen insensitivity: the Reifenstein syndrome revisited. *N Engl. J. Med.*, 297(7): 350-6.
- Amor D, Delatycki MB, Susman M, Casey E, Nash T, Warne G, Hutson J (1999). 46,XX/46,XY at amniocentesis in a fetus with true hermaphroditism. *J. Med. Genet.*, 36: 866-869.
- Barros A, Carvalho F, Fernandes S, Torgal A, Silva J, Sousa M (2001). Population screening of Y-chromosome microdeletions in Portugal: a study involving 428 infertile male patients. *Hum. Reprod.*, 16: 189.
- Bernstein R (1981). The Y chromosome and primary sexual differentiation. *JAMA*, 245(19): 1953-6.
- Bongiovanni AM (1962). The adrenogenital syndrome with deficiency of 3 beta-hydroxysteroid dehydrogenase. *J. Clin. Invest.*, 41: 2086-92.
- Bonthron DT (1997). Amalgamation of *in vitro* fertilized embryos, resulting in birth of a true hermaphrodite chimera. *Am. J. Hum. Genet.*, 61: A147.
- Bromilow IM, Duguid JK (1989). The liverpool chimaera. *Vox Sang.*, 57: 147-149.
- Carlos de la fuente G (2004). Duplicacion Peneana. *Revista Venezolana de Urología*, 50(2): 94-95.
- Chen CP, Chern SR, Sheu JC, Lin SP, Hsu CY, Chang TY, Lee CC, Wang W, Chen HE (2005). Prenatal diagnosis, sonographic findings and molecular genetic analysis of a 46,XX/46,XY true hermaphrodite chimera. *Prenat Diagn.*, 25: 502-506
- Cohen MM, Frederick RW, Balkin NE, Simpson SJ (1981). The identification of Y chromosome translocation following distamycin A treatment. *Clin. Genet.*, 19: 335-342.
- Danon M, Friedman SC (1996). Ambiguous genitalia, micropenis, hypospadias, and cryptorchidism. *Pediatric Endocrinology: a Clinical Guide 3rd edn* (Marcel Dekker, New York), pp. 281-304.
- de Grouchy J (1980). Jumeaux Mosaïques Chimères et autres aléas de la fécondation humaine. (Médici, Paris).
- Del Vecchio CC (1995). Difalia. Presentación de dos casos y revisión de la literatura. *Cir. Plast.*, 5(1): 21-25.
- Delobel B, Djelati R, Gabriel-Robez O (1998). Y-autosome translocation and infertility: usefulness of molecular, cytogenetic and meiotic studies. *Hum. Genet.*, 102: 98-102.
- Dupont B, Oberfield SE, Smithwick EM (1977). Close genetic linkage between HLA and congenital adrenal hyperplasia (21-hydroxylase deficiency). *Lancet*, Dec 24-31 ;2.
- European Society for Pediatric Endocrinology. ESPE (2010). www.eurospe.org. www.eurospe.org/clinical/clinical_publications.html
- Farag TI, Al-Awadi SA, Tippet P, el-Sayed M, Sundareshan TS, Al-Othman SA, el-Badramany MH (1987). Unilateral true hermaphrodite with 46,XX/46,XY dispermic chimerism. *J. Med Genet.* 24: 784-786.
- Fitzgerald PH, Donald RA, Kirk RL (1979). A true hermaphrodite dispermic Niu DM, Pan CC, Lin CY, Hwang B, Chung MY (2002). Mosaic or chimera with 46,XX and 46,XY karyotypes. *Clin. Genet.*, 15: 89-96.
- Frasier SD, Thorneycroft IH, Weiss BA (1975). Letter: Elevated amniotic fluid concentration of 17 alpha-hydroxyprogesterone in congenital adrenal hyperplasia. *J. Pediatr.*, 86(2): 310-2.
- Freiberg AS, Blumberg B, Lawce H, Mann J (1988). XX/XY chimerism encountered during prenatal diagnosis. *Prenat. Diagn.*, 8: 423-426.
- Froesch P, Schonle E, Froesch ER (1983). A patient with 46 XX/46 XY chimerism without hermaphroditism. The problem of prepupal diagnosis of the Klinefelter's syndrome. *Schweiz Med. Wochenschr.*, 113: 1065-1067.
- Gabriel-Robez O, Rumpler Y (1990). The meiotic pairing behaviour in human spermatocyte carriers of chromosome abnormalities and their repercussions on reproductive fitness. II. Robertsonian and reciprocal translocations. A European study. *Ann. Genet.*, 39: 17-25.
- Gardner RJM, Sutherland GR (1996). Chromosome Abnormalities and Genetic Counseling. Sex chromosome translocations New York, Oxford: Oxford University Press, pp. 95-114.
- Gartler SM, Waxman SH, Giblett E (1962). An XX/XY human hermaphrodite resulting from double fertilization. *Proc. Natl. Acad. Sci. USA*, 48: 332-335.
- Green AJ, Barton DE, Jenks P, Pearson J, Yates JR (1994). Chimaerism shown by cytogenetics and DNA polymorphism analysis. *J. Med. Genet.*, 31: 816-817.
- Goodfellow P, Darling S, Wolfe J (1985). The human Y chromosome. *J. Med. Genet.*, 22: 324-344.
- Hollowell JG (1977). Embryologic considerations of diphallus and associated anomalies. *J. Urol.*, 117: 728.
- Hsu LYF (1994). Phenotype/karyotype correlations of Y chromosome aneuploidy with emphasis on structural aberrations in postnatally diagnosed cases. *Am. J. Med. Genet.*, 53: 108-140.
- Hughes IA, Houk C, Ahmed SF, Lee PA (2006). Consensus statement on management of intersex disorders. *J. Pediatr. Urol.* 2(3): 148-62.
- Hunter A, Brierley K, Tomkins D (1982). 46,XX/46XY chromosome complement in amniotic fluid cell culture followed by the birth of a normal female child. *Prenat. Diagn.*, 2: 127-131.
- Imperato-McGinley J, Guerrero L, Gautier T, Peterson RE (1974). Steroid 5alpha-reductase deficiency in man: an inherited form of male pseudohermaphroditism. *Science*, 186(4170): 1213-5.
- Imperato-McGinley J, Peterson RE, Gautier T, Sturla E (1979). Male pseudohermaphroditism secondary to 5 alpha-reductase deficiency—a model for the role of androgens in both the development of the male phenotype and the evolution of a male gender identity. *J. Steroid Biochem.*, 11(1B): 637-45.
- Josso N (1971). Effect of testosterone and of some of its 17-hydroxylated metabolites on the müllerian duct of the foetal rat, in organ culture. *Rev. Eur. Etud. Clin. Biol.*, 16(7): 694-7.
- Kaefer M, Diamond D, Hendren WH, Vemulapalli S, Bauer SB, Peters CA (1999). The incidence of intersexuality in children with cryptorchidism and hypospadias: stratification based on gonadal palpability and meatal position. *J. Urol.*, 62(3 Pt 2): 1003-6.
- Kapoor R, saha M (1987). Complete duplication of the bladder, urethra, an external genitalia in a neonate: A case report. *J. Urol.*, 137: 1243.
- Kaufman A, Guia R, Davila M, Kaufman A (1990). diphallus with third urethra. *Urology*, 35: 257-260.
- Keenan BS (1980). Pseudovaginal perineoscrotal hypospadias: genetic heterogeneity. *Urol. Clin. North Am.*, 7(2): 393-407.
- Lawce H (1985). Prenatal chromosome findings in a case of XX/XY chimerism. *Karyogram*, 11: 93-94.
- Lawson Wilkins Pediatric Endocrine Society. LWPES (2008). <http://lwpes.org/>. <http://www.lwpes.org/professionals/snape/index.cfm>.
- Lillian YFH (1998). Prenatal diagnosis of chromosomal abnormalities through amniocentesis. In Aubrey Milunsky (Ed.). *Genetic Disorders and the Fetus. Diagnosis, Prevention and Treatment 4th edn* (Johns Hopkins University Press, Baltimore).
- Maruyama K, Takahashi A, Kobayashi T, Hatakeyama S, Matsuo Y (1999). Diphallia in the VATER association. *J. Urol.*, 162: 2144.
- Melekos M, Barbaliás H (1986). Penile Duplication. *Urology*, 27: 258-259.
- McLaren A, Simpson E, Tomonari K (1984). Male sexual differentiation in mice lacking H-Y antigen. *Nature*, 312(5994): 552-5.
- Nielsen J, Rasmussen K (1976). Y/autosomal translocations. *Clin. Genet.*,

- 9: 609-617.
chimera? Revisiting an old hypothesis about the cause of the 46,XY/46,XY hermaphrodite. *J. Pediatr.*, 140: 6732-735.
- Perez-Palacios G, Scaglia H, Kofan S (1975). Inherited deficiency of gonadotropin receptor in Leydig cells: A new form of male pseudohermaphroditism. *Am. J. Hum. Genet.*, pp. 27.
- Pinhas-Hamiel O, Zalel Y, Smith E, Mazkereth R, Aviram A, Lipitz S, Achiron R (2002). Prenatal diagnosis of sex differentiation disorders: the role of fetal ultrasound. *J. Clin. Endocrinol. Metab.*, 87: 4547-4553.
- Poissonnier M, Janvier D, Cabrol S, Reviron M, Noel L, Reviron J (1987). True hermaphroditism in a child with a chimeric XX/XY chromosome, a double erythrocyte population and an unusual Lewis (a+ b+) phenotype. *J. Genet. Hum.*, 35: 119-129.
- Powell C (1984). Sex chromosomes and sex chromosomes abnormalities. in Gersen SL, Keagle MB (eds) *The Principles of Clinical Cytogenetics* New Jersey, Totowa: Humana Press, pp 229-258.
- Rappold G (1993). The pseudoautosomal regions of the human sex chromosomes. *Hum. Genet.*, 92: 315-324.
- Rosenfield RL, Lucky AW, Allen TD (1980). The diagnosis and management of intersex. *Curr. Probl. Pediatr.*, 10(7): 1-66.
- Saenger P (1981). Steroid 5 alpha-reductase deficiency. In: Josso N, ed. *Intersex Child, Pediatric Adolesc. Endocrinol.*, 156-70.
- Sawai T, Yoshimoto M, Kinoshita E, Baba T, Matsumoto T, Tsuji Y, Fukuda S, Harada N, Niikawa N (1994). Case of 46,XX/47,XY, +21 chimerism in a newborn infant with ambiguous genitalia. *Am. J. Med. Genet.* 49: 428-430.
- Camacho-Gutierrez SF, Olvera-Caballero C, Barrientos-Perez M, Aparicio-Rodriguez JM (2004). Genitourinary reconstruction in a case of penis duplication associated to bladder duplication, perineal hypospadias and bowel sequestration. *Rev Mexicana de Urologia.* 64: 135-138.
- Sheehan SJ, Tobbia IN, Ismail MA (1985). Persistent Mullerian duct syndrome. Review and report of 3 cases. *Br. J. Urol.*, 57(5): 548-51.
- Smith A, Fraser IS, Elliot G (1979). An infertile man with balanced Y;19 translocation. Review of Y;autosomal translocations. *Ann. Genet.*, 22: 189-194.
- Simon-Bouy B, Plachot M, Mokdad A, Lavaud N, Muti C, Bazin A, Vialard F, Belaisch-Allart J (2003). Possible human chimera detected prenatally after in vitro fertilization: a case report. *Prenat. Diagn.*, 23: 935-937.
- Schoenle E, Schmid W, Schinzel A, Mahler M, Ritter M, Schenker T, Metaxas M, Froesch P, Froesch ER (1983). 46,XX/46,XY chimerism in a phenotypically normal man. *Hum. Genet.*, 64: 86-89.
- Siou CG, Brauner R, Lortat-Jacob S, Nivot S, Jaubert F, Fellous M, Nihoul-Fekete C, Rappaport R (1994). True hermaphroditism: genetic variants and clinical management. *J. Pediatr.*, 125: 738-744.
- Strain L, Dean JC, Hamilton MP, Bonthron DT (1998). A true hermaphrodite chimera resulting from embryo amalgamation after in vitro fertilization. *N. Engl. J. Med.*, 338: 166-169.
- Thomas RB (2005). Homebox genes internet page. <http://www.biosci.ki.se/groups/tbu/homeo.html>.
- Uehara S, Nata M, Nagae M, Sagisaka K, Okamura K, Yajima A (1995). Molecular biologic analyses of tetragametic chimerism in a true hermaphrodite with 46,XX/46,XY. *Fert. Steril.*, 63: 189-192.
- Verp MS, Harrison HH, Ober C, Oliveri D, Amarose AP, Lindgren V, Terman A (1992). Chimerism as the etiology of a 46,XX/46,XY fertile true hermaphrodite. *Fert. Steril.*, 57: 346-349.
- Viguié F, Romani F, Dadoune JR (1982). Male infertility in a case of (Y;6) balanced reciprocal translocation. *Hum. Genet.* 62: 225-227.
- Villanova X, Raventos A (1954). Pseudodiphallia, a rare anomaly. *J. Urol.*, 71: 338.
- Vogt PH, Edelmann A, Kirsch S (1996). Human Y chromosome azoospermia factors (AZF) mapped to subregions in Yq11. *Hum. Mol. Genet.*, 5: 933-943.
- Vogt PH (1999). Y chromosome and single gene defects that cause male infertility. in: Jansen R, Mortimer D (eds) *Towards reproductive certainty: fertility and genetics beyond 1999* Carnforth, UK: Parthenon, pp. 298-312.
- Watkins WM, Yates AD, Greenwell P, Bird GW, Gibson M, Roy TC, Wingham J, Loeb W (1981). A human dispermic chimaera first suspected from analyses of the blood group gene-specified glycosyltransferases. *J. Immunogenet.*, 8: 113-128.
- Walsh PC, Migeon CJ (1978). The phenotypic expression of selective disorders of male sexual differentiation. *J. Urol.*, 119(5): 627-9.
- Watchel SS, Bare J (1981). The XX testis. In: Josso N, ed. *The Intersex Child, Pediatric Adolescent Endocrinol.*, S Karger AG. pp. 116-32.
- Wilson JD (1972). Recent studies on the mechanism of action of testosterone. *N. Engl. J. Med.*, 287(25): 1284-91.
- Wilson TA, Wachtel SS, Howards S (1986). H-Y intermediate phenotype in male pseudohermaphroditism. *J. Pediatr.*, 109(5): 815-9.
- Williams DI (1981). Masculinizing genitoplasty. In: Josso N, ed. *The Intersex Child, Pediatric and Adolescent Endocrinology.* S Karger AG. pp. 237-46.
- Yaron Y, Feldman B, Kramer RL, Kasperski SB, Vo T, Feldman GL, Johnson MP, Evans MI, Ebrahim SA (1999). Prenatal diagnosis of 46,XY/46,XX mosaicism: a case report. *Am. J. Med. Genet.*, 84: 12-14.