

Full Length Research Paper

The efficacy of Ovopet® in the treatment of hip dysplasia in dogs

Andrés Aguirre^{1*}, Erena Gil-Quintana¹, Marisa Fenaux¹, Nuria Sanchez² and Celina Torre²

¹Department of Production, Quality and R&D of Eggnovo S.L., Avenida los Tilos 5, 31132 Villatuerta (Navarra), Spain.

²Department of Research of Affinity Petcare, Plaza Europa 54-56, 08902 L'Hospitalet de Llobregat, Barcelona, Spain.

Received 16 April, 2018; Accepted 3 July, 2018

Hip dysplasia is a widespread condition that can affect dogs of all ages. Hip dysplasia is caused by a subluxation in the hip joint. This leads to the development of osteoarthritis that causes inflammation and pain. At this sight, the efficacy of a supplement with Ovopet®, eggshell membrane, was evaluated together with its tolerability and safety. Forty client-owned medium sized arthritic dogs were treated daily for a period of 40 days with placebo or Ovopet®. Every ten days, the dogs were evaluated for functional limitation and joint mobility (hip functional scale), muscular atrophy and mobility range (extension-flexion rating). Dogs were also examined for blood analysis (inflammatory markers), and sonographies of the hip joint space were taken before and at the end of the study. Performances in daily life activities and vitality assessed by the owners were also recorded. Based on these observations, significant ($p<0.05$) reduction in muscular atrophy and improvement of mobility range was noted in Ovopet® treated group. Parameters such as as starting lameness, walking lameness, running and playing resistance and limitation to little jumps also experienced a significant ($p<0.05$) improvement. The parameters for function and positive behaviour description and pain sensation assessed by the owners showed a significant improvement ($p<0.05$) since day 20 of treatment. Based on recorded data, Ovopet® (15 mgKg⁻¹dog) treatment provides a significant improvement, reducing the pain the dog has and therefore improving physical function.

Key words: Ovopet®, hip dysplasia, dogs, osteoarthritis, feed supplement, eggshell membrane.

INTRODUCTION

Osteoarthritis (OA) is a painful and progressive disease that involves the permanent, long term deterioration and destruction of the cartilage and components surrounding the joints, which results in chronic pain, inflammation and decreased mobility (Henrotin et al., 2014).

The hip is one of the most common areas of OA in the body. Hip dysplasia is highly prevalent in dogs, and affects primarily large and giant breeds of dogs, never the

less this disease can also occur in medium-sized breeds and rarely in small breeds (Butler and Gambino, 2017). German Shepherds, Labrador Retrievers, Rottweiler's, Great Danes, Golden Retrievers and Saint Bernards appear to have a higher incidence, however these are all very popular breeds and may be over represented because of their popularity (Butler and Gambino, 2017). Dogs of all ages are subject to hip dysplasia and the

*Corresponding author. E-mail: produccion@eggnovo.com.

resultant OA (Gail et al., 2001).

Hip dysplasia is associated with abnormal joint structure and a laxity of the muscles, connective tissue, and ligaments that would normally support the joint. As joint laxity develops, the articular surfaces of the two bones lose contact with each other (Kyriazis and Prassinis, 2016). This separation of the two bones within the joint is called a subluxation, and this causes a drastic change in the size and shape of the articular surfaces (Butler and Gambino, 2017). OA of the hip is the result of the degeneration of the joint due to a laxity caused by hip dysplasia (Butler and Gambino, 2017). When a dog has hip dysplasia, the joint wears out abnormally and the protective cartilage on the surface of the joint deteriorates and the resultant bone-to-bone contact creates pain (Butler and Gambino, 2017).

Moreover, the degenerative changes of OA appear frequently causing inflammation and pain (Henrotin et al., 2014). Pain is also related with the inflammation of the joint (synovitis) (Henrotin et al., 2014). This pain makes the dogs shift most of their body weight to the front end. As a result, dogs showing few clinical symptoms may develop increased shoulder musculature while hind limb musculature remains under-developed (Kyriazis and Prassinis, 2016). As damage to the joint progresses and secondary OA sets in, symptoms of stiffness and lameness may be present (Kyriazis and Prassinis, 2016).

Some forms of degenerative joint disease can be treated with surgery but drugs are the most common therapy for OA treatment. Nevertheless, pharmacological treatment is limited to clinical signs alleviation (Comblain et al., 2016). In this way, non-steroidal anti-inflammatory (NSAIDs) are commonly prescribed to address anti-inflammatory mechanisms. Unfortunately, the use of NSAIDs may be associated with detrimental effects, especially gastrointestinal side effects (Comblain et al., 2016). Some clinical studies have highlighted the beneficial effects of dietary supplement for the treatment of OA in dogs (Comblain et al., 2016).

Glucosamine and chondroitin are two compounds that have been widely used for the treatment of OA in animals. These aminosaccharides act as a preferred substrate for the biosynthesis of glycosaminoglycan (GAG) chains, and subsequently for the production of aggrecan, main proteoglycan used by chondrocytes to build the cartilage extracellular matrix (ECM). They also exert anti-inflammatory and anti-catabolic effects through the inhibition of nuclear factor κ B (NF- κ B) binding activity (Comblain et al., 2016).

Ovopet® is an innovative ingredient obtained from egg shell membranes at Eggnovo S.L. via a patented process. Eggshell membrane discovery as a natural source of glycosaminoglycan's, such as chondroitin sulfate and hyaluronic acid among others, has led to the consideration of this product as a potential approach for the treatment of OA as shown in a previous study (Blasco

et al., 2016).

The goal of the present study is to assess the effectiveness of Ovopet® in the treatment of hip dysplasia and the consequent OA in dogs.

MATERIALS AND METHODS

Dog selection

A group of adults (63% female), privately owned arthritic dogs were used in this study. Their age was between 1 to 13 years old, with an average of 8 ± 0.56 years. All the participants were medium-sized dogs. Their body mass ranged from 15 to 40 kg, with an average of 34 ± 1.05 kg. The body condition of the 66% of the dogs was ideal according to the body condition score published in the manufacturer's site (http://www.affinitypetcare.com/veterinary/obesity/obesity_dog/flash/bcs.html). The German Shepherd was the most common breed (40% of dogs) followed by Labrador and Golden (15% of dogs each). All dogs had radiographic evidence of hip dysplasia. They were recently diagnosed dogs in all cases, so they had not been previously treated with chondroprotective supplements or diets. Besides the afore mentioned stated inclusion criteria, the owner had to describe at least one of the following signs: difficulty to stand up, difficulty to jump, difficulty to climb stairs or clear lameness. The study protocol was performed in compliance with national guidelines for research on animals. Throughout the study, dogs remained with their owners. The owner's consent was obtained at the beginning of the study.

Nutraceuticals

Ovopet® was obtained from Eggnovo S.L. (Navarra, Spain) in a sustainable and environmentally friendly manner without the use of chemicals. It consists of egg membranes separated from eggshells by a patented process. Compositional analysis of Ovopet® has identified a high content of protein (collagen types I-V-X, elastin, keratin) and moderate quantities of GAGs (chondroitin sulfate, HA) and glucosamine. Snacks were prepared by a Spanish pet food manufacturer.

Study protocol

The randomized and double-blind with placebo study was carried out in cooperation with Eudald Toralles and Sentmenat Veterinary Clinics (Barcelona). The veterinary monitoring was performed at days 0, 10, 20, 30 and 40. Veterinary Clinics were in charge of recruiting the dogs with hip dysplasia, getting the owners signed consent and performing the standard clinical tests according to the study protocol. If the inclusion criteria were met, the dogs could take part in the study. Firstly, the veterinary filled in the dogs' data (breed, age, body condition, sex and diet), did a clinical examination of the dog before starting the treatment and evaluated the OA grade with the Kellgren-Lawrence scale (Kohn et al., 2016). Based on the weight of the dog the veterinary established, the amount of fodder and the number of snacks that dogs had to intake during the study. This amount was revised in every veterinary visit to adjust the dosage of fodder. The performed protocol in each assessment day was as follows:

- (1) To assess the muscle atrophy by measuring the perimeter of the rear legs
- (2) To evaluate the extension-flexion range of the hip

- (3) To fill in a hip functional scale questionnaire
- (4) To fill in an evaluation questionnaire together with the owner
- (5) To fill in the side effects questionnaire
- (6) To draw blood for measuring inflammatory blood markers (at day 0 and 40)
- (7) To make a sonography of the hip (at day 0 and 40)

Two groups of patients were established, one taking the chondroprotective supplement with Ovopet® (N=30) and the other group taking the placebo supplement (the same recipe but without Ovopet®) (N=10). The treatment lasted 40 days and the recommended daily dose of Ovopet® was 15 mg Kg⁻¹ dog day⁻¹. The only authorised pharmacological treatment, when the lameness was intense or the quality of life decreased markedly was Metacam. The owners and the veterinary noted down if the dog needed rescue drugs.

Kellgren-Lawrence classification of OA degree

The OA degree (from 1 to 4) was classified using the Kellgren-Lawrence grading scale. The grades in the scale are described as follows:

Grade 1: Doubtful narrowing of joint space and possible osteophytic lipping.

Grade 2: Definite osteophytes, definite narrowing of joint space.

Grade 3: Moderate multiple osteophytes, definite narrowing of joint space, some sclerosis and possible deformity of bone contour.

Grade 4: Large osteophytes, marked narrowing of joint space, severe sclerosis and definite deformity of bone contour.

Assessment of muscular atrophy

The circumference of each thigh was measured at standard anatomical references based on the Bioarth assessment scale (Villaret al., 2016; Cuervo et al., 2014). The same investigator performed all measurements using a measure ribbon.

Assessment of flexion-extension range

To evaluate the hip mobility range, the veterinarian measured the flexion and extension degrees of the hip every ten days based on the Bioarth assessment scale (Villaret al., 2016; Cuervo et al., 2014). The range of movement was measured bilaterally for the hip using a goniometer. These measurements were taken for the maximum possible extension and flexion values.

Hip functional scale

The hip functional scale is an adaptation of the Bioarth assessment scale (Villaret al., 2016) to quantify the degree of OA. This is the questionnaire that the supplement manufacturer R&D department trained personnel employs for researching. The questionnaire contains two different sections: functional limitation and joint mobility. The functional limitation assesses the lameness before starting to walk, the lameness during walk, the resistance to walk, the resistance to run and play, the difficulty to climb stairs and the difficulty in little jumps. The joint mobility assesses the pain at manual mobilisation of the hip, the pain during palpation and the pain during movement. These parameters were assessed by the veterinarian in the clinical visits every ten days. The scale for most of the questions goes from one (no functional limitation or no pain) to four (complete functional limitation or extreme pain). However, some items use a three-point scale, such as, difficulty in little

jumps, pain during palpation and pain during movement.

Evaluation questionnaire with the owner

The evaluation questionnaire that the veterinarian completed with the owner is based partially on the Canine Brief Pain Inventory (Brown et al., 2018) and is divided in three sections: description of function, description of positive behaviour and visual scale. The description of the function compiles different questions in relation to the general activity of the dog, the ability to standing up from lying down, the ability to walk, the ability to run and the ability to climb stairs. The description of positive behaviour includes two questions: mood and feel like playing. The visual scale refers to the severity of the pain that the owner thinks that his/her dog suffers. Each section has different items and each item has a numerical rating scale from 0 to 10. Zero means no pain (or that pain does not interfere) and ten means extreme pain (or that pain interferes completely). Besides individual measurements for each parameter we obtained an average value for all the parameters included in the description of the function and another for the description of positive behaviour. The improvement with respect to the beginning of the study was calculated for each treatment (mean day 40 – mean day 0) x100 / mean day 0). We also calculated the difference in improvement between therapy and placebo (mean treatment – mean placebo).

Blood analysis

Blood was obtained from the cephalic vein for biochemical analyses of inflammation markers. It was collected under aseptic conditions in 5 ml tubes, and then centrifuged for 5 min at 2000 rpm to collect serum. Serum samples were analysed for Tumour necrosis factor- α (TNF- α) and nitric oxide (nitrite/nitrate) (NO). TNF α assay was performed using canine TNF α commercial ELISA set from R&D (Ref. CATA00, R&D systems, La Jolla, CA), following the manufacturer's instructions. No assay was performed as previously described (Miranda, Espey and Wink, 2001; García-Robledo, Corzo and Papaspyrou, 2014).

Sonography

Sonographic evaluations were performed under routine sedation in all dogs using the Vivid I (GE Healthcare, Wauwatosa, WI, USA) ultrasound system at day 0 and 40 after treatment. Linear transducer 12L-RS of high frequency (5-13 MHz) was used for the ultra sound examination. The animals were placed in dorsal decubitus, with posterior members in neutral position (between 10° flexion and 30° extension, 10° and 30° abduction and 0° and 10° external rotation), the knees forming an angle of 90° between the femur and the tibia/fibula. The images of the coxofemoral joints (both hips) were obtained in three sagittal views parallel to the longitudinal axis of the lateral side of the hip, dorsal to the greater trochanter of the femur. The measurement of the distance between the femur head and the acetabulum was taken for each view and the major value was considered for statistical analysis.

Statistical analysis

Data were analysed using the GraphPad (GraphPad Prism version 6.0 for Windows, GraphPad Software, Inc) program and the Epi Info TM (Epi Info version 7 for Windows, CDC). Data were assessed for normality with the D'Agostino and Pearson normality test, and for homoscedasticity with the Bartlett's test. Parametric analyses were performed with one-way ANOVA with repeated measures followed by Holm Sidak's multiple comparison post-test. Non-parametric

samples were compared with Friedman test for related samples.

RESULTS

All participants completed the study. The percentage of dogs taking part in the supplement study was similarly distributed among grade 1, grade 2, grade 3 and grade 4 of OA. Most of the dogs fulfilled two of the following inclusion criteria (48%): difficulty to stand up, difficulty to jump, difficulty to climb stairs or clear lameness, where the difficulty to stand up was the most common sign. Dogs were not administered rescue pain medication. The possible side effects related to the treatment such as: changes in appetite, vomits, diarrhoea and skin reactions were assessed in each veterinary visit. No significant side effects were seen during the treatment with Ovopet® and the veterinary did not relate the observed symptoms with Ovopet® as similar reactions were seen in the placebo group. Moreover, an initial test was carried out in 10 dogs giving them ten times the recommended daily dosage for 50 days to assess that Ovopet® was safe.

Assessment of muscular atrophy

A gradual improvement in the muscular perimeter in the group treated with Ovopet® was observed along the study reaching a significant improvement of 7.3% in the right ($p < 0.0001$) and 8.9% in the left ($p < 0.0001$) rear legs after 40 days of treatment with Ovopet® (Figure 1A and B). The placebo group showed only a slight increase (2.8%, $p = 0.3155$ and 3.2%, $p = 0.0011$) which differs from the continuous improvement showed in both legs of treated dogs since day 20 of treatment.

Assessment of flexion-extension range

To evaluate the hip mobility range, the veterinarian measured the flexion and extension degrees of the hip every ten days. Two patterns were observed depending on the treatment; the control group showed a significant increase in the flexion range (right rear leg, $p = 0.0266$ and left rear leg, $p = 0.0243$) during the study while in the dogs treated with Ovopet® this parameter was significantly reduced ($p = 0.0001$) in the right rear leg and it showed a tendency to decrease in the left rear leg (Figure 1C and D). The opposite occurred with the extension angles, which augmented significantly only in the treated group (right rear leg, $p < 0.0001$ and left rear leg, $p = 0.0011$) (Figure 1E and F).

Hip functional scale

The functional limitation assesses the lameness before starting to walk, the lameness during walk, the resistance

to walk, the resistance to run and play, the difficulty to climb stairs and the difficulty in little jumps (Figure 2A, B, C, D, E and F, respectively). In general, the pattern of each treatment was different. In the treated group of dogs, for the lameness before starting to walk ($p = 0.005$), the lameness during walk ($p = 0.0389$), the resistance to run and play ($p = 0.0038$) and the difficulty in little jumps ($p = 0.01$), there was a significant decrease while the placebo group remained stable or even augmented, although not significantly (Figure 2A, B, D and F). The assessment of the resistance to walk ($p = 0.0015$) and the difficulty to climb stairs ($p = 0.0024$) showed a progressive decrease after treatment which failed to reach statistical significance in the ANOVA post hoc tests. The opposite occurred with the placebo group, which showed a tendency to increase progressively (resistance to walk) or remained stable (difficulty to climb stairs) (Figure 2C and E).

The joint mobility assesses the pain at manual mobilisation of the hip, the pain during palpation and the pain during movement, parameters that the veterinarian measured in the clinical visits every ten days (Figure 3A, B and C respectively). In the group treated with Ovopet® there was a gradual decrease in pain since day 10 until the end of the study. There were statistically significant differences in the pain at manual mobilization of the hip ($p = 0.0008$) and in the pain during palpation ($p = 0.0193$) while the pain during movement only showed a tendency to decrease. Evaluation questionnaire with the owner compiles different questions in relation to the general activity of the dog (Figure 4A), the ability to stand up from lying down (Figure 4B), the ability to walk (Figure 4C), the ability to run (Figure 4D) and the ability to climb stairs (Figure 4E).

At the end of the study, there was a 5,6% of improvement in the description of the function between the treated and the placebo group. Focusing on each item, the general activity of the dogs that took Ovopet® increased significantly ($p < 0.0001$) since the beginning of the study while the general activity of the placebo group was maintained stable along the research. Similarly, in the rest of the items there was a progressive and significant improvement in the treated dogs compared to the placebo group: ability to rise from lying down ($p < 0.0001$), ability to walk ($p < 0.0001$), ability to run ($p < 0.0001$) and ability to climb stairs ($p < 0.0001$).

The description of positive behaviour includes two questions: mood (Figure 5A) and feel like playing (Figure 5B). In both items there was a significant ($p = 0.0006$ for mood and $p < 0.0001$ for desire to play) improvement between Ovopet® and placebo from day 20 on. This progress was 7,6% at day 40. The visual scale refers to the severity of the pain that the owner thinks that his/her dog suffers. In the placebo group the pain maintained stable along the study while in the group treated with Ovopet® there was a progressive and significant ($p < 0.0001$) decrease in pain (Figure 5C). The significant

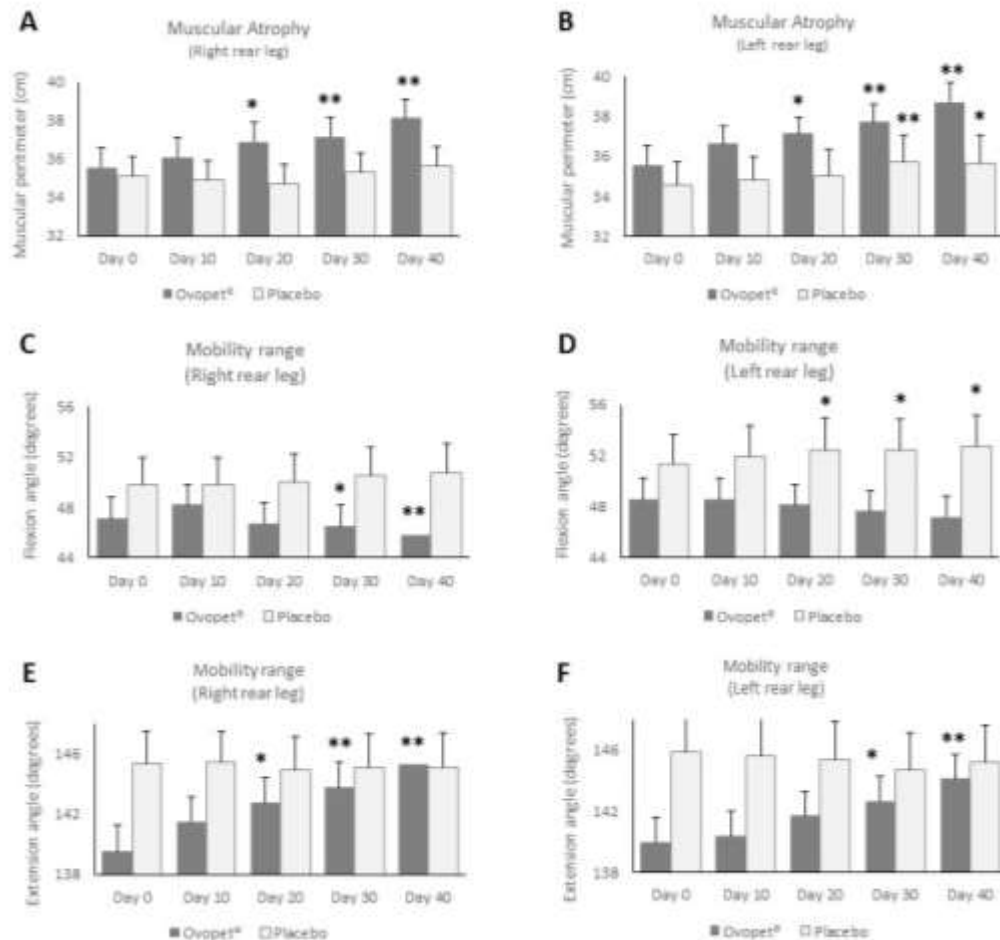


Figure 1. Evolution of the muscular perimeter and the mobility range (flexion and extension) during the treatment with Ovopet®. Muscular perimeter in the right (A) and in the left rear leg (B). Flexion of the right (C) and the left rear leg (D). Extension of the right (E) and the left rear leg (F). Black asterisks indicate significant differences ($p \leq 0.05$) when compared to basal values in the post-test. Values are represented as mean \pm SEM.

decline in pain in the treated group was 46.9% at the end of the treatment compared to day 0. Moreover, the difference in pain between the placebo and the Ovopet® group at day 40 was 37.9% less pain in the Ovopet® group.

Blood analysis

Anti-inflammatory blood markers, such as NO and TNF- α , were analysed before treatment and at the end of the study. A change in NO levels from 19.4 to 35.6 $\mu\text{mol/L}$ reflects an 83.6% increase in NO in the placebo group ($p=0.0645$) while levels in the Ovopet® treated group remained stable (Figure 6). Serum levels of TNF α did not differ significantly between treated and placebo group. Most of the values were below the detection levels (data not shown).

Sonography

The hip joint space from the legs was measured at day 0 and at day 40 using ultrasounds (Figure 7). The results showed a significant decrease in the joint space of both legs in the dogs treated with Ovopet® (Figure 7A and B) while in the placebo group the joint space maintained or increased. The improvement in synovitis at the end of the study was 19.6 and 24% in the right and left legs of Ovopet® treated dogs respectively (Figure 7C). The % of improvement in the Ovopet® group was statistically significant as compared with the placebo group in both legs ($p=0.0019$ and $p<0.0001$).

DISCUSSION

Medical treatment of hip dysplasia and OA has greatly improved in the last several years thanks to the

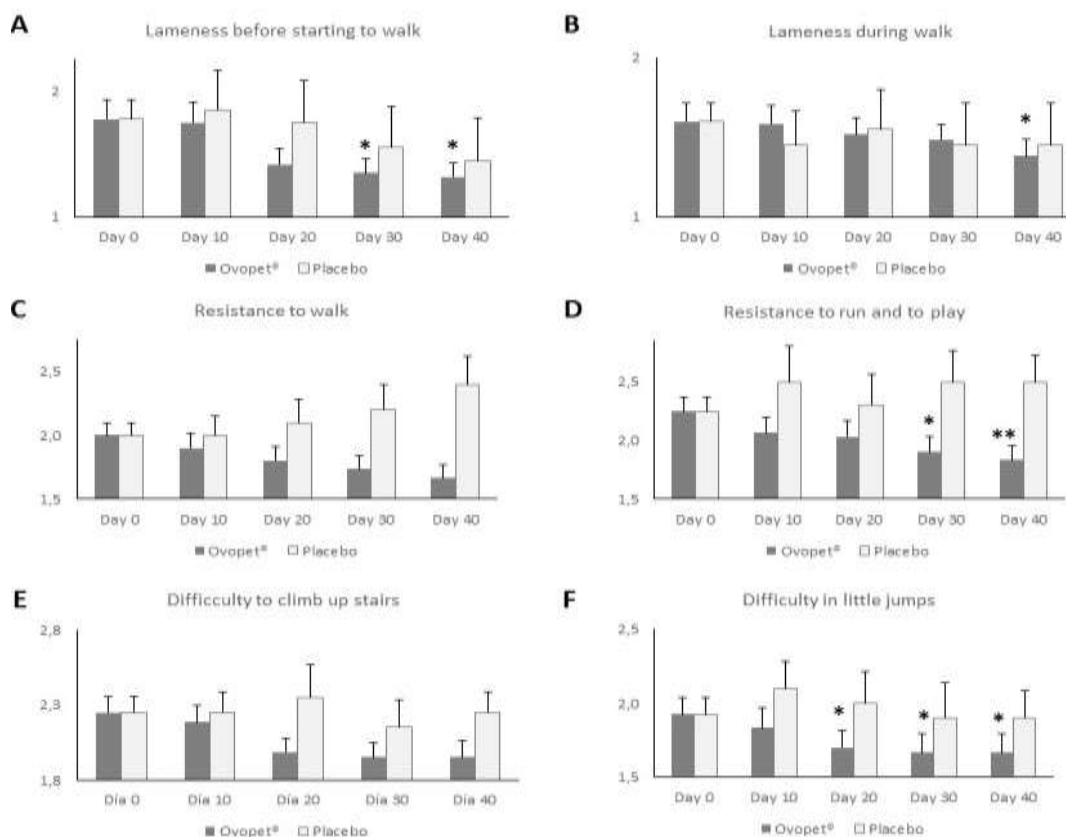


Figure 2. Evolution of the functional limitation parameters in the hip functional scale during the treatment with Ovopet®: lameness before starting to walk (A), lameness during walk (B), 0 resistance to walk (C), resistance to run and to play (D), difficulty to climb up stairs (E) and difficulty in little jumps (F). Black asterisks indicate significant differences ($p \leq 0.05$) when compared to basal values in the post-test. Values are represented as mean \pm SEM.

introduction and approval of several new supplements and drugs (Scott et al., 2017). In the present study, we have tested the efficacy of a novel dietary supplement Ovopet®, obtained from eggshell membranes, for the treatment of OA in dogs with hip dysplasia. OA is a condition that causes pain, inflammation and stiffness in joints (Barrouin-Melo et al., 2016) that are associated with ligamentous laxity and muscle weakening (Arden and Nevitt, 2006).

Although there is a lack of consensus in the research community regarding the outcomes that should be assessed in canine OA, validated and objective methods are urged (Belshaw et al., 2016), for instance, the goniometer to measure the hip range of motion (Jaegger et al., 2002), imaging (de Sousa et al., 2017) or the use of validated questionnaires (Belshaw et al., 2016). The efficacy assessment Invacion-Eggnovo performed in the present study aims to measure both, objective and semi-objective outcomes related to the known symptoms of OA and the physical limitations of the patients, to prove the efficacy of the natural and innovative eggshell-derived dietary supplement.

One of the symptoms associated to OA is the muscle weakening or muscular atrophy (Arden and Nevitt, 2006). In the present study, the muscular perimeter of rear legs was significantly improved in the Ovopet® group together with the range of motion (extension and flexion) of the hip. The decrease in the extension angle of dogs suffering hip dysplasia has been proven to worsen each year of a dog's life leading even to the inability of the dog to run, jump or climb steps (Greene et al., 2014; Dycus et al., 2017). Therapeutic exercises and diverse physical therapies have been employed to improve the hip range of motion and to decline OA symptoms such as muscle atrophy, pain, inflammation (Dycus et al., 2017). At the sight of the results, Ovopet® appears as an alternative treatment to improve the mobility range of dogs suffering OA and hip dysplasia.

In this study, enhanced joint mobility and functionality were observed in treated dogs. The joint mobility parameter was based on a veterinary physical examination to evaluate pain. To our knowledge, although the assessment of pain has not been validated to be completed by veterinary surgeons, there is a need

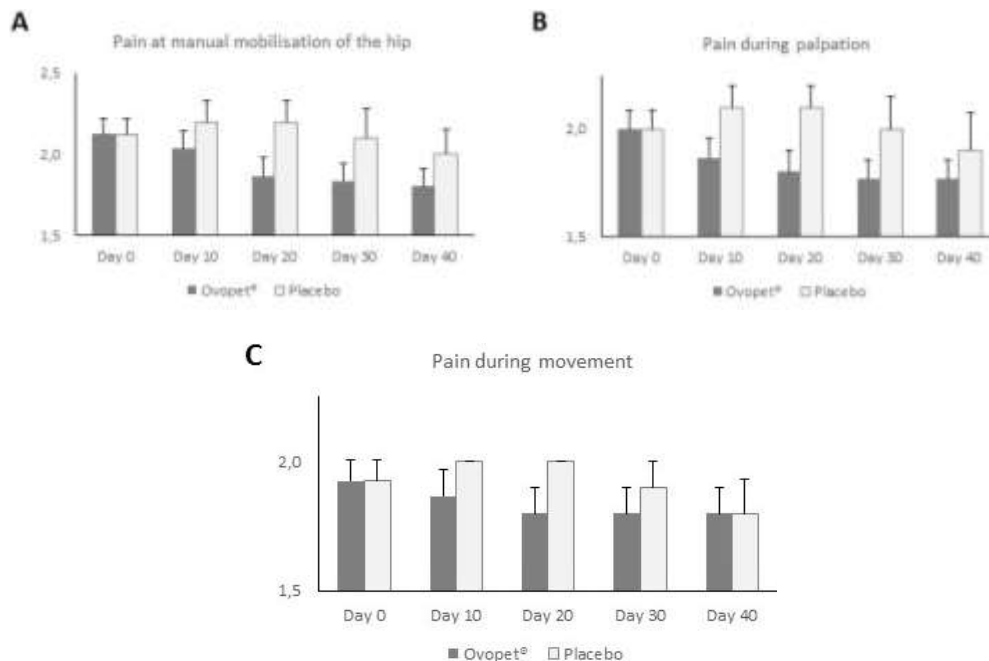


Figure 3. Evolution of the joint mobility parameters in the hip functional scale during the treatment with Ovopet®: pain at manual mobilisation of the hip (A), pain during palpation (B) and pain during movement (C). Black asterisks indicate significant differences ($p \leq 0.05$) when compared to basal values in the post-test. Values are represented as mean \pm SEM.

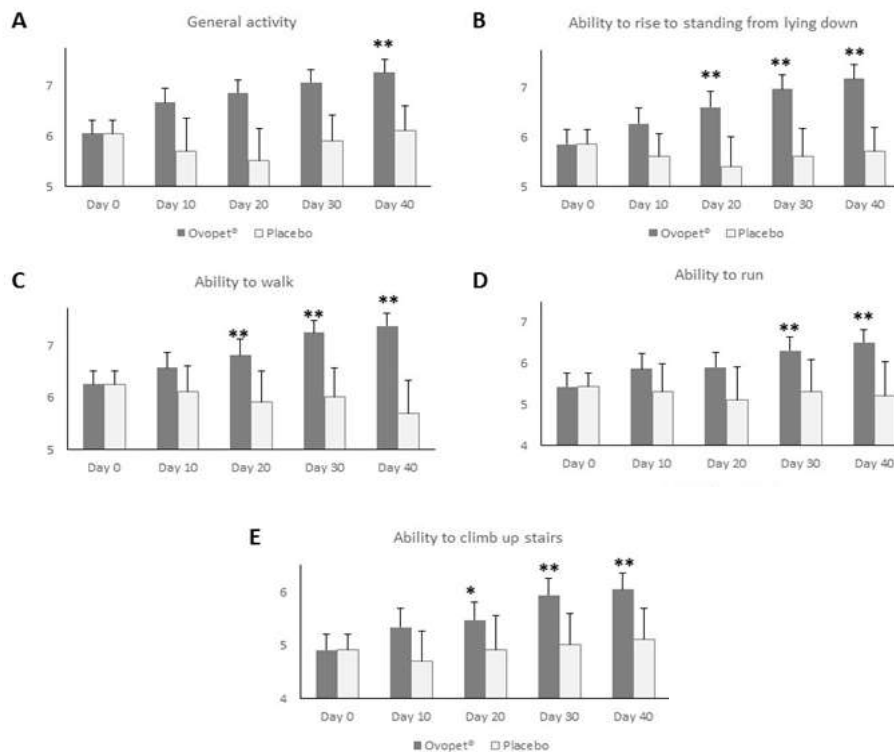


Figure 4. Evolution of the function description in the evaluation made by owners during the treatment with Ovopet®: general activity (A), ability to rise to standing from lying down (B), ability to walk (C), ability to run (D) and ability to climb up stairs (E). Black asterisks indicate significant differences ($p \leq 0.05$) when compared to basal values in the post-test. Values are represented as mean \pm SEM.

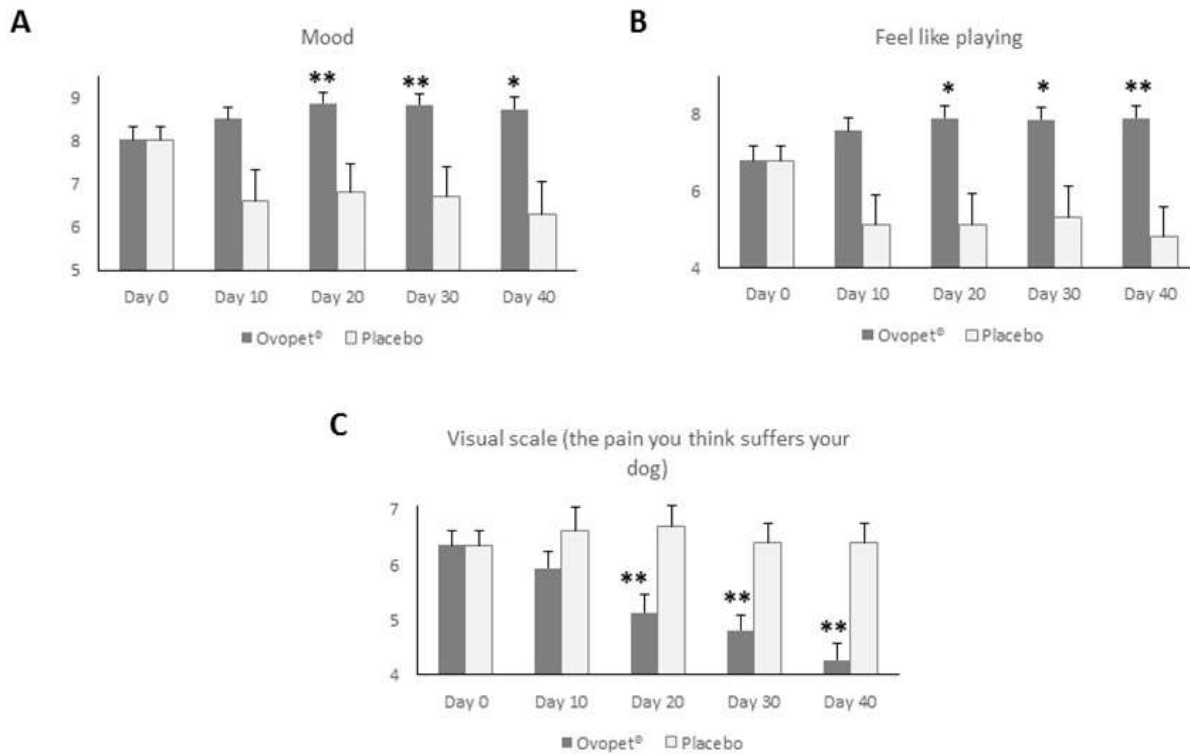


Figure 5. Evolution of the positive behaviour, mood (A) and feel like playing (B), and the pain that the owner thinks that suffers the dog (C) during the treatment with Ovopet®. Black asterisks indicate significant differences ($p \leq 0.05$) when compared to basal values in the post test. Values are represented as mean \pm SEM.

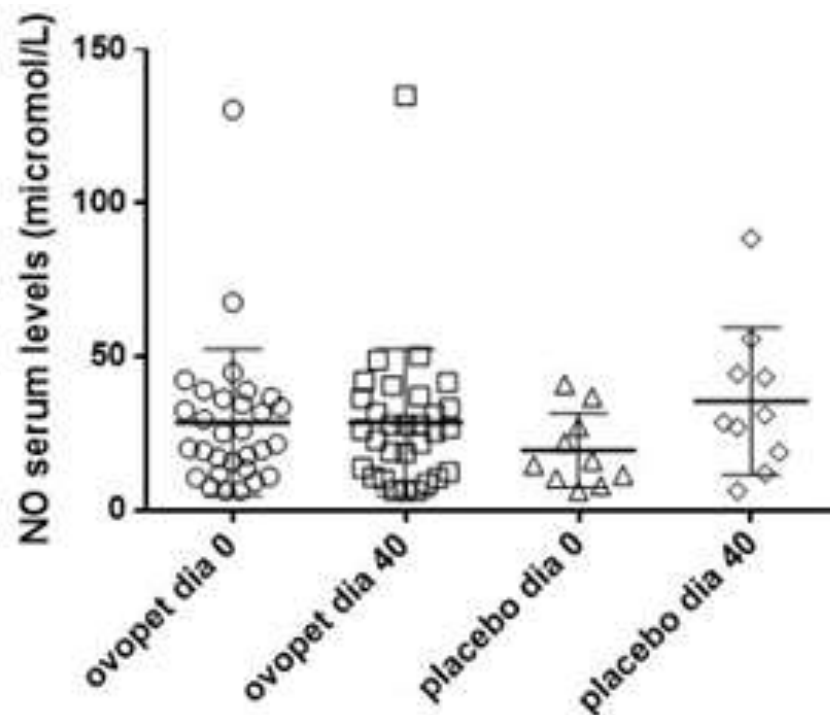


Figure 6. Serum levels of the inflammatory blood marker nitric oxide (NO) before and 40 days after treatment with placebo or Ovopet®. The horizontal line represents the mean \pm SEM.

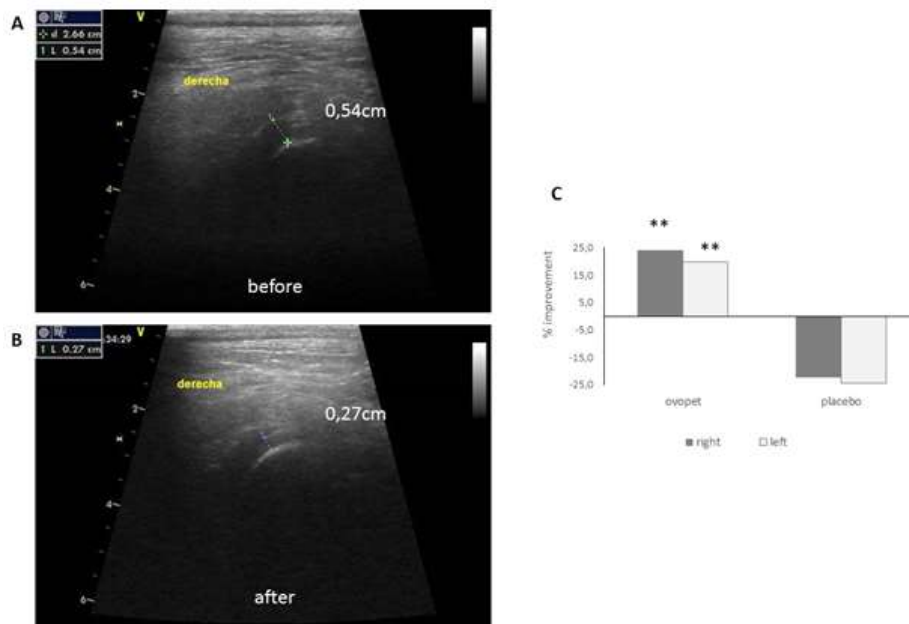


Figure 7. Sonographic evaluation of the evolution of the hip joint space after the treatment with Ovopet®. A: right hip of one treated dog before Ovopet® treatment. B: right hip of the same treated dog after treatment with Ovopet®. C: % of improvement of the hip joint space at the end of the study. (n = 30 for Ovopet®; n = 10 for placebo). Black asterisks indicate significant differences ($p \leq 0.05$) when compared to placebo.

to somehow measure pain by professionals as it is one of the most common outcomes when measuring canine OA (Belshaw et al., 2016). A tendency to decrease pain was measured in Ovopet® group that was not observed in the placebo group. The evaluation made by owners helped us to assess the function description and positive behaviour. In all the categories evaluated in the evolution of the function description there was significant improvement only in the Ovopet® treated group while in the dogs treated with placebo, all the parameters remained stable or even worsened. This is in contrast to what previously was observed in the evaluation of a patient response to treatment, where there was a caregiver placebo effect (Scott et al., 2017).

Here, the placebo effect associated with the owners of the dogs regarding the function description was not observed in this study population which is in concordance with the statement of other researchers saying that when looking at the group average change in animal OA, there is no a placebo effect (Gagnon et al., 2017). Similarly, to assess canine behavioural changes affected by pain, an owner-reported instrument was employed. The detailed behaviour-based assessment performed by the owners have been extensively employed (Belshaw et al., 2014; Essner et al., 2017) and offer the advantage of an extended assessment of dogs in their typical environment and routine (Sharkey, 2013). These results are in good concordance with the data obtained in the hip

functional scale for functional limitation that was assessed by the veterinarian. They are also in concordance with data of mobility range, which revealed an improvement of the flexion and extension angles, and with muscular atrophy, which showed an increase of the rear legs perimeter.

In OA and in synovitis there is an increase in the production of pro-inflammatory factors (Mobasheriet al., 2017; Bhattaram and Chandrasekharan, 2017). The anti-inflammatory properties attributed to eggshell membrane that are potentially responsible for reducing inflammatory cytokines IL-1 β and TFN- α are shown in rats (Ruff and De Vore, 2014). There is a need to prove these effects in clinical studies with eggshell membrane products used as nutraceutical compounds for dogs. Our finding of decreased NO blood concentration in treated dogs, although failed to be significantly different, may indicate that a similar anti-inflammatory mechanism was conferred by Ovopet®. Moreover, hip joint space was analysed by ultrasounds, revealing a significant narrowing of the hip joint space. The results obtained for blood measurements of NO and the sonographic evaluation of hip joint space indicates that Ovopet® was capable of reducing the inflammation.

The goal of dietary supplements intended to treat OA is to provide relief to the major clinical signs of OA. Ovopet® arises as an effective supplement to decline inflammatory pain, functional disability, lameness and

inflammation associated to hip dysplasia and OA, and therefore, to improve the quality of life of dogs. The data obtained in the present study support the use of this dietary supplement as an effective treatment for hip dysplasia and OA. Further research is needed to ascertain and better understand the mechanisms underlying the mode of action of eggshell membrane in osteoarthritic joints. For instance, the measurement of some biomarkers such as fragments of collagen type II (de Sousa et al., 2017) could be useful to gain insights in this complex mechanism.

CONFLICT OF INTERESTS

The authors have not declared any conflict of interests.

ACKNOWLEDGEMENTS

The authors wishes to express their gratitudes to the Eco-innovation Initiative of the European Union for co-founding the research.

REFERENCES

- Arden N, Nevitt MC (2006). Osteoarthritis: Epidemiology. *Best Practice and Research Clinical Rheumatology* 24(1):15-26.
- Barrouin-Melo SM, Anturaniemi J, Sankari S (2016). Evaluating oxidative stress, serological and haematological status of dogs suffering from osteoarthritis, after supplementing their diet with fish or corn oil. *Lipids in Health and Disease* 15(1):139.
- Belshaw Z, Asher L, Dean RS (2016). Systematic Review of Outcome Measures Reported in Clinical Canine Osteoarthritis Research. *Veterinary Surgery* 45(4):480-487.
- Bhattaram P, Chandrasekharan U (2017). The joint synovium: a critical determinant of articular cartilage fate in inflammatory joint diseases. In *Seminars in Cell and Developmental Biology* Academic Press. 62:86-93.
- Blasco J, Aguirre A, Gil-Quintana E, Fenaux M (2016). The effect of daily administration of 300 mg of Ovomet® for treatment of arthritis in elderly patients. *International Journal of Clinical Rheumatology* 11(5):077-081.
- Brown DC, Boston RC, Coyne JC, Farrar JT (2008). Ability of the Canine Brief Pain Inventory to detect response to treatment in dogs with osteoarthritis. *Journal of the American Veterinary Medical Association* 233(8):1278-83.
- Butler JR, Gambino J (2017). Canine hip dysplasia: Diagnostic imaging. *Veterinary Clinics: Small Animal Practice* 47(4):777-793.
- Comblain F, Serisier S, Barthelemy N, Balligand M, Henrotin Y (2016). Review of dietary supplements for the management of osteoarthritis in dogs in studies from 2004 to 2014. *Journal of veterinary pharmacology and therapeutics* 39(1):1-15.
- Cuervo B, Rubio M, Sopena (2014). Hip osteoarthritis in dogs: a randomized study using mesenchymal stem cells from adipose tissue and plasma rich in growth factors. *International Journal of Molecular Sciences* 15:13437-13460.
- De Sousa EB, dos Santos GC, Duarte MEL, Moura Neto V, Aguiar DP (2017). Metabolomics as a promising tool for early osteoarthritis diagnosis. *Brazilian Journal of Medical and Biological Research* 50(11):6485.
- Dycus DL, Levine D, Marcellin-Little DJ (2017) Physical Rehabilitation for the Management of Canine Hip Dysplasia. *Veterinary Clinics: Small Animal Practice* 47:823-850.
- Gail K, Smith VMD, Philipp D (2001). Evaluation of risk factors for degenerative joint disease associated with hip dysplasia in German Shepherd Dogs, Golden Retrievers, Labrador Retrievers and Rottweilers. *Journal of the American Veterinary Medical Association* 219(12):1719-1724.
- García-Robledo E, Corzo A, Papaspyrou S (2014). A fast and direct spectrophotometric method for the sequential determination of nitrate and nitrite at low concentrations in small volumes. *Marine Chemistry* 162:30-36.
- Greene LM, Marcellin-Little DJ, Lascelles BD (2013). Associations among exercise duration, lameness severity, and hip joint range of motion in Labrador Retrievers with hip dysplasia. *Journal of the American Veterinary Medical Association* 242(11):1528-1533.
- Henrotin Y, Lambert C, Richette P (2014). Importance of synovitis in osteoarthritis: Evidence for the use of glycosaminoglycans against synovial inflammation. *Seminars in Arthritis and Rheumatism* 43(5):579-587).
- Jaegger G, Marcellin-Little DJ, Levine D (2002). Reliability of goniometry in Labrador Retrievers. *American journal of veterinary research* 63(7):979-986.
- Kohn MD, Sassoon AA, Fernando ND (2016). Classifications in Brief: Kellgren-Lawrence Classification of Osteoarthritis. *Clinical Orthopaedics and Related Research* 474:1886-1893.
- Kyriazis A, Prassinou NN (2016). Canine hip dysplasia. Part I. Aetiopathogenesis & diagnostic approach. *Hellenic Journal Companion Animal Medicine* 5(1):36-47.
- Miranda KM, Espey MG, Wink DA (2001). Nitric Oxide: Biology and Chemistry. A Rapid, Simple Spectrophotometric Method for Simultaneous Detection of Nitrate and Nitrite 5(1):62-71.
- Mobasheri A, Rayman MP, Gualillo O, Sellam J, van der Kraan P, Fearon U (2017). The role of metabolites in the pathogenesis of osteoarthritis. *Nature Reviews Rheumatology* 13(5):302-311.
- Ruff KJ, De Vore DP (2014). Reduction of pro-inflammatory cytokines in rats following 7-day oral supplementation with a proprietary eggshell membrane-derived product. *Modern Research in Inflammation* 3(1):19-25.
- Scott RM, Evans R, Conzemius MG (2017). Efficacy of an oral nutraceutical for the treatment of canine osteoarthritis. *Veterinary and Comparative Orthopaedics and Traumatology* 30(05):318-323.
- Sharkey M (2013). The challenges of assessing osteoarthritis and postoperative pain in dogs. *The AAPS Journal* 15(2):598-607.
- Villar JM, Cuervo B, Rubio M (2016). Effect of intraarticular inoculation of mesenchymal stem cells in dogs with hip osteoarthritis by means of objective force platform gait analysis: concordance with numeric subjective scoring scales. *BMC veterinary Research* 12(1):223.