

*Full Length Research Paper*

## **Evaluation of biochemical indices of male rat reproductive function and testicular histology in wistar rats following chronic administration of aqueous extract of *Fadogia agrestis* (Schweinf. Ex Heirn) stem**

**Yakubu, M. T.\*, Oladiji, A. T. and Akanji, M. A.**

Medicinal Plants Research Laboratory, Department of Biochemistry, University of Ilorin, P. M. B. 1515, Ilorin, Nigeria.

Accepted 3 December, 2007

The effects of administration of aqueous extracts of *Fadogia agrestis* stem for 28 days and the 10 days post treatment effects on biochemical indices of reproductive function and testicular histology were evaluated in male albino rats. The rats were randomly selected into four study groups, A, B, C and D of 10 rats per group. Animals in group A (control) received 1 ml of distilled water (vehicle), and test groups B, C and D received graded doses of 18, 50, and 100 mg/kg body weight of extract respectively on daily basis for 28 days. At the end of 28 days treatment period, 5 animals were sacrificed while the remaining 5 from the same group were sacrificed after a ten day recovery period. There were significant ( $P < 0.05$ ) increases in the prostrate – body weight ratio (%), citric acid concentration and acid phosphatase activity at all the dose regimen and only at 50 and 100 mg/kg body weight dose regimen for calcium and phosphate, while pH was not altered. There was no recovery on prostatic parameters except the citric acid content at 18 mg/kg body weight. Sperm count, motility, morphology and density were significantly reduced at 50 and 100 mg/kg dose regimen. The pH, colour, turbidity and viscosity of semen were unaffected but the seminal vesicular-body weight ratio (%), fructose content and glutamate dehydrogenase activity were significantly ( $P < 0.05$ ) reduced at higher doses. Histopathological changes revealed destruction of spermatid cells and seminiferous tubules. Toxicity was mild and reversible at 18 mg/kg body weight dose regimen but there was irreversible derangement on male testicular histology at 50 and 100 mg/kg body weight dose regimen, which may adversely affect reproductive function especially male fertility.

**Key words:** *Fadogia agrestis* stem, prostate, seminal vesicle, sperm, oral administration, recovery, reproductive function indices, testicular histology.

### **INTRODUCTION**

The use of medicinal plants in the management of various illnesses is due to their phytochemical constituents and dates back to antiquity (Yakubu et al., 2007a). Phytochemicals isolated from medicinal plants can be used as agents or starting materials in the synthesis of drugs. The use of herbs is very common in developing countries, particularly in rural settings. However, during the last decade, an increase in the use of plants has been observed in metropolitan areas of

developed countries (Harnack et al., 2001). Plants are extensively used to manage sexual dysfunction. One of such plants widely used as an aphrodisiac in many localities in Nigeria is *Fadogia agrestis*.

*F. agrestis* Schweinf (Rubiaceae) otherwise known as Black aphrodisiac (English), Baakin gagai (Hausa) is an erect shrub of 1 - 3 feet high. The leaves and stem are yellowish and tomentellous. The aqueous extract of the stem have been shown to consist of saponins, alkaloids, anthraquinones and flavonoids (Yakubu et al., 2005). The stems of the plants largely used in folklore medicine as aphrodisiac (Irvine, 1961) has recently been demonstrated to have aphrodisiac potentials and thus can be used as sexual invigorators (Yakubu et al., 2005). How-

\*Corresponding author. E-mail: [tomuyak@yahoo.com](mailto:tomuyak@yahoo.com), [tomuyak@gmail.com](mailto:tomuyak@gmail.com). GSM No: +234 (0) 8033578658.

ever, despite the age long use of *Fadogia agrestis* stem, its effect on the reproductive functions of male rats most especially on the accessory glands of male reproductive systems like the prostate, seminal vesicle, physico-chemical characteristics of rat sperm and testicular histology is not known.

As part of the male reproductive system, the prostate gland's primary function is to secrete a slightly alkaline fluid, a fluid that carries sperm with sufficient power out of a man's body on its way to fertilizing a woman's egg. The seminal vesicle on the other hand contributes to the formation of seminal plasma and provides an ionically balanced nutritive milieu for the survival of sperm in the female reproductive tract (Prasad and Rajalakshmi, 1989). Seminal vesicular secretion is important for semen coagulation, sperm motility and chromatin stability.

The present investigation was designed to evaluate the effect of repeated administration of the aqueous extract of *F. agrestis* stem on the male rat testicular histology, physicochemical characteristics of rat sperm and some function indices of male rat prostate and seminal vesicle at the same doses used for the demonstration of its aphrodisiac potentials. Several authors (Gonzales et al., 2003; Jana et al., 2003; Sharma et al., 2003; Gupta et al., 2004) have used parameters like sperm cell characteristics and histological examination of the testes to assess the reproductive function in male rats, hence, their use in this study.

## MATERIALS AND METHODS

### Plant material and authentication

The sample of the whole plant bought from the herb sellers at Kulende Market, Ilorin, Nigeria was authenticated at the Department of Horticulture and Landscape Technology, Federal School of Forestry, Jos, Nigeria. A voucher specimen was deposited at their herbarium under a voucher number 2:108.

### Animals

Healthy, sexually experienced male white albino rats (*Rattus norvegicus*) weighing between 220 – 250 g were obtained from the Small Animal Holding Unit of the Department of Biochemistry, University of Ilorin, Ilorin, Nigeria. They were kept in well-ventilated house conditions (Temperature: 28 - 31°C; photoperiod: 12 h natural light and 12 h dark; humidity: 50 - 55%) with free access to rat pellets (Bendel Feeds and Flour Mills Limited, Ewu, Nigeria) and tap water.

### Assay kits

The assay kits for calcium, phosphate, glutamate dehydrogenase (GDH) and acid phosphatase (ACP) were obtained from Randox Laboratories, Co-Atrim, United Kingdom.

### Preparation of aqueous extract of *Fadogia agrestis* stem

The plant stem was cut into pieces, oven-dried at 40°C for 48 h to a

constant weight. The dried pieces were then pulverized using an electric blender (Blender/Miller III, model MS-223, China). The powdered material stocked in a plastic container was extracted in distilled water for 48 h at room temperature. This was then filtered using filter paper (Whatman No. 1). The filtrate was concentrated on steam bath to give about 0.57g ± 0.049 of the residue (brownish dark slurry). Appropriately calculated amount of the residues were reconstituted in distilled water to give the equivalent dose of 18 mg/kg body weight (value originated from ethnobotanical survey), higher doses of 50 mg/kg body weight and 100 mg/kg body weight (all doses were as used in our study of the aphrodisiac potentials of the plant) (Yakubu et al., 2005). The reconstituted aqueous extract was administered orally using metal oropharyngeal cannula to all animals in different groups.

### Animal grouping and extract administration

Male rats were randomly divided into four groups (A, B, C and D) of 10 animals each. Rats in groups B, C and D were administered with the plant extract once daily at 24 h interval at the doses of 18, 50 and 100 mg/kg body weight respectively for 28 days. Group, A which served as the control, received 1.0 ml of the vehicle (distilled water) in a similar manner for the same number of days. 24 h after their 28 daily doses, 5 rats from each group were sacrificed while the remaining 5 rats were not administered any of their doses again, but were only maintained on their rat pellet and water *ad libitum* for the 10 days recovery period designated as day 38. The rats were thereafter sacrificed 24 h after their 10 days post treatment.

All administrations were done daily at the same point time of between 0800 -0845 h. The experimental rats were allowed free access to rat pellets and tap water after the daily dose of the extract/distilled water. The study was approved by the Departmental Ethical Committee on the Care and Use of Experimental Animals.

### Collection of prostatic and seminal vesicle fluid

Under light ether anesthesia, the rats were quickly dissected and the prostate glands and seminal vesicle were excised from the animals. The prostate gland and seminal vesicle were drained of their contents (into separate sample bottles) and then stored frozen at 0°C for 24 h before being used for the various biochemical assay. The prostate gland and seminal vesicle were later blotted with tissue paper and thereafter weighed.

### Determination of prostatic and seminal vesicle function indices

The prostate body weight ratio was determined according to the method described by Yakubu et al. (2007b). The method described by Anderson et al. (1979) was used to estimate the seminal fluid fructose concentration. The concentrations of calcium, citrate, phosphate and pH of the prostatic fluid were determined by the methods described by Biggs and Moorehead (1974), Petrarulo et al. (1995), Fiske and Subbarow (1925) and Comhaire and Vermeulen (1995) respectively. The assay methods described by Wright et al. (1972) and Schmidt et al. (1965) were used to determine the activities of ACP and GDH respectively.

### Collection of sperm cells and determination of seminal parameters

The method of Amelar et al. (1973) was used in collecting sperm cells. Briefly, epididymis samples were removed from the freezer

**Table 1.** Effect of administration of aqueous extract of *Fadogia agrestis* stem on some secretory constituents of male rat prostate gland

Parameters/Doses	28 Days				Day 38			
	Control	18mg/kg body weight	50mg/kg body weight	100mg/kg body weight	Control	18mg/kg body weight	50mg/kg body weight	100mg/kg body weight
% Prostate gland body weight ratio	0.15±0.01 <sup>a</sup>	0.15±0.01 <sup>a</sup>	0.17±0.01 <sup>b</sup>	0.18±0.01 <sup>b</sup>	0.14±0.02 <sup>a</sup>	0.14±0.03 <sup>a</sup>	0.16±0.01 <sup>b</sup>	0.17±0.01 <sup>b</sup>
Ca <sup>2+</sup> (mmol/L)	19.00±1.03 <sup>a</sup>	21.50±1.05 <sup>a</sup>	23.10±0.87 <sup>b</sup>	25.40±1.21 <sup>c</sup>	19.05±0.05 <sup>a</sup>	19.40±0.25 <sup>a</sup>	22.39±0.13 <sup>b</sup>	25.10±1.08 <sup>c</sup>
Citrate (mg/100ml)	4.27±0.12 <sup>a</sup>	2.69±0.31 <sup>b</sup>	5.77±0.26 <sup>c</sup>	6.16±0.80 <sup>c</sup>	4.26±0.12 <sup>a</sup>	4.19±0.17 <sup>a</sup>	5.67±0.26 <sup>c</sup>	6.47±0.80 <sup>c</sup>
Phosphate (mmol/L)	14.00±0.58 <sup>a</sup>	14.52±0.97 <sup>a</sup>	17.21±1.01 <sup>b</sup>	18.22±0.47 <sup>c</sup>	13.80±0.99 <sup>a</sup>	13.82±0.20 <sup>a</sup>	16.04±1.10 <sup>b</sup>	18.01±0.67 <sup>c</sup>
ACP (U/l)	178.30±5.90 <sup>a</sup>	236.40±2.60 <sup>b</sup>	254.70±2.12 <sup>c</sup>	267.60±3.52 <sup>d</sup>	178.30±0.92 <sup>a</sup>	197.60±2.05 <sup>e</sup>	212.00±1.30 <sup>f</sup>	233.22±4.00 <sup>b</sup>
pH	6.60±0.01 <sup>a</sup>	6.55±0.01 <sup>a</sup>	6.50±0.01 <sup>a</sup>	6.40±0.01 <sup>a</sup>	6.50±0.01 <sup>a</sup>	6.55±0.01 <sup>a</sup>	6.55±0.01 <sup>a</sup>	6.50±0.01 <sup>a</sup>

n = 5 ± SD; Values carrying superscripts different from the control for each parameter are significantly different (P<0.05).

**Table 2.** Effect of administration of aqueous extract of *Fadogia agrestis* stem on some secretory constituents of rat seminal vesicle fluid

Parameters/Doses	28 Days				Day 38			
	Control	18mg/kg body weight	50mg/kg body weight	100mg/kg body weight	Control	18mg/kg body weight	50mg/kg body weight	100mg/kg body weight
% Seminal vesicle weight ratio	0.20±0.00 <sup>a</sup>	0.20±0.01 <sup>a</sup>	0.20±0.01 <sup>a</sup>	0.19±0.01 <sup>a</sup>	0.19±0.02 <sup>a</sup>	0.19±0.02 <sup>a</sup>	0.19±0.02 <sup>a</sup>	0.19±0.01 <sup>a</sup>
Fructose (mg/100ml)	65.00±3.40 <sup>a</sup>	66.00±2.14 <sup>a</sup>	51.70±2.25 <sup>b</sup>	43.20±1.79 <sup>c</sup>	66.21±1.03 <sup>a</sup>	65.25±2.07 <sup>a</sup>	49.83±0.28 <sup>b</sup>	44.08±0.24 <sup>c</sup>
Glutamate dehydrogenase activity (nM/min/mg protein)	139.45±3.21 <sup>a</sup>	135.29±2.03 <sup>b</sup>	117.20±4.78 <sup>c</sup>	103.25±5.21 <sup>d</sup>	137.41±2.22 <sup>a</sup>	139.60±3.84 <sup>a</sup>	119.44±3.01 <sup>b</sup>	108.12±3.04 <sup>c</sup>

n = 5 ± SD; Values carrying superscripts different from the control for each parameter are significantly different (P<0.05).

and then allowed to thaw slowly in a refrigerator. Samples were then carefully cut opened using clean sterile blade and placed in 1.0 ml of 0.1 M phosphate buffer of pH 7.4. It was then vigorously shaken for homogeneity and dispersal of sperm cells. The method of Biswas et al (2002) was used for the determination of sperm motility and sperm count while the method described by Magbagbeola et al. (2000) was used to estimate the sperm density. The sperm morphology was determined using the method described by Amelar and Dublin (1978) while the sperm viscosity was evaluated using the method described by Barrat and John (1998). To test for semen pH, pH paper was dipped into the sample, and the resulting colour was checked against known standards (Comhaire and Vermeulen, 1995).

### Histopathological examination

The procedure described by Krause (2001) was used. Briefly, fixed testes in 10%v/v buffered formaldehyde were dehydrated through ascending grades of ethanol (70, 90 and 95% v/v). They were cleaned in xylene, impregnated and embedded in paraffin wax (melting point 56°C); sections were cut at 5 µm on a rotatory microtome. The sections were floated out on clean microscope slides, which had previously been albuminized to prevent detachment from slides during staining procedure. They were air-dried for 2 h at 37°C (Drury and Wallington, 1973). After staining, the slides were passed through ascending concentration of alcohol (20 – 100%) for dehydration and then cleaned with xylene. A permanent mounting medium (basalm) was put on the tissue section. A thin glass-covered slip was placed on the covering-mounting medium and underlying tissue sections were allowed to dry. This was later observed using the Leitz, DIALUX research microscope at x200 and photomicrographs were taken in bright field at x200.

### Statistical Analysis

The determinations were replicated 5 times. Results were expressed as the mean ± SD. Means were analyzed using a one-way analysis of variance, followed by the Duncan Multiple Range Test to determine significant differences in all the parameters. Differences with values of  $P < 0.05$  were considered statistically significant (Mahajan, 1997).

## RESULTS

Extract administration at the higher dose levels (50 and 100 mg/kg body weight) resulted in significant increase ( $P < 0.05$ ) in the prostate gland body weight ratio (%) which were not reversed during the 10 days post treatment period (Table 1). There were significant increases ( $P < 0.05$ ) in the prostatic calcium, citrate, phosphate ions and acid phosphatase activity with those of calcium and phosphate manifesting only at higher doses of 50 and 100 mg/kg body weight (Table 1). The pH of the prostatic fluid was not significantly affected ( $P > 0.05$ ) following the administration of the plant extract at various doses. By the end of the recovery period, it was only the prostatic citric acid content at 18 mg/kg body that recovered towards the value of the control ( $P > 0.05$ ). Results of other prostatic parameters remained significantly altered during the post treatment period ( $P <$

0.05) (Table 1).

Administration of the plant extract did not produce any significant change ( $P > 0.05$ ) in the seminal vesicle body weight ratio (%) (Table 2). The 18 mg/kg body weight of the extract did not significantly alter ( $P > 0.05$ ) the fructose concentration of the seminal vesicle gland whereas higher doses (50 and 100 mg/kg body weight) produced significant reduction ( $P < 0.05$ ) (Table 2). No recovery was made during the post treatment period as values of the fructose concentration of the seminal vesicle fluid remained significantly altered ( $P < 0.05$ ) (Table 2). However, there was decrease in GDH activities of the seminal fluid suggestive of dose dependence with recovery made only by the 18 mg/kg body weight dosed groups ( $P > 0.05$ ) (Table 2).

Administration of the extract at 18 mg/kg body weight for 28 days did not significantly alter ( $P > 0.05$ ) male rat sperm counts, motility, morphology and density whereas there was significant reduction ( $P < 0.05$ ) in the sperm parameters at higher doses of 50 and 100 mg/kg body weight (Table 3). In addition, administration at all the doses did not alter the pH, colour, turbidity and viscosity of the semen (Table 3). It was only the 18mg/kg body weight dose group that had their sperm parameters returned towards the control values ( $P > 0.05$ ) while those of higher doses remained significantly altered ( $P < 0.05$ ) during the 10days post-treatment period (Table 3).

Histopathological examination of sections of treated rats' testes showed dose dependent lesions on seminiferous tubules ranging from mild distortion (Figure 2), destruction of sperm cell with no coordination in boundary of tubules (Figure 3) to complete destruction of spermatogenic cells characterized by loss of embryonic cell and germ cell detachment (Figure 4). These were however, absent in the control (Figure 1) which had intact seminiferous tubules.

## DISCUSSION

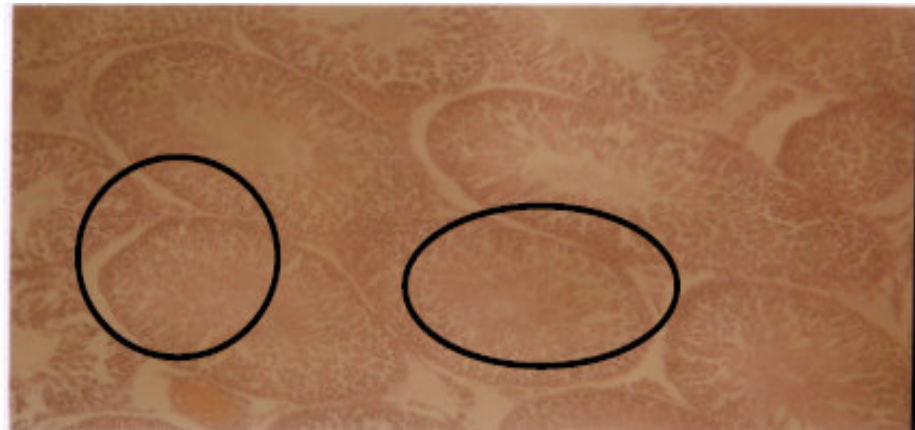
The age long usage of aqueous extract of *F. agrestis* stem as an aphrodisiac by the local population in Nigeria without adequate information on its toxicity most especially on male reproductive function necessitated this study. The biochemical parameters evaluated in this study are useful indices of male reproductive function (Gonzales et al., 2003; Jana et al., 2003; Sharma et al., 2003, Gupta et al., 2004). Biochemical indices of reproductive function when adversely altered will impede reproductive capability of animals.

According to Moore and Dalley (1999), an increase in organ body weight ratio is an indication of inflammation while a decrease is an indication of cell constriction. The significant increase in prostate-body weight ratio by the administration of the plant extract may be attributed to increased secretory activity of the prostate which in this study is supported by the increase in calcium, citrate and phosphate ions as well as acid phosphatase activity. Si-

**Table 3.** Effect of administration of aqueous extract of *Fadogia agrestis* stem on some characteristics of male rat sperm.

Parameters/Doses	28 Days				Day 38			
	Control	18mg/kg body weight	50mg/kg body weight	100mg/kg body weight	Control	18mg/kg body weight	50mg/kg body weight	100mg/kg body weight
Sperm counts (number/ml)	80.70 x 10 <sup>8</sup> ± 8.21 x 10 <sup>8a</sup>	79.66 x 10 <sup>8</sup> ± 8.44 x 10 <sup>8a</sup>	67.64 x 10 <sup>8</sup> ± 8.72 x 10 <sup>8b</sup>	63.90 x 10 <sup>8</sup> ± 8.89 x 10 <sup>8b</sup>	80.70 x 10 <sup>8</sup> ± 8.11 x 10 <sup>8a</sup>	79.66 x 10 <sup>8</sup> ± 8.44 x 10 <sup>8a</sup>	68.24 x 10 <sup>8</sup> ± 8.72 x 10 <sup>8b</sup>	64.90 x 10 <sup>8</sup> ± 8.26 x 10 <sup>8b</sup>
Sperm motility (%)	81.40±2.21 <sup>a</sup>	82.16±2.44 <sup>a</sup>	62.96±3.54 <sup>b</sup>	54.22±4.21 <sup>c</sup>	81.40±2.21 <sup>a</sup>	82.16±1.44 <sup>a</sup>	64.26±3.54 <sup>b</sup>	56.00±2.43 <sup>b</sup>
Sperm morphology (%)	73.40±4.17 <sup>a</sup>	72.76±5.14 <sup>a</sup>	61.60±3.84 <sup>b</sup>	54.59±4.01	73.40±4.17 <sup>a</sup>	72.94±3.45 <sup>a</sup>	63.20±2.43 <sup>b</sup>	56.60±4.61 <sup>c</sup>
Sperm density (10 <sup>6</sup> /ml)	65.16±2.47 <sup>a</sup>	65.66±1.21 <sup>a</sup>	50.00±0.53 <sup>b</sup>	44.19±0.25 <sup>c</sup>	65.17±2.47 <sup>a</sup>	65.30±2.14 <sup>a</sup>	53.00±1.53 <sup>b</sup>	44.80±1.30 <sup>b</sup>
pH of semen	7.41±0.07 <sup>a</sup>	7.42±0.03 <sup>a</sup>	7.40±0.06 <sup>a</sup>	7.44±0.02 <sup>a</sup>	7.40±0.06 <sup>a</sup>	7.40±0.06 <sup>a</sup>	7.40±0.06 <sup>a</sup>	7.44±0.03 <sup>a</sup>
Colour	Whitish-grey	Whitish-grey	Whitish-grey	Whitish-grey	Whitish-grey	Whitish-grey	Whitish-grey	Whitish-grey
Turbidity	Normal	Normal	Normal	Normal	Normal	Normal	Normal	Normal
Viscosity	Normal	Normal	Normal	Normal	Normal	Normal	Normal	Normal

n = 5 ± SD; Values carrying superscripts different from the control for each parameter are significantly different (P<0.05).

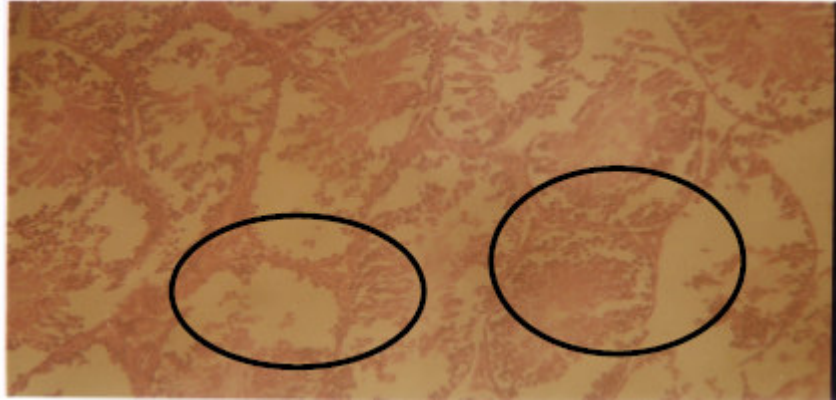


**Figure 1.** Photomicrograph of testis of rat administered with distilled water (Control). The circled spots indicate well-layered seminiferous tubules (x200).

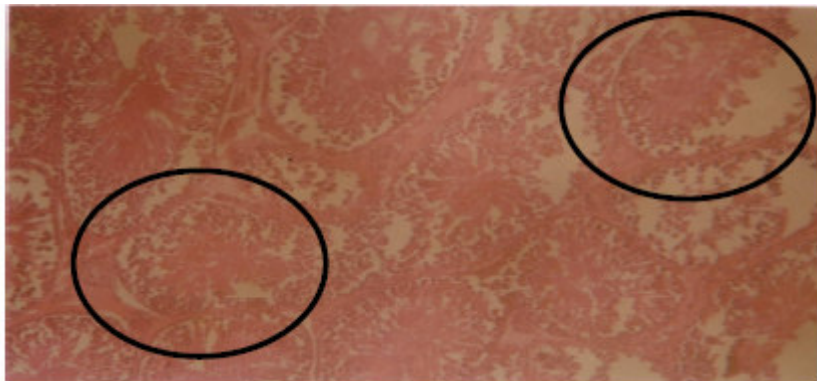
milar increase in testes - body weight ratio was also observed by Kamatchoung et al. (2002) following administration of *Zingiber officinale* and *Pentadiplandra brazzeana* in male rats.

Oral administration of aqueous extract of *F. agrestis* stem manifested its impact on male rat reproductive function by altering the concentration of some secretory constituents of the prostate and

seminal vesicle. The significant increase in the prostatic acid phosphatase activity obtained in this study may lead to indiscriminate hydrolysis of phosphate ester thereby denying the cells of ade-



**Figure 2.** Photomicrograph of testis of rat administered with 18 mg/kg body weight of aqueous extract of *Fadogia agrestis* stem. The circled spots indicate mild distortion of the seminiferous tubules (x200).



**Figure 3.** Photomicrograph of testis of rat administered with 50 mg/kg body weight of aqueous extract of *Fadogia agrestis* stem. The circled spots indicate severe disintegration of the seminiferous tubules with no coordination between the boundaries (x200).



**Figure 4.** Photomicrograph of testis of rat administered with 100 mg/kg body weight of aqueous extract of *Fadogia agrestis* stem. The circled spots indicate severe disintegration of the seminiferous tubules with loss of germ cell attachment from the seminiferous epithelium (x200).

adequate use of phosphate esters. The significant increase in the concentration of prostatic citrate and calcium may be an indication that the plant extract has caused increase in functional activity of the prostate which may adversely affect the reproductive function of the organ. The non-significant effect on the prostatic pH is an indication that the extract did not interfere with the buffering system in the prostate gland. The recovery made by the animals on prostatic citrate at 18 mg/kg body weight may suggest that the extract at this dose is 'safe'.

The seminal vesicle, whose primary secretory product is fructose, provides nutrients for the semen. Seminal vesicular secretion is important for sperm motility and stability of sperm chromatin. The lack of significant change in the fructose content of the seminal vesicle content, a better 'marker' for the functioning of seminal vesicle (Gonzales and Villena, 2001), at the least dose of 18 mg/kg body weight may be indication that the dose level could be tolerated by the animals. However, the reduction in the fructose content of the seminal fluid may be an indication that the secretory ability of the seminal vesicle was hindered by the extract (Farook et al., 1989), and this will adversely affect its nutritive potentials for the semen which will in turn affect sperm motility. The significant decrease in seminal fluid GDH activities may imply reduction in the amount of energy being made available to the sperm cell. Thus, the decreased nutrient and energy availability to the sperm cells at the higher doses of 50 and 100 mg/kg body weight may be responsible for the reduction in sperm motility as observed in this present study and will have adverse effect on male fertility. Such pattern of alterations agrees with that of Sharma et al. (2003) following the administration of *Semecarpus ana-cardium* fruits on reproductive function of male rats. The recovery at 18 mg/kg body weight made on seminal fluid GDH activities suggests transient toxicity of the extract at this dose level.

The lack of significant change in sperm count, motility, density and morphology at 18 mg/kg body weight implies that the extract did not adversely affect the sperm parameters at this dose. However, the significant reduction in sperm count, motility, density and morphology following extract administration at higher doses of 50 and 100 mg/kg body weight for 28 days may be an indication of adverse effect on the physical characteristics of the sperm. Such may imply that the extract possesses the potential of reducing fertility in males at higher doses (50 and 100 mg/kg body weight) when administered for a long period like 28 days. It could mean that the extract at these doses might have crossed the blood-testis barrier and have interfered with the functioning of testicular epithelium (germinal epithelium) since it is the germinal epithelium of the testes that produce the sperm cells (Dua and Vaidya, 1996), which is supported in this study by the distortions observed in the normal architecture of rat testes. The alterations in the physical characteristic of

sperm cells may also be attributed to various effect brought about by the plant extract on the other reproductive parameters earlier discussed in this study. The non-significant effect of the extract on viscosity of the semen may be an indication that the extract did not cause abnormal liquefaction (Comhaire and Vermeulen, 1995). Similarly, the lack of significant effect on semen pH was an indication that there was no infection, which would have resulted from decreased secretion of acidic products by the prostate such as citric acid, incomplete ejaculation or agenesis (or occlusion) of the seminal vesicles. The return to control values of semen parameters at 18 mg/kg body weight are indications of low and temporary toxicity of the extract.

The mild distortion in the testicular seminiferous tubules following the administration of the plant extract at the dose of 18 mg/kg body weight, (the traditionally acclaimed dose) when compared with the control further point to the low toxicity risk of the extract as earlier revealed by the studies on other biochemical parameters. However, the severe tubular distortion of the testes observed following the repeated administration of the extract at higher doses of 50 and 100 mg/kg body weight for a period of 28 days may suggest a possible influence on the male rat fertility. Gametogenesis occurs in the seminiferous tubules while the interstitial cells secrete the testicular hormone, mainly testosterone (Prasad and Rajalakshmi, 1989). Therefore, any alteration in the seminiferous tubules as observed in the histopathological studies will have its consequential effect on gametogenesis. Thus, administration of the plant extract at the dose of 18 mg/kg body weight revealed mild effect on the male rat fertility while the higher doses might indicate severe effect on male rat fertility.

The compromise in the supply of nutrients and energy, alteration in physical characteristics of sperm coupled with histopathological lesion on the seminiferous tubules at higher doses implies that the extract may impair reproductive function. Since, there was mild, reversible toxicity, at 18 mg/kg body weight dose of the extract, the dose employed locally, it may be that the plant extract at this dose is relatively 'safe', but at higher doses (50 and 100 mg/kg body weight), permanent and irreversible lesions affecting cellular metabolism and male reproductive function may occur, thus predisposing to infertility.

## REFERENCES

- Amelar RD, Dublin L (1978). Infertility in male. In: Kendall, A.R., Kaweafin L, Stein BS, Goldsmith HS (eds). Harper and Row Publishers, Philadelphia, USA. pp. 41-42.
- Amelar RD, Dublin L, Schoenfeld C (1973). Serum analysis: An office Technique. Urol. 2: 606-611.
- Anderson RA Jr, Reddy JM, Oswald C, Zaneveld LJD (1979). Enzymic determination of fructose in seminal plasma by initial rate analysis. Clin. Chem. 25(10): 1780-1782.
- Barrat CLR, John JC St (1998). Diagnostic tools in male infertility. Hum. Reprod. 13: Suppl 1: 51-61.
- Biggs HG, Moorehead WR. (1974). O-Cresolphthalein direct colorimetric method. Clin. Chem. 20: 1458-1460.

- Biswas D, Bari FY, Shamsuddin M, Rahman MM, Rahman MM (2002). Determination of glycerol percentages for preserving the black bengal buck (*Capra hircus*) spermatozoa for long time. Pak. J. Biol. Sci. 5(6): 715-718.
- Comhaire F, Vermeulen L (1995). Human semen analysis. Hum. Reprod. Update. 1 (4): 343-362.
- Drury RAB, Wallington EA (1973). In: Carleton's Histological Technique. 4<sup>th</sup> edn. Oxford University Press, NY. p. 58.
- Dua AA, Vaidya SR (1996). Sperm motility and morphology as changing parameters linked to sperm count variations. J. Postgrad. Med. 42: 93-6
- Farook T, Vanithakumari G, Bhuvanewari G, Malini T (1989). Effect of Anethole on accessory sex tissue of albino rats. JRAS XV: 167-70.
- Fiske CH, Subbarow Y (1925). The colorimetric determination of phosphorus. J. Biol. Chem. 66: 375-400.
- Gonzales GF, Rubio J, Chung A, Gasco M, Villegas L(2003). Effect of alcoholic extract of *Lepidium meyenii* (Maca) on testicular function in male rats. Asian J. Androl. 5: 349-352.
- Gonzales G, Villena A (2001). True corrected seminal fructose level: a better marker of the function of seminal vesicles in infertile men. Int. J. Androl. 24(5): 255-260(6).
- Gupta RS, Kachhawa JB, Chaudhary R (2004). Antifertility effects of methanolic pod extract of *Albizia lebbbeck*. Asian J. Androl. 6: 155-159.
- Harnack LJ, Rydell SA, Stang J (2001). Prevalence of use of herbal products by adults in the Minneapolis/St Paul, Minn, metropolitan area. Mayo Clinic Proceedings, 76: 688-694.
- Irvine FR (1961). Woody plants of Ghana. Oxford University Press, London. p. 878.
- Jana D, Maiti R, Ghosh D (2003). Effect of *Stephania hernandifolia* leaf extract on testicular activity in rats. Asian J. Androl. 5: 125-129.
- Kamatchoung P, Fandio YM, Dimo T Jatsa HB. (2002). Evaluation of androgenic activity of *Zingiber officinale* and *Pentadiplandra brazzeana* in male rats. Asian J. Androl. 4: 299-301.
- Krause WJ (2001). The art of examining and interpreting histologic preparations. A student handbook. Partheton Publishing Group, UK. pp. 9-10.
- Magbagbeola OA, Lawal OJ, Edunfunke IO (2000). Studies on the effects of cottonseed oil on male Sprague Dawley rats: 1. Effect on sperm count, sperm morphology, testicular alkaline phosphatase and blood chemistry. Nig. J. Biochem. Mol. Biol. 15(2): 131-138.
- Mahajan BK (1997). Significance of difference in means. In: Methods in Biostatistics for Medical and Research Workers, 6th edn. New Delhi: JAYPEE Brothers Medical Publishers. pp. 130-155.
- Moore KL, Dalley AF (1999). Clinical Oriented Anatomy (4<sup>th</sup> Edition). Lippincot Williams and Williams; a Woller Klumner Corporation , Philadelphia. pp. 263-271.
- Prasad, MRN, Rajalakshmi M (1989). Spermatogenesis and Accessory Gland Secretions. In: Textbook of Biochemistry and Human Biology. 2<sup>nd</sup> Edition. (Talwar, G. P., Srivastava, L. M. and Moudgil, L. M. Eds). Prentice-Hall of India Private Limited, New Delhi. pp. 883.
- Petrarulo M, Facchini P, Cerelli E, Marangella M, Linari F (1995). Citrate in urine determined with a new citrate lyase method. Clin. Chem. 41(10): 1518-1521.
- Schmidt C, Schmidt FW, Hoin D, Gelach U (1965). In: Methods of enzymatic analysis. Bermeyer HU (ed). Academic Press, NY. pp. 651-712.
- Sharma A, Verma PK, Dixit VP (2003). Effect of *Semecarpus anacardium* fruits on reproductive function of male albino rats. Asian J. Androl. 5: 121-124.
- Wright PJ, Leathwood PD, Plummer DT (1972). Enzymes in rat urine. Acid phosphatase. Enzymologia 42: 459-462.
- Yakubu MT, Akanji MA, Oladiji AT (2005). Aphrodisiac potentials of aqueous extract of *Fadogia agrestis* (Schweinf. Ex Heirn) stem in male albino rats. Asian J Androl 7(4): 399-404.
- Yakubu MT, Akanji MA, Oladiji AT (2007a). Male sexual dysfunction and methods used in assessing medicinal plants with aphrodisiac potentials. Pharmacognosy Rev. 1(1): 49-56.
- Yakubu MT, Akanji MA, Oladiji AT (2007b). Evaluation of antiandrogenic potentials of aqueous extract of *Chromolaena odoratum* (L.) K. R. leaves in male rats. Andrologia 39(6): 235-243.