

Full Length Research Paper

Identification of scuticociliate *Philasterides dicentrarchi* from indo-pacific seahorses *Hippocampus kuda*

Sang Phil Shin¹, Jee Eun Han¹, Dennis K. Gomez², Ji Hyung Kim¹, Casiano H. Choresca Jr.¹, Jin Woo Jun¹ and Se Chang Park^{1*}

¹Laboratory of Aquatic Animal Medicine and Research Institute for Veterinary Science, College of Veterinary Medicine, Seoul National University, Seoul 151 to 742, Republic of Korea.

²Institute of Aquaculture, College of Fisheries and Ocean Sciences, University of the Philippines in the Visayas, Miagao, Iloilo 5023, Republic of the Philippines.

Accepted 17 February, 2011

The “indo-pacific seahorses”, *Hippocampus kuda* which had been reared in one of the private commercial aquaria for exhibition were sent to the laboratory for diagnosis. Feces and intestinal contents from 5 seahorses were examined microscopically and revealed numerous scuticociliates. We identified the species of scuticociliate by light (wet mount) and scanning electron microscopy, PCR (polymerase chain reaction) and sequencing. This paper reports the first identification of scuticociliate *Philasterides dicentrarchi* from seahorse in Korea.

Key words: Indo-pacific seahorse, *Philasterides dicentrarchi*, scanning electron microscopy, polymerase chain reaction, sequencing.

INTRODUCTION

Scuticociliatosis is a disease caused by histophagus ciliates or free-living scuticociliates, facultative parasites of the order Scuticociliatida belonging to the genera *Uronema*, *Miamiensis*, *Tetrahymena*, and *Philasterides* (Thompson and Moewus, 1964; Cheung et al., 1980; Ferguson et al., 1987; Dragesco et al., 1995). These opportunistic histophagus parasites are characterized by their high potential for systemically invading the host and occasionally pathogenic causing high mortalities (Lom and Dyková, 1992; Kim et al., 2004a). Mortalities occurred in cultured marine fish (Dyková and Figueras, 1994; Dragesco et al., 1995; Munday et al., 1997; Iglesias et al., 2001) like olive flounder *Paralichthys olivaceus* (Jee et al., 2001; Kwon et al., 2003; Kim et al., 2004a, b) and in seahorse *Hippocampus erectus* (Thompson and Moewus, 1964). Scuticociliates primarily infect the gills, skin, and sometimes systemically affect the internal organs and brain of fish resulting to high mortality. It is also associated with various pathological changes, including bleeding

cutaneous ulcers, dystrophic and necrotic effects in muscles, hypochromic anemia and encephalitis associated with softening or liquefaction of brain tissues (Iglesias et al., 2001).

Scuticociliatosis has been recognized as an emerging problem that causes significant economic loss in aquaculture, through systemic infection (Jin et al., 2009). The causative agents of scuticociliatosis in Korea have been isolated and identified as *Uronema marinum* (Jee et al., 2001), *Pseudocohnilembus persalinus* (Kim et al., 2004b), *Philasterides dicentrarchi* (Kim et al., 2004a). *P. dicentrarchi* and *Miamiensis avidus* have caused mass mortality in turbot farms in Spain, Portugal, and France (Dyková and Figueras, 1994; Iglesias et al., 2001; Álvarez-Pellitero et al., 2004; Paramá et al., 2004). Seahorses are especially popular in some Asian countries due to strong demand from the Chinese traditional medicine and the souvenir trade on a global scale (Marichamy et al., 1993; Vincent, 1995). Recently, the Indo-Pacific seahorse *Hippocampus kuda* (Family Syngnathidae) that is widely distributed throughout the tropical Indo-Pacific Region (Lourie et al., 1999) become popular ornamental fish species and artificially cultured in Jeju Island, South Korea.

*Corresponding author. E-mail: parksec@snu.ac.kr. Tel: +82 2 880 1282. Fax: +82 2 880 1213.

The present study deals with the numerous scuticociliates obtained from the intestinal contents and feces of a moribund 5 seahorses sample based on light (fresh mounts) and scanning electron microscopy (SEM), PCR (polymerase chain reaction), and sequencing. The results revealed that the ciliates identified were *P. dicentrarchi*.

MATERIALS AND METHODS

Samples collection

In April 2008, 12 pieces of seahorse, *H. kuda* (average total length = 13.9 cm, average body weight = 10.9 g) were bought from a commercial hatchery in Jeju Island, South Korea for public exhibition in one of the private commercial aquaria in Seoul. After one month, some of the seahorses with no visible external lesion started to show lethargy, anorexia and died one by one with an interval of four to five days. In May 2008, 5 moribund seahorses were submitted to our laboratory for diagnostic examination. These seahorses showed sloughing of epidermis, depigmentation of skin and abdominal distension. In order to rule out disease causing factors of seahorses, fungal and parasitic infection was checked using wet mount of the skin-scratch, fecal, and internal contents. Moreover viral diseases, such as betanodavirus, birnavirus, iridovirus, and flounderherpesvirus which caused mass mortality in cultured marine fish in Korea, were also tested by using PCR assay. For bacterial isolation, we also investigated the bacterial strain via culturing, and using VITEK II system (BioMerieux, France).

Fungal, bacterial and viral diseases were all negative in tested methods and water parameters, such as dissolved oxygen (D.O.), temperature, pH and ammonia showed normal range value.

Light (wet mount) and scanning electron microscopy (SEM) examinations

Feces and intestinal contents were wet mounted and observed under a microscope. For SEM, these specimens were fixed in modified Karnovsky's fixative, post fixed in 1% osmium tetroxide in 0.05 M sodium cacodylate buffer (pH 7.2), dehydrated through an ethanol serial solutions of 30, 50, 70, 80, 90, 100, 100, 100% for 10 min per each concentration. After treatment of ciliates with hexamethyldisilazane (15 min, two times), specimen drying was performed at room temperature overnight. Ciliates were examined using a JEOL-5410 LV scanning electron microscope (NICEM, Korea).

Molecular analysis of parasites

Feces and intestinal contents total DNA was extracted with DNeasy® Tissue Kit (QIAGEN, USA) following the manufacturer's protocol. Extracted DNA was stored at -20°C until use for PCR and sequencing. Total SS rRNA (small subunit ribosomal RNA) PCR and nested PCR were modified as previously described (Kim et al., 2004a, b). Universal SS rRNA primer for scuticociliates, *U. marinum*, and *P. dicentrarchi* specific primers set were used for detection of seahorses pathogen. SS rRNA PCR was performed in 20 µl reaction mixtures containing DNA template (2 µl), a 10 pmol concentration each primer (Bioneer, Korea) and *i*-StarMaster mix PCR Kit (2.5 U *i*-StarTaq™ DNA Polymerase, 250 µM dNTP, 10 mM Tris-HCl, 2 mM Mg²⁺ solution, stabilizer and tracking dye) (Intronbio, Korea). Nested PCR was performed as described above except using 2 µl PCR Product and specific primer. The amplification was carried out in a T-personal 48 Biometra thermocycler (Biometra,

Germany) with the following parameters:

An initial denaturation step of 95°C 2 min; 35 serial cycles of a denaturation step of 95°C, 30 s, annealing at 50°C, 30 s extension at 72°C, 2 min; and final extension step of 72°C, 10 min.

PCR and nested PCR products were analyzed by 2.0% agarose gel electrophoresis in 1% Tris-borate-EDTA (TBE) buffer. Gels were stained with ethidium bromide (0.5 µg/ml), visualized and photographed under UV illumination. For definitive identification, amplified PCR product of scuticociliate isolated from seahorses was sequenced using BigDye™ terminator cycle sequencing kit (Macrogen Genomic Division, South Korea). Electrophoresis of sequencing reactions was completed using Automatic Sequencer 3730 x 1 DNA analyzer (Applied Biosystems, USA). SS rRNA gene sequence of isolate (SNUSS001) was compared and realigned using the multiple alignment algorithms in the MegAlign package Windows Version 3.12e (DNASTAR, USA) along with the three known scuticociliate species in Korea to give a phylogenetic tree.

The Genbank accession numbers of the known scuticociliates sequence used in this study were *P. dicentrarchi* (AY642280), *P. persalinus* (AY835669), *U. marinum* (AY551905).

RESULTS AND DISCUSSION

The ciliate in wet mount (Figure 1A) and by SEM (Figure 1B) examinations showed ovoid, elongated and egg shape. While the anterior part was tapered, the posterior part was rounded with a contractile vacuole and a long caudal cilium. The ciliate body was covered with numerous cilia. Posterior part was occupied with many food vacuoles. Using universal primer, PCR results revealed between 1500 and 2072 bp and nested PCR product (326 bp) results matched the size of the SS rRNA gene segment of *P. dicentrarchi*. Using *U. marinum* primer, result of the band showed to be negative (Figure 2). The result of the PCR product (1666 bp) sequenced showed 99% nucleotide similarity with *P. dicentrarchi*, 93% with *P. persalinus*, and 91% with *U. marinum*. Phylogenetic tree analysis was constructed based on SS rRNA gene and revealed that this strain is *P. dicentrarchi* (Figure 3). This sequence (1666 bp) was deposited in GenBank under the accession number GU572375. In the morphological examinations, the present results shared similar characteristics with the scuticociliates identified from weedy sea dragon *Phyllopteryx taeniolatus* (Umehara et al., 2003) and olive flounder (Song et al., 2009). Based on these descriptions, the ciliates were suggested as of the genus *Philasterides*. Further confirmation using nucleotide sequencing showed to be closely related to *P. dicentrarchi* and genetically distinguishable from the other two types of scuticociliates used in this study.

In other study, the *P. dicentrarchi* partial nucleotide sequence also showed high identity (99%) with the sequence of *M. avidus* (syn. *P. dicentrarchi*) that was isolated from farmed turbot (Paramá et al., 2006) and *M. avidus* is a senior synonym of *P. dicentrarchi* (Jung et al., 2005). In the present study, seahorses comes from the aquaculture system in Jeju Island, Korea, where scuticociliates infection has already been a problem in

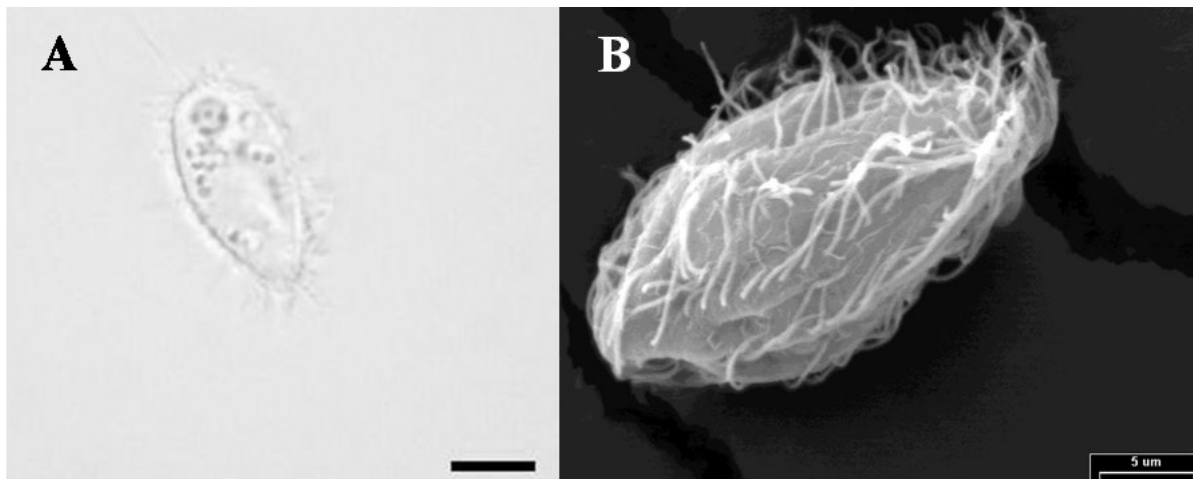


Figure 1. A: Light microscopy (wet mount) of the scuticiliate. Ciliate containing numerous food vacuoles. A contractile vacuole and a long caudal cilium observed at posterior part (1000x). B: Scanning electron micrograph. Ciliate had an ovoid body shape and covered with cilia over the body. Scale bar = 5 μ m.

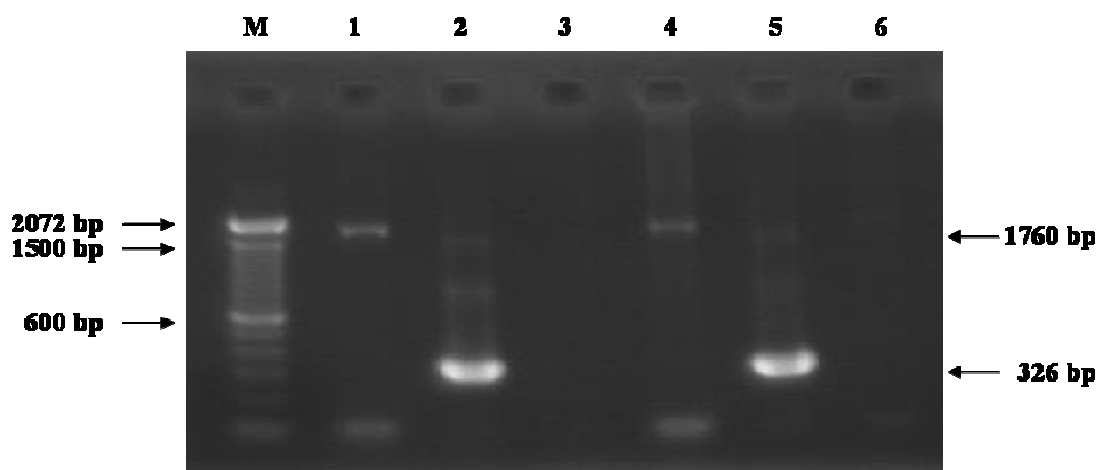


Figure 2. Amplification products obtained using the SS rRNA PCR and nested PCR assays for detection of scuticiliates species in seahorses feces (Lane 1 to 3) and intestinal contents (Lane 4 to 6). Lane M: 100 bp DNA ladder; Lane 1 and 4: PCR positive for scuticiliate using universal primer (1760 bp); Lane 2 and 5: nested PCR positive for *P. dicentrarchi* (326 bp); Lane 3 and 6: nested PCR negative for *U. marinum* (722 bp).

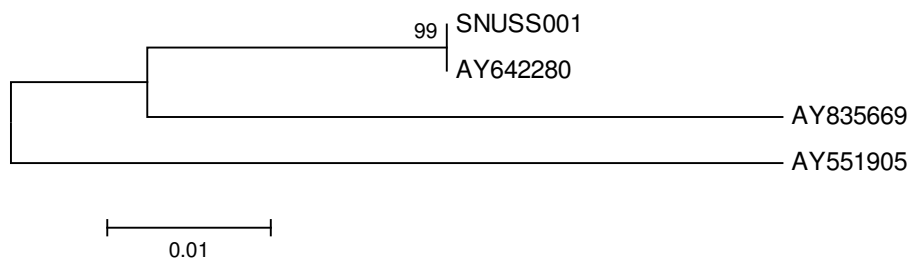


Figure 3. Phylogenetic tree based on the nucleotide sequence of small subunit ribosomal RNA of 3 scuticiliate species reported in Korea and 1 isolate (SNUSS001) from seahorses. Nucleotide sequences of known scuticiliates strains were obtained from GeneBank and their accession numbers are as follows: *P. dicentrarchi* (AY642280), *P. persalinus* (AY835669), and *U. marinum* (AY551905).

many olive flounder cultured system in Jeju Island (Kim et al., 2004a). Some of these seahorse culture systems were located near the olive flounder aquaculture systems where outbreak of *P. dicentrarchi* species has already occurred and showed higher pathogenicity than other scuticociliates isolated from this fish in Korea (Song et al., 2009). The species of *P. dicentrarchi* is an opportunistic histophagus or facultative parasitic ciliate that is also the notorious culprit of high or mass mortality in other cultured marine fish including turbot *Psetta maxima* (Iglesias et al., 2001) and seabass (Dragesco et al., 1995). In addition, *P. dicentrarchi* species can be infected via water to fish (Song et al., 2009). Cross-infection between cultured olive flounder and seahorse might be possible in this present study due to the similarity of species isolated and identified.

Since we have identified this pathogen as *P. dicentrarchi* in the intestines and feces of the seahorses that caused scuticociliatosis through the basis of morphological and molecular examination, therefore, we conclude that this pathogen causes the mortality of seahorses that was used for public exhibition in the aquarium.

ACKNOWLEDGEMENT

This study was financially supported by Basic Science Research Program (2010-0016748) through the National Research Foundation of Korea (NRF) funded by the Ministry of Education, Science and Technology, and by Korea Research Foundation Grant (KRF-2008-331-E00385).

REFERENCES

- Álvarez-Pellitero P, Palenzuela O, Padrós F, Sitjà-Bobadilla A, Riaza A, Silva R, Aran J (2004). Histophagous scuticociliatids (Ciliophora) parasitizing turbot *Scophthalmus maximus*: morphology, *in vitro* culture and virulence. *Folia Parasitol.*, 51: 177-187.
- Cheung PJ, Nigrelli RF, Ruggieri GD (1980). Studies on the morphology of *Uronema marinum* Dujardin (Ciliata: Uronematidae) with a description of the histopathology of the infection in marine fishes. *J. Fish. Dis.*, 3: 295-303.
- Dragesco A, Dragesco J, Coaste F, Gasc C, Romestand B, Raymond J, Bouix G (1995). *Philasterides dicentrarchi*, n. sp. (Ciliophora, Scuticociliatida), a histophagous opportunistic parasite of *Dicentrarchus labrax* (Linnaeus, 1758), a reared marine fish. *Eur. J. Protistol.*, 31: 327-340.
- Dyková I, Figueras A (1994). Histopathological changes in turbot *Scophthalmus maximus* due to a histophagous ciliate. *Dis. Aquat. Org.*, 18: 5-9.
- Ferguson HW, Hicks BD, Lynn DH, Ostland VE, Bailey J (1987). Cranial ulceration in Atlantic salmon *Salmo salar* associated with *Tetrahymena* sp. *Dis. Aquat. Org.*, 2: 191-195.
- Iglesias R, Paramá A, Alvarez MF, Leiro J, Fernández J, Sanmartín ML (2001). *Philasterides dicentrarchi* (Ciliophora, Scuticociliatida) as the causative agent of scuticociliatosis in farmed turbot *Scophthalmus maximus* in Galicia (NW Spain). *Dis. Aquat. Org.*, 46: 47-55.
- Jee BY, Kim YC, Park MS (2001). Morphology and biology of parasite responsible for scuticociliatosis of cultured olive flounder *Paralichthys olivaceus*. *Dis. Aquat. Org.*, 47: 49-55.
- Jin CN, Harikrishnan R, Moon YG, Kim MC, Kim JS, Balasundaram C, Azad IS, Heo MS (2009). Histopathological changes of Korea cultured olive flounder, *Paralichthys olivaceus* due to scuticociliatosis caused by histophagous scuticociliate, *Philasterides dicentrarchi*. *Vet. Parasitol.*, 161: 292-301.
- Jung SJ, Kitamura SI, Song JY, Joung IY, Oh MJ (2005). Complete small subunit rRNA gene sequence of the scuticociliate *Miamiensis avidus* pathogenic to olive flounder *Paralichthys olivaceus*. *Dis. Aquat. Org.*, 64: 159-162.
- Kim SM, Cho JB, Kim SK, Nam YK, Kim KH (2004a). Occurrence of scuticociliatosis in olive flounder *Paralichthys olivaceus* by *Philasterides dicentrarchi* (Ciliophora: Scuticociliatida). *Dis. Aquat. Org.*, 62: 233-238.
- Kim SM, Cho JB, Lee EH, Kwon SR, Kim SK, Nam YK, Kim KH (2004b). *Pseudocohnilembus persalinus* (Ciliophora: Scuticociliatida) is an additional species causing scuticociliatosis in olive flounder *Paralichthys olivaceus*. *Dis. Aquat. Org.*, 62: 239-244.
- Kwon SR, Kim CS, Kim KH (2003). Differences between short and long-term cultures of *Uronema marinum* (Ciliophora: Scuticociliatida) in chemiluminescence inhibitory activity, antioxidative enzyme and protease activity. *Aquaculture*, 221: 107-114.
- Lom J, Dyková I (1992). Protozoan Parasites of Fishes. Elsevier, Amsterdam, 26: 237-288.
- Lourie SA, Vincent ACJ, Hall HJ (1999). Seahorse: An Identification Guide to the World's Species and Their Conservation, Project Seahorse, London, p. 214.
- Marichamy R, Lipton AP, Ganapathy A, Ramalingam JR (1993). Large scale exploitation of seahorse (*Hippocampus kuda*) along the palk Bay coast of Tamil Nadu. *Mar. Fish. Inf. Serv.*, 119: 17-21.
- Munday BL, O'Donoghue PJ, Watts M, Rough K, Hawkesford T (1997). Fetal encephalitis due to the scuticociliate *Uronema nigricans* in sea-cage, southern bluefin tuna *Thunnus maccoyii*. *Dis. Aquat. Org.*, 30: 17-25.
- Paramá A, Arranz JA, Alvarez MF, Sanmartín ML, Leiro J (2006). Ultrastructure and phylogeny of *Philasterides dicentrarchi* (Ciliophora, Scuticociliatida) from farmed turbot in NW Spain. *Parasitology*, 132: 555-564.
- Paramá A, Iglesias R, Álvarez F, Leiro JM, Quintela JM, Peinador C, González L, Riguera R, Sanmartín M (2004). *In vitro* efficacy of new antiprotozoals against *Philasterides dicentrarchi* (Ciliophora, Scuticociliatida). *Dis. Aquat. Org.*, 62: 97-102.
- Song JY, Kitamura SI, Oh MJ, Kang HS, Lee JH, Tanaka SJ, Jung SJ (2009). Pathogenicity of *Miamiensis avidus* (syn. *Philasterides dicentrarchi*), *Pseudocohnilembus persalinus*, *Pseudocohnilembus hargisi* and *Uronema marinum* (Ciliophora, Scuticociliatida). *Dis. Aquat. Org.*, 83: 133-143.
- Thompson JC, Moewus L (1964). *Miamiensis avidus* n. g., n. sp., a marine facultative parasite in the ciliate Order Hymenostomatida. *J. Protozool.*, 11: 378-381.
- Umehara A, Kosuga Y, Hirose H (2003). Scuticociliata infection in the weedy sea dragon *Phyllopteryx taeniolatus*. *Parasitol. Int.*, 52: 165-168.
- Vincent ACJ (1995). Exploitation of seahorses and pipefishes. *Naga.*, 18: 18-19.