

Full Length Research Paper

# Assessment of the medical benefit in the folkloric use of *Bryophyllum Pinnatum* leaf among the Igbos of Nigeria for the treatment of hypertension

S. Ghasi<sup>1\*</sup>, C. Egwuibe<sup>2</sup>, P. U. Achukwu<sup>2</sup> and J. C. Onyeanus<sup>2</sup>

<sup>1</sup>Department of Pharmacology and Therapeutics, College of Medicine, University of Nigeria, Enugu, Nigeria.

<sup>2</sup>Department of Medical Laboratory Sciences, College of Medicine, University of Nigeria, Enugu, Nigeria.

Accepted 3 December, 2010

The effects of aqueous leaf extract of *Bryophyllum pinnatum* on the blood pressure of anaesthetized cats, as well as on the liver and kidney status of the rabbit were investigated in this study. The results revealed that, the extract produced a small fall in the blood pressure of the anaesthetized cat and also reduced the effect of adrenaline-induced elevation of blood pressure. In rabbits, biochemical analysis of serum was carried out; urea and creatinine were used as tests of its effect on the renal function while alkaline phosphatase (ALP), aspartate transaminase (AST) and alanine transaminase (ALT) served as enzyme indices of the liver function. In addition, the tissues of the liver and kidney were microscopically examined. The treated rabbits showed a significant decrease ( $P \leq 0.05$ ) in their serum creatinine accompanied by significant increase in their serum urea ( $P \leq 0.05$ ). No significant changes of these biochemical parameters were seen in the serum of control animals. While a significant increase ( $P < 0.05$ ) was observed in the activity of the ALP of the treated animals, a non-significant increase ( $P > 0.05$ ) was recorded in the AST and ALT aminotransferases of both the treated and control animals. The increase recorded in the treated group was much higher (8.64 and 13.63%) as compared to the control group (0.69 and 7.05%). The histopathological examination of the kidney and liver of treated animals showed shrunken glomeruli with increased urinary space, mild necrosis of the tubules and hyaline droplets, while the liver tissue revealed necrosis of the liver cells, lymphocytic infiltration and pericuffing of the bile duct. The control animals, however, showed normal histological structure. In addition after 4 weeks of treatment, body weight in the control group was significantly higher than those in the treated group. It was concluded that the pharmacological basis for the use of *B. pinnatum* among the Igbos of Nigeria to lower blood pressure was established by this study. However, the facts that the reduction in blood pressure produced is slight and the *B. pinnatum* leaf extract is potentially organotoxic negate its use as a blood pressure lowering agent.

**Key words:** *Byophyllum pinnatum*, blood pressure, biochemical analysis, histopathology, rabbit.

## INTRODUCTION

All cultures have traditions of folkloric medicine that include the use of plants and other ethnopharmacological products. Despite availability of modern medicine in the treatment of different ailments, people still continue to patronize herbal remedies for obvious reasons of availability and affordability. Different medicinal plants

have different medicinal properties. No one herb is found to be used just for one purpose.

The use of neem, *Azadirachta indica* in the treatment of malaria fever which is endemic in Africa has not been neglected. A fall in the parasite counts of chloroquine resistant strains of plasmodium berghei-infected mice when treated with intraperitoneal dose of the leaf extract of the *A. indica* plant was reported (Ekanem, 1978). There was also a report on the growth-inhibiting effect of the boiled leaf extract on *Plasmodium falciparum* culture

\*Corresponding author. E-mail: samuel.ghasi@unn.edu.ng.

and the antimalarial effect of the boiled leaf was found to be approximately half of the therapeutic dose of chloroquine sulphate on dry weight basis (Ade-Serano, 1982).

*Ocimum gratissimum* leaf or the whole plant is a popular treatment for diarrhoea (Dalziel, 1956). It is known to have anticholinergic property and therefore decreases the activity of the gastrointestinal tract. The plant is also rich in volatile oils which contains up to 75% of thymol, the antimicrobial activity of which is well documented.

The leaf of *Moringa oleifera* Lam (Moringaceae) is used in India as a hypocholesterolemic agent in obese patients. The administration of the crude leaf extract of the plant along with high fat diet reduced the high fat diet induced increases in serum liver and kidney cholesterol levels in rats (Ghasi et al., 2000).

The plant, *Bryophyllum pinnatum* (Crassulaceae) is accepted as a herbal remedy in some parts of the world. Many of the *Bryophyllum*'s traditional uses have been validated by animal studies and clinical investigations undertaken so far on the plant (Olajide, 1998; Rossi-Bergmann, 2000; Igwe and Akunyili, 2005). It is commonly known as air plant, miracle leaf, life plant etc. Among the Igbos of Nigeria, it is known as 'odaa opue', in Yoruba as 'ewe abamoda' or 'odundun' and in Chinese as 'da bu si.'

The plant is among the list of medicinal plants used by the Red-headed Yao people in Jinping of Yunnan Province, China, in the treatment of conditions like rheumatoid arthritis, tummy bug, injuries from falls, numbness of limbs, bruise, bum and ulcer (Chun-Lin and Rong, 2004).

Many of the *Bryophyllum*'s traditional uses have been confirmed by the clinical research conducted so far on the plant. The traditional use for infectious conditions (both internally and externally) is supported by research indicating that *Bryophyllum* leaves have antibacterial, antiviral and antifungal activity. The leaf and leaf juice have demonstrated significant antibacterial activity towards *Staphylococcus*, *Escherichia coli*, *Shigella*, *Bacillus* and *Pseudomonas*, including several strains of multi-drug resistant bacteria (Obaseki-Ebor, 1985).

A water extract of *Bryophyllum* leaves administered topically and internally has been shown to prevent and treat Leishmaniasis (Rossi-Bergmann, 2000). In addition to its antibacterial properties, the traditional uses of *Bryophyllum* for upper respiratory conditions and coughs have been validated by studies demonstrating that the leaf juice has potent anti-histamine and anti-allergic activities (Nassis, 1992). In an *in vivo* study with rats and guinea pigs, the leaf juice was able to protect against chemically induced anaphylactic reactions and death by selectively blocking histamine receptors in the lungs (Nassis, 1992).

On the other hand, previous *in vivo* study established the pharmacological basis for the use of *Bryophyllum* in gastric ulcerations; a leaf extract protected mice from

such ulcer inducers as stress, aspirin and ethanol. Other studies have confirmed that *Bryophyllum* can reduce fever and does provide anti-inflammatory, analgesic and muscle relaxant effects. Its anti-inflammatory effects have been partially attributed to the immunomodulatory and immune suppressant effect documented by scientists in several studies (Olajide, 1998).

In a recent work in Nigeria, the aqueous leaf extract of *B. pinnatum* was shown to have strong analgesic effect (Igwe and Akunyili, 2005). It is not well known or widely available in the United States of America as a herbal remedy but it continues to be a popular natural remedy throughout the tropics where it grows.

Among the Igbos of Nigeria, *B. pinnatum* is believed to have antihypertensive activity. Decoctions of the leaf are usually taken to lower the blood pressure. Some people also chew the raw leaves of the plant for this purpose. The aim of this study is to investigate the validity of this claim which is folkloric and not supported by any literature.

## MATERIALS AND METHODS

### Animals

Twenty-four adult healthy rabbits of both sexes weighing between 1.2 and 2.4 kg were used for this study. The animals were procured from the animal house of the College of Medicine at the University of Nigeria Teaching Hospital. They were divided into three sex-matched groups of eight animals each and maintained at room temperature. They were allowed free access to clean drinking water and were fed on standard rabbit pellets throughout the period of study. Blood samples were taken from the marginal ear vein of the animals to determine the baseline values of the biochemical parameters before the administration of the leaf extract of *B. pinnatum*.

### Design of experiment

The animals in the first and second groups received 150 mg and 300 mg/kg body weight of the aqueous extract of *B. pinnatum* respectively, while those in the third group served as the control and were fed orally with the feed and water only. The plant extract was administered intraperitoneally after it was reconstituted in distilled water. The total period of treatment was four weeks. Blood samples were collected at the end of the fourth week for the estimation of biochemical parameters namely; alkaline phosphatase, alanine transaminase and aspartate transaminase. Serum urea and creatinine were also estimated. Animals' individual body weights were checked before and after the experiment. Some of the animals were sacrificed at the end of the fourth week and their liver and kidney dissected out and processed for light microscopical examination.

### Processing of the crude plant extract

Fresh leaves of *B. pinnatum* were collected from Awka, Anambra State and identified by Prof. J. C. Okafor of the Fame Agricultural Centre, Enugu. The leaves were shade-dried, crushed manually in a ceramic mortar and extracted exhaustively in distilled water. The extract was evaporated to dryness with thermostatic electrothermal

heater. The temperature of the heater was regulated between 40 to 60°C to avoid burning. The dried sample which gave a yield of 28% was stored in the desiccator until used. Samples used throughout the period of the study were weighed from the stored sample. 4 g of the dried *B. pinnatum* was weighed out daily and diluted in 40 mls of distilled water to give a concentration of 100 mg/ml.

For administration, the extract was reconstituted daily in distilled water and administered intraperitoneally to the animals. Any unused diluted sample was discarded at the end of each experiment.

#### Method of blood collection from the rabbits

About 4 mls of venous sample was collected from each of the animals. The blood was collected from their marginal ear veins by venepuncture. The hair/fur around the ear was shaved and cleaned with 70% methanol spirit (particularly around the vein). The ear vein was occluded with thumb to allow accumulation of the blood in the vein. A sterile scalpel was used to puncture the vein and blood was allowed to drip down into a sterile plain tube up to the volume of blood that was needed.

#### Biochemical studies

##### Serum urea estimation

The modified diacetylmonoxime method of Wybenga et al. (1971) was used. Serum urea reacts with diacetylmonoxime at high temperature in an acid medium to produce a yellowish condensation product. The reaction can be intensified by the presence of ferric ions and thiosemicarbazide. The red complex formed is more linear with urea concentration than the yellow one. The reaction product is read at 540 nm (530 – 570 nm).

##### Serum creatinine determination

In serum creatinine determination of the samples, the alkaline picrate method of Fabing and Ertingshausen (1971) was used. Creatinine reacts with picric acid in an alkaline medium to form a red-orange coloured complex, creatinine picrate. This is referred to as Jaffe reaction. However, the reaction is not specific to creatinine, as many non-creatinine substances present in the plasma and the RBC are known to give Jaffe reaction.

##### Alkaline phosphatase estimation

Alkaline phosphatases are a group of phosphomonoester enzymes that have optimal activity when the PH is around 9.8. They act on large variety of physiological or non-physiological substrate. The method of Kind and King (1954) was employed. In the above method, disodium phenyl phosphate is used as the substrate. Hydrolyses of this substrate by the enzyme then liberates phenol and phosphoric acid. The phenol is estimated by its reaction with 4-aminoantipyrine to produce a colour in the presence of alkaline oxidizing agent, alkaline ferricyanide

##### Transaminases estimation

The method of Reitman and Frankel (1957) was employed for this study. The aminotransferases are metabolic enzymes, which catalyse transamination reaction in the body and they include aspartate transaminase and alanine transaminase. In this method,

the oxoacids produced are estimated by their coupling reaction with 2, 4-dinitrophenyl hydrazine to form an oxoacid hydrazone which is reddish brown in alkaline medium.

#### Microscopical examination of the organs

At the end of the four weeks, some of the animals were sacrificed under chloroform anaesthesia. Their livers and kidneys were harvested and fixed in 10% formalin for 24 h. The tissues were processed for light microscopy using an automatic tissue processor, embedded in paraffin wax, and thin sections (about 4 - 5 µm thick) were obtained using a rotary microtome. The sections were deparaffinized and stained by haematoxylin and eosin (H and E) method, according to Baker et al. (1998). Slides were examined and photographed independently by two histopathologists using a light microscope.

#### Blood pressure determination

Two cats that weighed 1.7 and 2.2 kg were used for this study according to the method as reported by Ghasi et al. (2009).

## RESULTS

#### Biochemical studies

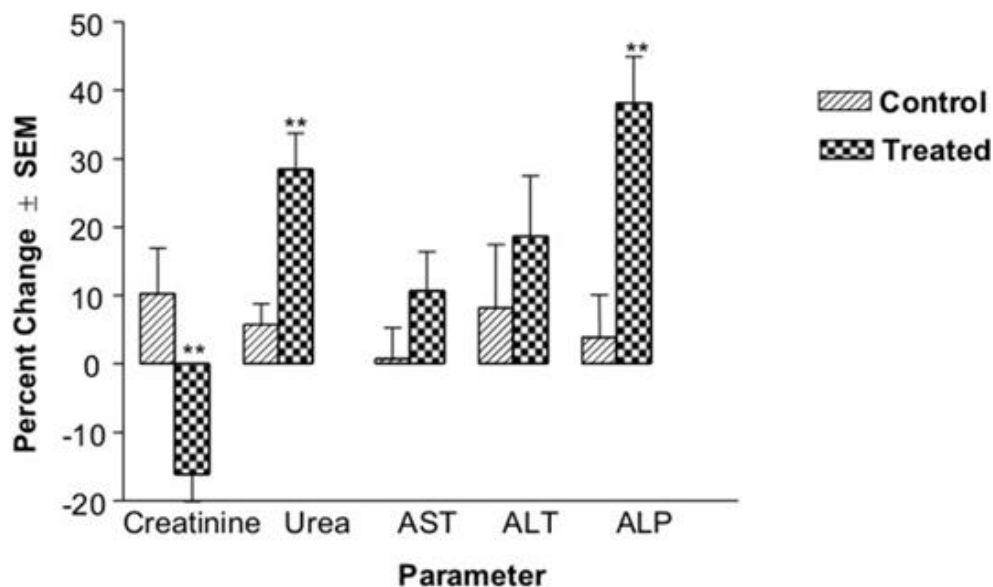
Possible changes in the renal function of the animal models were evaluated by the analysis of their serum urea and creatinine before and after the experiment, while the activities of the aspartate transaminase (AST), alanine transaminase (ALT) and alkaline phosphatase (ALP) served as a test of their liver function (Figure 1).

All the animals that received 300 mg/kg leaf extract of *B. pinnatum* died within a few days of the study. Consequently, analysis was between the control group and the test group that received 150 mg/kg of the extract.

Table 1 shows the mean value of the biochemical parameters analysed in the control animals before and after the 4 weeks study. Comparison was done between the arithmetic means of the control and test groups using paired Student 't' test as a measure of their statistical significance; thus each animal served as its own control. Significance was determined at  $P \leq 0.05$ .

The results revealed statistically non-significant increases in the serum urea and creatinine levels of the control animals at the end of the study compared to the baseline values. Whereas a non-significant decrease was seen in the activity of the alkaline phosphatase in the control group, a non-significant increase in the AST and ALT activities, of 0.69 and 7.05%, respectively were observed in the same group.

Table 2 shows the results of the biochemical parameters in the treated animals before the initiation of the treatment and after treatment with the aqueous extract of *B. pinnatum* (150 mg/kg) for 4 weeks. A significant increase was recorded in the serum urea level of these animals while a statistically significant decrease was observed in the serum creatinine level after the 4



**Figure 1.** Histogram of the percentage change  $\pm$  SEM of the values of some biochemical parameters at the end of 4 weeks in the case the control and treated groups compared to the baseline values \* $p < 0.05$ , \*\* $p < 0.005$ .

**Table 1.** Mean values of the biochemical parameters determined in the control animals.

Parameter	Unit	Baseline values	Values after 4 wks	P values
Creatinine	mg/dl	0.80 $\pm$ 0.08	0.85 $\pm$ 0.06	0.2753
Urea	mg/dl	34.88 $\pm$ 2.92	37.13 $\pm$ 3.77	0.1009
AST	iu/L	18.50 $\pm$ 1.25	18.63 $\pm$ 1.46	0.8786
ALT	iu/L	9.88 $\pm$ 1.36	10.63 $\pm$ 1.65	0.2654
ALP	iu/L	50.50 $\pm$ 6.65	49.13 $\pm$ 4.93	0.6261

Data represent mean  $\pm$  SEM of 8 rabbits ALT = alanine transminase, AST = aspartate transaminase and ALP = alkaline phosphatase.

**Table 2.** Mean values of the biochemical parameters in the treated animals.

Parameter	Unit	Baseline values	Values after 4 wks	P values
Creatinine	mg/dl	0.74 $\pm$ 0.11	0.60 $\pm$ 0.08	0.0080
Urea	mg/dl	25.25 $\pm$ 0.086	32.50 $\pm$ 1.96	0.0017
AST	iu/L	18.50 $\pm$ 0.73	20.25 $\pm$ 0.65	0.1222
ALT	iu/L	14.25 $\pm$ 1.10	16.50 $\pm$ 1.18	0.1218
ALP	iu/L	50.38 $\pm$ 8.52	65.50 $\pm$ 11.32	0.0046

Data represent mean  $\pm$  SEM of 8 rabbits, AST = aspartate transminase, ALT = alanine transminase and ALP=alkaline phosphatase.

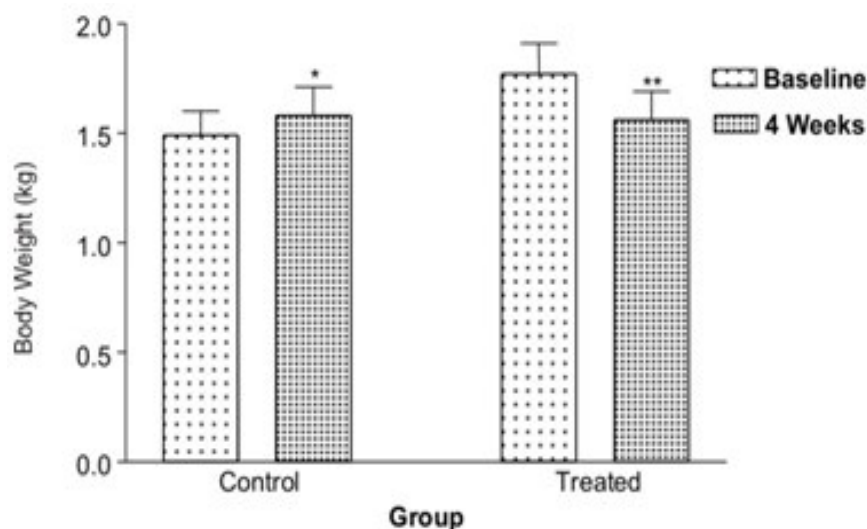
weeks treatment (Figure 1). Although, AST and ALT activities were non-significantly increased after 4 weeks; the increase was much higher (8.64 and 13.63%) in the treated animals, as compared to the control group (0.69 and 7.05%) for the same period of time. However, there was a significant increase in the activity of the alkaline phosphatase.

The comparison between the control group and the treated animals are shown in Table 3. The percentage differences of the biochemical parameters analysed in both groups were determined and the mean of the differences obtained. Unpaired Student 't' test was used as a measure of comparison between the two groups to ensure that any difference noted between the groups

**Table 3.** Mean values of biochemical parameters of the treated and control animals.

Parameter	Unit	A-control group % difference	B-treated group % difference	P- Values
Creatinine	mg/dl	10.24 ± 6.65	16.11 ± 4.01	0.0044
Urea	mg/dl	5.70 ± 3.10	28.49 ± 5.21	0.0021
AST	iu/L	0.75 ± 4.55	10.75 ± 5.61	0.1877
ALT	iu/L	8.21 ± 9.25	18.65 ± 8.90	0.2654
ALP	iu/L	3.90 ± 6.17	38.15 ± 6.75	0.0022

Data represents mean % difference ± SEM of 8 rabbits per group. AST = aspartate transaminase, ALT = alanine transaminase and ALP = alkaline phosphatase.



**Figure 2.** Weights of animals in the control and treated groups before the commencement of the study and at the end of 4 weeks. There was an increase in weight in the control group which was statistically significant and a decrease in weight in the treated group, the difference also statistically significant \*p < 0.005, \*\*p < 0.0005.

would be suggestive of the effect due to the herbal extract. There was a significant decrease in the serum creatinine level of the treated animals when compared with the control animals while a significant increase was observed in the urea level of the treated animals in comparison to the control group. Statistically non-significant increases were also observed in the transaminases of the treated animals when compared with the control group, although, the increase was much higher in the treated group while the activity of the alkaline phosphatase recorded a significant increase in the treated animals compared to the control animals.

Figure 2 compares the weights of the rabbits, in both the control and test groups, at the commencement and conclusion of the study.

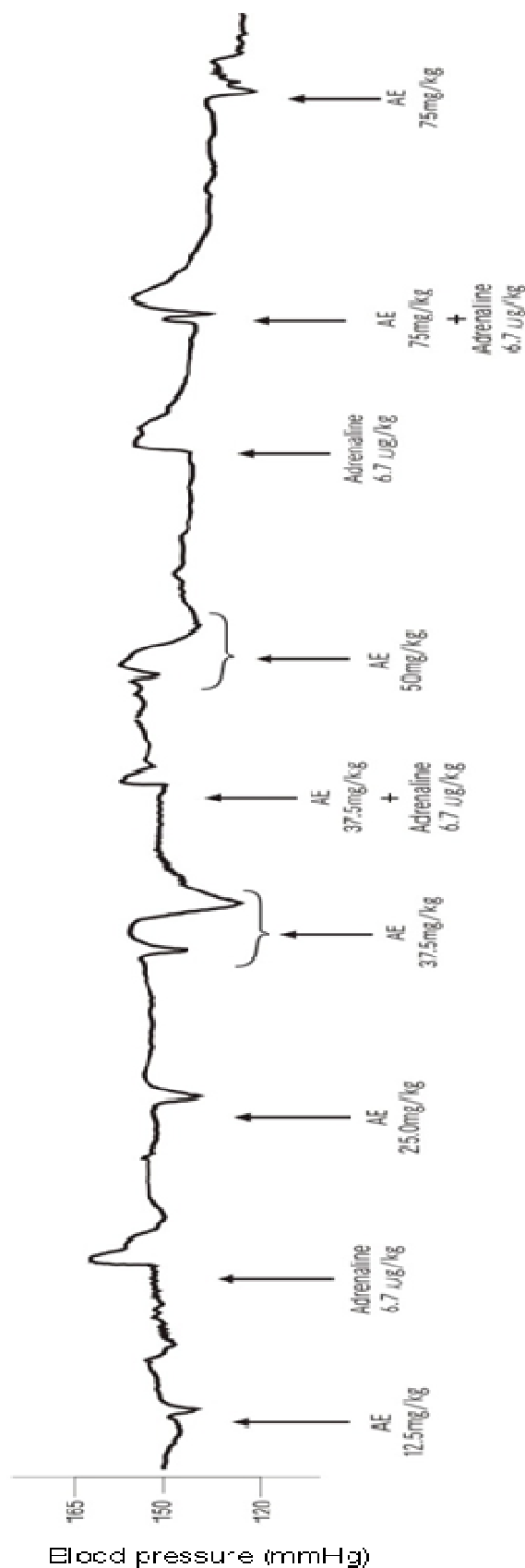
### Histological studies

The histological changes of the liver and kidney in the

different groups are shown in the plates. From the plates, the control animals showed a normal histological appearance (Plates 1 and 5) whereas in the treated animals, various degrees of histopathological appearance were observed in the liver of the animals treated with the aqueous extract. (Plates 2 to 4). The liver morphological changes manifest as monocellular infiltration, cuffing of the bile duct by inflammatory cells; degeneration and mild necrosis of the hepatocytes and sinusoidal dilatation. However, the histological changes in the kidney showed few tubular hyalinization, mild degenerate glomeruli and cellular infiltration (Plates 6 to 9).

### Blood pressure of anaesthetized cat

Anaesthetized cat was used in this experiment. Intravenous dose of 12.5 mg/kg body weight of the aqueous extract of *B. pinnatum* produced a slight reduction in the blood pressure by 3 to 4 mmHg. At 25.0



**Figure 3.** Effect of aqueous extract of *B. pinnatum* leaf on the blood pressure of anaesthetized cat.

mg/kg of the aqueous extract, the fall in the blood pressure was still slight; it reduced by 8 to 9 mmHg (Figure 3). Administration of 6.7 µg/kg adrenaline increased the blood pressure by 12 mmHg and the pressure returned to normal gradually over a period of one minute. The intravenous dose of the extract given to the cat was increased to 37.5 mg/kg and the fall in blood pressure was between 8 to 12 mmHg.

Treatment of the animal with 6.7 µg/kg adrenaline and 37.5 mg/kg extract of *B. pinnatum* concurrently reduced the blood pressure from 150 to 143 mmHg (4.6% decrease) and it returned to the baseline pressure within 3 min. 50 mg/kg of aqueous extract reduced the blood pressure more markedly by 8 to 15 mmHg. When 6.7 µg/kg adrenaline was administered concomitantly with 75 mg/kg extract, the blood pressure was reduced from 124 to 108 mmHg, a 12.0% decrease.

## DISCUSSION

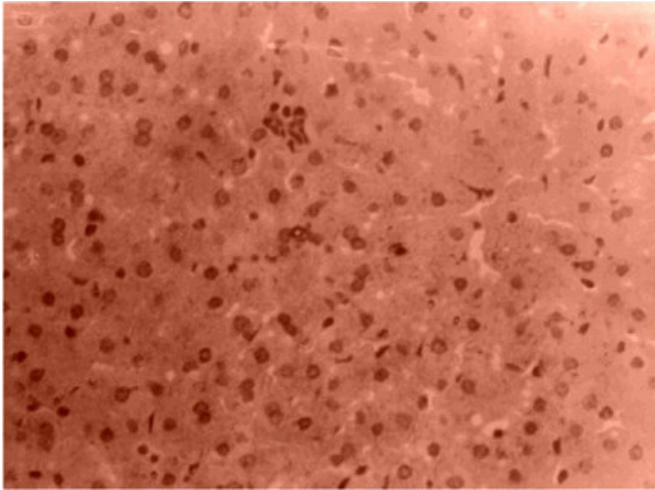
The current results of the 4 weeks study showed that the aqueous extract of the leaf of *B. pinnatum*, given intraperitoneally to rabbits in daily doses of 150 and 300 mg/kg body weight produced some biochemical and pathological changes in the animals.

The present results revealed a significant increase in the serum urea of the treated animals and a significant decrease in their serum creatinine level when compared with the animals in the control group. Adeoye and Oyedapo (2004) investigated the toxicity of the stem-bark of *Erythropophleum guineense* plant in Sprague - Dawley rats. The plant, like *B. pinnatum*, was reported to have caused a significant elevation of serum urea while significantly decreasing the serum creatinine of the rats after oral administration of the water extract of the alkaloidal fraction of the stem bark for 7 days. Interestingly, phytochemical analysis showed that this plant has similar chemical components with *B. pinnatum*. The elevation in serum urea was attributed to the impairment of the kidney, possibly, a result of the alkaloidal fraction of the plant (Adeoye et al., 2004), while the decrease in serum creatinine was attributed to the increased uptake of creatinine from circulation in the treated animals, which implies that the integrity of the skeletal muscles in the treated rats is adequately protected (Adeoye and Oyedapo, 2004).

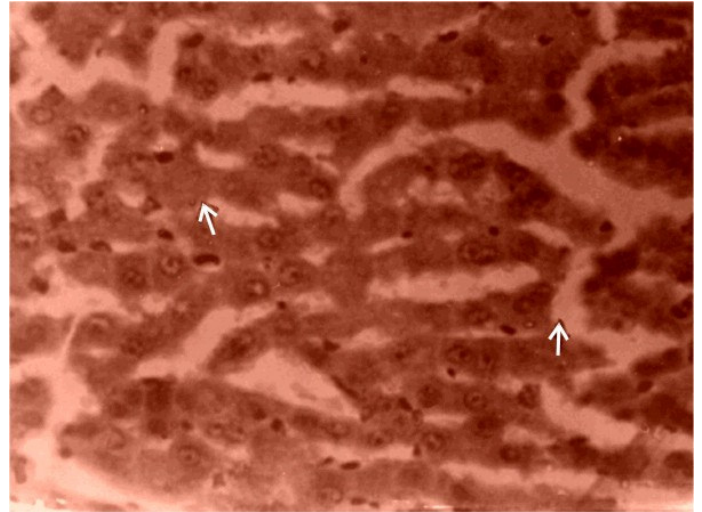
Some herbal extracts are known to increase serum liver enzymes. Akah et al. (1991) investigated the effect of aqueous extract of *A. indica* on the liver of rabbits and showed that it is hepatotoxic. The enzymes indices of hepatic dysfunction (SGPT, SGOT and ALP) as well as liver histology were studied, and significant elevation of these hepatic enzymes was observed after oral administration of the extract for 4 weeks.

In another hepatotoxic study carried out on the liver of albino rats, using rinbancin (a trademark preparation) as a homeopathic drug, the herbal preparation, which was

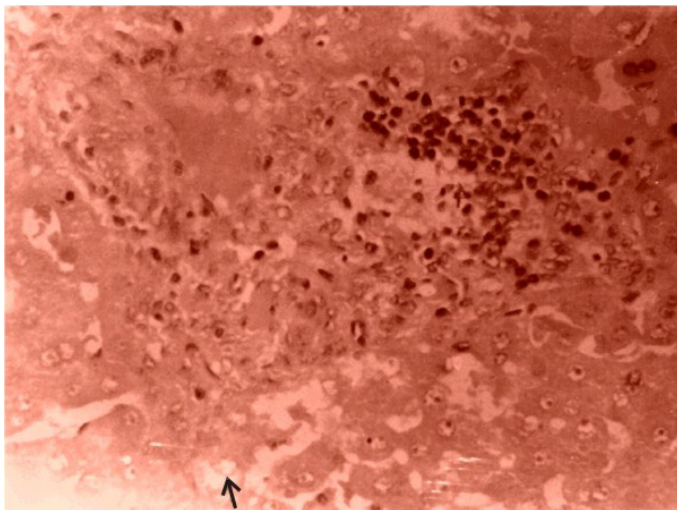




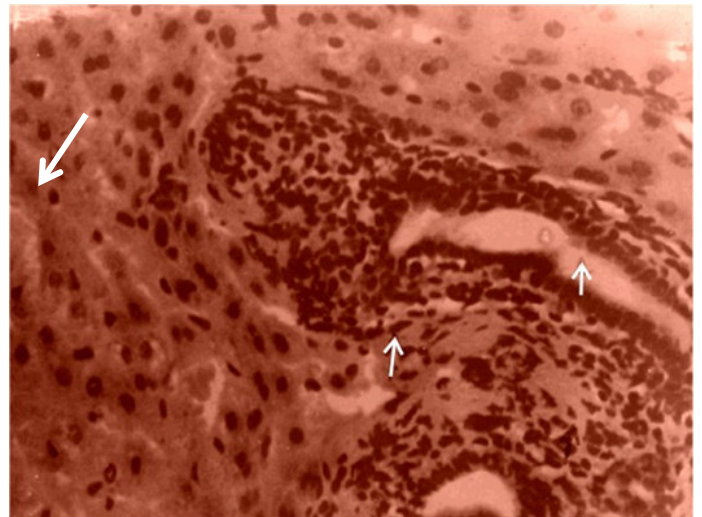
**Plate 1.** Photomicrograph of liver section of rabbit in the control group showing normal architecture. Stained by H&E technique X400.



**Plate 3.** Photomicrograph of liver section of rabbit dosed 150mg/kg showing sinusoidal dilatation (arrows). Stained by H&E technique X400.



**Plate 2.** Photomicrograph of liver necropsy of rabbit dosed 150mg/kg showing aggregation of inflammatory mononuclear cell infiltrates (white arrow). Other areas of the parenchyma show ghost hepatocytes suggestive of mild necrosis (black arrow). Features are consistent with toxic inflammation and necrosis. Stained by H and E technique X400.



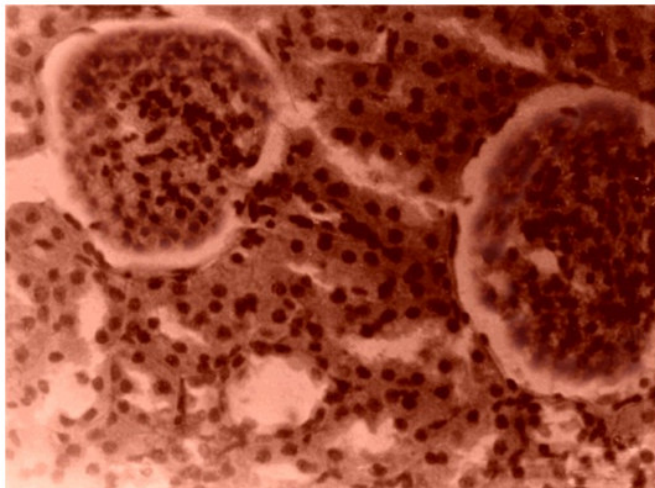
**Plate 4.** Photomicrograph of liver section of rabbit dosed 150mg/kg showing hypertrophy and peri-cuffing of the bile duct by a teeming population of inflammatory cells (arrows). Stained by H and E technique X400.

found to contain alkaloids, flavonoids and essential oils, was shown to have caused a significant elevation in all the liver function parameters tested after 13 weeks oral administration of the herbal preparation at certain dose levels of rinbacin (26.25 and 52.50 g/L) (Dioka et al., 2002)

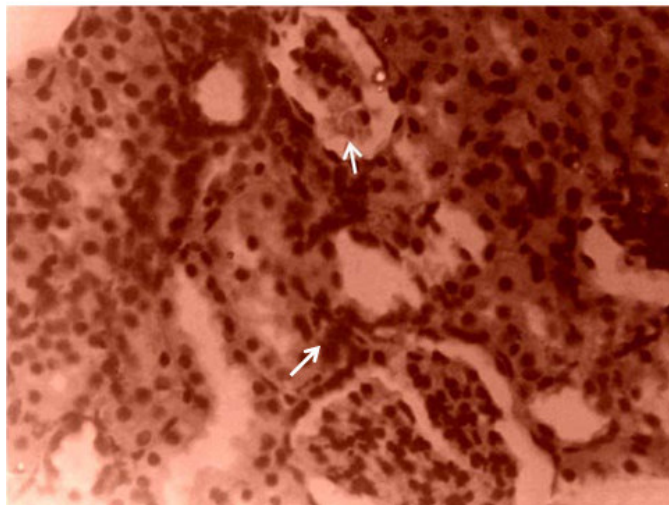
In the present investigation the levels of AST, ALT and ALP, hepatic enzyme markers were also measured and the results showed that there was a non-significant elevation in the transaminases (AST and ALT) in both the control and treated animals, though, the elevation was

more in the treated group, while the level of alkaline phosphatase was significantly increased in the treated animals. The control animals, however, presented a non-significant decrease in the activity of the alkaline phosphatase (ALP). Elevated activities of these enzymes are a common sign of hepatic disease conditions (Adolph and Lorenz, 1982). This confirmed the suggestion that the integrity of the liver may have been affected by the aqueous extract of *B. pinnatum* leaf.

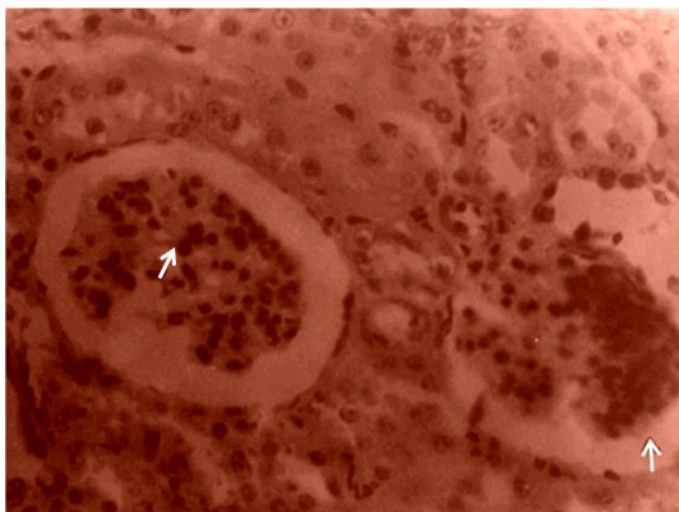
It was further observed in the present study that after the first week of treatment, the animals in the treatment



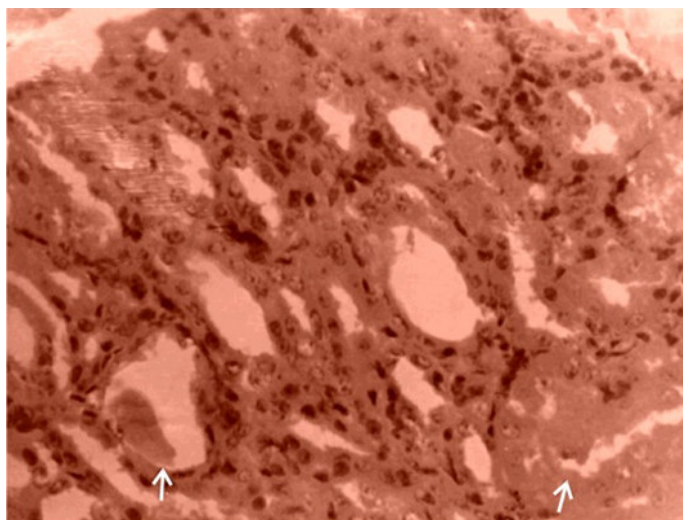
**Plate 5.** Photomicrograph of kidney necropsy section of rabbit in the control group showing no pathological changes. Stained by H&E technique X400.



**Plate 7.** Photomicrograph of kidney necropsy section showing mild degenerate glomeruli (small arrow). Notice cell degeneration (large arrow). Stained by H and E method X400.



**Plate 6.** The kidney section of rabbit dosed with 150 mg/kg of aqueous extract of *B. pinnatum* leaf displaying shrunken glomeruli and increased urinary space (small arrow) with degenerative changes (large arrow). Stained by H and E technique X400.



**Plate 8.** Photomicrograph of the kidney necropsy section of rabbit dosed 150 mg/kg showing tubular hyalinization (arrows). Stained by H and E technique X400.

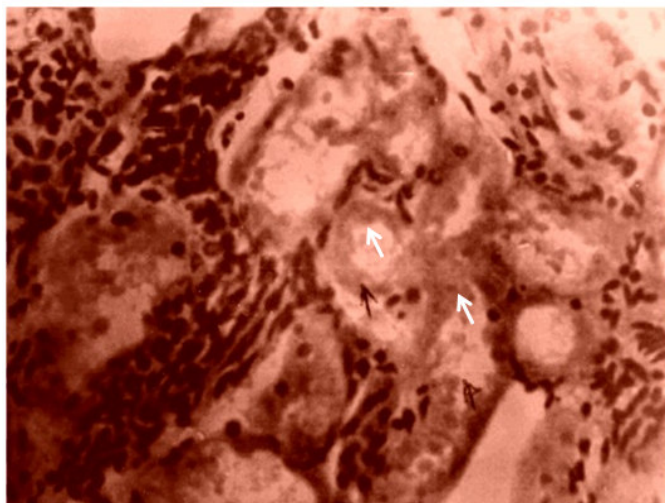
group began to feed less readily when compared to the control group. Moreover, at the end of the 4 weeks, the body weight of the control rabbits had significantly increased unlike the treated animals that lost weight. This explains one of the symptoms of the poisonous effects of *B. pinnatum* in cattle, where the animals experienced loss of appetite and weight.

During this investigation, it was observed that all the animals administered with the higher dose of 300 mg/kg body weight of *B. pinnatum* aqueous extract died after the 4<sup>th</sup> day of initiating treatment. It was also noticed that only one rabbit showed signs of dullness, while the rest were

generally asymptomatic and fed normally until they were found suddenly dead.

In herbal practice, most practitioners believe that plant remedies are non-toxic and free from undesirable side effects. However, many ordinary foods contain constituents that could be regarded as poisonous, such as the alpha gliadin produced by gluten in wheat oats and rye, the cyanogenic glycosides in many fruit seeds, the thiocyanates of the brassica vegetables, alkaloids of the solanaceae and lectins of many pulses including soya and red kidney beans (Jonathan, 2005). Also, cassava diet, a staple source of carbohydrate, caused fatty





**Plate 9.** Kidney section of rabbit dosed 150 mg/kg of extract and shows evidence of tubular hyalinization (white arrow) and necrosis in some areas (black arrow). Stained by H and E technique X400.

infiltrations in the pancreas of albino rats (Ureme et al., 2000). Nevertheless, these foods are generally considered safe.

During this study, the observation that animals which received high dose (300 mg/kg) of *B. pinnatum* crude leaf extract died after a few days, was not entirely surprising. *B. pinnatum* is rich in alkaloids, triterpenes, glycosides, flavonoids, steroids and lipids. It has also been found to contain pyruvate, phosphoenol pyruvate, bryotoxin C, bryophyllin, bryophyllol, bryophynol, bryophollenone etc. The leaves contain a group of chemicals called bufadienolides which are very active and have sparked the interest of scientists (Yamagishi et al., 1988). They are very similar in structure and activity as two other cardiac glycosides, digoxin and digitoxin. It has been reported that *Bryophyllum* species are highly toxic to stock. For instance, poisoned cattle showed signs of dullness, loss of appetite and weight (Kingsburg, 1964). Also in Australia and Southern Africa, various *Bryophyllum* species have killed cattle as a result of their cardiac glycoside content and conduction disturbances through the myocardium resulting in decreased cardiac output and death (Anderson et al., 1983; McKenzie and Dunster 1986; Reppas, 1995).

We could attribute the sudden death of the rabbits to the same conditions noted in the case of the poisoned cattle, that is, dysrhythmic conditions caused by the high dose of the aqueous extract of *B. pinnatum* (300 mg/kg) administered.

The kidney morphology indicated some mild changes in the glomerular structure of the treated animals in comparison to the control animals as indicated by the increased urinary space, shrunken glomeruli, mild necrosis of the tubules and hyaline droplets, while the pathological changes in the liver morphology of the

treated animals manifested as necrosis of the liver cells, with aggregation of inflammatory mononuclear cell infiltrates, and also pericuffing of the bile duct by the inflammatory cells. These alterations in the structure of the liver and kidney of the animals could be attributed to the toxic effects of certain from *B. pinnatum* leaf in these animals.

The fall in the blood pressure of the cat, produced by the aqueous extract of *B. pinnatum* leaf was found to be dose dependent, but not very marked. For every dose of the extract given, the reduction in the blood pressure, produced by the extract was found to be more pronounced with increasing dose. The hypotensive effect was, however, very transient and always returned to its original level within 3 min.

## Conclusion

Although, the extract decreased blood pressure supporting the claim of people that use it for that purpose, the findings here would not encourage the use of *B. pinnatum* for the management of hypertension. The antihypertensive effect produced would not be of any real benefit considering that the fall in blood pressure was always diminutive. One must be wary of ingesting the extract of this herb because of its potential to be not only hepatotoxic and nephrotoxic but, at high doses, also cardiotoxic.

It is suggested that effects of aqueous extract of *B. pinnatum* leaf on the cardiovascular system be pursued to determine its exact mode of action responsible for the mortality of the rabbits that received high dose of the extract.

## REFERENCES

- Adeoye BA, Oyedapo OO (2004). Toxicity of *Erythrophleum guineense* stem-bark: Role of alkaloidal fraction. *Afri. J. Trad., Complement. Alternat. Med.*, 1: pp. 45-54.
- Ade-Serano MA (1982). Growth Inhibitory and Lymphocytotoxic effect of *Azadirachta Indica*. *J. Med. Plants.*, 5: 137-139.
- Adolph L, Lorenz R (1982). Enzyme Diagnosis in Hepatic Disease in "*Enzyme Diagnosis in Disease of the Heart, Liver and Pancreas*" Tutte Druckerei Gmbtt, Salzweg-Passau Germany, pp. 81-104.
- Akah PA, Offiah VN Onuogu E (1991). Hepatotoxic effect of *Azadirachta indica* leaf extract in rabbits. *Fitoterapia*, 63 (4): 311-319.
- Anderson LAP, Anitra SR, Joubert JPJ (1983). Krimpiekte and acute cardiac glycoside poisoning in sheep caused by bufadienolides from the plant *Kalanchoe Lanceolata* Forsk. *Onderstepoort J. Veterin. Res.*, 50: 295-300.
- Baker FJ, Silvertown RE, Pallister CJ (1998). Introduction to Medical Laboratory Technology 7<sup>th</sup> Edition. Educational and Professional Publishing Limited, New Delhi, India, pp. 211-215.
- Chun L, Rong L (2004). Ethnobotanical Studies on Medicinal Plants used by the Red-headed Yao people in Jinping Yunran Province, China. *J. Ethnopharmacol.*, 90: 389-395.
- Dalziel JM (1956). Useful Plants of West Tropical Africa, 1<sup>st</sup> Edition, Crown Agents for Overseas Government, London, p. 28.
- Dioka C, Orisakwe EO, Afonne JO, Agbasi PU, Akumka DO, Okonkwo JC, Ilondu N (2002). Investigation into the hematologic and hepatotoxic effects of Rinbacin in Rats. *J. Health. Sci.*, 48(5): 393-

398.

- Ekanem JM (1978). Has *Azadirachta indica* (dogonyaro) any antimalarial activity Nig. Med. J., 8 (1): 8-11.
- Fabing DL, Ertingshausen G (1971). Automated reaction-rate method for determination of creatinine with the centrifichem. J. Clin. Chem., 17: 696-700.
- Ghasi S, Nwobodo E, Ofili JO (2000). Hypocholesterolemia effects of crude extract of *Moringa Oleifera* leaf in high fat diet fed Wistar rats. J. Ethnopharmacol., 69: 21-25.
- Ghasi S, Chijioke CP, Anakwue R (2009). Pharmacodynamic effect of piperazine citrate on the blood pressure of anaesthetized cat. Afr. J. Pharm. Pharmacol., 3(8): 379-383.
- Igwe SA, Akunyili DN (2005). Analgesic Effects of Aqueous extracts of the leaves of *B. Pinnatum*. Pharmaceut. Biol., 43(8): 658-661.
- Jonathan (2005). Introduction to side effects, safety and toxicity of medicinal herbs. <http://www.herbalogical.com/>.
- Kind PR, King EJ (1954). Estimation of plasma phosphatase by determination of hydrolysed phenol with amino-antipyrine. J. Clin. Pathol., 7(4): 322-326.
- Kingsburg JM (1964). Poisonous Plants of the United States and Canada. Eaglewood Cliffs: Prentice Hall: pp. 262-267.
- McKenzie RA, Dunster PJ (1986). Herbs and Flowers: *Bryophyllum* Poisoning of Cattle. Austr. Veter. J., 63: 222-227.
- Nassis CZ (1992). Antihistamine activity of *Bryophyllum* spp. *Brazilian Med. J. Biochem. Rev.*, 25 (9): 929-936.
- Obaseki-Ebor EE (1985). Preliminary report on the in-vitro antibacterial activity of *B. pinnatum* leaf juice. Afr. J. Med. Sci., 14(3-4): 199-202.
- Olajide OA (1998). Analgesic, anti-inflammatory and antipyretic effects of *Bryophyllum pinnatum* *Fitoterapia*, 69 (3): 249-252.
- Reitman S, Frankel S (1957). A colorimetric method for the determination of serum glutamate oxaloacetic and glutamic pyruvic transaminases. Am. J. Clin. Pathol., 28: 56-63.
- Reppas GP (1995). *Bryophyllum pinnatum* poisoning of cattle. Australian Veter. J., 72: 425-427.
- Rossi-Bergman B (2000). Treatment of Cutaneous leishmaniasis with *B. pinnatum*: experimental and clinical data. *Phytomedicine. suppl.*, 7 (2): SL115-117.
- Ureme SO, Obidua O, Ghasi S (2000). Cassava diet and histopathological changes of pancreas in albino rats. *Biomed. Res.*, 12(3): 237-240.
- Wybenga C, Di Giorgio J, Pileggi VJ (1971). Manual and automated methods for urea nitrogen measurement in whole serum. J. Clin. Chem., 17: 891-895.
- Yamagishi T, Haruna M, Yan YZ, Chang JJ, Lee KH (1988). Structure and Stereochemistry of bryophyllin-A, a novel cytotoxic bufadienolide orthoacetate from *B. pinnatum*. *Chem. Bull. (Tokyo)*, 36 (4): 1615-1617.