

Short Communication

Response of liver and gills of *Mystus gulio* to the heavy metal pollutants and metacercarian infection

Sherly Williams E.¹, Beena V. S.², Razeena Karim L.^{1*} and Seethal Lal S.¹

¹Environmental Sciences, Aquaculture and Fish Biotechnology Division, Department of Zoology, Fatima Mata National College, Kollam, India.

²Saraswathy Vidhayalam, Thiruvananthapuram, India.

Received 2 February, 2014; Accepted 26 August, 2014

***Mystus gulio* collected from the polluted waters of Veli lake in the Thiruvananthapuram district of Kerala, India was subjected to histopathological observations to study the effect of the pollutants on the tissue of the fishes. The epithelial layer of the secondary lamellae was lifted and detached from the underlying tissue, and was also seen in a degenerative form. The hepatocytes have lost their shape and regular arrangement, and was seen accumulated in a syncytial mass. Pycnotic nuclei, enlargement of nuclei and condensation of nuclear material were observed all through. Brownish pigments were scattered throughout the tissue which shows the possibility of accumulation of heavy metals. Inflammatory reaction of the liver against a metacercarian cyst was also demonstrated.**

Key words: *Mystus gulio*, Veli lake, syncytial mass, metacercarian cyst, pycnotic nuclei.

INTRODUCTION

Fish and aquaculture products contribute a significant amount of animal protein to the diets of people worldwide. Being highly nutritive, they serve as valuable food supplement in diets lacking essential vitamins and minerals (Jayasree and Arunachalam, 2000). Fishes and aquaculture products are seriously affected by pollution due to urbanization, industrialization and by human activities. Most of the pollutants are non biodegradable, which causes negative impact on the environment. When these pollutants reach the environment, it brings irreversible damage to the natural resources and ecosystem. Water pollution severely affects the aquatic life. Massive

fish kills and diseases of fishes due to industrial pollution have become a common feature in various parts of the country. Anaerobic conditions resulting from the organic wastes are responsible for the diseases in fish (Overstreet and Devender, 1976). Hyperplasia, fusion of gill lamellae separation of respiratory epithelium from underlying tissues, extensive lipid vacuolation in hepatocytes, atrophy and necrosis of pancreatic tissues were observed in estuarine fishes exposed to crude oil (Solangi and Overstreet, 1982). Stroke et al. (1985) observed hyperplasia of the gill tissues and swollen hepatic cells when the fishes are exposed to coal derived materials.

*Corresponding author. E-mail: razeenashibli@rediffmail.com.

Author(s) agree that this article remain permanently open access under the terms of the [Creative Commons Attribution License 4.0 International License](http://creativecommons.org/licenses/by/4.0/)

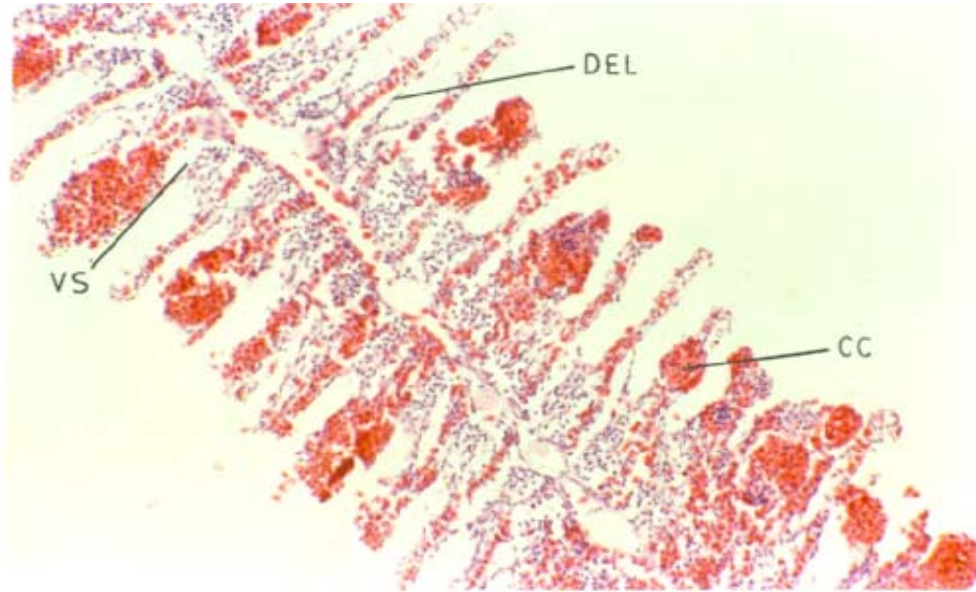


Figure 1. Appearance of gills of fish collected from polluted environment showing some degenerative changes in the secondary lamellae. DEL: Damaged epithelial layer, VS: vacuous space, CC: club shaped cells.

MATERIALS AND METHODS

To study the impact of pollution on *Mystus gulio*, histopathological studies were done on more candidate tissues like gills and liver. *M. gulio* collected from Veli and samples were collected depending on rain, breaking of pozhi and the summer season. Only medium sized fishes were selected for the present study and juveniles are not considered.

Some tissues like gill and liver which have morphological changes based on compound microscopic observations are selected and fixed on neutral buffered formalin and histological fixatives like Bouin's fluid. The tissues were washed overnight in running water to remove the fixative. The gill tissues were decalcified by keeping in perenyis fluid for sufficiently long period. Tissue sections with 5 to 6 microns thickness were processed, washed, dehydrated and mounted in paraffin wax, then it was sectioned to 5 to 6 microns thickness using rotary microtome and again processed and stain and observed under the microscope.

RESULTS AND DISCUSSION

Gills are important in respiration as well as osmoregulation of the fish. Numerous delicate leaf-like structures, the lamellae, project from each gill filament, and these consists of minute capillaries covered by a single layer of thin epithelial cells. These epithelial cells form a barrier between the fish's blood and surrounding water through which the gaseous exchange takes place. The gross appearance of gills of fish collected from polluted environment resembles that of the normal fish. However, the gills exhibited some degenerative changes in the secondary lamellae. The epithelial layer of the secondary lamellae at several sites was lifted and detached from the underlying tissue and was found to establish a connection with the epithelial layer of the adjacent lamellae

(Figure 1).

The development of epithelial layer was found to extend towards the tip of the lamellae. The epithelial layer surrounding the blood spaces have detached from their basement membrane leaving many vacuous spaces (Figures 1 and 2). Hyperplasia was more pronounced towards the base of the filament which influenced the fusion of the adjacent filaments, thereby reducing the respiratory surface area of the gill. Above all, the secondary gill lamellae were clubbed with a large accumulation of blood cells at the distal end.

The liver of teleosts is relatively a large organ and has no direct contact with the pollutants dissolved in the water. The pollutants in water affect the liver through blood and it is reported that the liver is susceptible to a number of toxic and metabolic disturbances and it serve as an index to toxicity of polluted water (Kulshrestha and Jauhar, 1984; Hiraoka and Okuda, 1983).

The histopathological examination of the liver of the fish collected from sewage and industry effluent polluted water showed noticeable changes. The hepatocytes have lost their shape and regular arrangement (Figure 3). Due to the rupture of the cell wall, cytoplasm and nuclei were seen scattered in the liver tissue. Pycnotic nuclei due to the rupture of the cell membrane were seen scattered in the neighbouring tissue (Figure 4).

The cell membranes appeared in a state of dissolution and are not in crisp appearance. Hepatocytes were seen accumulated in the form of a syncytial mass with scattered nucleus (Figure 3). Enlargement of nuclei and condensation of nuclear material were clearly observed throughout the tissue. Brownish pigments were seen scattered in liver tissue (Figure 4) and in certain areas it

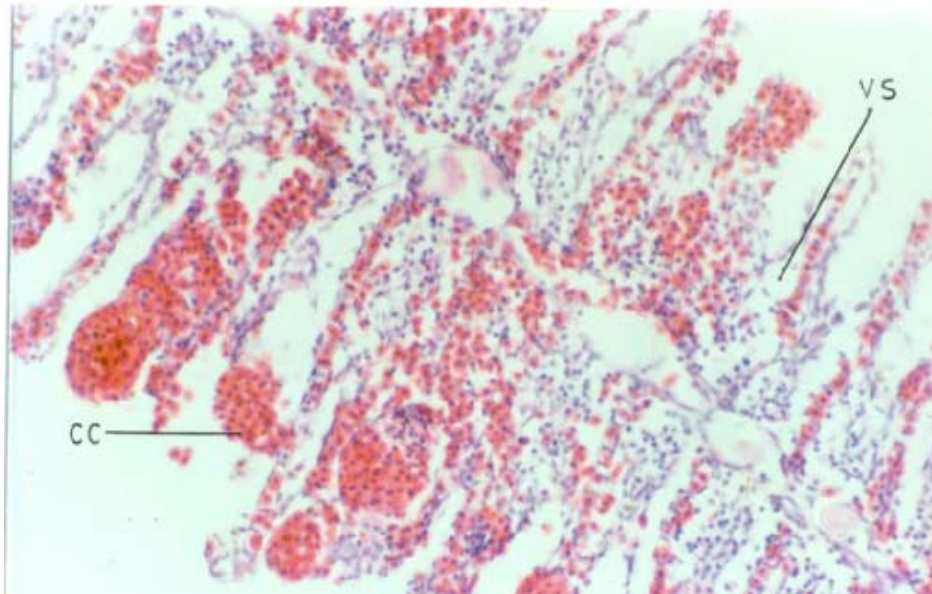


Figure 2. Epithelial layer surrounding the blood spaces showing detachment from basement membrane leaving many vacuous spaces
VS: Vacuous space, CC: club shaped cells.

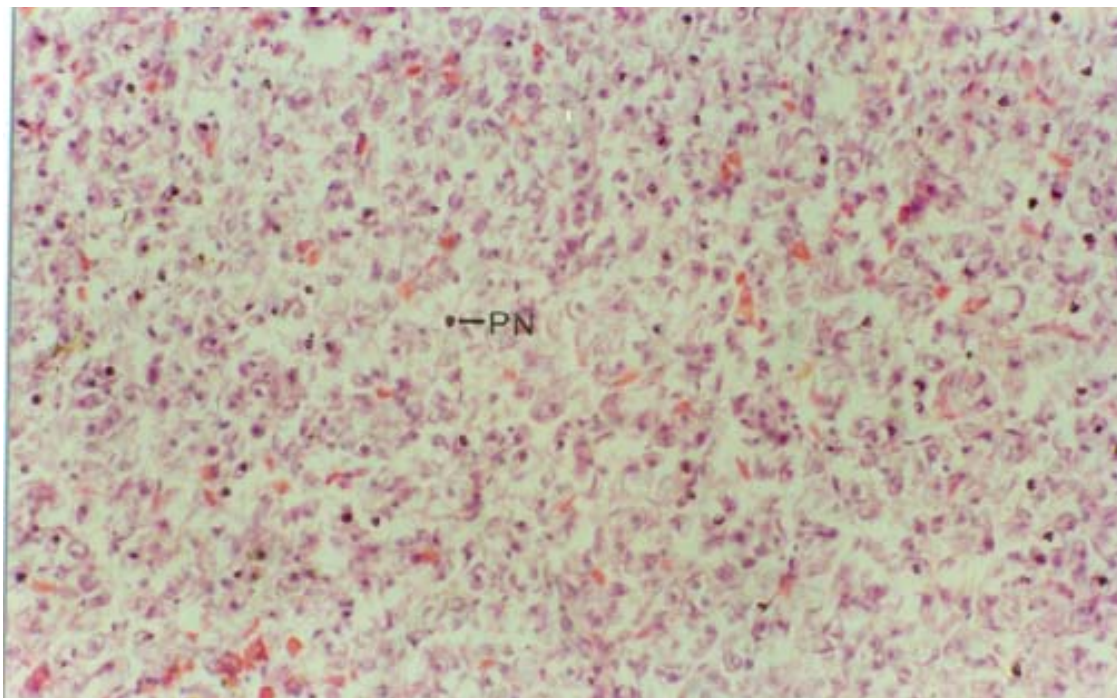


Figure 3. Hepatocytes accumulated in the form of a syncytial mass with scattered nucleus. Hepatocytes have lost their shape and regular arrangement.
PN: Pycnotic nuclei.

forms a mass of disintegrated cells invariably associated with a blood vessel (Figure 5).

The metacercarian larvae were found encysted in hepatic tissue (Figure 6). The cysts consist of two layers. The formation of inner membranous layer around the cyst

is covered by an outer fibrous layer secreted by the host. The degeneration of the host tissue was very obvious. A distinct coat had formed around the parasite cyst wall and the inflammatory reaction surrounding the cyst was very obvious. The capsule has a granular appearance. There

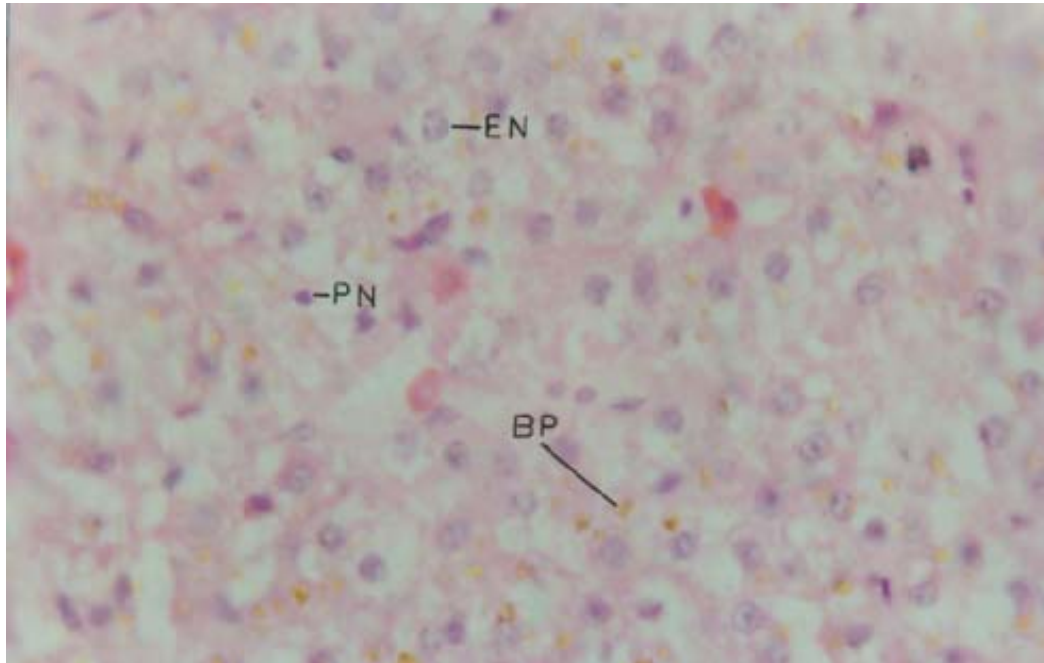


Figure 4. Clearly observed enlarged nuclei and condensed nuclear material. Brownish pigments were seen scattered in liver tissue.
 EN: Enlarged nuclei, PN: pycnotic nuclei, BP: brownish pigments.

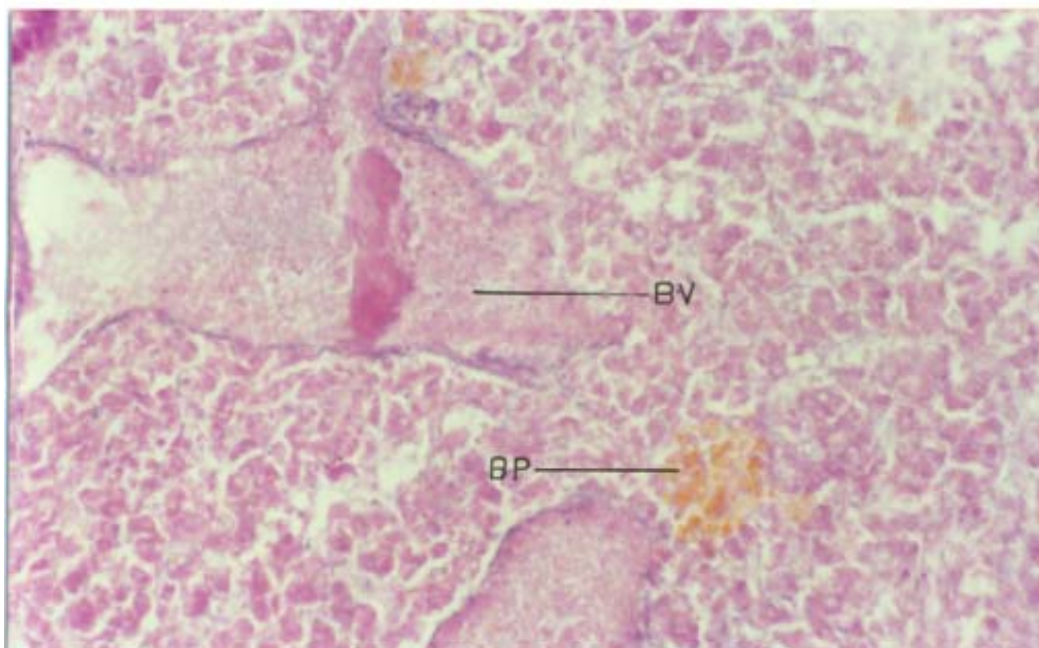


Figure 5. Clearly observed enlarged nuclei and condensed nuclear material showing certain areas where it forms a mass of disintegrated cells invariably associated with a blood vessel.
 BV: Blood vessels, BP: brownish pigments.

is a conspicuous accumulation of inflammatory cells around the cyst due to the elaboration of inflammatory process. Small number of melanocytes was found scattered

in the inflammatory cells (Figure 6).

As a reaction to the sewage pollution, the gills of *M. gultio* exhibited degenerative change such as lifting of the

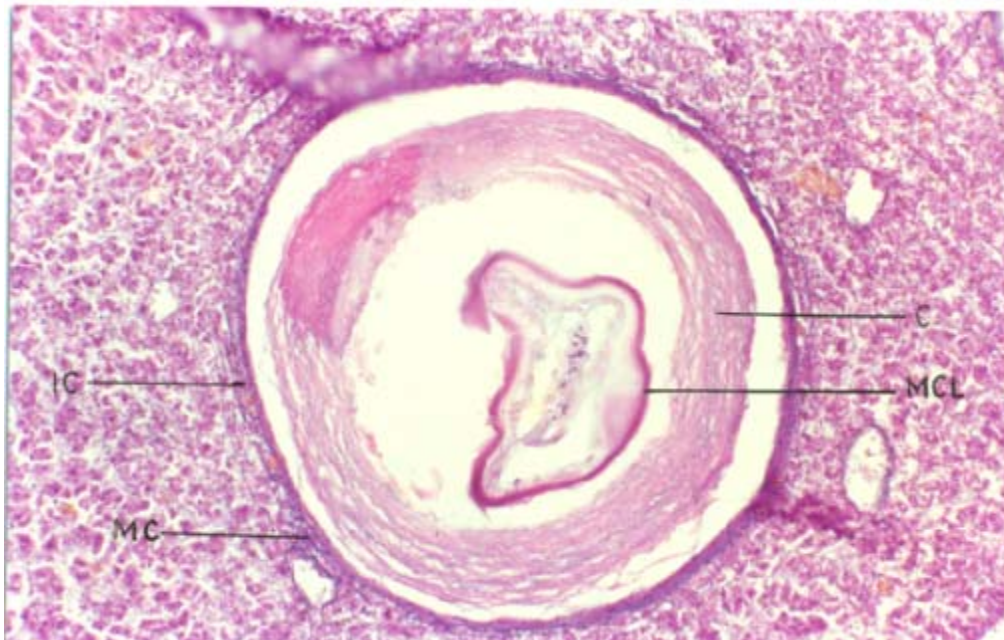


Figure 6. Metacercarian larvae encysted in hepatic tissue. The obvious inflammatory reaction shows a distinct coat formed around the parasite cyst wall. The capsule has a granular appearance. Small number of melanocytes were found to be scattered in the inflammatory cells.
TG: Tumor like outgrowth, MC: melanocytes, MCL: metacercarial larvae, C: cyst.

epithelial layer of secondary lamellae, its connection with that of the adjacent lamellae, the formation of vacuous space between the epithelial cells due to the formation of the hyperplasia growth. Similar degenerative changes owing to coal heavy distillate from industrial pollution, detergents, and influence of malathion was reported by Stoker et al. (1985), Eller (1975), Edwards and Overstreet (1976), Richmond and Dutta (1989), and Shrivastava and Shrivastava (1984). The appearance of club shaped cells packed with erythrocytes observed in the present study showed similarity with that of Stoker et al. (1985). It can be concluded that the observed degenerative reactions due to sewage pollution reduced the surface area of the filaments hindering respiration leading to suffocation which is deleterious to the host.

The changes observed in the liver tissue in the present study were degeneration of hepatocytes, pycnotic nuclei, syncytial mass of hepatocytes with scattered nuclei, engorgement of nucleus and condensation of nuclear material and the presence of brownish pigments. The brownish pigments present between the cells may be due to the accumulation of disintegrated cells. This may be an indication of the toxic materials present in the surrounding water which is absorbed by the liver through the blood, since liver has a function of detoxification.

In the present study, the encysted Metacercariae larvae appeared in the form of a nodule. This appearance of the larvae in the form of a capsule may be due to the granulomatous tissue derived from the inflammatory cells of the host tissue. A membranous tissue surrounding the

cyst and accumulation of fibroblasts in concentric layers around the larvae was noticed which was similar to that of Sommerville (1981). In the present observation, it was concluded that the membranous layer surrounding the parasite was secreted by the cyst and the fibroblast layer by the host tissue. Therefore, it can be concluded from the present study that the normal nature of the liver tissue was damaged and hence the normal functioning of the liver tissue is disrupted. This is due to the degeneration of the host tissue which is induced by the metacercarian cyst.

REFERENCES

- Edwards RH, Overstreet RM (1976). Mesenchymal tumors of some estuarine fishes of the Northern Gulf of Mexico I. Subcutaneous tumors, probably fibrosarcomas, in the striped mullet, *Mugil cephalus*. *Bull. Mar. Sci.* 26(1):33-40
- Eller LL (1975). Gill lesions in fresh water teleosts. In: Ribelin WE, Migaki G (Eds.), *The Pathology of Fishes*. The University of Wisconsin Press. pp. 305-330.
- Hiraoka Y, Okuda H (1983). Characteristics of Vertebral abnormalities of medaka as a water pollution indicator. *Hiroshima J. Med. Sci.* 32:261-266.
- Jayasree B, Subbiah A (2000). Mapping Fish research in India. *Curr. Sci.* 79(5):613-620.
- Kulshrestha SK, Jauhar L (1984). Effects of sublethal dose of thiodan and sevin on the liver of *Channa striatus*. Effects of sublethal dose of thiodan and sevin on liver of *Channa striatus*. In: Kulshrestha SK, Kumar V, Bhatnagar MC (eds.), *Effects of pesticides on aquatic fauna: Proceedings of the seminar held at Government Postgraduate College, Mhow, Technical papers*. pp. 71-78.
- Overstreet RM, Devender TV (1978). Implication of an environmentally

- induced Hamartoma in commercial shrimps. J. Inverte. Pathol. 31:234-238.
- Richmonds C, Dutta HM (1989). Histopathological changes induced by malathion in the gills of Bluegill *Lepomis macrochirus*. Bull. Environ. Contam. Toxicol. 43:123-130.
- Shrivastava J, Srivastava AK (1984). Histopathology of the gills of *Channa gachua* exposed to sublethal concentrations of malathion and chlordane. In: Kulshrestha SK, Kumar V, Bhatnagar MC (eds.), Effects of pesticides on aquatic fauna: Proceedings of the seminar held at Government Postgraduate College, Mhow, Technical papers. pp. 37- 44.
- Solangi MA, Overstreet RM (1982). Histopathological changes in two estuarine fishes, *Menidia beryllina* (Cope) and *Trinectes maculatus* (Block and Schneider), exposed to crude oil and its water – soluble fractions. J. Fish Dis. 5:13-35.
- Sommerville C (1981). A comparative study of the tissue response to invasion and encystment by *Stephanochasmus baccatus* (Nicoll 1907) (Digenia: Acanthocolpidae) in four species of flat fish. J. Fish Dis. 4:53-68.
- Stocker PW, Larsen JR, Booth GM, Lee ML (1985). Pathology of gill and liver tissues from two genera of fishes exposed to two coal – derived materials. J. Fish Biol. 27:31-46.