

Full Length Research Paper

Acute toxicity and histopathological assessment of methanol extract of *Cleome viscosa* (Linn.) whole plant.

Taiwo O. Elufioye* and Joel O. Onoja

Department of Pharmacognosy, Faculty of Pharmacy, University of Ibadan, Nigeria.

Received 3 February, 2015; Accepted 16 March, 2015

Cleome viscosa Linn (Cleomaceae) is a medicinal plant used widely in Nigeria for the management of various ailments. This research appraised the toxic potential of the plant with a view to validating or contesting its safety. Acute oral toxicity of the methanolic whole plant extract of *Cleome viscosa* was evaluated in mice using modified Lorke's method. Signs accompanying toxicity and possible death of animals were investigated for a period of two weeks to determine the median lethal dose (LD₅₀) of the extract. After two weeks observation period, all the animals in the respective dose groups 10, 100, 1000, 1600, 2900 and 5000 mg/kg were euthanized by cervical dislocation. The weight gained, absolute organ weight, and mean organ-body weight ratios (OBR) were determined and compared with values from those of the control group. The oral median lethal dose of the extract was found to be greater than 5000 mg/kg. There was a significant difference in weight gained on day 7 (P=0.052) among dose groups up to 1000 mg/Kg body weight. There was however, no significant difference in the relative organ weights between treated and control animals except for the Liver (p=0.048). Histopathological analysis showed mild congestion of the pulmonary vessels at dose 1600 mg/kg and above, mild diffuse vacuolar degeneration of hepatocytes across all tested dose as well as mild renal cortical congestion especially at high dose. The oral median lethal dose results indicate that the methanol extract of *Cleome viscosa* whole plant is non-toxic by oral administration at the tested doses.

Key words: *Cleome viscosa*, methanol extract, acute toxicity, histopathology

INTRODUCTION

For centuries and in most of the cultures throughout the world, herbal prescriptions and natural remedies are commonly employed for relief or treatment of diseases (Maqsood et al., 2010). Also in modern world, herbal medicines are becoming popular as people resort to natural therapies. Novel clinically active drugs are being isolated from higher plants. Regrettably, there are limited

scientific evidence as to the efficacy and safety to back up the continued therapeutic application of these medications. The justification for their use has rested largely on long term clinical knowledge (Zhu, 2002). Now, with the upsurge in the use of herbal medicines, a comprehensive scientific exploration of these plants will go a long way in substantiating their folkloric usage as

*Corresponding author. E-mail: toonitaiwo@yahoo.com; Tel: +234-8033850773.

Author(s) agree that this article remain permanently open access under the terms of the [Creative Commons Attribution License 4.0 International License](https://creativecommons.org/licenses/by/4.0/)

well as their prophylactic properties (Sofowora, 1993). One foremost and prevailing benchmark in the selection of herbal medicines for use in health services is safety. Plants extracts should not only be efficacious but safe for consumption.

Cleome viscosa Linn. (Cleomaceae) is a weed distributed throughout the tropical regions of the world and plains of India. The plant is an annual, sticky herb with a strong penetrating odour, yellow flower and long slender pods containing seeds. In Ayurvedic system of medicine, the plant is used for the treatment of fever, inflammations, liver diseases, bronchitis and diarrhea (Chatterjee et al., 1991). The rural people use the fresh juice of the crushed seed for the treatment of infantile convulsions and mental disorder. The juice of the plant diluted with water is given internally in small quantities in fever and the leaves are useful in healing wounds and ulcer (Nadkarni, 1982; Kirtikar et al., 1984).

The smoke from its leaves is used by the locals to repel mosquitoes at night. Its extract exhibited larvicidal activity against the second and fourth instar larvae of *Anopheles stephensi*, a vector of malaria in India (Saxena et al., 2000). *C. viscosa* is highly effective in a wide spectrum of diseases and reported to possess antidiarrhoeal (Devi et al., 2002), analgesic (Parimaladevi et al., 2003), antipyretic activity (Devi et al., 2003), psychopharmacological, anti-microbial properties including *in vitro Helicobacter pylori* and wound healing activity (Parimala et al., 2004a; Mahady et al., 2006; Panduraju et al., 2011), also against *Escherichia coli*, *Proteus vulgaris* and *Pseudomonas aeruginosa* (Sudhakar et al., 2006). In view of the reported effects of *C. viscosa*, the toxic potential of this plant was studied to generate information on its toxicity profile.

MATERIALS AND METHODS

Plant materials

The plant, *C. viscosa* Linn. was collected from Jeje area of Ibadan, Oyo State and authenticated at the Forestry Research Institute of Nigeria where voucher specimen was deposited under the reference number FHI 109669. The whole plant was dried at room temperature and powdered. About 2 kg of the powdered sample was soaked with 100% methanol for 48 h. The extract was concentrated using rotary evaporator and percentage yield was 5.12%. The dry extract was stored in a refrigerator at 4°C for further use.

Animals

The animals (ICR mice), both male and female, 6 to 7 weeks old (15 to 27g) used for these experiments were obtained from the Animal House, Department of Zoology, University of Ibadan. The mice were housed under standard conditions, fed with standard animal feed and given water *ad libitum* throughout the study period. They were allowed to acclimatize for seven days before the test was commenced. All experimental protocols were in compliance with University of Ibadan Ethics Committee Guidelines as well as

internationally accepted principles for laboratory animal use, and care as found in the US guidelines (NIH publication Number 85-23, revised in 1985).

Phytochemical screening

Preliminary phytochemical screening was carried out according to Harborne, 1998.

Acute toxicity study

Acute toxicity study was carried out according to modified Lorke's method (Lorke, 1983). The study was conducted in two phases using a total of sixteen animals. The mice were fasted overnight prior administration of plant extract. In the first phase, twelve animals were divided into 4 groups of 3 mice each. Groups 1, 2 and 3 animals were given single dose of 10, 100 and 1000 mg/kg of the extract orally, respectively, to establish the possible range of doses producing any toxic effect. Group 4, the control group received a mixture of distilled water and dimethyl sulfoxide (DMSO). In the second phase, the first three animals received 1600, 2900 and 5000 mg/kg separately, while the fourth (the control) received a mixture of distilled water and DMSO. All animals were observed frequently on the day of treatment and surviving animals were monitored daily for 2 weeks for signs of acute toxicity. Recovery and weight gain were seen as indications of having survived the acute toxicity. The weights of these organs were also taken and the mean organ-body weight ratios calculated and compared with those of the control group. Body weights of the mice were recorded on study days 0 (initiation), 7 and 14 (termination). At the end of 14 days, all surviving mice were euthanized by cervical dislocation. Five organs, heart, lungs, liver, kidney and spleen were isolated and subjected to complete gross necropsy and histopathological study. Histopathological assessment and photomicrography of prepared slides were done using an Olympus light microscope with attached Kodak digital camera. % Relative organ weight = Absolute organ weight (g)/Body weight of mice on sacrifice day x100. Figure 1 to 5.

Statistical analysis

The statistical analyses were carried out using Statistical Package for Social Sciences (SPSS-17 computer package) and ANOVA (one-way) followed by Duncan's Multiple Comparison Test. All data were expressed as mean \pm SD of triplicate parallel measurements. Differences between means at 5% level ($p \leq 0.05$) were considered significant.

RESULTS AND DISCUSSION

Despite the widespread use of medicinal plants, few scientific studies have been undertaken to ascertain the safety and efficacy of traditional remedies. To determine the safety of drugs and plant products for human use, toxicological evaluation is carried out in various experimental animals to predict toxicity and to provide guidelines for selecting a 'safe' dose in humans. The highest overall concordance of toxicity in animals with humans is with hematological, gastrointestinal, and cardiovascular adverse effects (Olson et al., 2000), while certain adverse effects in humans, especially

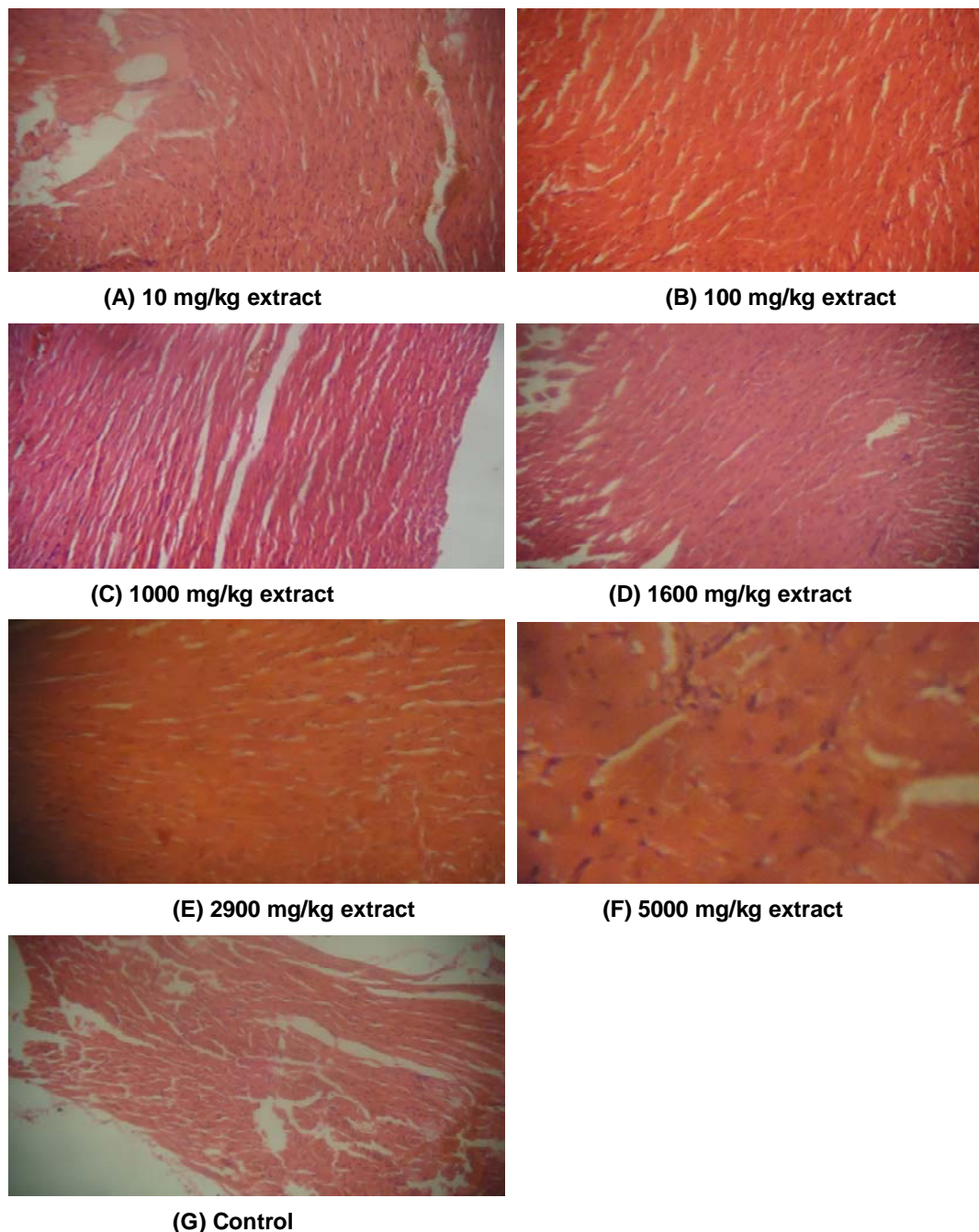


Figure 1. Histopathological assessment and photomicrography of the of the **heart** $\times 100$ in mice treated with 10 mg/kg, 100mg/kg, 1000mg/kg, 1600mg/kg, 2900mg/kg, 5000mg/kg of methanol extract of *C. viscosa* whole plant and control group.

hypersensitivity and idiosyncratic reactions, are poorly correlated with toxicity observed in animals. Furthermore, it is quite difficult to ascertain certain adverse effects in animals such as headache, abdominal pain, dizziness and visual disturbances. In addition, interspecies differences in the pharmacokinetic parameters make it difficult to translate some adverse effects from animals to

humans (Olson et al., 2000). The antipyretic, analgesic, and anti-inflammatory (Parimala et al., 2003a, b) as well as antimicrobial (Sudhakar et al., 2006), psychopharmacological effects (Parimala et al., 2004b) and immunomodulatory effects (Tiwari et al., 2004) of *C. viscosa* has been reported.

The biological/pharmacological activity, as well as

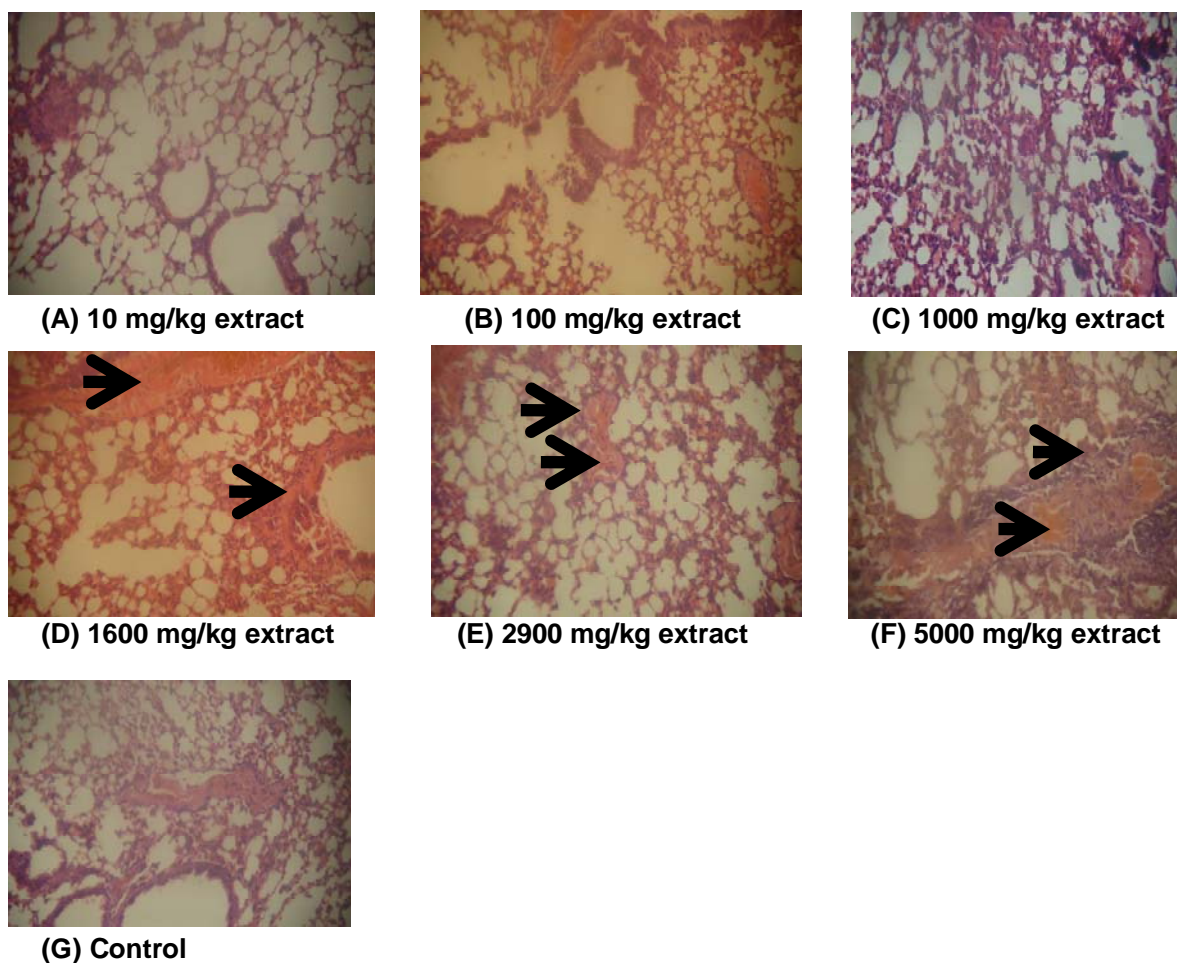


Figure 2. Histopathological assessment and photomicrography of the of the **lungs** $\times 100$ in mice treated with 10 mg/kg, 100mg/kg, 1000mg/kg, 1600mg/kg, 2900mg/kg, 5000mg/kg of methanol extract of *C. viscosa* whole plant and control group.

toxicity potential of a plant is directly related to the type, nature and quantity of secondary metabolites present in it. Thus, screening for the presence of possible phytochemicals in a plant is imperative. The results of preliminary phytochemical screening are given in Table 1. It shows the presence of flavonoids, phenolic compounds, alkaloids, phytosterol, fatty acid and saponins. Anthraquinone, tannin and coumarins were absent in the methanolic extract of *C. viscosa* L.

Flavonoids and other phenolics are ubiquitous in nature and can occur either in the free state or as glycosides. They constitute one of the most characteristic classes of compounds in higher plants and many are easily recognized as flower pigments in most flowering plants. However, their occurrence is not restricted to flowers but include all parts of the plant. They are widespread and have relatively low toxicity compared to other active plant compounds. Flavonoids have potential to be biological "response modifiers", such as anti-allergic, anti-inflammatory, anti-microbial and anti-cancer.

Phytosterols also have been implicated in lowering cholesterol (Pollak, 1953; Tilvis and Miettinen, 1986) and inhibiting lungs, breast, ovarian and stomach cancer (Woyengo et al., 2009). They also have long history of safety (Jones 2007). Medicinal use of alkaloid-containing plants has a long history (Hesse, 2002). The percentage of alkaloids in plants is usually small, and is not homogeneous over the plant tissues. Depending on the plants, the maximum concentration could be observed in the leaves fruits, seeds, root or bark (Grinkevich, 1983). Furthermore, different tissues of the same plants may contain different alkaloids (Orekhov, 1955). Consuming some secondary metabolites can have severe consequences. Alkaloids can block ion channels (Hamill and McBride, 1996), inhibit enzymes (Pastuszak et al., 1990), or interfere with neurotransmission producing hallucinations (Gaudreau and Gagnon, 2005), convulsion, vomiting and even death (Audi, 2005), diterpene gossypol blocks phosphorylation and is very toxic, spinasterol from spinach interferes animal hormone

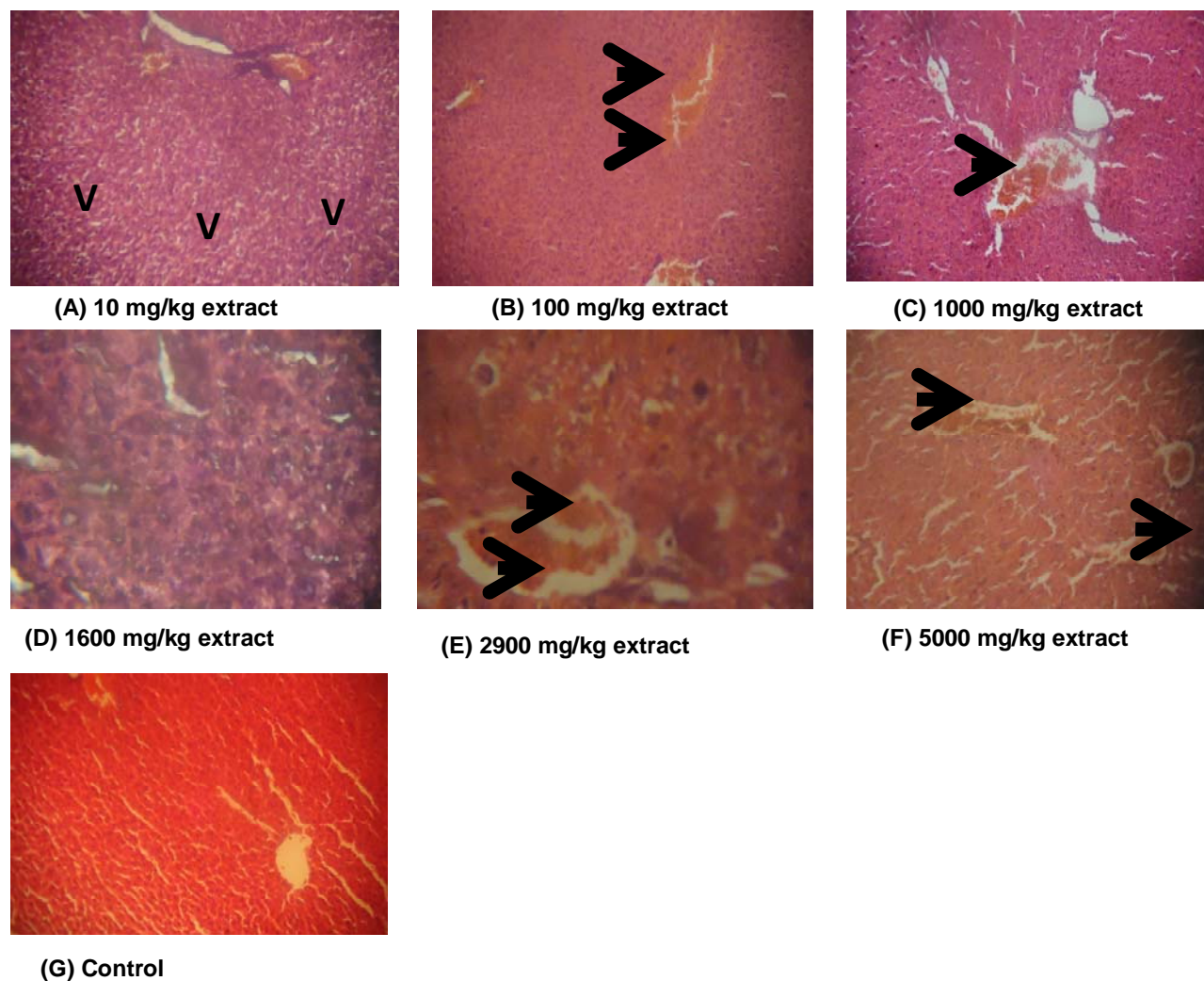


Figure 3. Histopathological assessment and photomicrography of the of the liver $\times 100$ in mice treated with 10 mg/kg, 100mg/kg, 1000mg/kg, 1600mg/kg, 2900mg/kg, 5000mg/kg of methanol extract of *C. viscosa* whole plant and control group. VD= vacuolar.

actions, gallotannins also binds to protein and block digestion (Hartmann, 2007). Plants containing cyanogenic glycosides can liberate cyanide which blocks cytochrome C-oxidase thus, becoming potentially poisonous (Venturi, 2011). Some phenolics can be carcinogenic while tannic acid has been shown to cause damage to intestinal walls (Glenn, 2005). Saponins are known to have deleterious haemolyzing effect on circulating erythrocytes (Sofowora, 1993).

The acute lethal study of *C. viscosa* on mice (Table 5) showed that no animal died within 24 h after oral administration of the extract, and the LD₅₀ was greater than 5000 mg/kg. The major signs of toxicity noticed within 24 h include ataxia, lethargy and asthenia. These signs were not seen in 10 mg/kg dose group but progressed and became increasingly pronounced as the dose increased towards 5000 mg/kg b.w. The LD₅₀, being greater than 5000 mg/kg b.w., is thought to be safe

as suggested by Lorke (Tijani et al., 1986; Deora et. al., 2010). Again, the absence of death among mice in all the dose groups throughout the two weeks of the experiment seems to support this claim. The LD₅₀ value of more than 5,000 mg/kg, showed that the extract is practically safe.

Also in the toxicity studies, mice in all experimental group gained weight over the course of this study (Table 2 to 5). There was a significant difference in body weight gained on day 7 ($p > 0.052$) among dose groups up to 1000 mg/Kg body weight. Mice in all experimental group gained weight over the course of this study especially those mice that took higher doses (Table 3). There was however no statistically significant differences ($p > 0.05$) noted in absolute organ weights between the *C. viscosa* extract treated and control groups. Also, there was no statistically significant difference in relative organ weights between treated and control animals except for the liver

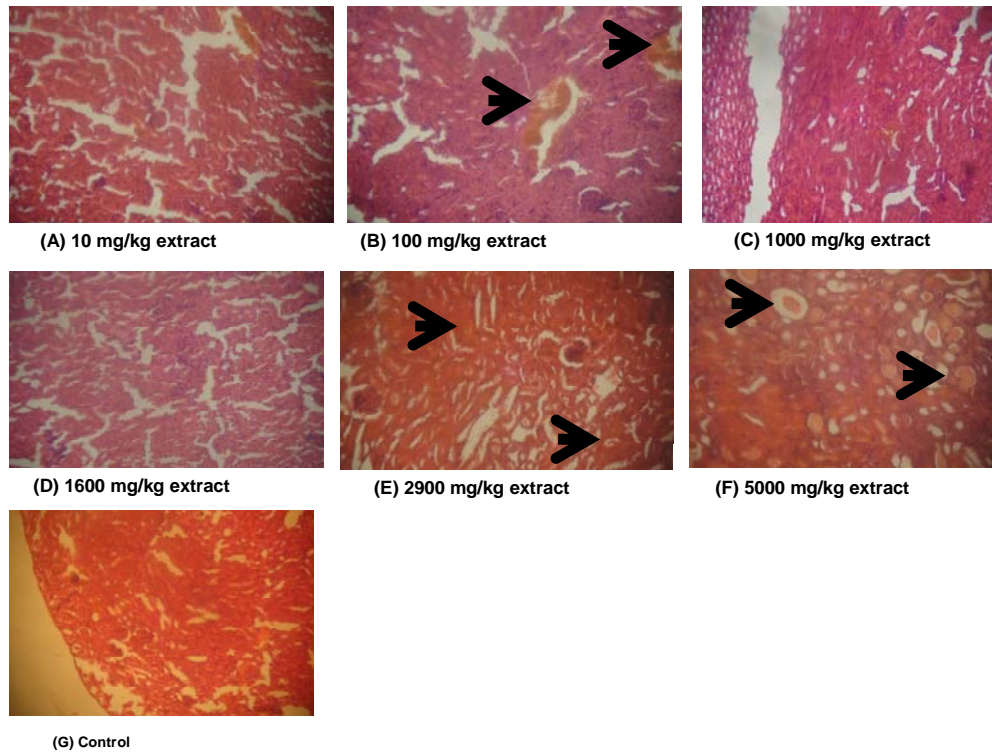


Figure 4. Histopathological assessment and photomicrography of the of the **kidney** $\times 100$ in mice treated with 10 mg/kg, 100mg/kg, 1000mg/kg, 1600mg/kg, 2900mg/kg, 5000mg/kg of methanol extract of *C. viscosa* whole plant and (G) control group.

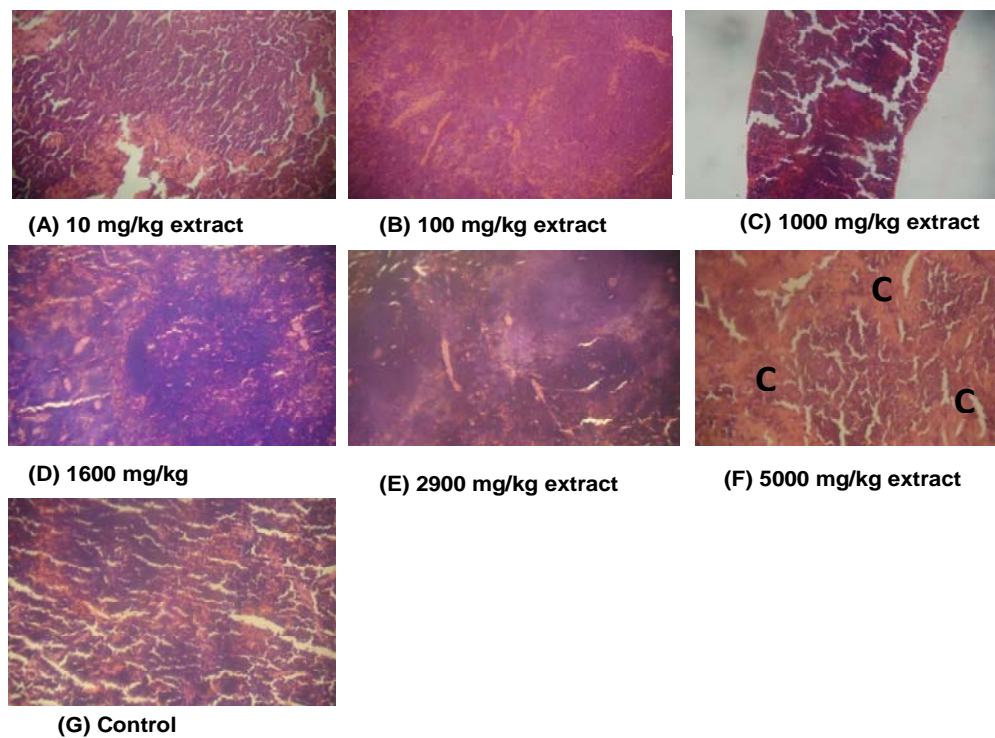


Figure 5. Histopathological assessment and photomicrography of the of the **spleen** $\times 100$ in mice treated with 10 mg/kg, 100mg/kg, 1000mg/kg, 1600mg/kg, 2900mg/kg, 5000mg/kg of methanol extract of *C. viscosa* whole plant and control group. C= congestion.

Table 1. Preliminary phytochemical screening of *Cleome viscosa* methanolic extract.

Chemical tests	<i>C. viscosa</i> methanolic extract
Detection of alkaloids	
Dragendorff's test	+
Hager's test	+
Detection of phenols	
Ferric chloride test	+
Detection of flavonoids	
Alkaline reagent test	+
Detection of anthroquinones	
Free anthroquinones test	-
Modified bortrager's test	-
Detection of phytosterols	
Salkowski's test	+
Detection of fatty acids	
	+
Detection of tannins	
Ferric chloride test	-
Detection of saponins	
Froth test	+
Coumarins	
	-

Keys: (+) = Present and (-) = Absent.

Table 2. Effect of oral administration of methanol extract of *C. viscosa* on the body weights of mice.

Experiment	Dose (mg/kg b.w.)	Initials (g) 0 days	Weight gain (g) After 7 days	Weight gain (g) 14 days
Phase 1	10	17.6667 ^a ±2.0816	18.0000 ^a ±1.0000	18.6667 ^a ±0.5773
	100	20.0000 ^a ±1.0000	22.0000 ^{ab} ±1.0000	22.0000 ^a ±0.0000
	1000	20.6667 ^a ±1.5275	23.6667 ^b ±1.1547	22.6667 ^a ±1.1547
Control	0	18.6667 ^a ±3.2145	19.3333 ^{ab} ±4.0414	19.6667 ^a ±4.5092
	1600	22.0000	23.0000	28.0000
Phase 2	2900	27.0000	25.0000	30.0000
	5000	20.0000	22.0000	28.0000

Test of significance was done in rows. Values are presented as mean ± standard deviation (n=3) in the same row with different superscripts differ significantly ($p < 0.05$) compared to the control group by one-way ANOVA followed by Duncan's Multiple Comparison Test. Weight values in phase-2 (were $n < 3$) were not compared due to absence of measure of variability.

except for the Liver ($p=0.048$). Liver weight relative to body weights increased in a dose dependent manner in all group with the test extract (Table 4) with the highest liver weights at dose 2900 mg/kg body weight. However, the magnitudes of the

alterations were small and were not considered treatment-related. Mild diffuse vacuolar degeneration of hepatocytes and moderate portal congestion of the liver appears to be the major gross pathology accompanying treatment of mice with methanolic

Table 3. Effect of oral administration of methanol extract of *C. viscosa* on absolute organ weight.

Organ	10 mg/kg	100 mg/kg	1000 mg/kg	1600 mg/kg	2900 mg/kg	5000 mg/kg	Control
Heart	0.1200 ^a ±0.0435	0.1200 ^a ±0.0100	0.1333 ^a ±0.0288	0.12	0.19	0.23	0.1000 ^a ±0.0360
Lungs	0.1767 ^a ±0.0152	0.1533 ^a ±0.0305	0.1667 ^a ±0.0251	0.16	0.21	0.22	0.1500 ^a ±0.0519
Liver	0.8833 ^a ±0.0230	1.0300 ^a ±0.0173	0.8933 ^a ±0.2396	1.63	1.77	1.41	1.0633 ^a ±0.3412
Kidney	0.1400 ^{ab} ±0.0200	0.1667 ^b ±0.0057	0.1667 ^b ±0.0057	0.16	0.27	0.21	0.1300 ^a ±0.0264
Spleen	0.0833 ^a ±0.0115	0.1233 ^a ±0.0321	0.0933 ^a ±0.0152	0.27	0.16	0.09	0.1233 ^a ±0.0611

Test of significance was done in rows. Values are presented as mean ± standard deviation(n=3) in the same row with different superscripts differ significantly (p < 0.05) compared to the control group by one-way ANOVA followed by Duncan's Multiple Comparism Test. Dose groups with single mice per group (n<3) were not compared due to absence of measure of variability.

Table 4. Effect of oral administration of methanol extract of *C. viscosa* on organ-body weight.

Organ	10 mg/kg	100 mg/kg	1000 mg/kg	1600 mg/kg	2900 mg/kg	5000 mg/kg	Control
Heart	0.6481 ^a ±0.2579	0.5454 ^a ±0.0454	0.5939 ^a ±0.1531	0.4285	0.6333	0.8214	0.4999 ^a ±0.0726
Lungs	0.9483 ^a ±0.1067	0.6969 ^a ±0.1388	0.7360 ^a ±0.1161	0.5714	0.7000	0.7857	0.7833 ^a ±0.2753
Liver	4.7338 ^{ab} ±0.1359	4.6817 ^{ab} ±0.0786	3.9128 ^a ±0.8335	5.8214	5.9000	5.0357	5.3333 ^b ±0.5166
Kidney	0.7523 ^a ±0.1293	0.7575 ^a ±0.0262	0.7360 ^a ±0.0331	0.5714	0.9166	0.7500	0.6708 ^a ±0.0273
Spleen	0.4453 ^a ±0.0489	0.5605 ^a ±0.1460	0.4141 ^a ±0.0834	0.9642	0.5333	0.3214	0.6027 ^a ±0.1687

Test of significance was done in rows. Values are presented as mean ± standard deviation(n=3) in the same row with different superscripts differ significantly (p < 0.05) compared to the control group by one-way ANOVA followed by Duncan's Multiple Comparism Test. Dose groups with single mice per group (n<3) were not compared due to absence of measure of variability.

Table 5. Acute lethal effect of methanol extract of *Cleome viscosa* administered orally mice.

Experiment	Dose (mg/kg b.w.)	Mortality of mice after 24hrs of administration	Mortality at 14 days observation
Phase 1*	10	0/3	0/3
	100	0/3	0/3
	1000	0/3	0/3
Control	0	0/3	0/3
Phase 2	1600	0/1	0/1
	2900	0/1	0/1
	5000	0/1	0/1
Control	0	0/1	0/1

(*Experiment was conducted in two phases; each dose group of phase-1 made up of 3 mice while those in phase 2 have 1 mice per group).

Table 6. Post mortem result for acute toxicity of methanol extract of *C. viscosa* administered orally to mice.

Organ	10 mg/kg	100 mg/kg	1000 mg/kg	1600 mg/kg	2900 mg/kg	5000 mg/kg	Control
Heart	None	None	None	None	None	None	None
Lungs	None	None	None	Mild congestion of pulmonary vessels	Mild congestion of pulmonary vessels	Mild congestion of pulmonary vessels	None
Liver	Mild diffuse vacuolar degeneration of hepatocytes	Moderate portal and central venous congestion	Mild portal congestion	Moderate central venous congestion	Mild diffuse vacuolar degeneration of hepatocytes	Moderate portal and central venous congestion	None
Kidney	None	Renal cortical congestion	None	None	Few tubules have protein casts in their lumen	Renal tubules have copious amount of proteinaceous material in the lumen	None
Spleen	None	None	None	None	None	Congestion	None

with methanolic extract of *C. viscosa* (Table 6). Again, liver congestion could be attributed in part to its role in biotransformation of xenobiotics or to a slight clog of liver which is a function of lipid metabolism at that dose apart from vascular changes which could be attributed to the treatment.

The findings of this study indicate that the methanolic whole plant extract of *C. viscosa* may be considered safe for consumption since no animal died within 24 h after oral administration of the extract and the LD₅₀ was greater than 5000 mg/kg.

CONCLUSION

The methanol extract of *Cleome viscosa* whole plant appears non-toxic by oral administration at the tested doses as indicated by the high oral median lethal dose.

Conflicts of Interest

The authors declare that they have no conflicts of interest.

REFERENCES

- Audi J, Belson M, Patel M, Schier J, Osterloh J (2005). Ricin poisoning: a comprehensive review. *JAMA* 294(18):2342-2351.
- Chatterjee A, Prakash SC (1991). *The Treatise on Indian Medicinal Plants*, 2nd Eds., Vol. I. New Delhi, Council for Scientific and Industrial Research. P 155.
- Deora PS, Mishra CK, Mavani P, Asha R, Shrivastava B, Rajesh KN (2010). Effective alternative methods of LD₅₀ help save numbers of experimental animals. *J. Chem. Pharm. Res.* 2(6):450-453.
- Devi BP, Boominathan R, Mandal SC (2002). Evaluation of anti-diarrheal activity of *Cleome viscosa* L. extract in rats. *Phytomedicine* 9(8):739-742.
- Devi BP, Boominathan R, Mandal SC (2003). Evaluation of antipyretic potential of *Cleome viscosa* Linn. (Capparidaceae) extract in rats. *J. Ethnopharmacol.* 87(1):11-13.

- Gaudreau JD, Gagnon P (2005). Psychogenic drugs and delirium pathogenesis: the central role of the thalamus. *Med. Hypotheses* 64(3):471-475.
- Glenn I (2005). The role of plant secondary metabolites in mammalian herbivory: ecological perspective. *Proc. Nutr. Soc.* 64:123-131.
- Grinkevich NI, Safronich LN (1983). The chemical analysis of medicinal plants. *Proceedings Allowance Pharmaceutical Universities*. pp. 122-123.
- Hamill OP, McBride DW (1996). The pharmacology of mechanogated membrane ion channels. *Pharmacol. Rev.* 48(2):231-252.
- Harborne JB (1998). *A Guide to modern techniques of plant Analysis*. USA: Kluwer Academic Publisher.
- Hartmann T (2007). From waste products to ecochemicals: fifty years research of plant secondary metabolism. *Phytochemistry* 68:22-24.
- Hesse M (2002). *Alkaloids: Nature's Curse or Blessing?* Wiley VCH. P 303.
- Jones PJ (2007). Ingestion of phytosterols is not potentially hazardous. *J. Nutr.* 137(11):2485.
- Kirtikar KR, Basu BD (1984). *Indian Medicinal plants*, Lalit Mohan Basu Publication, Dehra Dun, 2nd Edn, vol. 1. pp. 181-185.
- Lorke D (1983). A new approach to practical acute toxicity

- testing. Arch. Toxicol. 53:275-287.
- Mahady GB, Bhamarapravati S, Adeniyi BA, Penland SL, Doyle B, Locklear T, Solver C (2006). Traditional Thai Medicines inhibit *Helicobacter pylori* in-vitro and in-vivo: support for ethnomedical use. Ethnobot. Res. Appl. 4:159-165.
- Maqsood S, Singh P, Samoon MH, Balange AK (2010). Effect of dietary chitosan on non-specific immune response and growth of *Cyprinus carpio* challenged with *Aeromonas hydrophila*. Inter Aqua Res. 2:77-85.
- Nadkarni AK (1982). Indian Materia Medica. Popular Prakashan Bombay. 1:351-352, 498.
- Olson H, Betton G, Robinson D, Thomas K, Monro A, Kolaja G, Lilly P, Sanders Sipes G, Bracken W, Dorato M, Deun KV, Smith P, Berger B, Heller A (2000). Concordance of toxicity of pharmaceuticals in humans and in animals. Regul. Toxicol. Pharmacol. 32:56-67.
- Orehkov AP (1955). Chemistry of alkaloids (Acad. 2 ed.). M.: USSR. P 12
- Panduraju T, Parvathi B, Rammohan M, Srinivas RC (2011). Wound healing properties of *Cleome viscosa* Linn. Hygeia J. Drugs Med. 3:41-45.
- Parimala B, Boominathan R, Mandal SC (2003a). Evaluation of anti-inflammatory activity of *Cleome viscosa*. Indian J. Nat. Prod. 19:8-12.
- Parimala DB, Boominathan R, Mandal SC (2003b). Studies on analgesic activity of *Cleome viscosa* in mice. Fitoterapia 74(3):262-266.
- Parimala DB, Boominathan R, Mandal SC (2004a). Studies on psychopharmacological effects of *Cleome viscosa* Linn. extract in rats and mice. Phytother. Res. 18:169-172.
- Parimala DB, Boominathan R, Mandal SC (2004b). Studies on psychopharmacological effects of *Cleome viscosa* Linn. extract in rats and mice. Phytother. Res. 18:169-172.
- Parimaladevi B, Boominathan R, Mandal SC (2003). Studies on analgesic activity of *Cleome viscosa* in mice. Fitoterapia 74(3):262-266.
- Pastuszak I, Molyneux RJ, James LF, Elbein AD (1990). Lentiginosine, a dihydroxyindolizidine alkaloid that inhibits amyloglucosidase. Biochemistry 29(7):1886-1891.
- Pollak OJ (1953). Reduction of blood cholesterol in man. Circulation 7(5):702-6.
- Saxena BR, Koli MC, Saxena RC (2000). Preliminary ethnomedical and phytochemical study of *Cleome viscosa*. Ethnobotany 12:47-50.
- Sofowora AE (1993). Medicinal plants and traditional medicine in Africa. Spectrum Books Limited, Ibadan, Nigeria. pp. 150-156.
- Sudhakar M, Rao CV, Rao PM, Raju DB (2006). Evaluation of antimicrobial activity of *Cleome viscosa* and *Gmelina asiatica*. Fitoterapia 77(1):47-49.
- Tijani A, Pomtantz A, Khawar R, Fusi M (1986). Community acquired infections in children on maintenance cyclosporine therapy. Int. J. Pediatr. Nephrol. 7:141-144.
- Tilvis RS, Miettinen TA (1986). Serum plant sterols and their relation to cholesterol absorption. Am. J. Clin. Nutr. 43(1):92-7.
- Tiwari U, Rastogi B, Thakur S, Jain S, Jain NK (2004). Studies on the immunomodulatory effects of *Cleome viscosa*. Indian J. Pharm. Sci. 66:171-176.
- United Nations (2005). Globally Harmonized System of Classification and Labelling of Chemicals (GHS), 1st ed.; United Nations: Geneva, Switzerland.
- Venturi S (2011). Evolutionary significance of iodine. Curr. Chem. Biol. 5(3):155-162.
- Woyengo TA, Ramprasath VR, Jones PJH (2009). Anticancer effects of phytosterols. Eur. J. Clin. Nutr. 63(7):813-20.
- Zhu M, Lew KT, Leung P (2002). Protective Effects of Plant formula on Ethanol-induced Gastric Lesions in Rats. Phytother. Res. 16:276-280.