



CHIRURGIE THORACIQUE / THORACIC SURGERY

CHEST SURGICAL APPROACHES IN AFRICA: A CONSTANT CHALLENGE

MENEAS GC, ABRO S, YANGNI-ANGATE KH.

Department of Cardiovascular and Thoracic Diseases,
Anatomy Unit, Bouake Teaching Hospital, Cote d'Ivoire

Correspondence: Koffi Herve Yangni-Angate

Cardiothoracic and Vascular Surgery Department and Anatomy Unit, Bouake Teaching Hospital, Cote d'Ivoire.
Email: Cardiovascthodiseasesdept@gmail.com

Summary

Objective: Thoracic surgical approach has taken a decisive turn since videoscropy utilization for cardiac and non-cardiac thoracic surgery. This study aims to present indications and results of chest surgical approaches performed in Cote d'Ivoire. **Methods:** Using the 1998 and 2014 nationwide inpatient database, we identified retrospectively 814 patients including 475 men and 339 women who underwent a cardiothoracic surgery. Mean age was 32.73 years; range was: 2 months - 88 years. **Results:** Cardiac Surgery was performed on 473 patients (58.10%) and General Thoracic Surgery on 341 patients (41.89%). For Cardiac Surgery, median vertical sternotomy was the most surgical approach performed (n=250; 52.85%), while classic postero-lateral thoracotomy was the most surgical approach performed in General Thoracic Surgery (n=321; 94.13%). Immediate postoperative pain required opioids administration in 84.39% of cases. Average length of hospitalization and healing were respectively 9.43 days (range: 2-50 days) and 18.30 days (range: 1-56 days). **Conclusion:** Development of minimally invasive chest approaches remains one of our challenges because those currently practiced are uncomfortable for patients and make longer hospital stay and wound healing.

Keywords: Surgical Approach, Thorax, Minimally Invasive Procedures.

Introduction

For about two decades, thoracic surgical approach has taken a decisive turn with videoscapy introduction in cardiac and non-cardiac thoracic surgery. This thriving technique becomes gradually a reference technique in thoracic surgical approach and is a minimally invasive approach to the thorax with minimal post-operative pain, reduction of the duration of hospitalization and a post anaesthetic procedures. However, this thoracic approach requires a specific technical and ancillary material that limits diffusion in developing countries. Chest surgical approaches are surgical accesses to the chest and its content. Two major groups of chest approaches are described: conventional or classic and minimally invasive" surgical approaches ⁽¹⁾. The conventional surgical approaches are anterior approaches ⁽²⁾ such as the vertical median sternotomy, the Chamberlain anterior mediastinotomy, the anterolateral thoracotomy, the partial Sternotomy with anterolateral thoracotomy "Hemiclamshell", the bilateral transverse Sterno-thoracotomy "clamshell"; the side approaches ⁽³⁾ such as the lateral thoracotomy, and posterolateral approaches ⁽³⁾. "Minimally invasive" ⁽¹⁾ chest approach tracts involve direct thoracoscopy, video-assisted thoracoscopic surgery, video-assisted thoracic surgery, video-assisted in conventional surgery, minimally invasive cardiac surgery assisted by video-assisted thoracoscopic surgery, approaches tracts for diagnostic biopsies (the "traditional" mediastinoscopy; video mediastinoscopy) and robotics ⁽⁴⁾. This study aims to report indications of chest surgical approach tracts performed in Cote d'Ivoire and post-operative results.

Methods

Using the 1998 and 2014 nationwide inpatient database, we identified retrospectively, 814 patients including 475 men and 339 women who underwent a cardiothoracic surgery. Mean age was 32.73 years; range was: 2 months - 88 years. Postoperative pain was treated according to two

different protocols depending on the ladder of the WHO analgesic activity scale [5] Protocol 1 begins with the WHO analgesic ladder III (ladder 3) i.e. intravenously injected morphine by syringe pump at a dose of 0.3 mg.kg-1.d-1 from D0-D3 postoperative then nefopam by slow intravenous injection at a dose of 20 mg x 4. D-1 associated with paracetamol intravenously at a dose of 1g x 4.d-1 from post-operative D4-D6; then an oral treatment with paracetamol associated with codeine (500/30mg) at a dose of 1capsule x 3.d-1 or by tramadol 50 mg at a dose of 1 capsule x 2/day, from D6 to discharge. Protocol 2 begins with the WHO analgesic ladder II (ladder 2) i.e. neoplasm by slow intravenous injection at a dose of 20 mg x 4. D-1 associated with intravenously injected paracetamol at a dose of 1g x 4.d-1 from postoperative D0-D4; then an oral treatment with paracetamol associated with codeine (500/30 mg) at a dose of x 1capsule 3.d-1 or 50 mg of tramadol at a dosage of 1 capsule 2 x/d, from D4 to the exit. No epidural analgesia or intercostal nerve block was used. Chest tubes were set in continuous aspiration to -25 mmHg except in case of pneumonectomy. Chest surgical approaches performed, their indications, post-operative results regarding intensity of post-operative pain assessed by analgesic protocol used, length of stay, time of healing and the appearance of the postoperative scar had been studied.

Results

Eight hundred and fourteen (814) chest surgical approaches were performed (Fig.1), including 422 (51.84%) classic posterolateral thoracotomies, 265 (32.55%) vertical median sternotomies, 120 (14.74%) xiphoid incisions for pericardial drainage by Marfan retro-xiphoid approach and 7 (0.85%) other thoracic surgical approaches. These chest approaches were used either for Cardiac Surgery (n = 473; 58.10%) or for non-cardiac chest surgery (n = 341; 41.89%). In Cardiac Surgery, 250 (52.85%) vertical median sternotomies, 101 (21.35%) posterolateral thoracotomies, 120 (25.36%) xiphoid incisions and 2 (0.42%) video-aided thoracoscopic surgery were performed (Fig.2).

The vertical median sternotomy was indicated for surgical correction of 87 (18.39%) valve diseases, 121 (25.58%) congenital heart disease, and other 42 (8.87%) acquired heart diseases. All pericardial drainages (N = 120; 25.36%) were performed by a classic xiphoid incision according to MARFAN retro-xiphoid approach. The classic postero-lateral thoracotomy was prescribed for the correction of 98 (20.71%) congenital heart disease and 3 (0.63%) surgical explorations for post-operative bleeding. Video-assisted thoracoscopy was prescribed 2 times (0.42%) for ductus arteriosus closure by clips. In non-cardiac thoracic surgery, 321 (94.13%) posterolateral thoracotomies, 15 (4.39%) vertical median sternotomies (1.46%) and 5 (1.46%) other surgical approaches were done (Fig.2). The postero-lateral thoracotomy technique was prescribed for the surgical treatment of 121 (35.48%) pleural diseases, 133 (39.00%) diseases, 19 (5.57%) mediastinal disorders, 34 (9.97%) parietal diseases, and 14 (4.10%) other non-cardiac chest diseases. Conventional vertical median sternotomy was prescribed for the surgical treatment of 7 (2.05%) and mediastinal disorders and 8 (2.34%) parietal conditions. The previous Chamberlain mediastinotomy (n = 2; 0.58%), and mediastinoscopy (n = 3; 0.87%) were prescribed to carry out mediastinal tumor biopsies. The intensity of postoperative pain after the vertical median sternotomy and posterolateral thoracotomy (n = 687; 84.39%) was sharp and required the administration of morphine by injection (WHO analgesic ladder 3), while minimally invasive approaches such as Chamberlain anterior mediastinotomy, mediastinoscopy and video-assisted thoracoscopy were less painful and required the administration of tramadol by injection (analgesic WHO ladder 2) (Table I) . The hospital stay was 5.25 days (4-7 days) for vertical median sternotomy, 13.68 days (3-31 days) for posterolateral thoracotomy, 9.37 days (4-14 days) xiphoid incisions and 3.5 days (2-4 days) for minimally invasive approaches such as Chamberlain anterior mediastinotomy, mediastinoscopy and video-assisted thoracoscopy (Table I).

The hospital varied depending on the type of surgical procedure performed (Table II and III). Healing time was 22.25 days (17-30 days) for vertical median sternotomies, 27.69 days (13-60 days) for posterolateral thoracotomies, 17.5 days (10-20 days) for xiphoid incisions with a highly visible and unsightly scar while it was 7.5 days (6-10 days) for minimally invasive approaches such as Chamberlain anterior mediastinotomy, mediastinoscopy and video-assisted thoracoscopy with a less visible and anaesthetic scar.

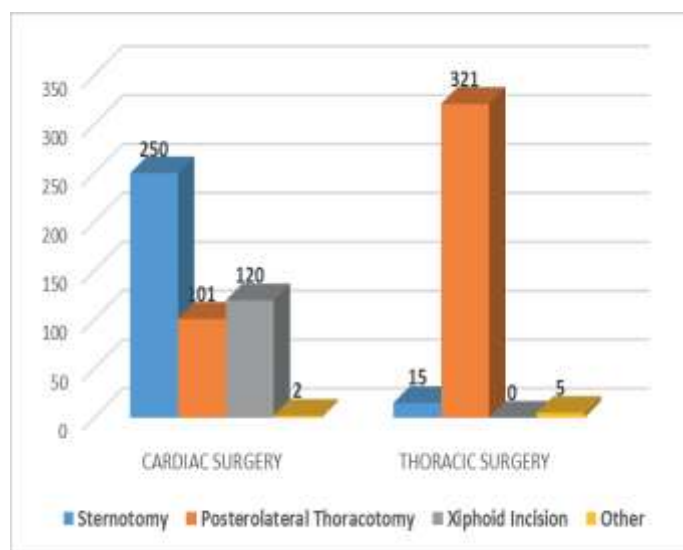
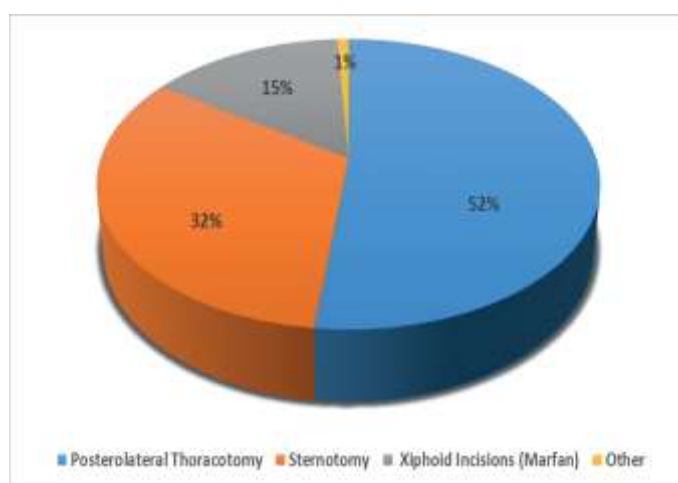


Table I: Postoperative results according to chest approach

Approaches	Postoperative pain treatment	Hospital stay length : days Average (extreme)	Postoperative disorders (%)	Cicatrization duration (days)
Vertical median sternotomy N=265	Morphine (48h) + tramadol +/- nefopam (5 days)	5.25 (4-7)	0	22.25 (17-30)
Posterolateral thoracotomy N=422	Morphine (48h) + tramadol +/- nefopam (5 days)	13.68 (3-31)	6.3	27.69 (13-60)
Xiphoid incision N=120	Tramadol +/- nefopam (4-5 days)	9.37 (4-14)	1.3	17.5 (10-20)
Others (videothoracoscopy, mediastinoscopy, chamberlain mediastinotomy) n=7	Tramadol +/- nefopam (48h)	3.5 (2-4)	0	7.5 (6-10)

Table II: Postoperative results according to procedure in Cardiac Surgery

Procedures	Hospital stay length : days Average (extreme)	Postoperative pain treatment	Postoperative disorders (%)	Cicatrization duration (days)
STERNOTOMY				
Valvular surgery	9 (8-10)			
Pericardiectomy	10.5 (8-13)			
ASD/VSD repair	8.5 (3-13)			
Cure of AVSD	6.5 (6-7)	Morphine (48H) + Tramadol +/- Nefopam (5 Days)	0	13, 50 (7-20)
Tetralogy of Fallot repair	8.35 (5-21)			
pulmonary stenosis repair	11 (8-14)			
POSTEROLATERAL THORACOTOMY				
Open PDA closure	5.73 (4-9)			
Modified Blalock Operation	5.6 (5-6)	Morphine (48H) + Tramadol +/- Nefopam (5 Days)	0	10.5 (8-14)
Aorta coarctation repair	7			
INCISION XIPHOIDIENNE				
Pericardial drainage	9.37 (4-14)	Tramadol +/- Nefopam (4-5 Days)	1.3	17.5 (10-20)
OTHER (VIDEO-THORACOSCOPY)				
PDA closure by VIDEO	3.5 (3-4)	Tramadol +/- Nefopam (4-5 Days)	0	8 (7-10)

Table III: Postoperative results according to non-chest cardiac procedures

indications	Hospital stay length : days Average (extreme)	Postoperative pain treatment	Postoperative disorders (%)	Cicatrization duration (days)
POSTEROLATERAL THORACOTOMY				
Empyemectomy / pleurectomy	10.04 (5-31)			
Mechanic and chemical pleurodesis	9.57 (4-15)			
Pneumonectomy/Lobectomy	11.5 (6-30)			
Bullectomy	7			
Bronchotomy	6.6 (6-8)	Morphine (48H) + Tramadol +/- Nefopam (5 days)	6.3	27.69 (13-60)
Tumoral biopsy	3.5 (3-5)			
Tumorectomy	7.66 (7-8)			
Diaphragmatic repair	8.5 (4-17)			
Exploratory Thoracotomy for Post traumatic hemothorax	7.66 (3-14)			
STERNOTOMY				
Tumorectomy	7.66 (7-8)	Morphine (48H) + Tramadol +/- Nefopam (5 days)	0	13.50 (7-20)
OTHERS Mediastinoscopy/ Mediastinotomy				
Mediastinal Tumor biopsy	2	Tramadol +/- Nefopam (24 H)	0	7 (6-10)

Discussion

Cardiac and non-cardiac thoracic surgery in Cote d'Ivoire is carried out mainly through traditional surgical approaches. Minimally invasive thoracic surgical approaches are almost non-existent. This situation is contrary to that of the developed countries where the minimally invasive thoracic surgery and minimally invasive cardiac surgery are growing for over 15 years [6]. According to Jougon and colleagues [2], previous chest surgical approaches are the preferred approaches for mediastinal surgery, cardiac surgery, and pulmonary and cardiopulmonary transplan-tations while the posterolateral thoracotomy has always been considered as the preferred approach for lung surgery. For cardiac surgery, we have addressed all valvular diseases acquired by vertical median sternotomy to carry out a valve replacement or a valvular plasty. Our practice was different from Obadia J-F's [7; 8] in France in 2006 and 2010. He has used video-assisted thoracoscopy to carry out valve replacement, even complex valvular plasties, and tumor resections. As for American authors like Alexander Iribane [9; 10]; they extend the prescriptions for minimally invasive cardiothoracic surgery to repairs or replacements of the aortic valve, to the repair or replacement of the mitral valve, and to aortocoronary bypass. According to literature [8; 10; 11; 12], the minimally invasive mitral valve surgery is the most performed practice of the minimally invasive cardiothoracic surgery. Regarding congenital heart diseases, they were addressed either through a sternotomy or through a conventional posterolateral thoracotomy, except 2 (0.42%) cases of arterial channels that were addressed by video-assisted thoracoscopy which is below the current trend whereby some congenital heart diseases such as inter-atrial and inter-ventricular communications are operated from a minimally invasive thoracic approach (8; 9; 13; 14; 15). Unlike Hui-Ping Liu (16) in 1994 in China, who proposed a pericardial surgical drainage by video-assisted thoracoscopy in particular for patients with pleural and pericardial effusion, we have realized all pericardial surgical drainages by Marfan retro-xiphoid approach. Regarding the non-cardiac thoracic surgery, the minimally invasive approach is almost nonexistent in our practice because of

the lack of suitable equipment and training of the surgical team while according to several authors (17-41) the minimally invasive thoracic surgery remains the technique choice to surgically treat almost all pleural, pulmonary and mediastinal diseases. However, according to Joshua Neto et al (42) in 2014 in Brazil and Thomas Kirby [30] in 1995 in the USA, regardless of the type of surgery, the minimally invasive approaches are used in two forms. In one hand, in a direct form or by mini-thoracotomies or by the technique by muscular savings and in other hand, in an indirect form with the video-assisted performed safely. Intensity and duration of post-operative pains are less important in chest minimally invasive approach versus conventional thoracic approach. So, Santambrogio (37) in 1995 in Italy, administered 106 mg of ketorolac versus 143 mg, Ayed (38) in 2000 in Kuwait, used Demerol 75 mg (45-150) versus 150 mg (40-300) and Abdala [35] in 2001 in Spain administered painkillers for 38 hours versus 77 hours. As for Kuhlman (43) in 1999 in France, asserted that given the various backgrounds of pain after thoracic surgery, it is rare that a single technique, even the most sophisticated, brings about a total control of painful manifestations and namely shoulder pains. Also, regardless of the choice of a postoperative local analgesia technique, the association with a parenteral supplement administered on demand should be prescribed systematically. According to V Joshi (44) in England in 2013, Video-Assisted Thoracic Surgery reduces length of hospital stay.

Brevity of hospital stay for minimally invasive thoracic approach versus conventional chest approach was also dealt with by other authors namely Santambrogio (37) in 1995 in Italy, Ayed (38) in 2000 in Kuwait, Abdala (35) in 2001, in Spain. They respectively found it for pulmonary segmentectomy, an average length of 4.6 versus 7.8 days; 3 versus 5 days; 5.3 versus 7.5 days. Other authors like Ayed (31) in 2000 in Kuwait, Waller [33] in 1994 in England and Gebhard (34) in 1996 in Germany, reported hospital stay length as follows in order: 6.5 versus 10.7 days, 4 versus 5 days and 5 versus 7 days for the surgical treatment of pneumothorax (with talc)

by video-assisted Thoracic surgery versus thoracotomy. S for Thomas Kirby [30] in 1995 in the USA, it is 7.1 versus 8.3 days for pulmonary lobectomy by video-assisted thoracic surgery versus thoracotomy. In cardiac surgery, the same observations were made by authors like Lin PJ ⁽⁴⁵⁾ in 1997 and Murat Basaran ⁽⁴⁶⁾ in 2008 found respectively hospital stays of 5.1 days versus 8 days and 5.4 days versus 7.2 days for surgical closure of an Inter-Ear Communication by Anterolateral Mini-thoracotomy versus conventional vertical median sternotomy. As for Sung-Ho Jung ⁽⁴⁷⁾, in 2009, he mentioned a 3.6-day hospital stay versus 6.1 days for surgical closure of an Inter-Ventricular Communication by Antero-lateral thoracotomy versus conventional vertical median mini-sternotomy. Other authors ^(48, 49, 50) were also unanimous on the fact that minimally invasive approaches decreased post-operative complications, reduced the duration of chest tube and the length of stay in hospital while success of the surgical procedure is comparable to traditional surgical approaches.

Considering these results in literature, the average hospital stay is 9.43 days (range 2-50 days) in our practice remains excessive. The hospital stay in our study was comparable to the length of hospital stay found by other authors for conventional chest approaches while it was too long compared to the minimally invasive approaches with the same authors. Regarding the rate of wound infections to abscesses type of the wound found in 7.6% of cases, our results were comparable to those of Grossi [51] in 1999 who reports an incidence of 5.7% for conventional sternotomy versus 0.9% for the mini-thoracotomy. The cost of minimally invasive approaches remains questionable. Actually according to Swanson SJ ⁽⁵²⁾ in the USA, hospital costs of conventional thoracotomy for lobectomy (\$ 21,016) are higher than those of Video-assisted Thoracic Surgery (\$ 20,316) for the same intervention ($p = 0.027$). These results tally with the findings of Casali ⁽⁵³⁾ in 2009, in England, who indicated that the overall cost of Video-assisted Thoracic Surgery for a lobectomy was lower (8023 € ± 565) compared to the cost of a lobectomy (8178 € ± 167) ($P = 0.0002$)

by conventional thoracotomy; and that, due to the reduction in the duration of the patient's postoperative stay in intensive care for Video-assisted Thoracic surgery. The author concludes that the video-assisted Thoracic Surgery for a lobectomy is cheaper than lobectomy by conventional approach; and the increased costs of surgical procedure due to consumables is offset by a shorter hospital stay. Rodriguez E ⁽⁵⁴⁾ drew the same conclusion in September 2014, in the USA. He found out that the aortic valve replacement by right anterior minimally invasive approach is less expensive than that achieved by conventional median sternotomy (\$ 38,769 versus \$ 42,656; $p < 0.01$). In our developing countries, this practice of minimally invasive chest approach is possible as it has already been carried out in South Africa ⁽⁵⁵⁾, Turkey [56] and Brazil ⁽⁵⁷⁾, but unlike Western countries, in developing countries like ours, the video-assisted Thoracic Surgery is more expensive than the conventional thoracotomy approach because of consumables cost ^(56, 58). Thus, the practice of these minimally invasive approaches in our developing countries will require a good strategy for patient selection ^(58, 59). However, to start this minimally invasive thoracic approach in our developing countries, the Brazilian model of Cardiac Surgery could be encouraged because it provides direct minimally invasive thoracic without video-assistance and gives satisfactory results ⁽⁵⁷⁾. In non-Thoracic Cardiac Surgery, the thoracotomy with Muscular Saving ⁽³⁰⁾ could be recommended because it gives encouraging results. Moreover, as argued by Frank Edwin ⁽⁶⁰⁾, in 2011, in Ghana; the development of Cardio-Thoracic Surgery seems closely parallel to the country's economic development and patients' ability to honor the cost of this surgery. In our developing countries, health insurance seems to be an essential condition for the Cardio-Thoracic Surgery and Minimally invasive Cardio-Thoracic Surgery development. According to Joshi V ⁽⁴⁴⁾ in England in 2013, the Video-Assisted Thoracic Surgery has a similar recurrence rate with that of the conventional thoracotomy; it reduces the risk of intra-operative bleeding.

Conclusion

The development of minimally invasive approaches for thoracic and cardiovascular surgery remains a challenge in Cote d'Ivoire. Thoracic approaches being currently used in Cote d'Ivoire are uncomfortable, extend hospitalization and healing time, leave unsightly scars and sometimes turn excessive. Therefore, we need to convert our classical option to a minimally invasive approaches which remains a challenge for us.

Conflicts of interest: The authors did not report any conflict of interest in connection with the writing of this scientific article.

References

- 1- Azorin J-F, Vidal R, Martinod E, de Kerangal X, Dahan M. Voies d'abord mini-invasives du thorax. EMC (Elsevier SAS, Paris), Techniques chirurgicales – Thorax, 42-220, 2006.
- 2- Jougon J, Delcambre F, Velly J-F. Voies d'abord chirurgicales antérieures du thorax. EMC (Elsevier Masson SAS, Paris), Techniques Chirurgicales – Thorax, 42-210, 2004.
- 3- Brichon P-Y. Thoracotomies latérales et postéro-latérales. EMC (Elsevier Masson SAS, Paris), Techniques chirurgicales – Thorax, 42-205, 2009.
- 4- Le Pimpec-Barthes F. Les grands principes de la Chirurgie Thoracique consulté le 05/04/2016 sur le site internet : http://despneumo.org/s/IMG/pdf/Principes_chir_Thorax_F_Barthes_DES_Mai_2009.pdf.
- 5- Ventafridda V, Tamburini M, Caraceni A, De Conno F, Naldi F. A validation study of the WHO method for cancer pain relief. *Cancer*. 1987;59:850-6.
- 6- Okada S, Sugawara H, Tanaba Y, Ishimori S, Yamauchi T, Satoh S. Thoracoscopic major lung resection using a newly developed instrument retraction system and a voice-controlled robot. *Kyobu Geka* 2000;53:862-5.
- 7- Obadia J-F. Chirurgie cardiaque mini-invasive assistée par vidéothoroscopie: où en sommes-nous? *mt cardio*. 2006;2:1-5.
- 8- Obadia J-F. Chirurgie cardiaque mini-invasive assistée par vidéothoroscopie. EMC (Elsevier Masson SAS, Paris), Techniques chirurgicales - Thorax, 42-519, 2010.
- 9- Iribarne A, Karpenko A, Russo M J, Cheema F, Umann T, Oz MC, et al. Eight-Year Experience with Minimally Invasive Cardiothoracic Surgery. *World J Surg*. 2010 34:611–615.
- 10- Iribarne A, Easterwood R, Chan E Y, Yang J, Soni L, Russo MJ et al. The golden age of minimally invasive cardiothoracic surgery: current and future perspectives. *Future Cardiol*. 2011; 7:333-46.
- 11- Lucà F, Van Garsse L, Rao CM, Parise O, La Meir M, Puntrello C, et al. Minimally Invasive Mitral Valve Surgery: A Systematic Review. *Minim Invasive Surg*. 2013, Article ID 179569, 10 pages.
- 12- Ritwick B, Chaudhuri K, Crouch G, Edwards JR, Worthington M, Stuklis RG. Minimally Invasive Mitral Valve Procedures: The Current State. *Minim Invasive Surg*. 2013, Article ID 679276, 8 pages.
- 13- Baharestani B, Rezaei S, Jalili SF, Omrani G, Heidarali M. Experiences in Surgical Closure of Atrial Septal Defect with Anterior Mini-Thoracotomy Approach. *J Cardiovasc Thorac Res*. 2014; 6,181-4.
- 14- Gaetano P, Raffaele G, Veronica R, Sabato C, Sergio P, Marco M, et al. Anterolateral Minithoracotomies for the Radical Correction of Congenital Heart Defects. *Tex Heart Inst J*. 2009; 36:575–9.
- 15- Kim JE, Jung SH, Kim GS, Kim JB, Choo SJ, Chung CH, et al. Surgical Outcomes of Congenital Atrial Septal Defect Using da Vinci™ Surgical Robot System. *Korean J Thorac Cardiovasc Surg*. 2013;46:93-7.
- 16- Liu HP, Chang CH, Lin PJ, Hsieh HC, Chang JP, Hsieh MJ. Thoracoscopic management of effusive pericardial disease: Indications and technique. *Ann Thorac Surg*. 1994; 58:1695–7.
- 17- Giudicelli R, Thomas P, Lonjon T, Ragni J, Bulgare JC, Ottomani R, et al. Major pulmonary resection by video assisted mini-thoracotomy. Initial experience in 35 patients. *Eur J Cardiothorac Surg*. 1994; 8:254-8.
- 18- Roviario G, Varoli F, Rebuffat C, Vergani C, D'Hoore A, Scalambra SM, et al. Major pulmonary resections: pneumonectomies and lobectomies. *Ann Thorac Surg*. 1993;56:779-83.

- 19- Walker WS, Craig SR. Video-assisted thoracoscopic pulmonary surgery--current status and potential evolution. *Eur J Cardiothorac Surg.* 1996;10:161-7.
- 20- P. Bonnette. Vidéo-chirurgie thoracique et médiastinoscopie à visée diagnostique. Technique et indications. Encyclopédie Médico-Chirurgicale (EMC) (Elsevier Masson SAS, Paris), Techniques chirurgicales – Pneumologie. 2008; 6-000-P-43.
- 21- Ashton RC Jr, Connery CP, Swistel DG, DeRose JJ Jr. Robot-assisted lobectomy. *J Thorac Cardiovasc Surg.* 2003;126:292-3.
- 22- Fortunato JA, Pereira ML, Martins AL, Pereira de S, Paz ME, Paludo L, et al. Video-assisted cardiac surgery: 6 years of experience. *Rev Bras Cir Cardiovasc.* 2012; 27:24-37.
- 23- Luh SP, Liu HP. Video-assisted thoracic surgery—the past, present status and the future. *J Zhejiang Univ Science B.* 2006 7: 118-28.
- 24- Sedrakyan A, van der Meulen J, Lewsey J, Treasure T. Video assisted thoracic surgery for treatment of pneumothorax and lung resections: systematic review of randomised clinical trials. *BMJ.* 2004;329: 1008.
- 25- Michael J Mack, Ronald J Aronoff, Tea E Acuff, Mark B Douthit, Richard T Bowman, and William H. Ryan. Present Role of Thoracoscopy in the Diagnosis and Treatment of Diseases of the Chest *Ann Thorac Surg.* 1992;54:403-9.
- 26- Begum S, Hansen HJ, Papagianopoulos K. VATS anatomic lung resections-the European experience. *J Thorac Dis.* 2014;6:S203-10.
- 27- Scarcia M, Zahidb I, Billéa A, Routledge T. Is video-assisted thoracoscopic surgery the best treatment for paediatric pleural empyema? *Interactive CardioVascular and Thoracic Surgery.* 2011;13:70-6.
- 28- Chen QK, Chen C, Chen XF, Jiang GN. Video-Assisted Thoracic Surgery for Pulmonary Aspergilloma: A Safe and Effective Procedure. *Ann Thorac Surg.* 2014;97:218–23.
- 29- Cohen G, Hjortdal V, Ricci M, Jaffe A, Wallis C, Dinwiddie R et al. Primary thoracoscopic treatment of empyema in children. *J Thorac Cardiovasc Surg.* 2003;125:79-84.
- 30- Kirby TJ, Mack MJ, Landreneau RJ, Rice TW. Lobectomy-video-assisted thoracic surgery versus muscle-sparing thoracotomy. A randomized trial. *Thorac Cardiovasc Surg.* 1995;109:997-1002.
- 31- Ayed AK, Al-Din HJ. Video-assisted thoracoscopy versus thoracotomy for primary spontaneous pneumothorax: a randomized controlled trial. *Med Principles Pract.* 2000; 9:113-8.
- 32- Sekine Y, Miyata Y, Yamada K, Yamada H, Yasukawa T, Saitoh Y, et al. Video-assisted thoracoscopic surgery does not deteriorate postoperative pulmonary gas exchange in spontaneous pneumothorax patients. *Eur J Cardiothorac Surg.* 1999; 16:48-53
- 33- Waller DA., Forty J., Morrill GN. Video-assisted thoracoscopic surgery versus thoracotomy for spontaneous pneumothorax. *Ann Thorac Surg.* 1994;58:372-7.
- 34- Gebhard FT., Becker HP., Gerngross H., Bruckner UB. Reduced inflammatory response in minimal invasive surgery of pneumothorax. *Arch Surg.* 1996;13:1079-82.
- 35- Abdala OA., Levy RR., Bibiloni RH., Viso HD, De Souza M, Satler VH. Advantages of video assisted thoracic surgery in the treatment of spontaneous pneumothorax. *Medicina (B Aires).* 2001; 61:157-60.
- 36- Tschopp JM., Boutin C., Astoul P., Janssen JP., Grandin S., Bolliger CT., et al. Talcage by medical thoracoscopy for primary spontaneous pneumothorax is more cost-effective than drainage: a randomised study. *Eur Respir.* 2002;20: 1003-9. .
- 37- Santambrogio L., Nosotti M., Bellaviti N., Mezzetti M. Videothoracoscopy versus thoracotomy for the diagnosis of the indeterminate solitary pulmonary nodule. *Ann Thorac Surg.* 1995;59:868-71.

- 38- Ayed AK., Raghunathan R. Thoracoscopy versus open lung biopsy in the diagnosis of interstitial lung disease: a randomised controlled trial. *R Coll Surg Edinb.* 2000;45:159-63.
- 39- Miller JD., Urschel JD., Cox G., Olak J., Young JE., Kay JM., et al. A randomized, controlled trial comparing thoracoscopy and limited thoracotomy for lung biopsy in interstitial lung disease. *Ann Thorac Surg.* 2000;70:1647-50.
- 40- Sugi K., Kaneda Y., Esato K. Video-assisted thoracoscopic lobectomy achieves a satisfactory longterm prognosis in patients with clinical stage 1A lung cancer. *World Surg.* 2000;24:27-31.
- 41- Craig SR, Leaver HA, Yap PL, Pugh GC, Walker WS. Acute phase responses following minimal access and conventional thoracic surgery. *Eur Cardiothorac Surg.* 2001;20: 455-63
- 42- Castro Neto JV, Melo EC, Silva JF, Rebouças LL, Correa LC, Germano Ade Q et al . Minimally Invasive Procedures – Direct and Video-Assisted Forms in the Treatment of Heart Diseases. *Arq Bras Cardiol.* 2014; 102:219-25.
- 43- KUHLMAN G. Analyse sémiologique de la douleur postopératoire en chirurgie thoracique. Évaluation et traitement de la douleur. Elsevier, Paris et SFAR. 1999;23-9.
- 44- Joshi V, Kirmani B, Zacharias J. Thoracotomy versus vats: is there an optimal approach to treating pneumothorax? *Ann R Coll Surg Engl.* 2013; 95: 61–4.
- 45- Lin PJ, Chang CH, Chu JJ, Liu HP, Tsai FC, Chung YY, et al. Surgical closure of Atrial Septal Defect minimally invasive cardiac surgery or Median Sternotomy? *Surg Endosc.* 1997;12:820–24.
- 46- Murat B, Ali K, Cihan O, Alper U, Eylul K, Melih U. Comparison of 3 Different Incisions Used for Atrial-Septal Defect Closure. *Heart Surg Forum.* 2008;11:290–4.
- 47- Jung SH, Je HG, Choo SJ, Yun TJ, Chung CH, Lee JW. Right or left Antero-lateral Minithoracotomy for repair of congenital Ventricular Septal Defects in adult patients. *Interact Cardiovasc Thorac Surg.* 2010, 10: 22–6.
- 48- Villamizar NR, Darrabie MD, Burfeind WR, Petersen RP, Onaitis MW, Toloza E, et al. Thoracoscopic lobectomy is associated with lower morbidity compared with thoracotomy. *J Thorac Cardiovasc Surg.* 2009; 138: 419-25.
- 49- Hunaid A Vohra, Louise Adamson, David F. Weeden. Does video-assisted thoracoscopic pleurectomy result in better outcomes than open pleurectomy for primary spontaneous pneumothorax? *Interact*
- 50- Paul S, Altorki NK, Sheng S, Lee PC, Harpole DH, Onaitis MW, et al Thoracoscopic lobectomy is associated with lower morbidity than open lobectomy: A propensity-matched analysis from the STS database. *J Thorac Cardiovasc Surg.* 2010; 139:366-78.
- 51- Grossi E A, Galloway A C, Ribakove G H, et al. Minimally invasive port access surgery reduces operative morbidity for valve replacement in the elderly. *The Heart Surgery Forum* 1999;2:212–5.
- 52- Swanson SJ, Meyers BF, Gunnarsson CL, et al. Videoassisted thoracoscopic lobectomy is less costly and morbid than open lobectomy: a retrospective multiinstitutional-database analysis. *Ann Thorac Surg.* 2012; 93:1027-32.
- 53- Casali G, Walker WS. Video-assisted thoracic surgery lobectomy: can we afford it? *Eur J Cardiothorac Surg.* 2009;35:423-8.
- 54- Rodriguez E, Malaisrie SC, Mehall JR, Moore M, Salemi A, Ailawadi G, et al. Right anterior thoracotomy aortic valve replacement is associated with less cost than sternotomy-based approaches: a multiinstitutional analysis of 'real world' data. *J Med Econ.* 2014;19:1-7.

- 55- Navsaria PH, Nicol AJ. Video-assisted thoracoscopic pericardial window for penetrating cardiac trauma. *S Afr J Surg.* 2006; 44:18-20.
- 56- Alpay L, Lacin T, Teker D, Okur E, Bay-sungur V, Kanbur S, et al. Comparative cost analysis study of lobectomy performed via video-assisted thoracic surgery versus thoracotomy in Turkey. *Wideochir Inne Tech Malo Inwazyjne.* 2014;9:409-14.
- 57- Da Silveira WL, Bosco FA, Leite AF, Peixoto FA, de Sousa M, de Souza CC. Correction of Simple Congenital Heart Defects in Children and Adolescents Through Mini-thoracotomies. *Arq Bras Cardiol.* 2007; 88:358-62.
- 58- P Van Schil. Cost analysis of video-assisted thoracic surgery versus thoracotomy: critical review. *Eur Respir J.* 2003;22:735–8.
- 59- Yim AP. Cost-containing strategies in video-assisted thoracoscopic surgery. An Asian perspective. *Surg Endosc.* 1996;10 :1198-2000.
- 60- Edwin F, Tettey M, Aniteye E, Tamatey M, Sereboe L, Entsua-Mensah K, et al. The development of cardiac surgery in West Africa - the case of Ghana. *Pan Afr Med J.* 2011; 9-15.