

Full Length Research Paper

Histological effects of chronic administration of *Phyllanthus amarus* on the superior colliculus of adult wistar rats

Josiah Obagwharhievwo Adjene

Department of Anatomy, School of Basic Medical Sciences, University of Benin, Edo State, Nigeria.
E-mail: joadjene@yahoo.com. Tel: +2348034084016, +2348053478526.

Accepted 14 May, 2010

Effects of administration of *Phyllanthus amarus* commonly used for the treatment of jaundice, diarrhea, dysentery, urogenital disease and wound on the superior colliculus of adult wistar rats was carefully studied. Rats of both sexes (n = 24), with average weight of 200 g were randomly assigned into two treatments (A and B) and control (C) groups of 8 rats each. The rats in the treatment groups (A and B) received 400 and 800 mg of aqueous extract of *P. amarus* per kg body weight respectively through the orogastric tube administration daily for thirty days. The control group received equal volume of distilled water daily for thirty days through the same route. The rats were fed with growers marsh obtained from Edo Feeds and Flour mill Limited, Ewu, Edo State, Nigeria and given water liberally. The rats were sacrificed by cervical dislocation on the thirty-one days of the experiment. The superior colliculus was carefully dissected out and quickly fixed in 10% formal saline for histological study. The findings indicate that rats in the treated groups (A and B) showed some cellular degenerative changes, hypertrophy, sparse cellular population and vacuolations in the stroma of the superior colliculus as compared to the control group. Chronic administration of *P. amarus* may therefore have an adverse effect on the visual and somatosensory motor sensibilities by affecting the microanatomy of the superior colliculus of adult wistar rats. It is recommended for further studies aimed at corroborating these observations.

Key words: Histological effects, *Phyllanthus amarus*, superior colliculus, wistar rats.

INTRODUCTION

Most of the population of the underdeveloped and developing countries depends on some form of traditional and herbal medicines since ancient times. One of the plants that are widely used traditionally for the treatment of many diseases in many countries is the *Phyllanthus amarus* (Calixto et al., 1998; Muhamad and Mustafa, 1994). *P. amarus* has bitter, astringent, cooling, diuretic, stomachic, antiseptic, antiviral, antidiabetic, hypotensive, antinociceptive and febrifuge properties and is traditionally used in the treatment of jaundice, diarrhea, dysentery, diabetes, fevers, urogenital diseases, ulcers and wounds (Santos et al., 1995; Calixto et al., 1998).

Herbal medicines are widely perceived by the public as being natural, healthful and free from side effects. Plants contain hundreds of constituents and some of them may elicit toxic side effects. Toxic effect of some herbal medicines has been reported (Shaw et al., 1997; Kaplowitz,

1997; Calixto, 2000).

The superior colliculus is concerned with ocular movement. Such movements can result from stimulation of a wide area in the pretectal and tegmental regions of the brain. The superior colliculus controls regulates many movements of the eye and head. It acts as an integrative center subserving visual perception. Thus, it also has a role in certain aspects of vision. Its major role is to coordinate responses evoked by a variety of sensory signals with behavioural movements that directs the head, eyes and ear towards environmental stimulus. Thus, the superior colliculus has a critical role in visual localization, orientation tracking movements, accommodation and papillary reflex. Its superficial layers are concerned with vision (Reczkoski and Diamond, 1978) and its deep layer has been implicated in eye movements and somesthetic input (Altman and Bayer, 1981). It has

been observed in monkey that the neurons in the superior colliculus are involved in a somatosensory motor feedback loop that monitors the force of the active muscles together with the spatial position of the limb that is required for proper interaction with an object (Nagy et al., 2006). Multisensory depression is a fundamental index of multisensory integration in the neurons of the superior colliculus. Nitregic interneurons play a role in refining the cortico-collicular projection patterns that are believed to be essential for superior colliculus output neurons. It is engage in multisensory integration and to support normal orientation responses to cross modal stimuli (Stein et al., 2009). The loss of these cortical influences permits visual orientation behaviour in the presence of a normal disruptive auditory stimulus (Jiang and Stein, 2003).

The superior colliculus neurons play some spatial-temporal filter properties that are closely similar to those of their retina as well as those of their inputs from the cortical visual motion detector areas, suggesting their common role in motion analysis and related behavioral actions (Waleszczyk et al., 2007). Cortical structures such as the medial and lateral geniculate bodies, inferior and superior colliculi have higher glucose utilization than other structures. There is also a correlation between functional activity and metabolic rate such as in the visual and auditory system (Siesjo, 1978). The aim of present study is to investigate the possible general histological effects of chronic administration of *P. amarus* on the superior colliculus of adult wistar rats.

MATERIALS AND METHODS

Animals

Twenty-four (24) adult wistar rats of both sexes with average weight of 200 g were randomly assigned into three groups: A, B and C of (n = 8) in each group. Groups A and B of (n = 16) served as treatment groups while Group C (n = 8) was the control. The rats were obtained and maintained in the Animal Holdings of the Department of Anatomy, School of Basic Medical Sciences, University of Benin, Benin City, Edo State, Nigeria. The animals were fed with grower's mash obtained from Edo Feeds and Flour Mill Limited, Ewu, Edo State, Nigeria and given water liberally. The *P. amarus* leaves were obtained in Benin City, dried and processed into aqueous extract at the Department of Pharmacognosy, Faculty of Pharmacy, University of Benin, Benin City, Edo State, Nigeria.

Preparation and administration of *P. amarus*

The plant leaves were obtained in Benin City, cleaned and oven dried at 50°C and was macerated into dry powder. The *P. amarus* powder was extracted with distilled water using Soxhlet apparatus and concentrated by rotary evaporator at 65°C. It was then transferred into a suitable container and freeze dried ready for the experiment.

Animals in Group A were given the aqueous extract of *P. amarus* at a single dose of 400 mg/kg body weight daily for thirty days through the orogastric tube, while animals in Group B received 800 mg/kg body weight daily via the same route and the same period. Animals in Group C received equal volume of distilled water, for the

same period and through the same route of administration. The rats were sacrificed by cervical dislocation on the thirty-one day of the experiment. The skulls were opened using bone forceps to expose the brain and the superior colliculus was quickly dissected out and fixed in 10% formal saline for routine histological techniques after Drury et al. (1976). The reagents and chemicals used in this experiment were obtained from May & Baker (M & B) laboratory chemicals.

Histological study

The tissues were dehydrated in an ascending grade of alcohol (ethanol), cleared in xylene and embedded in paraffin wax. Serial sections of 7 microns thick were obtained using a rotatory microtome. The deparafused sections were stained routinely with haematoxyline and eosin (Drury et al., 1976). Photomicrographs of the desired results were obtained using research photographic microscope in the Department of Anatomy, School of Basic Medical Sciences, University of Benin, Benin City, Edo State, Nigeria.

RESULTS

The results obtain in this experiment was limited to the general histological features using the haematoxyline and eosin (Drury et al., 1967) method. It does not involve and never intends to show the sectional scale bars of neurons of the superior colliculus.

The desired sections of the superior colliculus from the control animals showed normal histological features with the neurons appearing distinct and of various sizes. The neuron and glial cells appeared normal with no vacuolation in the stroma of the superior colliculus (Figures 1 and 2).

The sections of the superior colliculus treated with *P. amarus* revealed some cellular degenerative changes such as hypertrophy, sparse cellular population and vacuolations in the stroma of the treated sections of the superior colliculus with that of Group B more marked (Figure 3 and 4).

DISCUSSION

The results (H and E) of this experiment showed some cellular degenerative changes such as hypertrophy and sparse cellular population and vacuolations in the stroma of the treated sections as compared to the control section of the superior colliculus of adult wistar rats.

Neuronal degeneration has been reported to result in cell death, which is of two types, namely apoptotic and necrotic cell death. These two types differ morphologically and biochemically (Wyllie, 1980). Pathological or accidental cell death is regarded as necrotic and could result from extrinsic insults to the cell such as osmotic, thermal, toxic and traumatic effects (Farber et al., 1981). It was reported that cell death in response to neurotoxins might trigger an apoptotic death pathway within brain cells (Waters, 1994). Cell death in response to neurotoxins occurs as a controlled event involving a genetic programmed in which caspase enzymes are activated

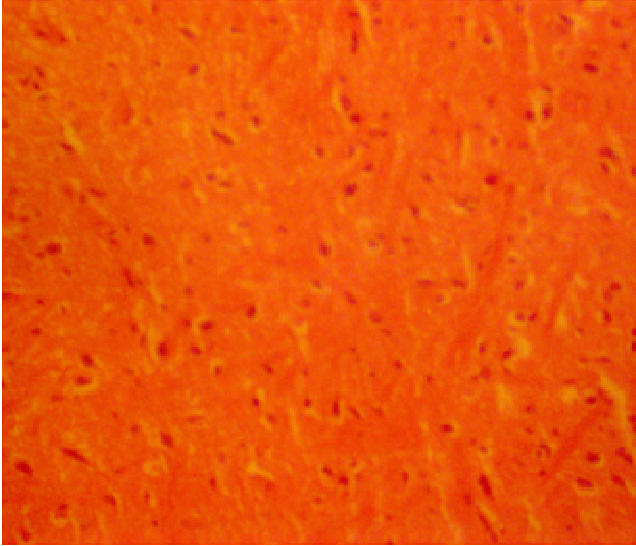

Figure 1. Control section of the superior colliculus (H and E method x100).

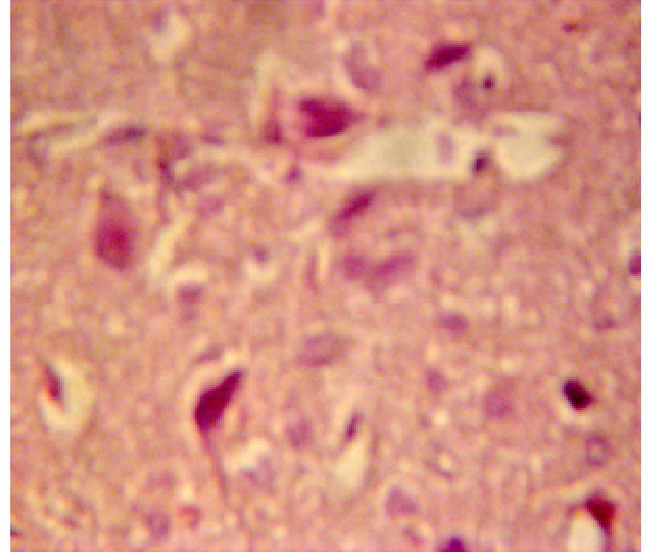


Figure 3. Treated section of the superior colliculus with 400 mg/kg of *P. amarus* (H and E method x 400).

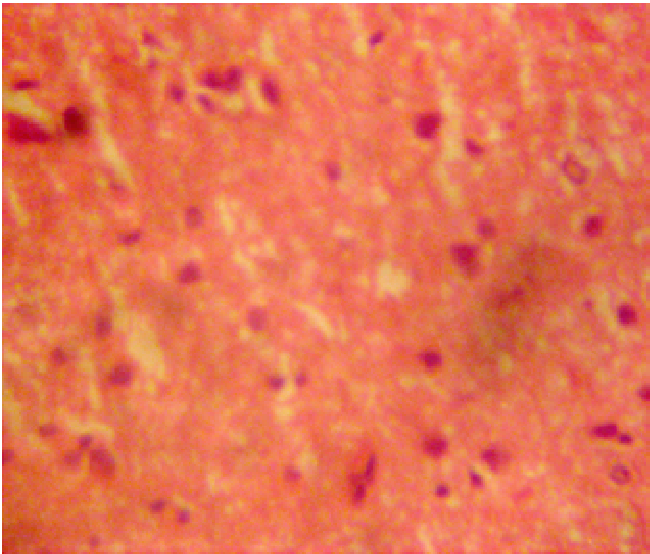


Figure 2. Control section of the superior colliculus (H and E method x 400).

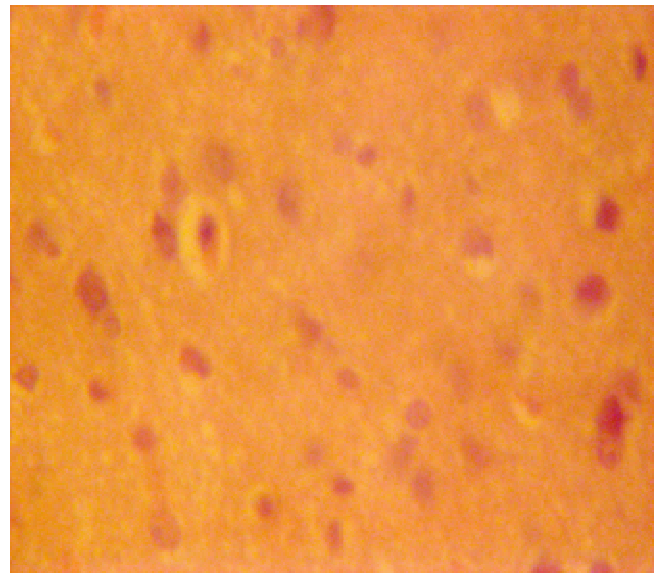


Figure 4. Treated section of the superior colliculus with 800 mg/kg of *P. amarus* (H and E method x 400).

Waters, 1994).

The process of cellular necrosis involves disruption of the membranes structural and functional integrity. Cellular necrosis is not induced by stimuli intrinsic to the cells as in programmed cell death (PCD), but by an abrupt environmental perturbation and departure from the normal physiological conditions (Martins et al., 1978). There is the need to further investigate the actual mechanism by which *P. amarus* induced neuronal degeneration in the superior colliculus of adult wistar rats in this study.

Extensive cell death in the central nervous system is present in all neurodegenerative diseases (Waters,

1994). The type of nerve cell loss and the particular part of the brain affected dictate the symptoms associated with an individual disease (Waters, 1994). In this study, *P. amarus* may have acted as toxin to the cells of the superior colliculus, affecting their cellular integrity and causing defect in membrane permeability and cell volume homeostasis.

In cellular necrosis, the rate of progression depends on the severity of the environmental insults. The greater the severity of the insults, the more rapid the progression of neuronal injury (Ito et al., 1975). The principle holds true

for toxicological insult to the brain and other organs ((Martins et al., 1978). The prime candidates for inducing the massive cell destruction observed in neurodegeneration are neurotoxins (Waters, 1994). These may be substances present in small amounts in the environment, or even naturally occurring chemicals such as glutamate used by the brain as transmitter's substances (Waters, 1994). The latter when present at a critical level can be toxic to the brain cells they normally excite (Waters, 1994). It could be inferred from these results that chronic administration of *P. amarus* resulted in increased toxic effects on the superior colliculus of adult wistar rats. The decrease in cellular population observed in this study may have been as a result of cell death caused by the toxic effects of *P. amarus*. In the same way, it has been reported that chronic administration of chloroquine resulted in the cellular degenerative changes, sparse cellular population and vacuolation appearing in the stroma with some autophagic vacuoles in the inferior colliculus and medial geniculate body of adult wistar rats (Adjene and Adenowo, 2005; Adjene and Caxton-Martins, 2006).

The vacuolations observed in this experiment may be due to *P. amarus* interference with the stroma of the superior colliculus. The cellular hypertrophy observed in this experiment could be attributed to the adverse effects of *P. amarus* on the superior colliculus of adult wistar rats. It is probable that the results obtain in this experiment may have been due to the neurotoxic effect of *P. amarus* on the neuronal cells of the superior colliculus of adult wistar rats.

The importance of this report lies in the potential adverse effects of *P. amarus* on the microanatomy of the superior colliculus of adult wistar rats. The observations obtain in this study provides further evidence that medicinal use of *P. amarus* has an adverse side effects. It therefore, call for caution and discretion as is been use in traditional medicine

Conclusion and recommendation

The study revealed histological evidence that chronic administration of *P. amarus* has a potential adverse effect on the superior colliculus. It caused some cellular degenerative changes such as hypertrophy, sparse cellular population and vacuolations in the stroma of the treated sections in the superior colliculus of adult wistar rats. These results may probably affect the functions of the superior colliculus in visual and somatosensory motor sensibilities in adult wistar rats.

REFERENCES

- Adjene JO, Adenowo TK (2005). Histological studies of the effect of chronic administration of Chloroquine on the inferior colliculus of adult wistar rat. *J. Med. Biomed. Res.* 4(1): 83-87.
- Adjene JO, Caxton-Martins AE (2006). Some histological effect of chronic administration of Chloroquine on the medial geniculate body of adult wistar rat. *Afr. J. Med. Sci.* 35: 131-135.
- Altman AS, Bayer CS (1981). Time of Origin of neurons of rat superior colliculus in relation to other components of the visual and visuomotor Pathways. *Exp. Brain Res.* 42: 424-434
- Calixto JB (2000). Efficacy, Safety, Quality Control, Marketing and Regulatory Guidelines for Herbal Medicines (Phytotherapeutic Agents). *Braz. J. Med. Biol. Res.* 3: 179-189.
- Calixto JB, Santos ARS, Cechinel-Filho V, Yunes RA (1998). A Review of the Plants of the Genus *Phyllanthus*: their Chemistry, Pharmacology and Therapeutic Potential. *Med. Res. Rev.* 18: 225-258.
- Drury RAB, Wallington EA, Cameron R (1976). *Carleton's Histological Techniques*: 4th ed., Oxford University Press NY, USA, pp. 279-280.
- Farber JL, Chein KR, Mittnacht S (1981). The pathogenesis of Irreversible cell injury in ischemia; *Am. J. Pathol.* 102: 271-281
- Ito U, Sparts M, Walker JR, Warzo I (1975). Experimental Cerebral Ischemia in Magolian Gerbils (1). Light microscope observations. *Acta Neurophatolgy USA*, 32: 209-223.
- Jiang W, Stein BE (2003). Cortex controls multisensory depression in superior colliculus. *J. Neurophysiol.* 90: 2123-2135.
- Kaplowitz N (1997). Hepatotoxicity of Herbal Remedies. Insight into the Intricacies of Plant-Animal Warfare and Cell Death. *Gastroenterology*, 113: 1408-1412.
- Martins LJ, Al-Abdulla NA, Kirsh JR, Sieber FE, Portera-Cailliau C (1978). Neurodegeneration in excitotoxicity, global cerebral ischaemia and target Deprivation: A perspective on the contributions of apoptosis and necrosis. *Brain Res. Bull.* 46(4): 281-309.
- Muhamad BZ, Mustafa AM (1994). Penerbit Fayar Bakti Sdn. Bhd, Kualalumpu, Malaysia.
- Nagy A, Krusel W, Rottman S, Dannenberg S, Hoffmann K (2006). Somatosensory- motor neuronal activity in the superior colliculus of the primate. *Eur. J. Neurosci.* 24(3): 917-924.
- Reczkoski D, Diamond D (1978). cells of origin of several efficient Pathways from the superior colliculus in Galago Senegalerisis. *Brain Res.* 146: 351-357.
- Santos ARS, Ailho VC, Yunes RA, Calixto JB (1995). Analysis of the Mechanism Underlying the Anti-nociceptive Effect of the Extracts of Plants from the Genus *Phyllanthus*. *Gen. Pharmacol.* 26: 1499 -1506
- Shaw D, Leon C, Koleu S, Murray V (1997). Traditional Remedies and Food Supplements. A Five-year Toxicology Study (1991 -1995). *Drug Safety.* 17: 342-356.
- Siesjo BK (1978). Utilization of substrates by brain tissues. *Brain energy metabolism.* John Wiley and Sons, USA, pp. 101-130.
- Stein BE, Stanford TR, Rowland B, McHaffie JG, Lavadas E (2009). Plasticity and synergy in multisensory integration. Presented at the 10th international multisensory research for the city college of New York.
- Waleszczyk WJ, Nagy A, Wypych M, Berenyi A, Paroczy Z, Eordegh G, Ghazaryan, A, Benedek G (2007). Spectral receptive field properties of neurons in the feline superior colliculus. *Exp. Brain Res.* ISSN 0014-4819 Coden Exbrap. 181(1): 87- 98
- Waters CM (1994). Glutamate induced apoptosis of striatal cells in Rodent model for Parkinsonism. *Neuroscience*, 63: 1-5
- Wyllie AH (1980). Glucocorticoid-induced thymocyte apoptosis in associated and endogenous endonuclease activation. *Nature*, London, 284: 555-556.