

Full Length Research Paper

Evaluation of herbal ointment formulation of *Milicia excelsa* (Welw) C.C berg for wound healing

Udegbumam S. O.^{1*}, Nnaji T.O.¹, Udegbumam R. I.¹, Okafor J. C.¹ and Agbo I.²

¹Department of Veterinary Surgery, Faculty of Veterinary Medicine, University of Nigeria, Nsukka.

²Department of Veterinary Microbiology, Faculty of Veterinary Medicine, University of Nigeria, Nsukka.

Accepted 24 September, 2012

The wound healing effect of *Milicia excelsa* ointment was evaluated in three groups of rats using the excision wound model. Also the antibacterial effect of *M. excelsa* extract on *Pseudomonas aeruginosa* and *Staphylococcus aureus* was investigated. The result of the study showed that the ointment of *M. excelsa* significantly enhanced wound contraction and epithelialization. The epithelialization time in the *M. excelsa* ointment treated group was significantly shorter than time of epithelialization in the base treated group. On day 7, wound sections of rats treated with *M. excelsa* ointment showed abundant neutrophils, few macrophages and few fibroblasts while in the base treated rats, abundant neutrophils, few macrophages and few fibroblasts were seen. By day 14, wound sections of *M. excelsa* ointment treated rats showed abundant fibroblasts, mild collagenization, moderate macrophages and vascularization whereas moderate neutrophils, few macrophages and few fibroblasts were seen in the sections of base treated rats. *M. excelsa* extract at 100, 50, 25 and 12.5 mg/ml inhibited the growth of *S. aureus* but not *P. aeruginosa*. In this study, daily application of *M. excelsa* ointment enhanced wound contraction, epithelialization and fibroplasia. These results provide scientific evidence showing the efficacy of *M. excelsa* leaves in wound healing.

Key words: *Milicia excelsa*, ointment, excision wounds, contraction, epithelialization.

INTRODUCTION

Wound healing is a biologic process that enables the skin or any tissue to repair itself after an injury (Nguyen et al., 2009; Nilani et al., 2010). The process of wound healing involves four distinct but overlapping phases namely haemostasis, inflammation, proliferation and remodeling (Shivhare et al., 2010). These processes occur spontaneously and ensure proper restoration of the structural and functional integrity of the injured tissues (Schwartz, 1984; Raina et al., 2008). Occasionally, wound healing

does not progress in the ordered stepwise manner leading to development of chronic wound (Prakash and Solanki, 2011). Wounds are thus treated to shorten the duration of healing and to minimize the complications associated with wound healing (Myers et al., 1980).

In medical practice, clinical management of wounds most often involves topical application of antibiotic ointments, antiseptics and desloughing agents to aid wound repair (Chulani, 1996; Savanth and Mehta, 1996). Alternative

*Corresponding author. E-mail: sudegbunam@yahoo.com.

wound dressing agents such as growth factors (Embil et al., 2000), hydrocolloid gels (Steed, 1995), tissue extracts (Udupa et al., 1991), probiotics (Nasrabadi et al., 2011) and plant extracts (Nayak and Pinto, 2006; Nayak et al., 2009; Olugbuyiro et al., 2010; Abu-Al-Basal, 2010; Ezike et al., 2010) have been reported by various workers to possess pro-healing effects.

In most countries of Africa and Asia, herbal medicines are the most commonly used alternative wound treatments. These ethno medicines are affordable and rarely cause hyper sensitive reactions (Raina et al., 2008; Olajuyigbe and Afolayan, 2011). They also encourage blood clotting, fight infection and accelerate tissue regeneration (Raina et al., 2008; Ezike et al., 2010). These advantages of herbal remedy in wound care have spurred many researchers to investigate the wound healing potential of many plants materials used in traditional wound care. However, there is need for more studies to validate, standardize and prove the safety of plants used in traditional medicine before these plants could be recommended for wound management.

Milicia excelsa (welw.) C.C. Berg family Moraceae popularly known as Iroko tree or African teak is a large deciduous tree 30 to 50 m high occurring naturally in humid forests of West Africa (Agyeman et al., 2009). Literature search showed that *M. excelsa* has many medicinal uses. Its bark, roots, leaves and latex are used to prepare ethno medicines for the treatment of cough, fever, backache, tooth ache, abdominal pain, oedema, venereal diseases, hepatitis, liver diseases and haemostasis (Ndenecho, 2009). Oral information obtained from traditional healers in Uzo-Uwani in Nsukka area South East Nigeria showed that aqueous extract obtained from its leaves is used to treat fresh wounds. Although its leaf extract is claimed by traditional inhabitants in Nsukka area to have potent wound healing activity, no scientific study has been carried out to validate their claim. This present study was conducted to investigate the wound healing effect of the herbal ointment formulated from the methanol leaf extract of *M. excelsa*. The result of this study will validate the claim of the traditional healers on the efficacy of *M. excelsa* leaves in wound healing.

MATERIALS AND METHODS

Fresh leaves of *M. excelsa* were collected from Uzo Uwani in Nsukka area and were authenticated by Mr A. O. Ozioko of the International Centre for Ethno medicine and drug development, Nsukka. A voucher specimen INTERCEDD/801 was deposited at the centre for reference purposes.

Preparation of extract

The leaves were air dried, pulverized and macerated in 80% methanol for 48 h. After filtration, the filtrate was concentrated in a rotary evaporator at 40°C to obtain the methanol extract of *M. excelsa* (yield: 33.9% w/w). The extract was stored in the refrigerator until

use. For the antibacterial study and ointment preparation, the extract was suspended in 10% dimethyl sulphuroxide (DMSO).

Phytochemical analysis

The extract was screened for the presence of tannins, alkaloids, flavonoids, saponins, glycosides and arthroquinones using standard phytochemical methods (Evans, 1996).

Animal model

Thirty albino rats of both sexes weighing 200 to 250 g were used for the study. The rats were maintained in standard experimental conditions and fed rodent diets and water. All animal experiments were in compliance with the National Institute of Health Guide for Care and Use of Laboratory Animals (Pub No. 85-23, revised 1985).

Ointment preparation

The methanol leaf extract of *M. excelsa* was used to prepare the ointment for topical application. *M. excelsa* ointment (50% w/w) was prepared using soft white paraffin as base (Okore et al., 2004). White paraffin (8 g) was weighed into a mortar suspended on a water bath. The water was heated to boiling point. Then 8 g of the extract was dissolved in DMSO and mixed thoroughly with the melted paraffin for few minutes. A neomycin-bacitracin (cicatr[®]) ointments (50% w/w) was prepared using the same procedure stated above. The ointments were packed into ointment tubes and sealed until use.

Excision wound creation

Excision wounds were inflicted on rats to study the wound healing effect of *M. excelsa* (Morton and Malone, 1972). Thirty rats were anaesthetized with diethyl ether and their dorsum shaved prior to wound creation. The shaved skins were disinfected with 70% alcohol. The areas of the dorsum to be excised (2 cm diameter) were traced with the aid of circular rubber seal and a blue marker. The traced dorsal areas were excised using scalpel blade and surgical scissors. Post excision, wound areas were immediately traced on transparent papers placed over the wound. The tracing paper was later placed on 1 mm² graph sheet and traced out. The numbers of squares were counted and the area recorded as documented by Chah et al. (2006).

Grouping of animals

Rats were assigned to three treatment groups (n = 10). The wounds of rats in groups one and two were treated topically with ointment base (soft white paraffin) and cicatr[®] ointment (50% w/w) while wounds of group three rats were treated with *M. excelsa* ointment (50% w/w). The rats were housed individually in metal cages and their wounds treated daily from day 0 until their wounds healed completely.

Gross appearance of wounds

The gross appearance of the wounds were noted daily and recorded as wet/inflamed and dry/uninflamed. The day of appearance of scar tissues and day of their fall were also noted.

Table 1. Phytochemical compounds identified in *M. excelsa* extract.

Phytoconstituent	Result
Tannins	++
Alkaloids	++
Flavonoids	+++
Saponins	+++
Glycosides	-
Terpenoids	-
Arthroquinones	-

+++ , Highly present, ++, moderately present, -, absent.

Rate of wound contraction and epithelialization

The wound areas were traced on day 0 and every 3 days subsequently. Wound contraction was calculated as a percentage reduction in wound area (Alqasoumi et al., 2011). The time taken to obtain 50% wound closure (WC₅₀) was also calculated (Alqasoumi et al., 2011). Epithelialization time was also recorded (Nayak et al., 2009).

Histology

Wound healing was monitored histologically by collecting tissue biopsies from two rats per group on days 7 and 14. Biopsy (3 mm) from each wound site was excised to a depth sufficient to include newly formed granulation tissues, adjacent wound edges and underlying muscles surrounded by a margin of normal skin. Tissue sections were fixed in 10% formal saline. Tissues were processed as described by Nasrabadi et al. (2011). Five micrometer sections were stained with haematoxylin-eosin and examined with light microscope (x 400) for the presence of macrophages, neutrophils and fibroblasts. The cell distributions were graded as few, moderate and abundant.

Antibacterial study

The agar diffusion method was used to evaluate the antibacterial effect of the extract (Perez et al., 1990). Pure isolates of *Pseudomonas aeruginosa* and *Staphylococcus aureus* obtained from the Veterinary Microbiology laboratory, University of Nigeria, Nsukka were used. The crude extract 100 mg/ml was subjected to two fold serial dilutions to obtain 50, 25, 12.5 and 6.25 mg/ml solutions. A single colony of each test isolate was suspended in 2 ml sterile nutrient broth. The suspension was adjusted to 10⁶ cfu/ml and used to inoculate Muller Hinton agar. The inoculated agar plate was allowed to dry and the plates divided into five equal parts and labeled accordingly. Using a sterile cork borer (6 mm diameter), five wells were made in each segment. Then 0.02 ml of the extract (100, 50, 25, 12.5 and 6.25 mg/ml) were delivered into the appropriate wells. The culture plates were allowed to stand for 30 min to ensure proper diffusion of the extract into the agar and then incubated for 24 h at 37°C. After incubation, the inhibition zone diameter (IZD) for each well was measured to the nearest possible millimeter (mm).

Statistical analysis

The percentage wound contraction and wound epithelization time were analyzed using analysis of variance (ANOVA) in SPSS.15.0

software. Least significant difference (LSD) was used to separate variant means at probability level less than 0.05 ($p < 0.05$).

RESULTS

Phytochemical analysis

Phytochemical screening of the extract showed the presence of tannins, alkaloids, flavonoids and saponins (Table 1).

Gross appearance of wound surface

The wound surfaces of rats treated with *M. excelsa* ointment and cicatrin[®] ointment were dry/uninflamed throughout the treatment period while wound of the base treated rats remained wet/inflamed up till day 6 post wounding. Scar tissues were observed in the cicatrin[®] and extract ointment groups on day 6 while scar tissues were seen on the base group by day 9. While scars in the extract treated group started to fall by day 12, scars in the base treated group started to fall by day 15. By day 18, no scar tissue was seen in all rats treated with *M. excelsa* ointment.

Wound contraction and epithelialization

The percentage wound contraction in the *M. excelsa* ointment treated group on days 12, 15 and 18 were significantly ($p < 0.05$) higher compared to wound contraction in the base treated group. The percentage wound contraction seen in the *M. excelsa* ointment treated group was statistically comparable to that of the cicatrin[®] treated group (Table 2). The WC₅₀ in base, cicatrin and *M. excelsa* ointment treated groups were 10.4, 7.1 and 8.6 days, respectively. The epithelialization time in the *M. excelsa* ointment treated group was significantly ($p < 0.05$) shorter than time of epithelialization in the base treated group (Table 3).

Histology

On day 7, sections from wound of rats treated with *M. excelsa* ointment (Figure 1) showed abundant neutrophils, few macrophages and few fibroblasts. Moderate number of neutrophils, few macrophages and few fibroblasts were noted in the section of cicatrin[®] treated rats (Figure 2). In the base treated rats (Figure 3), abundant neutrophils, few macrophages and few fibroblasts were seen. By day 14, wound sections of *M. excelsa* ointment treated rats (Figure 4) showed abundant fibroblasts, mild collagenization, moderate macrophages and vascularization. In the wound sections of cicatrin[®] treated rats (Figure 5), significant collagenization, abundant fibroblasts, moderate macrophages and capillaries were seen while moderate neutrophils, few macrophages and few fibroblasts were seen in the sections of base treated rats

Table 2. Percentage wound contraction of rats treated with *M. excelsa* ointment.

Group	Percentage wound contraction					
	Day 3	Day 6	Day 9	Day 12	Day 15	Day 18
1	21.3 ± 4.2 ^a	24.6 ± 10.9	37.1 ± 7.9	64.4 ± 1.8 ^a	71.6 ± 2.9 ^a	87.2 ± 2.4 ^a
2	14.1 ± 1.1 ^b	29.6 ± 9.7	75.7 ± 10.1	83.7 ± 6.4 ^b	87.3 ± 6.1 ^b	95.4 ± 4.0 ^b
3	8.1 ± 5.9 ^b	16.7 ± 7.3	55.4 ± 19.1	76.2 ± 5.2 ^{ab}	87.4 ± 3.3 ^b	94.7 ± 1.4 ^b

Gp 1, Base treated; Gp 2, cicatrin[®] treated; GP 3, *M. excelsa* ointment treated. Different superscripts in a column shows significant difference at $p < 0.05$.

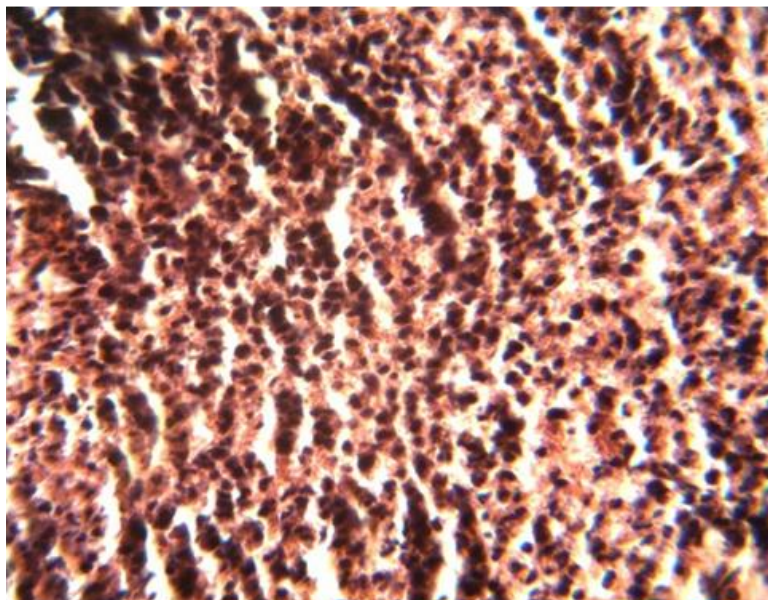


Figure 1. *M. excelsa* ointment treated day 7 shows abundant neutrophils, few macrophages and few fibroblasts.

Table 3. Wound epithelialization time of rats treated with *M. excelsa* ointment.

Group	Epithelialization time (days)
1	20.5 ± 2.32 ^a
2	13.75 ± 1.1 ^b
3	16.5 ± 2.08 ^c

Gp 1, Base treated; Gp 2, cicatrin[®] treated; GP 3, *M. excelsa* ointment treated. Different superscripts in a column shows significant difference at $p < 0.05$.

(Figure 6).

Antibacterial study

As shown in Table 4, the leaf extract at 100, 50, 25 and 12.5 mg/ml inhibited the growth of *S. aureus* but not *P. aeruginosa*.

DISCUSSION

The process of wound healing involves granulation, fibroblast proliferation, collagenization, epithelialization and remodeling (Shivhare et al., 2010). Hence in this study, we used the excision wound model to assess the effect of *M. excelsa* ointment on wound contraction, epithelialization, fibroblast proliferation and collagen deposition. This study also investigated the antibacterial effect of *M. excelsa* extract.

The wounds of the *M. excelsa* ointment treated rats were dry and uninfamed from day 3 post wounding. The ability of the ointment to maintain a dry wound surface suggests that *M. excelsa* possessed both astringent and anti-inflammatory properties. These two effects may be attributed to the abundance of tannins, flavonoids and alkaloids in the leaves of *M. excelsa*. Tannins are known to have astringent and haemostatic activity (Ezike et al., 2010). Flavonoids and alkaloids isolated from medicinal plants have been shown by various experiments to poss-

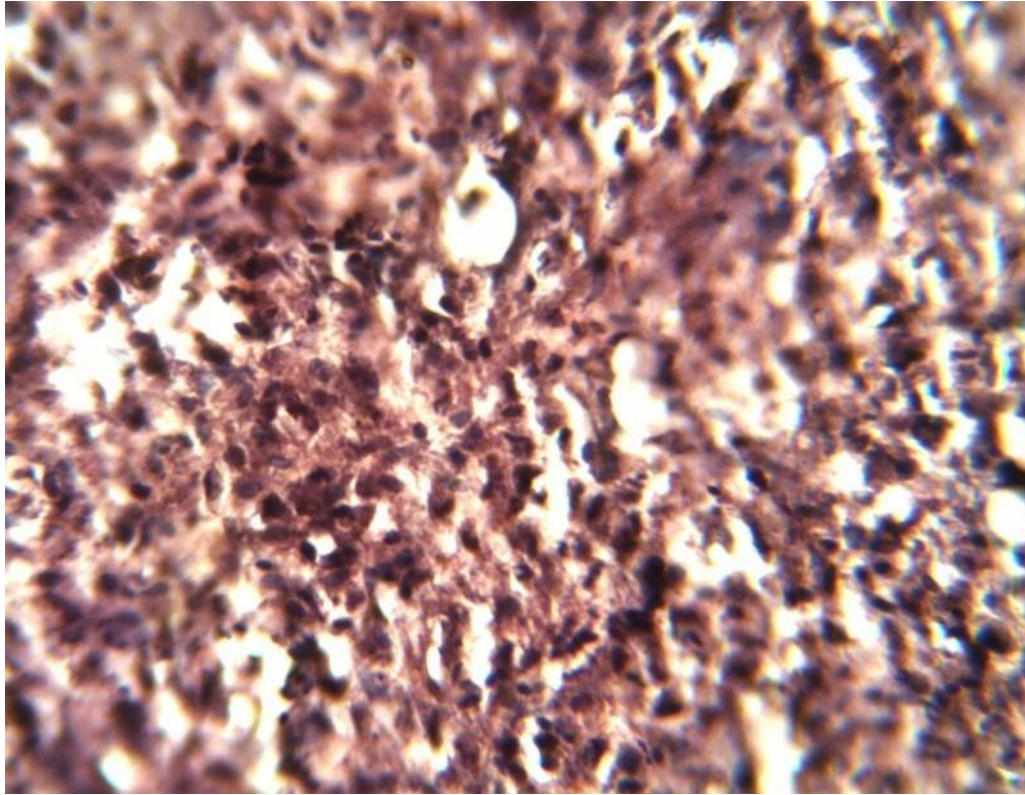


Figure 2. Cicatrin® treated day 7 shows moderate number of neutrophils, few macrophages and few fibroblasts.

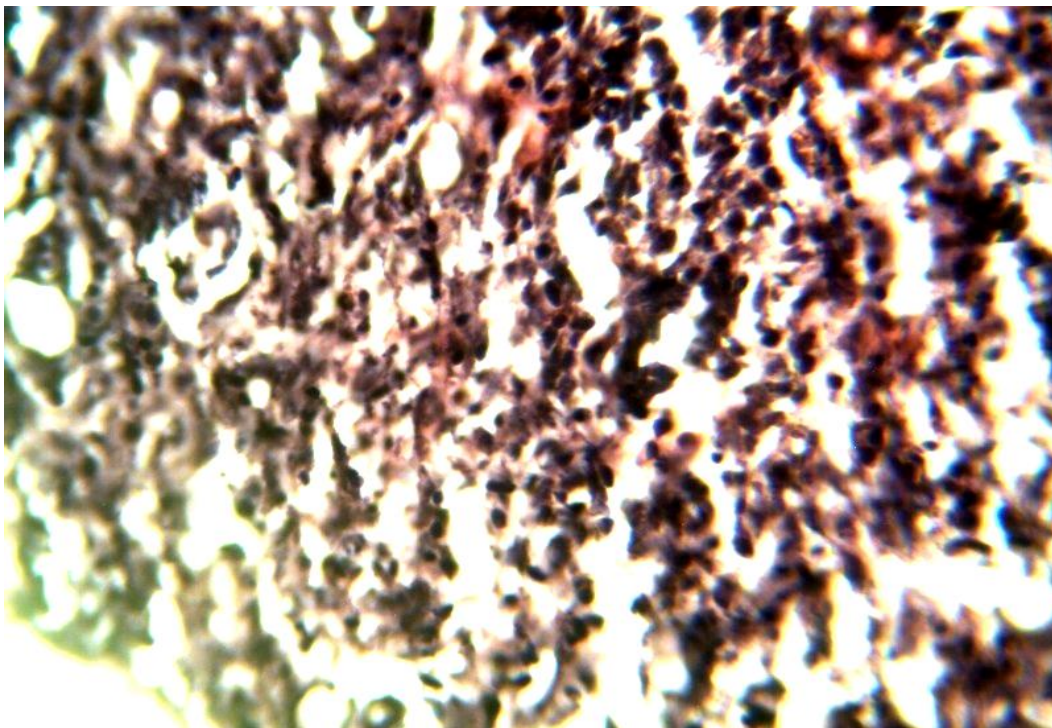


Figure 3. Base treated day 7 shows abundant neutrophils, few macrophages and few fibroblasts.

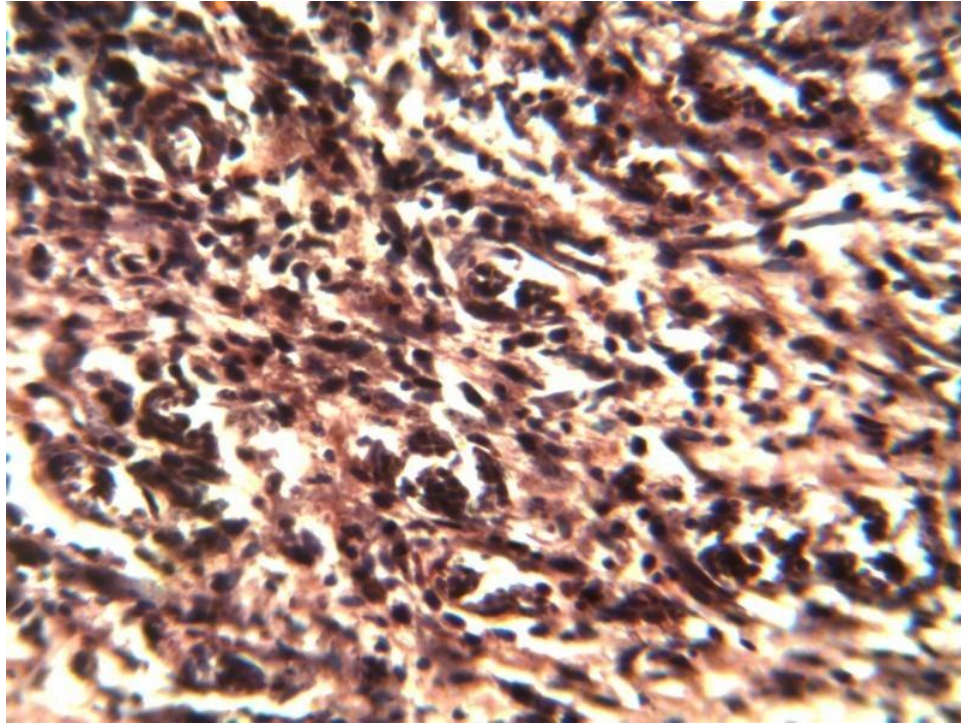


Figure 4. *M. excelsa* ointment treated day 14 shows abundant fibroblasts, mild collagenization, moderate macrophages and vascularization.

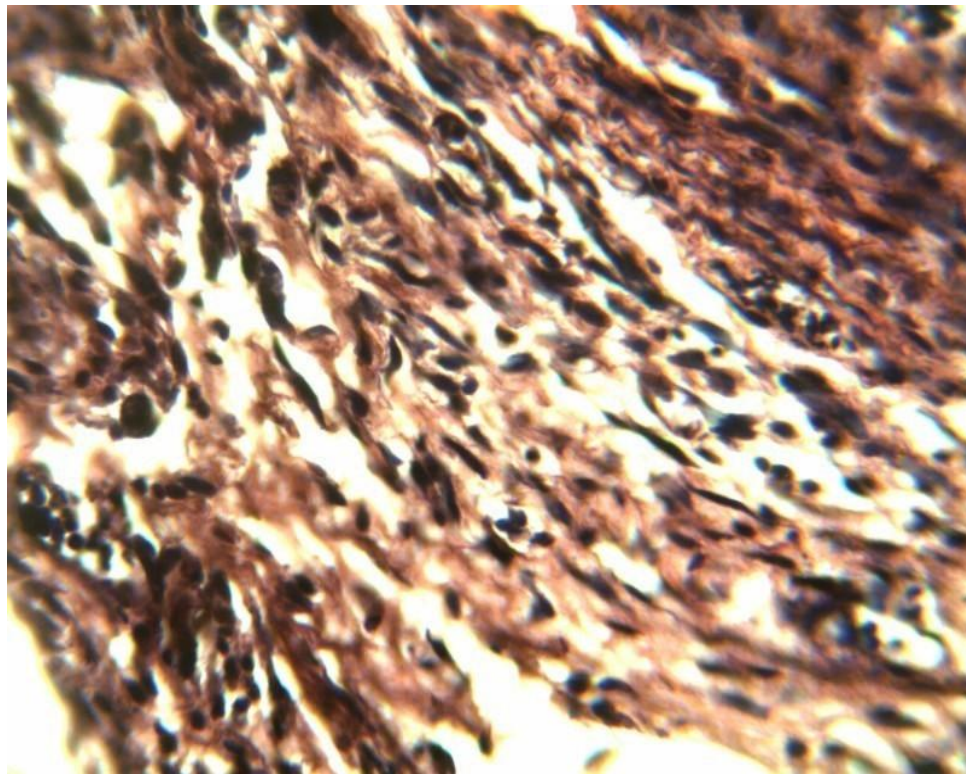


Figure 5. Cicatrin® treated day 14 shows significant collagenization, abundant fibroblasts, moderate macrophages and capillaries.

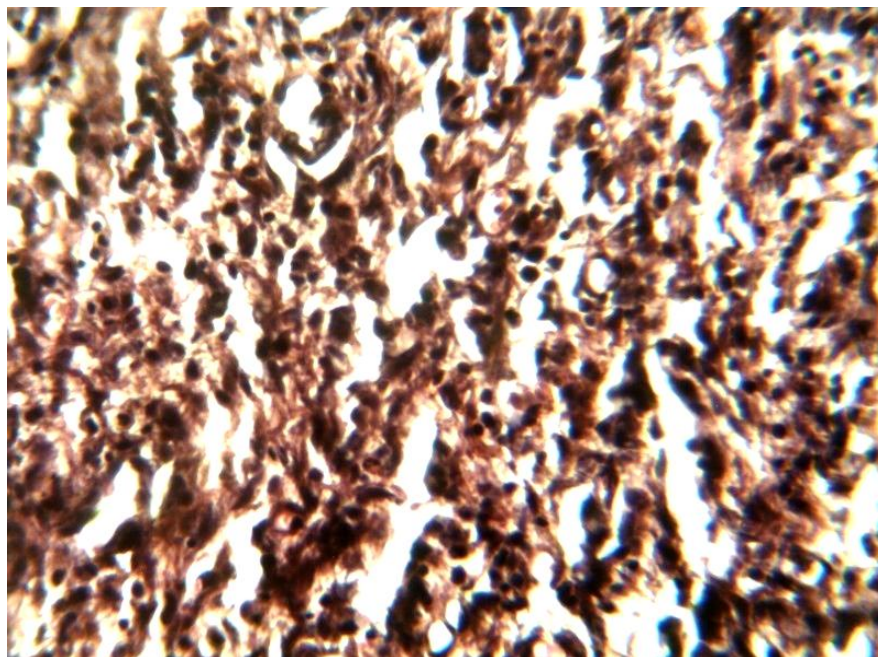


Figure 6. Base treated day 14 shows moderate neutrophils, few macrophages and few fibroblasts.

Table 4. Inhibitory zone diameter (mm) of different concentrations of the extract.

Concentration (mg/ml)	<i>Pseudomonas aeruginosa</i>	<i>Staphylococcus aureus</i>
100	0	2.5
50	0	1.9
25	0	1.6
12.5	0	1.0
6.25	0	0

possess anti-inflammatory property thus creating enabling environment for tissue repair (Rogas et al., 1992; Bhujbal et al., 2008).

The inflammatory phase of wound healing is initiated by neutrophils which are the predominant cells in the first two days post wounding (De La Torre and Sholar, 2006). As inflammation continues, monocytes are attracted to the site of injury by growth factors released by platelets and other cells (Santoro and Gaudino, 2005). Monocyte mature into macrophages which function to phagocytize bacteria and debris damaged tissues (Jia and Pamer, 2009; Tam et al., 2011). Macrophages also coordinate tissue repair through the production of growth factors and other cytokines which initiate angiogenesis, fibroplasia and extracellular matrix synthesis (Greenhalgh, 1988; DiPietro, 1995; Deodhar and Rana, 1997). It was noted that the number of macrophages in the wounds of cicatrin® and *M. excelsa* ointment treated rats were more compared to the neutrophil number in the base treated

rats by day 14. This shows that wound healing was progressing faster in cicatrin® and *M. excelsa* ointment treated groups compared to the base group.

The proliferative phase of wound healing is characterized by granulation, epithelialization and contraction (Wasman et al., 2010). In the granulation phase, fibroblasts secrete substances such as glycosaminoglycans and collagen needed for connective tissue maturation and increased wound strength (Stadelmann et al., 1998; Clark, 2001; Nasrabadi et al., 2011). Wound contraction enables the wound edges to pull together while epithelialization leads to the formation of new epithelial covering over the wound (Kumar, 2002). This study showed that the rates of wound contraction and epithelialization were more rapid in the *M. excelsa* ointment group compared to the control group. The histologic study of the wound of the *M. excelsa* ointment treated rats showed more fibroblast proliferation and significant collagenization on day 14. These results obtained in the extract ointment treated

group suggests that daily application of the ointment of *M. excelsa* promoted collagen expression (Bonte et al., 1993), angiogenesis (Shukla et al., 1999) and tensile strength of the wounds (Suguna et al., 1996).

Wound fluids and exudates often provide conducive environment for microbial growth (Okoli et al., 2007). Thus bacteria such as *P. aeruginosa*, *S. aureus*, *Escherichia coli*, *Proteus vulgaris* and *Clostridium tetani* are routinely isolated from wounds of man and animals (Emele et al., 1999; Bowler et al., 2001). Among these wound isolates, *P. aeruginosa* (Hamud-Socoro, 2004; Hancock and Speert, 2000) and *S. aureus* (Rantala et al., 2004; Fagade et al., 2010) have developed resistance to common antibacterial agents. The result of this study showed that the extract of *M. excelsa* remarkably inhibited the growth of *S. aureus*. This antibacterial activity of the extract might have contributed to its wound healing effect (Deshmukh et al., 2009).

This study showed that the daily application of *M. excelsa* ointment on excision wounds of rats promoted wound contraction, epithelialization and fibroplasia. The findings of this study provide scientific evidence confirming the efficacy of *M. excelsa* leaves in wound healing.

REFERENCES

- Abu-Al-Basal MA (2010). Healing potential of *Rosmarinus officinalis* L. on full thickness excision cutaneous wounds in alloxan –induced – diabetic BALB/c mice. *J. Ethnopharmacol.* 131:443-450.
- Agyeman VK, Ofori DA, Cobbinah JR, Wagner MR (2009). Influence of *Phytolyma lata* (Homoptera psyllidae) on seed growth of *Milicia excelsa*. *Ghana J. Forest.* 25:29-39.
- Alqasoumi SI, Hasan S, Yusufoglu HS, Alam A (2011). Anti-inflammatory and wound healing activity of *Fagonia schweinfurthii* alcoholic extract herbal gel on albino rats. *African J. Pharm. Pharmacol.* 5(17):1999-2001.
- Bhujbal SS, Chitlange SS, Suralkar AA, Devanand B, Shinde DB, Patil MJ (2008). Anti-inflammatory activity of an isolated flavonoid fraction from *Celosia argentea* Linn. *J. Med. Plants Res.* 2(3):52-54.
- Bonte F, Dumas M, Chadgne C, Meybeck A (1993). Influence of asiatic acid, madecassic acid and asiaticoside on human collagen I synthesis. *Planta Med.* 60:133-135.
- Bowler PG, Duerden BI, Armstrong DG (2001). Wound microbiology and associated approaches to wound management. *Clin. Microbiol. Rev.* 14:244-269.
- Chah KF, Eze CA, Emuelosi CE, Esimone CO (2006). Antibacterial and wound healing properties of methanolic extracts of some Nigerian medicinal plants. *J. Ethnopharmacol.* 104:164-167.
- Chulani HL (1996). In: *The law of medical negligence* 1st ed. Radhakrishnan Medical and Educational Trust: Mumbai. Pp. 51-83.
- Clarke RA (2001). Fibrin and wound healing. *Annals of New York Academy of sciences.* 936:355-367.
- De La Torre, Sholar A (2006). Wound healing: chronic wounds. *E-medicines.com.* Retrieved Jan. 2008.
- Deodhar AK, Rana RE (1997). "Surgical physiology of wound healing: a review". *J. Postgrad. Med.* 43 (2):52-56.
- Deshmukh PT, Fernandes J, Atul A, Toppo E (2009). Wound healing activity of *Calotropis gigantean* root barks in rats. *J. Ethnopharmacol.* 125:178-181.
- DiPietro LA (1995). Wound healing: the role of macrophages and other immune cells. *Shock.* 4:233-240.
- Embil JM, Papp K, Sibbald G, Tousignant J, Smiell JM, Wong B, Lau CY (2000). Recombinant human platelet-derived growth factor-BB (becaplermin) for healing chronic lower extremity diabetic ulcers: an open-label clinical evaluation of efficacy. *Wound Rep. Reg.* 8:162-168.
- Emele FE, Izomoh MI, Alufohai E (1999). Microorganisms associated with wound infection in Ekpoma, Nigeria. *West Afr. J. Med.* 18:97-100.
- Evans WC (1996). *Trease and Evans Pharmacognosy*, 14th edition. W.B Saunders co. Ltd. U.K. pp. 293-321.
- Ezike AC, Akah PA, Okoli CO, Udegbunam S, Okume N, Okeke C, Iloani O (2010). Medicinal plants used in wound care: Studies of *Prosopis africana* (Fabaceae) stem bark. *Indian J. Pharm. Sci.* 334-338.
- Greenhalgh DG (1988). The role of apoptosis in wound healing. *Int. J. Biochem Cell Biol.* 30: 1019-1030.
- Hamud-Socoro AA (2004). *Pseudomonas aeruginosa* resistance to tetracycline and triclosan. *Cantaurus.* 12:7-9.
- Hancock REW, Speert DP (2000). Drug resistance updates. Harcourt publishers Ltd. United Kingdom. pp. 247-255. Doi:10.1054/drug.2000.0152.
- Jia T, Pamer EG (2009). "Dispensable but not irrelevant". *Science.* 325: 549-550.
- Kumar A (2002). Wound healing and general management of wounds. *Veterinary surgical techniques.* UBS publishers distributions Ltd. New Delhi. pp. 151-160.
- Morton JJ, Malone MH (1972). Evaluation of vulneary activity by an open wound procedure in rats. *Arch. Int. Pharmacodyn.* 196:117-126.
- Myers KA, Marshal RD, Friedin J (1980). *Principles of Pathology in Surgery*, 1st ed. Blackwell Scientific Publications: London. Pp. 58-82.
- Nasrabadi HN, Ebrahimi TM, Banadaki DS, Kajousangi TM, Zahedi, F (2011). Study of cutaneous wound healing in rats treated with *Lactobacillus plantarum* on days 1, 3, 7, 14 and 21. *African J. Pharm. Pharmacol.* 5(21):2395-2401.
- Nayak BS, Pinto PLM (2006). *Catharanthus roseus* flower extract has wound healing activity in Sprague Dawley rats. *BMC Comp. Altern. Med.* 6:41-47.
- Nayak BS, Standiford S, Maxwell A (2009). Evaluation of the wound-healing activity of the ethanolic extract of *Morinda citrifolia* leaf. *J. Evid. Based Complementary Altern. Med.* 6:351-356.
- Nayak SB, Raju SS, Eversley M, Ramsubhag A (2009). Evaluation of wound healing activity of *Lantana Camara* L.- A preclinical study. *Phytother. Res.* 23:241-245.
- Ndenecho EN (2009). Herbarium and resources for the development of ethnopharmacology in Mount Cameroon region. *African J. Pharm. Pharmacol.* 3(3):78-86.
- Nilani P, Pranavi A, Duraisamy B, Damodaran P, Subhashini V, Elango K (2011). Formulation and evaluation of wound healing dermal patch. *Afr. J. Pharm. Pharmacol.* 5(19):1252-1257.
- Okoli CO, Akah PA, Okoli AS (2007). Potentials of leaves of *Aspilia africana* (Compositae) in wound care: an experimental evaluation. *BMC Comp. Altern. Med.* 7:24 doi:10.1186/1472-6882-7-24.
- Okore VC, Ibezim EC, Adikwu MU, Attama AA, Esimone CO, Uzuogbu BD, Ofokansi KC (2004). Laboratory techniques in Pharmaceutics and pharmaceutical microbiology (Okore VC ed.). 2nd Edition. El'Demark Publishers, Enugu. Pp. 50-53. ISBN: 978-8061-44-3
- Olajuyigbe OO, Afolayan AJ (2011). In vitro antibacterial activities of crude aqueous and ethanolic extracts of stem bark of *Acacia mearnsii* De Wild. *Afr. J. Pharm. Pharmacol.* 5(9):1234-1240.
- Olugbuyiro JAO, Abo KA, Leigh OO (2010). Wound healing effect of *Flabellaria paniculata* leaf extract. *J. Ethnopharmacol.* 127:786-788.
- Perez C, Pauli M, Bazerque P (1990). An antibiotic assay by the well agar method. *Acta Biol. Med. Exp.* 15:113-115.
- Prakash B, Solanki R (2011). Role of medicinal plants in wound healing. *Research J. Med. Plant.* 5(4):392-405.
- Raina R, Prawezi S, Verma PK, Pankaj NK (2008). Medicinal plants and their role in wound healing. *Vet. Scan.* 3:1-7.
- Rantala M, Lahti E, Kuhalampi J, Pesonen S, Jarvinen AK, Koulumies S, Honkanen-Buzaiski T (2004). Antimicrobial resistance in *Staphylococcus* spp., *Escherichia coli* and *Enterococcus* spp. In dogs given antibiotics for chronic dermatological disorders compared with non-treated control dogs. *Acta. Vet. Scan.* 45:37-45.
- Rogas A, Hernandez L, Pereda-Miranda R, Mata R (1992). Screening

- for antimicrobial activity of crude drug extracts and pure natural products from Mexican medicinal plants. *J. Ethnopharmacol.* 35:275-283.
- Santoro MM, Gaudino G (2005). Cellular and molecular facets of keratinocyte re-epithelialization during wound healing. *Exp. Cell Res.* 304:274-286.
- Savanth SS, Mehta N (1996). In: Savanth SS, Shah RA, Gore D. (Eds.) Text book and atlas of dermatosurgery and cosmetology, 1st ed. ASCAD: Mumbai. Pp. 50-61.
- Schwartz S (1984). Principles of surgery. Mc Graw comp NewYork. Pp. 289-304.
- Shivhare Y, Singour PK, Patil UK, Pawar RS (2010). Wound healing potential of the methanolic extract of *Trichosanthes dioica* Roxb (fruits) in rats. *J. Ethnopharmacol.* 127:614-619.
- Shukla A, Rasik AM, Dhawan BN (1999). Asiaticoside-induced elevation of antioxidant levels in healing wounds. *Phytother. Res.* 13:50-54.
- Stadelmann WK, Digems AG, Tobin GR (1998). Physiology and healing dynamics of chronic cutaneous wounds. *Am. J. Surg.* 176:26S-38S.
- Steed DL (1995). Clinical evaluation of recombinant human platelet-derived growth factor for the treatment of lower extremity diabetic ulcers. *J. Vasc. Surg.* 21:71-81.
- Suguna L, Sivakumar P, Chandrakasan G (1996). Effects of *Centella asiatica* extract on dermal wound healing in rats. *Indian. J. Exp. Biol.* 34:1208-1211.
- Tam JCW, Lau KM, Liu CL, To MH, Kwok HF, Lai KK, Lau CP, Ko CH, Leung PC, Fung KP, Lau CBS (2011). The in vivo and in vitro diabetic wound healing effects of a 2-herb formula and its mechanism of action. *J. Ethnopharmacol.* Doi:10.1016/j.jep.2011.01.032.
- Udapa SL, Shaila HP, Udapa AL, Ramesh KV, Kulkarni DR (1991). *Biochem. Arch.* 7:207-212.
- Wasman SQ, Mahmood AA, Salehuddin H, Zahra AA, Salmah I (2010). Cytoprotective activities of *Polygonum minus* aqueous leaf extract on ethanol-induced gastric ulcer in rats. *J. Med. Plants. Res* 4:2658-2666.