

Full Length Research Paper

Omental pedicle transposition and suture repair of peripheral nerve: A comparative study of functional, histological, morphometric and relative gastrocnemius muscle weight in rabbits

Al-Timmemi, H. A.^{1*}, Ibrahim, R.¹, Zuki, A. Z.² and Azmi, T. I.²

¹Department of Clinical Studies, Faculty of Veterinary Medicine, Universiti Putra Malaysia, 43400 UPM, Serdang, Selangor, Malaysia.

²Department of Preclinical Studies, Faculty of Veterinary Medicine, Universiti Putra Malaysia, 43400 UPM, Serdang, Selangor, Malaysia.

Accepted 28 October, 2011

The peripheral nervous system is able to regenerate after injury. Etiologies of injuries include penetrating injury, crush, traction, and ischemia compression. However, the presence of various nerve injury treatments such as coaptation and another technique to attain functional nerve regeneration are still inadequate. This study aimed to compare the effectiveness of omental pedicle transposition and epineural nerve suture on peripheral nerve regeneration in a rabbit model. Ten male New Zealand white rabbits were divided into two groups. In the primary epineural repair group or control group (CG), the left sciatic nerve was skeletonized from the sciatic notch till the point of bifurcation. The nerve was transected at the mid shaft of the femoral bone and repaired with six epineural sutures. In the treatment group (TG), the epineural repaired sciatic nerve was wrapped with omental pedicle around the site of coaptation. Assessment of the nerve regeneration was based on functional (motor and sensory), histological, morphometric criteria and relative gastrocnemius muscle weight. The results of the examination show that the treated group had better regeneration and functional recovery.

Key words: Omental pedicle, regeneration, hispathological, morphometric, sciatic nerve.

INTRODUCTION

The peripheral nervous system is able to regenerate after injury that is as a result of penetrating injury, crush, traction, or ischemia compression (Robinson, 2004) and microsurgical suture repair remains the current gold standard in clinical practice (Lundborg, 2000). However, recent studies were focused on a biological approach to nerve healing using omentum pedicle transposition. Omentum secretes and is the repository of many factors to promote an environment conducive to growth and overcome limitations in regeneration and functional recovery. In the omentum, the leukocyte aggregate in the perivascular area is termed milky spots (Mironiv et al.,

1979). Macrophage colony stimulating factor (MCSF) is locally produced in the milky spots (Dux, 1989). This study aimed to compare the effectiveness of omental pedicle transposition (OMPT) and epineural nerve suture on peripheral nerve regeneration in a rabbit model.

MATERIALS AND METHODS

Experimental animals design

Ten male New Zealand white rabbits (3 to 5 months old) weighing between 2.0 and 2.3 kg (animals unit, UKM, Malaysia) were used in the experiment. They were kept in their respective cages and given broad-spectrum antibiotics and antihelminthic. All procedures used in this study were approved by the Faculty of Veterinary Medicine, Universiti Putra Malaysia, Animal Care and Use Committee (08

*Corresponding author. E-mail: hameed_altmeme@yahoo.com.

R13/Dec 08). Rabbits were randomly divided into two groups (n=5). The two groups comprised animals with coaptated transected sciatic nerve with epineurial nerve suture as a control group (CG) and those with omental pedicle transposition as a treatment group (TG). The animals were euthanized from each group on day 112 post operations (PO).

Anesthesia

Induction of anesthesia was done by intramuscular injection of a mixture of 35 mg/kg ketamine hydrochloride (Bioketan, Vetoquinol Biowet, Sp. Zo.O, France), 5 mg/kg of xylazine hydrochloride (ILIUM XYLAZIL-20, Australia) and 1 mg/kg acepromazine maleate (Calmivet, Vetoquinol, Ltd. Lure cedex, France). Maintenance was carried out with 1.5% of halothane using a flow rate of 500 ml/min in a non-breathing circuit (modified Jackson-Reed Bain) using a face mask. The left hind limb was surgically prepared from upper midline to stifle joint, and draped with the aperture of the fenestrated drape at the intended operation site and covered with Opsite® (Smith and Nephew-Medical Limited/ England).

Surgical protocol

The skin was incised on the postero-lateral thigh, approximately 2 cm and caudo-lateral to the greater trochanter of the femur at the level of the distal at one-third of the femur. The muscles were split to expose the sciatic nerve from the sciatic notch to its bifurcation of the tibial and peroneal nerves and the nerve was transected at mid shaft of femoral bone. After this step, the animals were separated into two groups. In the CG, the nerve ends were coaptated immediately under a dissecting microscope (Kruss, Germany). Six equidistant epineurial simple interrupted sutures were applied about 1 mm from the edge of the transected using 8-0 nylon (Monofilament, ETHICON, USA). The superficial fascia and skin was sutured using 3-0 Vicryl (Biovек, Dynek Pty Ltd, Australia).

In the TG, the abdominal wall was incised at ventral midline 5 cm from xiphoid cartilage to umbilical region, and the omentum was extended to create the omental pedicle. The omental pedicle was extended caudally on the peritoneal surface of the abdominal wall, at the level of the femoral bone to create a separation between the semi-membranous and adductor muscles by blunt dissection using curved Kelly forceps, and to penetrate the upper part of abdominal wall to pull the omental pedicle without torsion. The omental pedicle was wrapped around the coaptation site of the left sciatic nerve and fixed with semi-membranous muscle using two stitches of 3.0 vicryl simple interrupted sutures. The midline incision was closed using 3.0 vicryl simple continuous sutures. All animals were given post-operative analgesia (10 mg/kg Tramadol hydrochloride) (Domadol® India, 50 mg); 0.2 ml/kg intramuscularly administered at 12 h intervals for three consecutive days.

Clinical observations

The motor and sensory sciatic nerve clinical reflexes were evaluated from the first day to day 112 PO.

Motor functions evaluation

Animals were monitored daily for the onset and the ability to walk to day 112 PO. They were examined for type of walking including crouching, crawling on heel, and normal, as well as knuckling, which was classified into severe, moderate, mild and normal. The muscle contraction force was graded from weak, moderate to

strong, and muscle mass atrophy graded as severe, moderate, mild or normal.

Sensory functions evaluation

Sensory functions of the coaptated sciatic nerves were tested daily to the end of the experiment. Toe spreading reflex, lateral aspect leg sensation, toe pinch and toe prick were evaluated as either present or absent. In addition, the foot withdrawal and vocalization tests of lateral aspect leg sensation, toe pinch and toe prick were recorded as positive responses indicating recovery and improved function.

Relative gastrocnemius muscle weight measurement (RGMW)

Following sacrifice of the rabbits, the gastrocnemius muscles were harvested and immediately weighed. The contralateral muscle was also harvested as control for weight variation between individual rabbits. Each muscle was then weighed separately using 0.0001 g weight (Sartorius Analytic Balance Model 2603, Munich, Germany) to calculate the percentage reduction in muscle mass (denervated muscle weight vs. contra lateral muscle weight). The muscles weight data were expressed as a ratio of the operated limb (left) to un-operated right limb as a negative control to calculate the RGMW.

Histopathology and Histomorphometry findings

The anastomosed left sciatic nerve was exposed and harvested from each animal. Three samples 1 cm long were collected from the proximal, middle (coaptate site) and distal segments of the coaptated sciatic nerve. The samples were trimmed of any excess length and divided into two parts each of 5 mm from proximal and distal segment for semithin and light microscopy sections. A 1 cm long nerve sample was obtained from the intermediate segment of the right sciatic nerve, which corresponded to the lesion site as a negative control. The samples for the light microscope were fixed with 10% neutral buffered formalin, dehydrated in a graded ethanol series, cleared in xylene, embedded in paraffin and cut into 5 µm thick sections and stained with hematoxyline, eosin and Meyer's modified trichrome stain.

The specimens for semithin section were fixed with 4% glutaraldehyde overnight at 4°C. The specimens were dehydrated, infiltrated with resin and polymerized. Following polymerization, the samples were sectioned using an ultra microtome (Leica). Semithin sections were stained with 1% toluidine blue and examined using Olympus image analysis (BX 51 TF attachment of CC 12 camera). The number of myelin nerve fibers, total fiber and axon diameters were determined using image software (Abramoff et al., 2004). The myelin thickness was derived from the differences between the fiber and axon diameter. In addition, the g ratio of each fiber was calculated as the axon diameter to the fiber diameter ratio. Right sciatic nerve (normal right hind limb) specimen were also collected and prepared as negative control.

Statistical analysis

All data were expressed as mean and standard deviations (M±SD). Statistical comparison between all groups was performed using Statistical Package for the Social Sciences (SPSS) 16.0 software (non-parametric tests), Kruskal Wallis and Mann-Witney tests for clinical observation and for morphometric analysis, one-way analysis of variance test (ANOVA), followed by Tukey and Duncan post tests were used. P value ≤ 0.05 was considered significant.

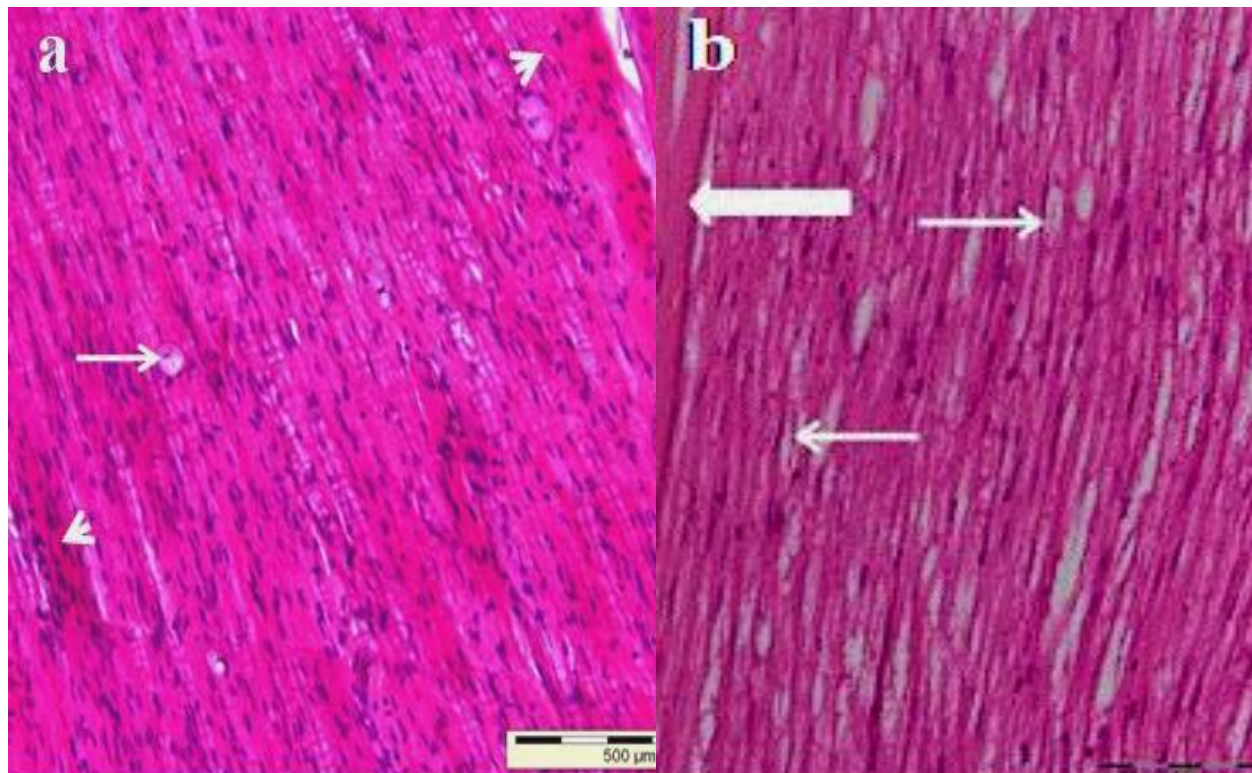


Figure 1. Light micrographs of the proximal segment of sciatic nerve on day 112 PO. (a) CG showing low vacuolated nerve fibers (arrow) and presence of collagen fibers (scar) at the peri and epineurium (arrow heads); (b) TG showed good myelination, normal thickness of epineurium (thick arrow), short internodal space (thin arrows), and good parallel arrangement of nerve fibers (H&E).

RESULTS

Sciatic nerve functions evaluation

Motor observations

The onset and ability to walk of the TG showed significantly earlier improvement ($p \leq 0.05$) compared to the CG. The type of gait (crouching and crawl) and knuckling disappeared in all animals of TG with significant difference ($p \leq 0.05$) compared to the CG. The muscle contraction force became stronger in the TG with significant difference ($p \leq 0.05$) compared to the CG. When the animals of TG were used, the operated limb and the muscle mass recovered to mild with significant difference ($p \leq 0.05$) compared to the CG group on day 112 PO.

Sensory clinical observations

Sensory clinical signs including toe spread, lateral leg sensation; toe pinch and toe prick in the TG animals showed that sensory reflexes were regained with significant difference ($p \leq 0.05$) compared to CG on day 112 PO.

Histopathology findings

Histopathology findings of the proximal stump sections of the CG showed mild adherence with surrounding tissue, low vacuolated nerve fibers, deposited collagen fibers (scar) at peri and epineurium and with some Schwann cells proliferation (Figure 1a). The TG showed improvement of the parallel arrangement of nerve fibers; less nerve fiber degenerated and increased the angiogenesis (Figure 1b). The coaptated site in the CG showed the presence of vacuolated and degenerative nerve fibers, granulomatous tissue surrounding the stitches and intraneural scar tissue formation (Figure 2a), while TG anastomosed segment sections showed a few degenerated nerve fibers, increased presence of Schwann cells and good parallel arrangement nerve fibers (Figure 2b).

The distal longitudinal segment in the CG showed mild adherence with surrounding tissue, low vacuolated degenerative nerve fibers, and presence of collagen fibers (scar) at peri and epineurium (Figure 3a), whereas the sections in TG showed normal parallel arrangement of the nerve fibers, few collagen fibers, increased vasculature and a number of Schwann cells (Figure 3b). The cross section of the distal segment in the CG appeared to have high thickness of fibrous tissue and

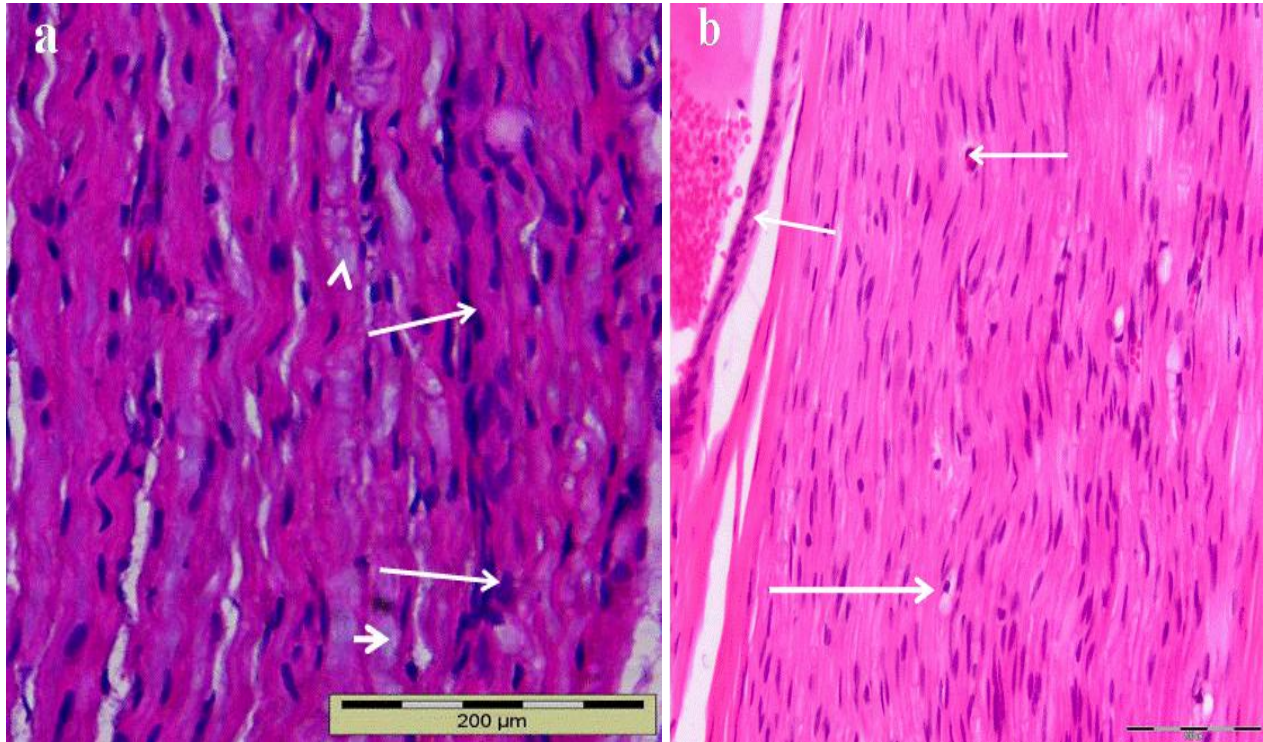


Figure 2. Light micrograph of coaptation site on day 112 PO. (a) mid-segment of CG with the presence of vacuolated degenerative nerve fibers (arrow heads); granulomatous tissue surrounded the stitches and fibroblast cells (arrows); (b) mid-segment of the TG showing high number of Schwann cells, good parallel arrangement nerve fibers and good angiogenesis (thin arrows) and low degenerative nerve fibers (thick arrow).

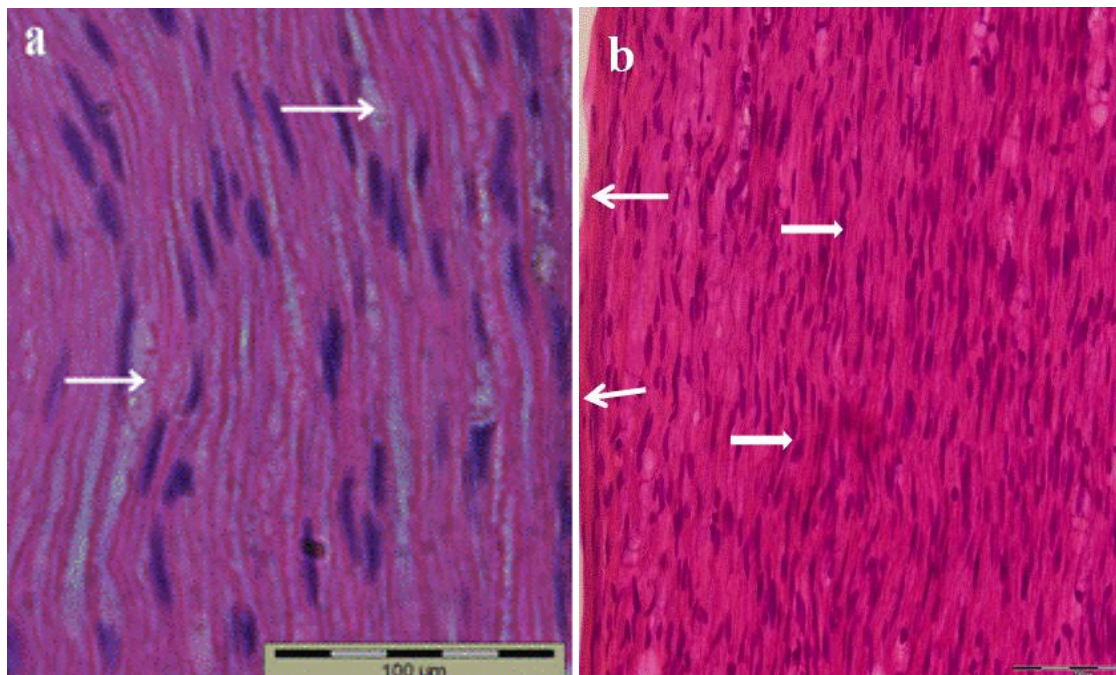


Figure 3. Light micrograph of the distal segment of the sciatic nerve on day 112 PO. (a) Longitudinal section of the CG showing vacuolated degenerative nerve fibers, scar tissue in the epineurium and low numbers of Schwann cells, H & E; (b) the TG showing normal parallel arrangement of the nerve fibers, few collagen fibers (thin arrows) and high density of Schwann cells (thick arrow) (H&E).

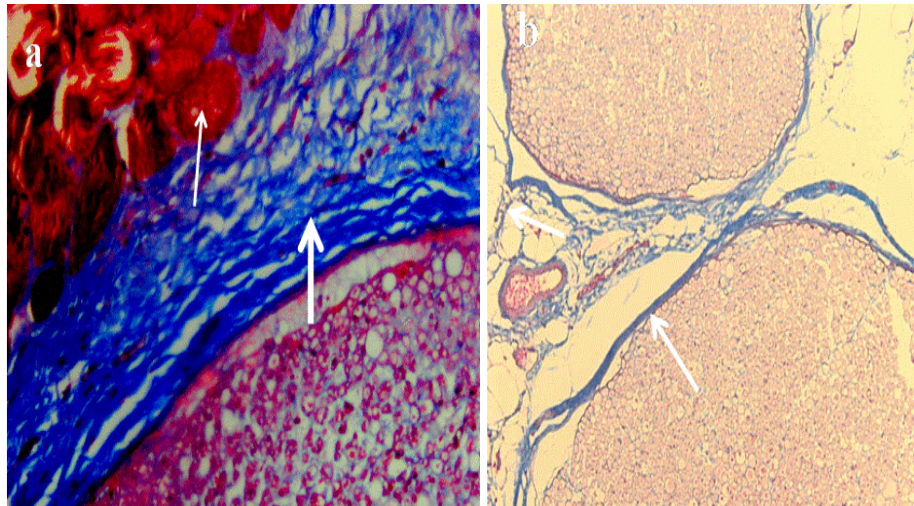


Figure 4. Light micrograph of the transverse section of distal segment of sciatic nerve on day 112 PO. (a) The section of the CG showing thickness of fibrous tissue at perineurium and epineurium (thick arrow) attached with surrounding muscles (thin arrow) (X 200); (b) the TG showing the thin layer of peri and epineurium connective tissue (arrow); Meyer's modified trichrome stain X100.

proliferation of fibroblast at perineurium and epineurium, attached with surrounding muscle (Figure 4a). The TG sections showed a thin epi-perineurium sheath and minimum scar tissues (Figure 4b). Semithin transverse sections of the distal segment in the CG showed thickness of internal perineurium and extraneural nerve fibers at perineurium (Figure 5a); the sections of the distal segment in the TG showed different sizes of myelinated fibers with good fasciculation (Figure 5b).

Histomorphometric analysis on day 112 post operation

Analysis of the proximal segment sections showed that the number of myelinated nerve fibers and fiber diameter did not show a significant difference ($p \leq 0.05$) in the TG compared to the negative control. However, there was a significant ($p \leq 0.05$) decrease in the number of myelinated nerve fibers in the CG compared to TG. The axon diameter and myelin sheath thickness in the TG sections did not show a significant difference ($p \leq 0.05$) compared to the negative control while there was a significant ($p \leq 0.05$) increase in the TG compared to CG. Analysis of the distal segment sections showed that the number of myelin nerve fibers was not significantly different ($p \leq 0.05$) in the TG compared to the negative control group. The fiber diameter, axon diameter and myelin sheath thickness in the CG and TG were significantly ($p \leq 0.05$) decreased compared to that of the negative control group (Table 1).

The distal segment sections showed a decrease in the number of myelin nerve fibers and diameter of myelinated

nerve fibers compared to the proximal segment especially in the TG compared to the CG. The axon diameter and myelin sheath thickness in the proximal segment were greater in the TG group compared to the CG. The g ratio in the distal segment was decreased compared to the proximal segment in TG. The transection of the sciatic nerve produced a loss of neural innervation of the gastrocnemius muscle, which led to a decrease in gastrocnemius muscle mass. The statistical analysis of RGMW showed 0.57 ± 0.01 in the CG sections compared to 0.81 ± 0.04 in the TG at day 112 PO.

DISCUSSION

Results of this study show that the onset of movement of limb and animals walking early developed in the TG compared to the CG. The omentum used in this study could secrete analgesic substances such as opioids, neurotransmitters including gamma aminobutyric acid (GABA), norepinephrine and other monoamines in their roles in the modulation of pain. Agner et al. (2001) reported the role of analgesic substance in the mechanism of modulation of pain. However, the knuckling disappeared in all animals in the TG and this might be due to the role of omentum effectiveness functional recovery on the transected sciatic nerve on day 112 PO, which enhanced early innervation of the extensor and flexor muscle that controls normal locomotion of the limb. Harman-Boehm et al. (2007) reported that the omentum is rich in macrophages and mononuclear cells and that the macrophage is essential for successful nerve

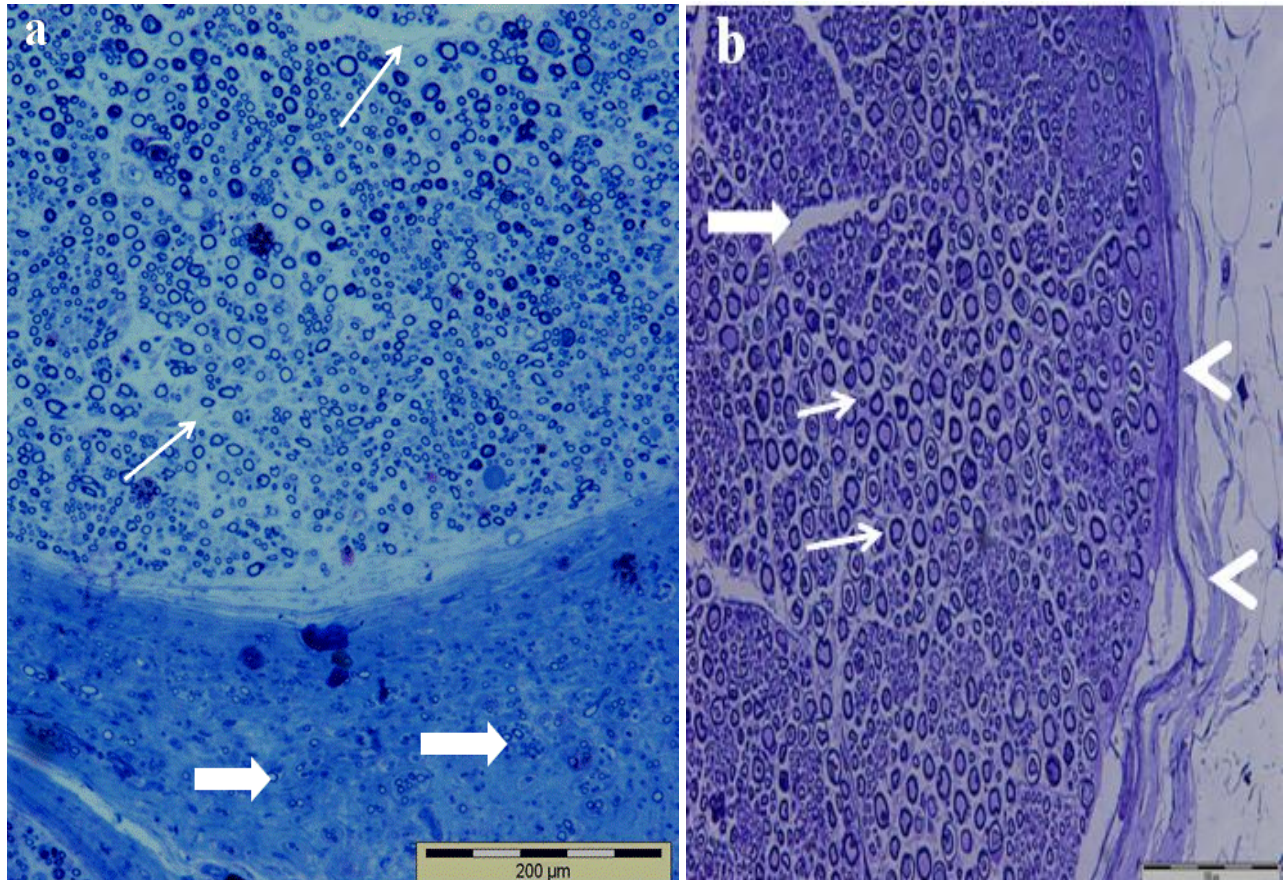


Figure 5. Light micrograph of the distal segment of sciatic nerve on day 112 PO. (a) 5 mm distal coaptated site of the CG illustrating thickness of internal perineurium (thin arrow), extraneurial nerve fibers (thick arrows) and thick collagen fibers deposit in the epineurium (1 μ m section); Toluidine blue; (b) 5 mm distal of coaptated site of the TG showing normal myelination and well distribution of nerve fibers (thin arrows), fasciculation with normal perineurium (thick arrow) and normal epineurium (arrow heads).

Table 1. Statistical analysis of mean values of the fibers number, fiber diameter, myelin thickness, axon diameter and g ratio of the negative control, CG and TG on day 112 PO.

Sample	Negative control	CG	TG
Proximal			
Number of fibers	13292 \pm 1091 ^a	8435 \pm 406 ^b	12730 \pm 692 ^a
Diameter of the fibers (μ m)	10.352 \pm 0.73 ^a	6.14 \pm 1.90 ^b	7.70 \pm 1.39 ^{ab}
Thickness of the sheath (μ m)	3.472 \pm 0.41 ^a	2.28 \pm 0.85 ^b	2.60 \pm 0.54 ^{ab}
Diameter of the axons (μ m)	6.86 \pm 0.28 ^a	3.86 \pm 1.69 ^b	5.10 \pm 0.91 ^{ab}
g ratio	0.66 \pm 0.07 ^a	0.62 \pm 0.08 ^a	0.66 \pm 0.03 ^a
Distal			
Number of fibers	13292 \pm 1091 ^a	8072 \pm 52 ^b	10923 \pm 570 ^a
Diameter of the fibers (μ m)	10.352 \pm 0.73 ^a	4.56 \pm 1.94 ^b	6.226 \pm 1.64 ^b
Thickness of the sheath (μ m)	3.472 \pm 0.41 ^b	1.73 \pm 0.73 ^a	1.95 \pm 0.73 ^a
Diameter of the axons (μ m)	6.86 \pm 0.28 ^a	3.03 \pm 1.30 ^b	4.27 \pm 1.09 ^b
g ratio	0.66 \pm 0.07 ^a	0.63 \pm 0.02 ^a	0.68 \pm 0.06 ^a

^{a,b,c} Means (n=5) with different superscript within same row are significantly different at (p < 0.05) compared to negative control (right hind limb).

regeneration by release growth factors and cytokines that stimulate Schwann cell proliferation.

The muscle contraction force and muscle mass atrophied were related with muscular denervation and muscle disuse, increased muscle mass was attributed to the progress of the motor function of the sciatic nerve. Neurometesis of sciatic nerve reduced muscle contraction force and muscle mass early, therefore the TG animals regained their muscle force contraction and muscle mass more rapidly than in the CG. A study by Burnett and Zager (2004) mentioned that the reinnervation of denervated muscle might regain muscle mass and muscle contraction force.

The degree of sensory reflexes included spreading of toe which increased from day to day, gradually regaining function involving the second, third and fourth toes, which is in agreement with the report by Schmitz and Beer (2001) who described the gradual return of the peroneal nerve function. This index might be applicable to the monitoring of recovery in an animal to express differences in the final degree of recovery. Therefore, in a study of the recovery of the sciatic nerve in rabbits, the reliability and desensitization of the toe-spreading reflex is evaluated as a sign of functional recovery alongside concurrent muscle weights. Improvement of motor and sensory functions could indicate that regenerating nerve fibers grow out through the site of coaptation due to low intraneural fibrosis. The absorption action of the omentum decreases the level of fibrinogen and fibrin production derived from fibrinogen, which leads to decreased fibrosis (scar) at the coaptation site of the transected sciatic nerve. Decreased fibrosis will facilitate the extension and direction of axons to align and orientate correctly. This result is similar to the findings of Al-Timmemi et al. (2010) who showed that omental pedicle transposition had more newly developed nerve fibers and less scar tissue.

The histological sections findings of the coapted sciatic nerve in the TG showed considerable improvement and acceleration of transected sciatic nerve compared to the CG. Meanwhile, the CG histology of transection of injured sciatic nerve showed that the nerve fibers challenged both regeneration and axon path finding to the target organ because of the disruption of the endoneurial sheath with loss of axon alignment. This increased the proportion of extra-fascicular regenerating axons, and more fiber misdirection to the target organs. The continuous degeneration and deposition of collagen induced a retardation of the myelination process. This result is consistent with Dilley et al. (2003) which reported that the extraneural fibrosis and wound-bed adhesions may tether the suture site and adjacent nerve bed. The coapted sciatic nerve in the TG showed more progress of normal parallel orientation of the nerve fibers, few collagen fibers, increased vasculature and increased number of Schwann cells. The increase of Schwann cells resulted from the high concentration of stem cells in

the omental adipose tissue. It is reported that adipose tissue contains a large number of stromal stem cells (Zuk et al., 2001), which are directly released from this tissue to the transected sciatic nerve. Effectively, increased angiogenesis, vascular endothelial growth factor (VEGF), fibroblast growth factors (FGF) and proximity to associated nerve tissue combined to stimulate differentiation of stem cells into Schwann cells.

Total number of myelinated nerve fibers in the proximal and distal stumps of the nerve fibers studied showed a significant decrease ($p \leq 0.05$) in the number of fibers across day 112 PO in all groups. Assessment of the healing process of the distal segment is very vital in the interpretation of the outcome of treatments given. This is because the distal segment is more severely affected by the degenerative (Wallerian) effects of incision as well as inflammatory and collagenation response to such nerve injuries (Stoll et al., 2002). The proximal stumps generally have higher nerve fiber number values above those of the distal. Such difference results from the anatomical positioning of the stumps in direct relation to the neuron, which aids in the axoplasm transport for the nourishment of the neuron by serving as a source of neurotrophic factors (Yin et al., 1994). Nerve fiber diameter is an indicator of the level of maturation of a nerve fiber (Giannini et al., 1989). An assessment of the nerve fiber is a good parameter for measuring the healing process of an injured nerve (Chamberlain, 1998).

The proximal stump generally has higher values for the diameter measurements in all the groups, which gives credence to the reports of growth in the direction of the distal stump from the proximal (Madison et al., 1992). The individual values for the diameter of the proximal stump are higher than those of earlier reports revealing that they were much smaller in size than the distal stump during the healing period (Sanders, 1948). The increased diameter is influenced by the establishment of the connection between the regenerative nerve fibers and end-organs. Somatic motor fibers, which gain connection with muscles, become much larger than those which fail to make such a connection (Gordon et al., 1997; Munson et al., 1997), possibly associated with the uptake of neuro-trophic factors from the active target organ (Mendell et al., 1994).

The myelin thickness and axon diameter in normal nerve healing process is a positive relationship of the mature myelinated nerve fiber population which exists between the axon caliber and the myelin sheath thickness of such nerves as demonstrated in earlier morphometric studies (Hildebrand and Hahn, 1978; Fraher, 1992). Nerve fiber regeneration begins as thin, non-myelinated fibers which progress gradually through the regeneration of complete myelin sheaths with associated Ranvier nodes (Young, 1942). This mechanism was observed in this study where there was a general decrease across groups and times below the normal recorded values for the negative control in both the proximal and

distal stumps. The improved healing observed in the TG is the result of the ability of the omental pedicle to secrete neurotrophic and neurotropic factors as well as clear the injury site of scar tissues and debris (rich phagocytic activity). The g ratio is the ratio of axonal diameter to the total fiber diameter (axon diameter/fiber diameter) and is thus reflective of the myelin sheath thickness and the progress of maturation (Perrot et al., 2007).

In this study, both the proximal and distal stumps of all the groups exhibited approximation of normal on day 112 PO. However, the TG was better off in the healing process using this parameter when compared to the CG histological although statistical analyses revealed no significant difference between them.

The relative gastrocnemius muscle weight shows that the immediate peripheral target organ of the sciatic nerve is the gastrocnemius muscle. An assessment of the relative weight of this muscle over time following transection and/or treatment indicates the regenerative status of the sciatic nerve. Since atrophy ensues immediately post-nerve injury thereby decreasing the weight of the muscle target organ, a comparison between the study groups showed that the TG had a better relative muscle weight ratio than the CG.

In conclusion, the surgical and motor and sensory clinical signs included were more improved compared with CG. The histopathological examination showed the absence of degenerative nerve fibers, increased Schwann cells, parallel arrangement of nerve fibers, minimal scar tissue formation and good myelination in TG. The morphometric analysis showed increase in the number of myelinated nerve fibers, fiber diameter, axon diameter and myelin sheath thickness compared with CG, also, TG had better g ratio value. Gastrocnemius muscle atrophy was low in TG compared with CG group. The result shows that TG was better in peripheral nerve regeneration and functional recovery.

ACKNOWLEDGEMENTS

Authors would like to thank the Electron Microscope staff for collaboration in the preparation of semithin sectioning and are grateful to the Histology Laboratory staff.

REFERENCES

- Abramoff MD, Magelhaes PJ, Ram SJ (2004). Image processing with Image. *J. Biophotons Int.* 11: 36-42.
- Agner C, Yeomans D, Dujovny, M (2001). The neurochemical basis for the application of the greater omentum in neurosurgery. *Neuro. Res.* 23: 7-15.
- Al-Timmemi HA, Ibrahim R, Zuki AZ, Azmi TI (2010). Effects of omental pedicle transposition on regeneration of neurotmesis sciatic nerve in rabbit. *Pertanika. J. Trop. Agric. Sci.* 33: 145-150.
- Burnett M, Zager E (2004). Pathophysiology of peripheral nerve injury: a brief review. *Neurosurg. Focus*, 16: 1-7.
- Chamberlain LJ (1998). Influence of implant parameters on the mechanisms of peripheral nerve regeneration. Ph.D. thesis, Massachusetts Institute of Technology, Cambridge, MA.
- Dille A, Lynn B, Greening J, DeLeon N (2003). Quantitative *in vivo* studies of median nerve sliding in response to wrist, elbow, shoulder and neck movements. *Clin. Biomech.* 18: 899-907.
- Dux K (1989). Proliferative activity of macrophages in the greater omentum of the mouse in relation to the early postnatal development of the vascular structures. *J. Leuke. Biol.* 40: 445-458.
- Fraher JP (1992). Myelin-axon relationships in the rat phrenic nerve longitudinal variation and lateral asymmetry. *J. Comp. Neuro.* 23: 551-557.
- Giannini C, Lais A, Dyck PJ (1989). Number, size, and class of peripheral nerve fibers regenerating after crush, multiple crush, and graft. *Brain Res.* 500: 131-138.
- Gordon T, Tyreman N, Rafuse VF, Munson JB (1997). Fast-to-slow conversion following chronic low-frequency activation of medial gastrocnemius muscles in cats. I. Muscle and motor unit properties. *J. Neurophys.* 77: 2585-2604.
- Harman-Boehm I, Blüher M, Redel H, Sion-Vardy N, Ovadia S, Avinoach E, Shai I, Klötting N, Stumvoll M, Bashan N, Rudich A (2007). Macrophage infiltration into omental versus subcutaneous fat across different populations: effect of regional adiposity and the co-morbidities of obesity. *J. Clin. Endocrinol. Metab.* 92: 2240-2247.
- Hildebrand C, Hahn R (1978). Relation between myelin sheath thickness and axon size in spinal cord white matter of some vertebrate species. *J. Neuro. Sci.* 38: 421-434.
- Lundborg GA (2000). 25-year perspective of peripheral nerve surgery: evolving neuroscientific concepts and clinical significance. *J. Hand Surg. Am.* 25: 391-414.
- Madison RD, Archibald SJ, Krarup C (1992). Peripheral nerve injury. In *Wound Healing: Biochemical and Clinical Aspects.* Cohen IK, Diegelmann RF and Lindblad WJ (Eds.). Philadelphia: W.B. Saunders. pp. 450-487.
- Mendell LM, Collins WF, Munson JB (1994). Retrograde determination of motoneuron properties and their synaptic input. *J. Neurobi.* 25: 707-721.
- Mironiv VA, Gusev SA, Baradi AF (1979). Mesothelial stomata overlying omental milky spots: scanning electron microscopic study. *Cell Tissue Res.* 201: 327-330.
- Munson JB, Foehring RC, Mendell LM, Gordon T (1997). Fast-to-slow conversion following chronic low-frequency activation of medial gastrocnemius muscles in cats. I. Motoneuron properties. *J. Neurophys.* 77: 2600-2605.
- Perrot R, Lonchamp P, Peterson AC, Eyer J (2007). Axonal neurofilaments control multiple fiber properties but do not influence structure or spacing of nodes of Ranvier. *J. Neurosci.* 27: 9573-9584.
- Robinson LR (2004). Traumatic injury to peripheral nerves. *Suppl. Clin. Neurophys.* 57: 173-86.
- Sanders F (1948). The thickness of the myelin sheaths of normal and regenerating peripheral nerve fibres. *Proc. R. Soc. Lond.* 135: 323-357.
- Schmitz 1, Beer G (2001). The toe-spreading reflex of the rabbit revisited functional evaluation of complete peroneal nerve lesions. *Lab. Anim.* 35: 340-345.
- Stoll G, Jander S, Myers R (2002). Degeneration and regeneration of the peripheral nervous system: from Augustus Waller's observation to neuroinflammation. *J. Peri. Neuro. Surg* 7: 13-27.
- Yin QW, Johnson J, Prevette D, Oppenheim RW (1994). Cell death of spinal motoneurons in the chick embryo following deafferentation: rescue effects of tissue extracts, soluble proteins and neurotrophic agents. *J. Neurosci.* 14: 629-7640
- Young JZ (1942). Functional repair of nervous tissue. *Phys. Rev.* 22: 318-374.
- Zuk PA, Zhu M, Mizuno H, Huang J, Futrell JW, Katz AJ, Benhaim P, Lorenz HP, Hedrick MH (2001). Multilineage age cells from human adipose tissue: implication for cell-based therapies. *Tissue Eng.* 7: 211-228.