

Full Length Research Paper

Haematological evaluation of Wistar rats exposed to chronic doses of cadmium, mercury and combined cadmium and mercury

Hounkpatin, A. S. Y.^{1*}, Etorh, P. A.^{1,2}, Guédénon, P.¹, Alimba, C. G.³, Ogunkanmi, A.³, Dognon, T. V.¹, Boni, G.¹, Aissi, K. A.¹, Montcho, S.¹, Loko, F.⁴, Ouazzani, N.⁵, Mandi, L.⁵, Boko, M.¹ and Creppy, E. E.⁶

¹Interfaculty Centre of Training and Research in Environment for Sustainable Development (CIFRED), University of Abomey-Calavi, 03 BP 1463, Cotonou, Benin.

²Departement of Biochemistry and Cellular Biology, University of Abomey-Calavi, 01BP 526 Cotonou, Benin.

³Department of Cell Biology and Genetics, Faculty of Science, University of Lagos, Nigeria

⁴Polytechnic School of Abomey-Calavi, Research Laboratory in Applied Biology, University of Abomey-Calavi, 01 BP 2009 Cotonou, Benin.

⁵Laboratory of Hydrobiology, Ecotoxicology and Cleansing, Department of Biology, Faculty of Science Semlalia, University Cadi Ayyad, BP 2390, Marrakech, Morocco.

⁶Laboratory of Toxicology and Applied Hygiene/UFR of Pharmaceutical Sciences, 146, Road Leo Saignat, 33076 Bordeaux Cedex, France.

Accepted 10 May, 2013

Cadmium and mercury present in the environment, cause blood disorders. This study was conducted to evaluate the influence of cadmium, mercury and their combination on hematological parameters of Wistar rats. For this purpose, two different doses of each metal and their combination were administered orally for 28 days to six groups of five rats each. Two groups (A and B) were respectively exposed to CdCl₂ (0.25 and 2.5 mg/kg), two other groups (C and D) respectively received HgCl₂ (0.12 and 1.2 mg/kg) and the last two groups (E and F) were respectively treated with the combination of these two metals: (0.25 mg/kg Cd + 0.12 mg/kg Hg) and (2.5 mg/kg Cd + 1.2 mg/kg Hg). The control group (G) received the same volume of distilled water. At the end of exposure, bodies of rats were weighed and the whole blood was collected by retro-orbital sinus method for analysis of hematological parameters. The results of this study show a significant decrease ($p < 0.05$) in white blood cells (WBC) in the lot treated with the combination (0.25 mg/kg Cd + 0.12 mg/kg Hg) and also indicate a significant decrease ($p < 0.05$) in WBC, red blood cells (RBC), hemoglobin concentration (HGB) and the mean corpuscular hemoglobin concentration (MCHC) with high levels of mercury (2.5 mg/kg) and the combination (2.5 mg/kg Cd + 1.2 mg/kg Hg). An increase in the number of platelet count (PLT) in all intoxicated lots was observed.

Key words: Cadmium, mercury, hematology, blood parameters, rats.

INTRODUCTION

Heavy metals are hazardous substances that cause serious health risk to ecosystems and organisms due to

their high toxicity conferred by nature of their environmental persistence (Abbas, 2002). Mercury ecosystem by

mercury and people consuming seafood are major concerns of health organizations since the Minamata disaster (Takizawa and Osame, 2001). Estimates made in populations deriving their livelihoods from fishing have shown that between 1.5 and 17 children in 1000 showed cognitive impacts due to consumption of fish containing mercury (OMS, 2010). Contamination of fish with methyl-mercury has been shown by research (Lindqvist et al., 1991). Research works also revealed the presence of high doses of other contaminants, particularly cadmium, in fish, shrimp (Guédénon et al., 2012a; Hounkpatin et al., 2012a, b) and other staple food such as drinking water (Adam et al., 2010), vegetables (Dougnon et al., 2012), seafood and giant snails (Edorh et al., 2009). Studies by Guédénon et al. (2012b) showed that fish contamination by cadmium and mercury is directly linked to the presence of these two metals in the environment. Cadmium and mercury have no known biological function (Seymore, 1994), and cause many diseases when accumulated in the body from food. Cadmium is toxic to humans, excessive exposure can cause death (Othumpangat et al., 2005). It enters cells and accumulates in high concentrations in cytoplasmic and nuclear space (Andujar et al., 2010). It has been observed to have a high affinity for the liver and kidneys (Cai et al., 2001). The classic symptoms of mercury contamination are carcinogenicity and/or damage to kidney function, visual, metabolic, reproductive, neurological and immunological (OMS, 2010; Mergler et al., 2007). The toxicity of mercury is directly assimilated by living organisms and bioaccumulate in the food chain (Mergler et al., 2007; Guimarães et al., 2000). After ingestion of contaminated food, over 90% of mercury is absorbed through the gastrointestinal wall, and then transferred into the body through the bloodstream and after 4 days, diffused throughout the human body. The brain has the special focus of this element especially in lipid molecules, with mercury (Hg) concentrations being up to 6 times higher than those measured in the blood (Kjellstrom et al., 1989). The methyl-mercury is a very active neurotoxin that can pass into the blood and across cell membranes. These properties provide a stable period with a relatively long half-life: 70 days in the blood (Picot and Proust, 1998). The alterations in haematological changes serve as the earliest indicators of toxic effects on tissue (Paprikar, 2003). Blood is the most important tissue, in which changes in metabolic processes are reflected, therefore, abnormal alteration in blood parameters are the reliable indicator of toxic effects of drugs, chemicals and diseases (Lodia and Kansala, 2012)

Mercury and cadmium has been recognized as a biological toxicant. They are widely dispersed in the environment and are, with excessive levels, toxic to humans (Jarup, 2003). Absorbed cadmium and mercury following oral ingestion is carried via blood to soft tissues. In this respect, the present study was designed to evaluate the toxic effects of cadmium, mercury and their combination on the disruption of hematology in Wistar rats.

MATERIALS AND METHODS

Biological material

The animal material was composed of 35 male albino Wistar rats weighing about 108 ± 25 g. These rats were obtained at the Animal Breeding Unit of the University of Lagos, Nigeria and were acclimated for two weeks before the experiments. They were placed in designed sterile polypropylene cages in room temperature (25 to 30°C) with relative humidity of $60^\circ\text{C} \pm 5\%$. The cages were illuminated with a sequence of 12 h light and 12 h darkness. Animals had free access to water and standard rodent laboratory chow (Ladokun feed Nigeria®) *ad libitum*, in the animal "Botanical and Zoological Garden" in the University of Lagos.

Chemicals and preparation of different solutions

The chemicals tests used for the experiment were cadmium chloride and chloride anhydrous of mercury. The powdered mercuric chloride ($\text{HgCl}_2 = 271.50$; minimum assay: 98%) and cadmium chloride ($\text{CdCl}_2 = 183.32$; minimum assay: 99%) were purchased from "General Purpose Reagent BDH Chemicals Ltd. Poolo England". Concentrations were prepared for the experiment: 0.25 and 2.5 mg/kg for cadmium chloride and 0.12 and 1.2 mg/kg for mercuric chloride. The different solution concentrations were based on different daily doses, the average weight of each lot and the daily volume administered to rats (1 ml).

Distribution of rats and tests

After two weeks of acclimatization, 35 animals were randomly divided into six groups of five rats each and one control group. Cadmium, mercury and their combination were administered by gavage (via stomach tube) for 28 consecutive days following the method of Awodele et al. (2010). The six groups of rats received daily doses of cadmium, mercury and their combination in a final volume of 1 mL of water. The first two groups (A and B) respectively received cadmium chloride (0.25 and 2.5 mg/kg), both groups (C and D) that followed received mercuric chloride (0.12 and 1.2 mg/kg) and the last two groups (E and F) received the combination of these two metals: (0.25 mg/kg Cd + 0.12 mg/kg Hg) and (2.5 mg/kg Cd + 1.2 mg/kg Hg), respectively. The control group (G) received only the same volume of distilled water (Table 1). These different doses of cadmium respectively correspond to a dose producing significant results: 0.25 mg/kg (Ganesh and Satish,

*Corresponding author. E-mail: harmelle2007@yahoo.fr. Tel. 00 (229) 95 49 35 77 / 93 91 64 64.

Abbreviations: WBC, White blood cell count; RBC, red blood cells; HGB, hemoglobin concentration; HCT, haematocrit; MCH, mean corpuscular hemoglobin, MCV, volume of mean corpuscular erythrocyte; MCHC, mean corpuscular hemoglobin concentration; PLT, platelet count; LYM, number of lymphocytes; ROS, reactive oxygen species.

Table 1. Distribution of rats.

Group	Number	Cadmium (Cd) (mg/Kg)		Mercury (Hg) (mg/Kg)		Distilled water (mg/kg)
		0.25	2.5	0.12	1.2	-
A	5	x				
B	5		x			
C	5			x		
D	5				x	
E	5	x		x		
F	5		x		x	
G	5					x

1994) and 10 times this concentration (2.5 mg/kg). As for mercury, 1/10 (1.2 mg/kg) and 1/100 (0.12 mg/kg) of the LD₅₀ (Bharat et al., 2010) were used.

Clinical observations

During the experimental period, the animals were subjected to a clinical examination on a daily basis. Signs such as loss of appetite, refusal to drink, the characteristics of feces (diarrhea or not), occurrence of abscesses, wounds and loss of hair were taken into account.

Blood collection and haematological analysis

After 28 days of exposure, rats were fasted overnight. They were weighed before the collection of blood and sacrifice. All samples were taken between 7 and 9 am to avoid variations due to circadian rhythm. Whole blood was obtained from a puncture of the retro-orbital sinus by the conventional method (Van Herck et al., 1992). Blood samples collected in ethylene diamine tetra-acetic acid (EDTA) anticoagulant tubes (8.5%) was quickly returned by mixing with anticoagulant in the tube. All blood samples were labeled and immediately conveyed to the laboratory for analysis. Hematological parameters were analyzed: white blood cell count (WBC), red blood cells (RBC), hemoglobin concentration (HGB), haematocrit (HCT), the mean corpuscular hemoglobin (MCH), volume a mean corpuscular erythrocyte (MCV), the mean corpuscular hemoglobin concentration (MCHC), platelet count (PLT) and the number of lymphocytes (LYM). All hematological parameters were analyzed in the "Haematology Unit, Lagos state University Teaching Hospital (ULTH)" using the automated method with the automatic analyzer "Haematology auto analyzer Sysmex KX-21N".

Statistical analysis

Results are expressed as mean \pm SEM of n experiments (where n represents the number of animals used). The differences between the treated and control rats were evaluated using the Students t-test $p (T > t) = 0.05$. The software used was Microsoft Excel 2010 and XL Stat 2011. The differences were statistically significant if the value of $p < 0.05$ and not significant if the value of $p > 0.05$.

RESULTS AND DISCUSSION

During the exposure period, the rats showed clinical signs of toxicity. Group of rats (D) treated with the high concentration of mercury, showed an appearance of abscesses on the cheek (Figure 1) and loss of hair on the arm (Figure 2). For the group of rats (F) treated with the combination of the high concentration of cadmium and mercury, loss of hair on the back (Figure 3) and a wound on the tail (Figure 4) was observed. Similar observations were made by Alimba et al. (2012) which noted hair loss and appearance of abscesses in rats exposed to landfill leachate containing heavy metals after analysis. Similarly, Boujelbene et al. (2002) after experiments confirmed that the bristles are a reliable biomarker of exposure to highlight cadmium intoxication.

The mean and standard deviation of the blood parameters of the blood of rats exposed to cadmium, mercury and cadmium and mercury in combination at various concentrations are shown in Table 2. For WBC, there was a significant decrease (9.85 ± 0.49) in animals of groups D, E and F compared to control group G. For RBC, we noticed a significant decrease in animals of groups D, F compared to the control group G. HGB decreased significantly in the blood of rats of groups D and F relative to the control group G. MCHC decreased significantly in the blood of the rats in groups D and F compared to the control group G. A decrease in HCT and LYM with the high concentration of mercury and the combination of high concentrations of cadmium and mercury was observed. In addition, there was an increase in PLT in all lots intoxicated compared to control group. The results found in this study show that some parameters widely vary depending on the lot of Wistar rats intoxicated with cadmium, mercury and their combination and the control group. This is for example the case of the erythrocyte. Indeed on animals of groups D and F, it reached values of $5.59 \cdot 10^6 / \mu\text{L}$ and $5.46 \cdot 10^6 / \mu\text{L}$ against $8.46 \cdot 10^6 / \mu\text{L}$ with animals of lot G (control). The number of

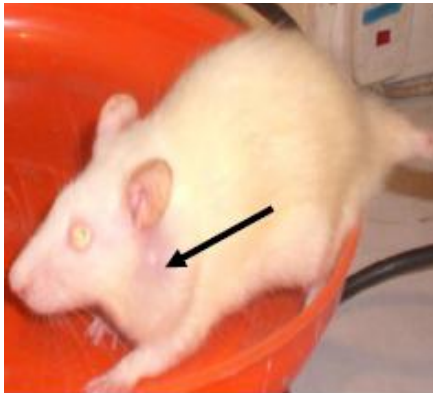


Figure 1. Abscess on the cheek. Rats (Group D) treated with the high concentration of mercury.

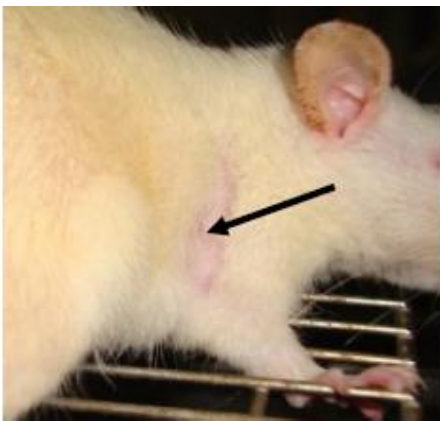


Figure 2. Loss of hair on the arm. Rats (Group D) treated with the high concentration of mercury.

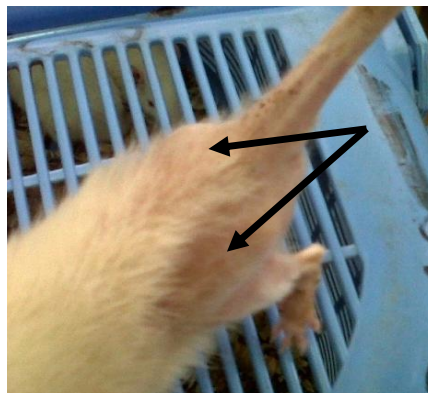


Figure 3. Loss of hair on the back. Rats (Group F) treated with the combination of the high concentration of cadmium and mercury.

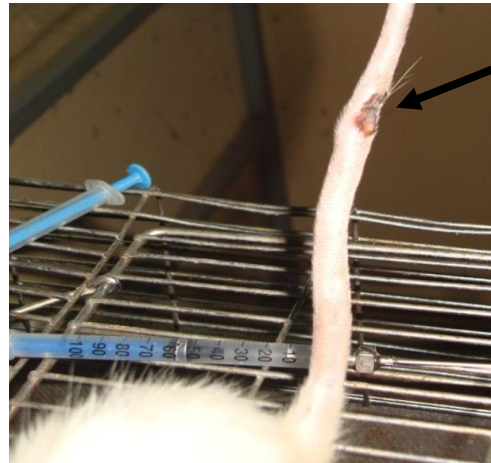


Figure 4. Wound on the tail. Rats (Group F) treated with the combination of the high concentration of cadmium and mercury.

red blood cells obtained from animals in the groups D and F was very low compared to the results of Boukerche et al. (2007) where these authors found $8.45 \cdot 10^6/\mu\text{L}$ as the number of red blood cells in healthy Wistar rats. So the high dose of mercury and the combination of high doses of cadmium and mercury reduce the number of red blood cells causing anemia in Wistar rats intoxicated. These results were proved by Guédénon et al. (2012b) on fish exposed to cadmium and mercury and Kanhiya et al. (2009) in rats treated with mercuric chloride (0.926 mg/kg) orally for 21 days. The number of red blood cell hemolysis decreased due to intoxication (Lavicoli et al., 2003). The red blood cell count in not intoxicated rats (control) was stable and varied a little from one subject to another. Regarding hemoglobin, a similar trend was obtained with the lowest levels in the rats of groups D and F. This decrease in hemoglobin was also found by Lahouel et al. (2004) in rats intoxicated with paracetamol; by Bersenyi et al. (2003) in rabbit lead poisoning by Kanhiya et al. (2009) in rats treated with mercuric chloride (0.926 mg/kg) orally for 21 days, and by Ognjanović et al. (2003) in rats exposed to cadmium chloride. However, the reduction in HGB can be probably due to the production of reactive oxygen species (ROS) under the influence of mercuric chloride and cadmium chloride. This results in the destruction of the red blood cell membrane and its function.

With regard to hematocrit, a similar trend was obtained with the lowest levels in the rats of groups D and F. These results corroborate those of Tadjine et al. (2008) and Bersényi et al. (2003) on rabbits treated with metals. Considering the white blood cells, changes were observed mainly in rats of groups D and F in which the number was lower. These low values are related to the

Table 2. Mean values and standard deviation of the blood parameters of rats exposed to Cd, Hg and Cd + Hg.

Dose	Parameter	Control	Cd	Hg	Cd+Hg
		G	A	C	E
Low	WBC	13.95±0.21	13.55±1.76	10.17±2.32	8.47±1.50*
	RBC	8.46±0.72	7.45±1.76	7.36±0.49	7.18±0.69
	HGB	14.40±0.35	13.60±2.40	13.47±1.57	13.32±1.12
	HCT	47.450±0.07	44.95±8.83	46.47±5.20	45.07±4.84
	MCV	60.30±1.98	61.00±2.54	63.00±4.86	62.87±5.15
	MCH	18.20±0.42	18.50±1.13	18.25±1.40	18.60±1.10
	MCHC	31.30±0.84	30.30±0.56	29.00±1.07	29.60±0.89
	PLT	624.50±16.26	965.00±158.39	768.50±163.59	742.50±94.60
LYM	69.60±10.46	69.00±10.46	69.87±11.96	69.80±6.29	
High	WBC	13.95±0.21	12.50±1.20	9.85±0.49*	8.15± 0.49*
	RBC	8.46±0.72	7.78±0.66	5.59±1.02*	5.46±0.78*
	HGB	14.40±0.35	14.47±0.96	10.37±1.97*	9.65±0.77*
	HCT	47.450±0.07	48.00±3.57	37.55±8.74	35.85±4.73
	MCV	60.30±1.98	61.00±1.91	66.62±5.86	60.50±0.72
	MCH	18.20±0.42	18.60±0.58	18.52±0.48	18.45±0.77
	MCHC	31.30±0.84	30.20±0.29	27.35±1.39*	27.00±0.70*
	PLT	624.50±16.26	901.50±241.41	822.50±378.70	841.00±427.09
LYM	69.60±10.46	71.32±11.02	65.75±5.47	65.30±4.38	

*The difference between the value of blood parameters of the experiment groups and that of the negative control at 0.05. WBC, White blood cells (X103/ μ L); MCV, mean corpuscular volume (fL); RBC, red blood cells (X106/ μ L); MCH, mean corpuscular hemoglobin (pg); HGB, hemoglobin (g/dL); PLT, platelets (X103/ μ L); HCT, hematocrit (%); LYM: lymphocytes (%); MCHC, mean corpuscular hemoglobin concentration (g/dL).

toxic action of mercury and cadmium and mercury combination which can induce leukopenia and thrombocytopenia in cases of severe liver dysfunction (Lee, 2004). These observations were also made by Lodia and Kansala (2012) and Veena et al. (2011) in mice treated with lead. The significant decrease in hemoglobin (10.37±1.97 and 9.65±0.77 g/dL) in rats of groups D and F, associated with a decrease in MCHC (27.35±1.39 and 27.00±0.70 g/L) indicate a tendency to macrocytosis and hypochromia hematopoiesis in the liver which occurs efficiently. Mercury and the combination of high concentrations of cadmium and mercury could inhibit heme synthesis of red blood cells as evidenced by Lodia and Kansala, (2012) and Veena et al. (2011) after lead poisoning. This causes signs of anemia described by Bottomley and Muller-Eberhard (1998). However, red blood cells were low in heme, where there was decrease in mean corpuscular hemoglobin concentration; indicated by our results in rats of groups D and F. The observed decrease in erythrocytes, hemoglobin and haematocrit is consistent with previous studies of anemia by Horiguchi, (2007) and Dhanapakiam and Ramasamy (2001). It was evidenced that the anemia was caused not only by

increased destruction of erythrocytes (Kori-Siakpere et al., 2009) but also by decrease in the synthesis and release of erythrocytes into the blood circulation (Vinodhini and Narayanan, 2008). About heavy metals accumulation in kidney, spleen and liver by the same authors, it is conceivable that heavy metals might have suppressed the activity of these hematopoietic tissues. This idea is supported by the study of Gill and Epple (1993) that attributed the anemia to impaired erythropoiesis caused by a direct effect of metals on haematopoietic centres (kidney/spleen), accelerated erythroclasia due to altered membrane permeability and/or increased mechanical fragility and defective Fe metabolism or failure of intestinal uptake of Fe due to mucosal lesions.

Conclusion

In view of these results, it appears that cadmium chloride and mercuric chloride induce hematological disturbances in rats. A large variation in these parameters from blood was recorded for the high concentration of mercuric chloride and the combination of high concentrations of

cadmium chloride and chloride mercuric. These environmental pollutants known for their effects which are particularly dangerous to human health, are present in the air, soil, water and ricocheted is found in foods of first necessity consumed by humans. Monitoring of these pollutants is necessary for a sustainable environment.

REFERENCES

- Abbas HH, Zaghloul KH, Mousa MA (2002). Effect of some heavy metal pollutants on some biochemical and histopathological changes in Blue tilapia, *Oreochromis aureus*. Egypt. J. Agric. Res. 80(3):1395-1411.
- Adam S, Edoth P, Totin H, Koumolou L, Amoussou E, Aklidikou K, Boko M (2010). Pesticides et métaux lourds dans l'eau de boisson, les sols et les sédiments de la ceinture cotonnière de Gogounou, Kandi et Banikoara (Bénin). Int. J. Biol. Chem. Sci. 3 (5):1141-1150.
- Alimba CG, Bakare AA, Aina OO (2012). Liver and kidney dysfunction in wistar Rats exposed to municipal landfill leachate. Scientific. Academic. Publish. 2(4):150-163.
- Andujar P, Bensefa-Colas L, Descatha A (2010). Intoxication aiguë et chronique au cadmium. Res. Rev. Med Intern. 31(2):107-115.
- Awodele O, Olayemi SO, Alimba CG, Egbejogu C, Akintonwa A (2010). Protective effect of vitamin C and or vitamin E on micronuclei induction by rifampicin in mice. Tanzania. J. Health. Res. 12:2.
- Bersényi A, Fekete SG, Szocs Z, Berta E (2003). Effect of ingested heavy metals (Cd, Pb and Hg) on haematology and serum biochemistry in rabbits. Acta. Vet. Hung. 51 (3):297-304.
- Bharat BP, Atish R, Soumik A, Shelley B (2010). Induction of oxidative stress by non-lethal dose of mercury in rat liver: Possible relationships between apoptosis and necrosis. J. Environ. Biol. 31:413-416.
- Bottomley SS, Muller-Eberhard V (1998). Pathophysiology of the heme synthesis. Pemin. Hematol. 25:282-303.
- Boujelbene M, Gorbil F, Makni-ayadi F, Guermazi F, Kammoun A, Groute F, Soleilhavoup JP, El eki addeltett AH (2002). Impact d'un traitement chronique au cadmium sur la fonction rénale chez le rat : Détermination d'un biomarqueur d'exposition. L'Eurobiologist., 258 (35):3-17.
- Boukerche S, Aouacheri W, Saka S (2007). Les effets toxiques des nitrates : étude biologique chez l'homme et chez l'animal. Ann. Biol. Clin. 65(4):38.
- Cai Y, Aoshima K, Katoh T, Teranishi H, Kasuya M (2001). Renal tubular dysfunction in male inhabitants of a cadmium-polluted area in Toyama, Japanan, eleven-year follow-up study. J. Epidemiol. 11:180-189.
- Dhanapakiam P, Ramasamy VK (2001). Toxic effects of copper and zinc mixture on some haematological and biochemical parameters in common carp, *Cyprinus carpio* (Linn). J. Environ.Biol. 22:105-111.
- Dougnon TV, Edoth PA, Bankolé HS, Dougnon TJ, Montcho SA, Hounkpatin A, Gouissi M, Sossou B, Boko M, Creppy EE (2012). Evaluation of the toxicological quality of the leaves of *Solanum macrocarpum* L. cultivated with the chicken's droppings and water of marsh at Cotonou (Benin). J. Res. Environ. Sci. Toxicol., 1(1):001-006.
- Edoth AP, Agonkphoun E, Gnanadi K, Guédénon P, Koumolou L, Amoussou C, Ayedoun A, Boko M, Gbeassor M, Rihn H, Creppy E (2009). An assessment of the contamination of *Achatina achatina* by toxic metals in Okpara village. Int. J. Biol. Chem. Sci. 3(6):1428-1436.
- Ganesh CJ, Satish KA (1994). Cadmium chloride induces dose dependent increases in the frequency of micronuclei in mouse bone marrow. Sci. Mut. Res. 306:85-90.
- Gill TS, Epple A (1993). Stress-related changes in the haematological profile of the American eel (*Anguilla rostrata*). Ecotoxicol. Environ Saf. 25:227-235.
- Guedenon P, Edoth PA, Kaki C, Yehouenou EPA, Gnanadi K, Montcho S, Hounkpatin A, Koumolou L, Boko M. (2012a). Arsenic, Cadmium, Copper and Lead Accumulation in Water, Sediments and Fish Species of Oueme River in Bonou. British J. Pharm. Toxicol. 4(1):13-20.
- Guedenon P, Edoth PA, Hounkpatin ASY, Alimba CG, Ogunkanmi A, Nwokejiegbe EG, Deguenon Y, Gbeassor M, Creppy EE (2012b). Haematological study of *Clarias gariepinus* exposed to chronic and subchronic doses of cadmium, mercury and combined cadmium and mercury. Sci. Nat. 4(2):2-19.
- Guimarães JRD, Roulet M, Lucotte M, Mergler D (2000). Mercury methylation along a lake-forest transect in the Tapajós river floodplain, Brazilian Amazon: seasonal and vertical variations. Sci. Total Environ. 261:91-98.
- Horiguchi H (2007). Anemia induced by cadmium intoxication, Nihon Eiseigaku Zasshi. Japanese J. Hygien. 62(3):888-904.
- Hounkpatin ASY, Edoth PA, Salifou S, Gnanadi K, Koumolou L, Agbandji L, Aissi KA, Gouissi M, Boko M (2012a). Assessment of exposure risk to lead and cadmium via fish consumption in the lacustrine village of Ganvié in Benin Republic. J. Environ. Chem. Ecotoxicol. 4(1):1-10.
- Hounkpatin AS, Edoth PA, Sézonlin M, Guédénon P, Elégbédé B, Boni G, Dougnon V, Montcho S, Kéké E, Boko M (2012b). Pollution of aquatic ecosystems by heavy metals at Ganvié's lacustrine city (Benin). Int. Res. J. Biotechnol. 3(6):81-87.
- Jarup L (2003). Hazards of heavy metal contamination. Br. Med. Bull. 68:167-82.
- Kanhiya M, Prabhu NS (2009). Assessment of haematotoxic potential of mercuric chloride in rat. J. Environ. Biol. 30 (5):927-928.
- Kjellstrom T, Kennedy P, Wallis S, Stewart A, Friberg L, Lind B, Wutherspoon T, Mantell C (1989). Physical and mental development of children with prenatal exposure to mercury from fish. Stage II. Interviews and psychological tests at age 6, Solna. Nat. Swedish. Environ. Protect. Board. Report. 3642.
- Kori-Siakpere O, Ogbé MG, Ikomi RB (2009). Haematological response of the African cat fish *clarias gariepinus* (Burchell,1822) to sub-lethal concentrations of potassium permanganate. Sci. Res. Essay. Academic J. 4(5):457-466.
- Lahouel M, Boukour S, Segueni N, Fillastre JP (2004). Effet protecteur des flavonoïdes contre la toxicité de la vinblastine, cyclophosphamide et du paracétamol par inhibition de la peroxydation lipidique et augmentation du glutathion hépatique. J. Pat. Bio. 10:314-322.
- Lavicoli I, Carelli G, Stanek EJ, Castellino N, Calabrese EJ (2003). Effects of low doses of dietary lead on red blood cell production in male and female mice. Toxicol. Lett. 137:193-199.
- Lee WM (2004). Acetaminophen and the US acute liver failure study group: Lowering the risks of hepatic failure. Hepatology. 40:6-9.
- Lindqvist O, Johansson K, Aastrup M, Andersson A, Bringmark L, Gunnar-Hovsenius G (1991). Mercury in the swedish environment recent research on causes, consequences and corrective methods. Water Air Soil Pollut. 55:261.
- Lodia S, Kansala L (2012). Antioxidant activity of *rubia cordifolia* against lead toxicity. Int. J. Pharmacol. Sci. Res. 3(7):2224-2232.
- Mergler D, Anderson HA, Chan LHM, Mahaffey KR, Murray M, Sakamoto M, Stern AH (2007). Methylmercury Exposure and Health Effects In Humans. Worldwide Concern. Ambio. 36 (1):3-11.
- Ognjanović BI, Pavlović SZ, Maletić SD, Zikić RV, Stajin AS, Radojčić RM, Sačić ZS, Petrović VM (2003). Protective influence of vitamin E on antioxidant defense system in the blood of rats treated with cadmium. Physiol. Res. 52(5):563-570.
- OMS (2010). Exposure to mercury: a major public health concern. WHO Training 20 Avenue Appia, CH-1211 Geneva - 27, Switzerland. 4p.
- Othumpangat S, Kashon M, Joseph P (2005). Eukaryotic translation initiation factor 4E is a cellular target for toxicity and death due to exposure to cadmium chloride. J. Biol. Chem. 280:162-169.
- Paprikar MV, Sharma BB (2003). J. Cell. Tissue. Sci. Mut. Res. 31:12-17.
- Picot A, Proust N (1998). Mercury And Its Compounds: from speciation to toxicity. Actualit. Chim. 4:16-24.

- Seymore T (1994). Bioaccumulation of metals in *Barbus marequensis* from the Olifants River, Krugar National Park and lethal levels of manganese to juvenile *Oreochromis mossambicus*. M. Sc. Thesis. Rand. Afrikaans University, South Africa.
- Tadjine A, Djerar H, Courtois A (2008). Toxicité des poussières rejetées par le complexe sidérurgique d'Annaba sur quelques paramètres hématologiques du lapin Européen. *Environ. Risque Sante*. 7:3.
- Takizawa Y, Osame M (2001). Understanding Minamata Disease: Methylmercury Poisoning in Minamata and Niigata Japan. Tokyo: Japan Public. Health. Assoc. pp. 27-32.
- Van Herck H, Baumans V, Van Der Craats NR (1992). Histological changes in the orbital region after orbital puncture. *Lab. Anim.* 26:53-58.
- Veena S, Leena K, Arti S, Shweta L, Sharma SH (2011). Ameliorating Effect of *Coriandrum sativum* Extracts on Hematological and Immunological Variables in an Animal Model of Lead Intoxication. *J. Pharm. Allied. Health Sci.* 1:16-29.
- Vinodhini R, Narayanan M (2008). Bioaccumulation of heavy metals in organs of fresh water fish *Cyprinus carpio* (Common Carp). *Int. J. Environ. Sci. Technol* 5(2):179-182.