

Full Length Research Paper

Reversal of experimental varicocele-induced testicular toxicity by L-ascorbate in rats

Saalu, L. C.^{1*}, Oguntola, J. A.¹, Babalola, O. S.¹ and Oyewopo, A. O.²

¹Department of Anatomy, Lagos State University College of Medicine (LASUCOM) Ikeja, Lagos, Nigeria.

²Department of Anatomy, College of Health Sciences, University of Ilorin, Nigeria.

Accepted 16 December, 2008

Varicoceles are the abnormal tortuosity and dilatation of the veins of the pampiniform plexus that drain the testis. Varicoceles are variously considered the commonest “correctable” cause of infertility or the commonest “reported” cause of infertility depending on individual viewpoint. Even though the pathophysiology of testicular damage in varicocele has not been completely understood, there is an increasing body of evidence pointing towards the role of reactive oxygen species (ROS) and oxidative stress in the pathogenesis of varicocele related subfertility. In this study we investigated the role of L-ascorbate (vitamin C) as an antioxidant in rejuvenating the testis following its damage in experimental varicocele. Thirty male Sprague- Dawley weighing 150-200 g were divided into three groups. While the first group had sham operations, experimental varicoceles were established by complete ligation of the left and right main spermatic vein in the later two groups. The third group in addition to varicocele induction had daily gavage administration of 8 mg/kg body weight vitamin C for fifty six days. All animals were sacrificed by decapitation fifty six days after varicocele induction. Testicular weights, testicular volumes, caudal epididymal sperm characteristics, testicular histology and serum hormone levels were evaluated. Results showed that the testes of the rats that were given vitamin C post experimental varicocele had better physiological, biochemical and histological profiles than those of the untreated animals. These results indicate the potency of vitamin C for modulating testicular toxicity in varicocelelized animals.

Key words: Varicocele, ascorbic acid, testis, infertility.

INTRODUCTION

Varicocele, the abnormal tortuosity of the veins of the pampiniform plexus that drains the testis, is one of the main causes of male infertility. In a World Health Organization multicentre study on 9043 infertile couples, varicocele was found in 25.4% of men with abnormal semen, compared with 11.7% of normal semen (WHO, 1992). It was shown that the presence of grade 1 varicocele in adolescence appears to have no effect on normal testicular growth, but patients with grade 2 varicocele are at risk of unilateral testicular volume loss and grade 3 varicocele, of bilateral testicular volume loss (Kass et al., 2001). However the pathogenesis of testicular damage or the mechanism of which varicocele produces sperm dysfunction has not been clearly iden-

tified yet (Santoro et al., 2001). The proposed mechanisms include testicular hypoxia by venous stasis and small vessel occlusion, leading to Leydig cell and germinal cell dysfunction, increased testicular and scrotal temperature and decrease in gonadotrophin and androgen secretion (Hudson, 1988). Irrespective of the infertility status, it was identified that there is a strong relationship between sperm dysfunction and varicocele (Lewis et al., 1995; Hendin et al., 1999). Varicocele is associated with increased production of spermatozoal reactive oxygen species (ROS). Indeed, Hendin et al. (1999) reported a 4-fold increase in the frequency of elevated ROS generation in the incidental varicocele group compared to their control patients. ROS are species such as superoxide, hydrogen peroxide, and hydroxyl radical and are associated with cell damage.

A characteristic feature of most, if not all, biological membranes is an asymmetrical arrangement of lipids within the bilayer. The lipid composition of plasma mem-

*Corresponding author. E-mail: chiasaalu@hotmail.com. Tel: 234-8033200876.

brane of mammalian spermatozoa is markedly different from those of mammalian somatic cells. They have very high levels of phospholipids, sterols, saturated and polyunsaturated fatty acids. Therefore sperm cells are particularly susceptible to the damage induced by reactive oxygen species (ROS) release (Hendin et al., 1999). ROS are cytotoxic and cause tissue injury in several pathophysiologicals, such as cancer, glomerular nephritis and arthritis. Thus sperm dysfunction may be a consequence of elevated seminal ROS. Several studies have also demonstrated that in the presence of increased antioxidant enzyme levels, testicular dysfunction can be prevented in varicocele subjects (Hendin et al., 1999; Suziki and Sofikitis, 1999; Sharma and Agarwal, 1996).

Treatments involving antioxidants have been used successfully to decrease oxidative stress related injuries in many organ systems as well as in the testis (Suziki and Sofikitis, 1999; Ozokutan et al., 2001; Saalu et al., 2006).

L-Ascorbate (vitamin C) is an essential nutrient for a large number of higher primate species, a small number of other mammalian species (notably guinea pigs and bats), a few species of birds, and some fish (McCluskey et al., 1985). The pharmacophore of vitamin C is the ascorbate ion. In living organisms, ascorbate is an antioxidant, since it protects the body against oxidative stress (Padayatty et al., 2003).

Although varicolectomy is considered as a highly effective treatment of infertility due to varicoceles, a significant number of men remain infertile after varicolectomy (Sofikitis and Miyagawa, 1992). Therefore there is an increasing interest to develop conservative modes of therapy of infertility due to varicoceles. Considering that oxygen radical scavengers provide significant restoration of testicular function after testicular vascular diseases (Henry and Turner, 1996; Saalu et al., 2007), we aim to study the effect of the administration of Vitamin C on testicular morphology, and testicular spermatogenic and steroidogenic functions in rats that had earlier been varicocele.

MATERIALS AND METHODS

The drug

Ascorbate was obtained at Julie Pharmacy Ikeja, Lagos.

Animals

Adult male Sprague – Dawley rats weighing 150 – 200 g were used for the study. The animals were kept in the Animal House of Department of Anatomy, LASUCOM, Ikeja and housed in wire mesh cages under standard environmental conditions with the provision of 12 h light and 12 h darkness. Rat feeds (Pfizer feeds Nigeria Limited, Lagos, Nigeria) and water were provided *ad libitum*.

Experimental protocol

Thirty male Sprague Dawley rats were weighed and divided randomly into three groups of ten rats each. Group A served as the

control and the rats were neither rendered varicocele nor treated with vitamin C. Groups B and C served as experimental groups in which the rats were rendered bilaterally varicocele. To induce varicocele, the animals were anaesthetized with intra-abdominal injection of 7 mg/kg body weight ketamine hydrochloride. A 2 cm median incision was made through the skin, beginning caudal to the prepuce and extending cranially. The right and left spermatic vein were exposed and ligated completely with a 4-0 nylon suture as described by Sofikitis and Miyagawa (1992). Group C in addition had gavage administration of 8 mg/kg body weight vitamin C daily for fifty six days after varicocele induction.

Autopsy, organ weight and volume estimation

At the end of the experimental period, each rat was weighed and sacrificed by decapitation. The testis were excised, dissected free of surrounding tissue, their weights determined and volumes measured by water displacement method.

Sperm characteristics

The testes from each rat were carefully exposed and removed. They were trimmed free of the epididymides and adjoining tissues. From each separated epididymis, the caudal part was removed and placed in a beaker containing 1 mL physiological saline solution. Each section was quickly macerated with a pair of sharp scissors and left for a few minutes to liberate its spermatozoa into the saline solution. Sperm motility, concentration and progressive motility were determined as earlier described (Saalu et al., 2006, 2007). Semen drops were placed on the slide and two drops of warm 2.9% sodium citrate were added. The slide was covered with a cover slip and examined under the microscope using X40 objective for sperm motility. Sperm count was done under the microscope using improved Neubauer haemocytometer.

Estimation of plasma levels of testosterone

Plasma testosterone concentrations were estimated using the Enzyme Immunology Assay (EIA) method as earlier described (Saalu et al., 2006). Plasma samples collected were stored at – 20°C while assayed. The EIA kits used were obtained from Immunometrics (London U. K) and contained testosterone EIA substrate reagents and EIA quality control samples. A quality control sample was run for the hormone at the beginning and at the end of the assay variation. The EIA kit used had a sensitivity level of 0.3 nmol/L (0.1 ng/mL). The intra and inter assay variations were 11.00 and 10.10% respectively.

Histological analysis

This was done as essentially as described by Akpantah et al. (2003). The organs were cut in slabs of about 0.5 cm thick and fixed in Bouin's fluid for a day after which it was transferred to 70% alcohol for dehydration. The tissues were passed through 90% alcohol and chloroform for different durations before they were transferred into two changes of molten paraffin wax for 20 min each in an oven at 57°C. Serial sections of 5 µm thick were obtained from a solid block of tissue and were stained with haematoxylin and eosin stains, after which they were passed through a mixture of equal concentration of xylene and alcohol. Following clearance in xylene, the tissues were oven-dried. Light microscopy was used for the evaluations.

Statistical analysis

Data were expressed as mean ± SEM. They were subjected to ana-

Table 1. Body weights (g), testicular weights (g) and testicular volumes (mL) of rats rendered varicocele with or without vitamin C treatment.

Parameter	Varicocele without vitamin	Varicocele with vitamin C	Control
Initial live body weight	190.36 ± 9.20	180.12 ± 8.70	195.03 ± 5.00
Final live body weight	186.45 ± 25.40	166.24 ± 13.60	230.53 ± 13.00
Body weight difference	3.91 [2.05]	13.88 [7.71]	35.5 [18.20]
Testicular weight	0.51 ± 0.13	1.59 ± 0.06	1.85 ± 0.51
Testicular volume	0.56 + 0.14*	1.58 ± 0.07	1.86 + 0.30

*P<0.05 compared to control group; [] Percentage.

Table 2. Sperm characteristics of rats rendered varicocele with or without vitamin C treatment.

Parameter	Varicocele alone	Varicocele with vitamin C	Control
Sperm concentration (X 10 ⁶ /mL)	1.34 ± 4.80**	23.25 ± 5.07*	45.0 ± 6.00
Sperm motility (%)	6.0 ± 4.04**	23.0 ± 5.63*	71.8 ± 4.23
Progressivity	b ₁	b ₁	a ₁

*P<0.05 compared with the control group; **P<0.01 compared with the control group.

a₁, Rapid linear progressive motility; b₁, Sluggish linear or non – linear motility.

lysis of variance (ANOVA). Statistical significance between the various groups was separated by t – test (SAS, 2002).

RESULTS

Body weight changes

Table 1 shows that rats in control group had significant (P<0.05) increase in weight. Both varicocele groups lost weights when compared with their initial weights. However the weight loss by the varicocele rats that received vitamin C was higher than the losses by varicocele group that did not receive vitamin C.

Weights and volume of testes mean

Table 1 also shows that the testicular weights and volumes of the varicocele alone were the least, being significantly lower (P<0.05) compared to the mean testicular weights and volumes of the varicocele rats that in addition had vitamin C.

Epididymal sperm characteristics

Spermatozoa concentration: As shown in Table 2, the varicocele alone group had marked oligospermia with their sperm concentration being significantly lower (P<0.01) compared to the control group. The varicocele with vitamin C group however showed only moderate oligospermia, the sperm concentration being significantly lower (P<0.05) than the control group.

Spermatozoa motility: Even though percentage sperm motility of both the varicocele alone and varicocele with vitamin C groups were significantly lower (P<0.01 and P<0.05 respectively) compared to the control group, the varicocele with vitamin C group still had a significantly higher (P<0.05) sperm motility than the varicocele alone group (Table 2).

Progressivity of spermatozoa motility: The sperm cells from the cauda epididymides of both varicocele alone and varicocele with vitamin C groups showed sluggish linear or non-linear movement. Spermatozoa from the control group exhibited progressive rapid linear movement.

Serum testosterone levels

There was a significantly lower (p<05) serum testosterone levels in the varicocele alone rats compared with the control rats. The serum testosterone level of the varicocele rats that were post treated with vitamin C was lower but not significantly lower (p>0.5) when compared to the control (Figure 1).

Testis morphology

Light microscopy was used for evaluation of testicular histology as shown in Figures 2 to 4. The seminiferous tubules of the control rats were completely differentiated. Spermatozoa are shown in some of the tubules. However in the varicocele group without vitamin C treatment there was marked degeneration of the seminiferous tubules. There was also widening of the lumen as a result of hypospermatozoa formation. The testes of the rats

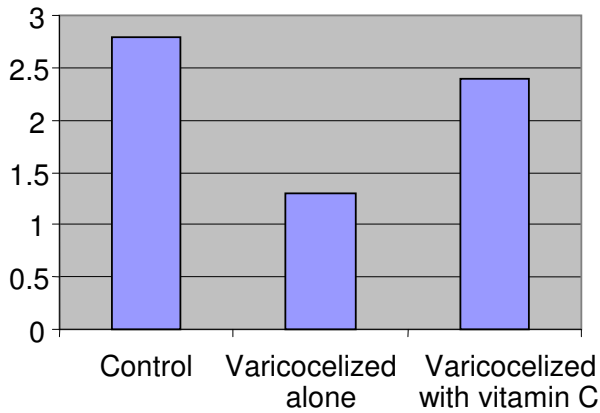
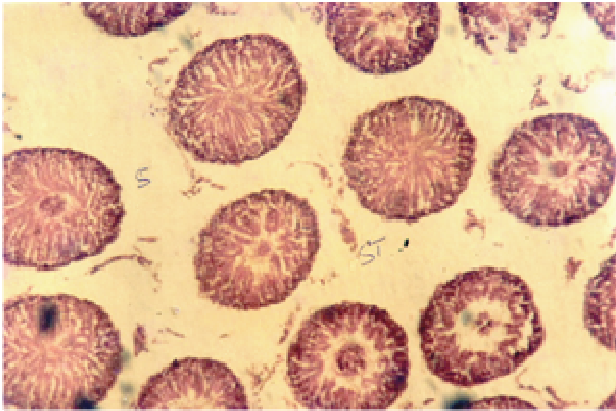


Figure 1. Serum testosterone levels (ng/mL) in rats rendered varicocelized with or without vitamin C treatment.

H and E (X 100)



H and E (X 400)

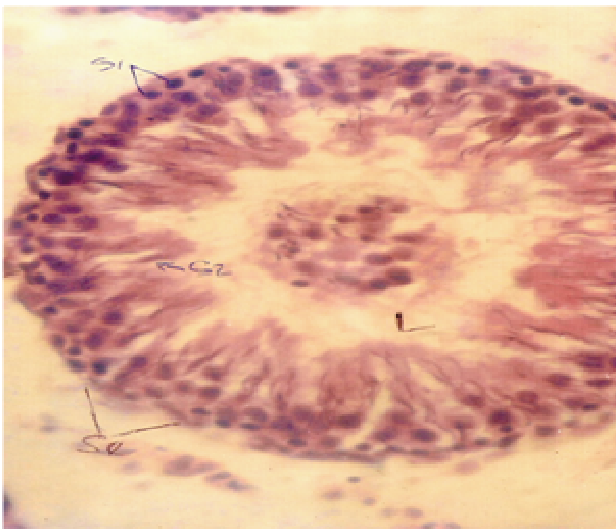
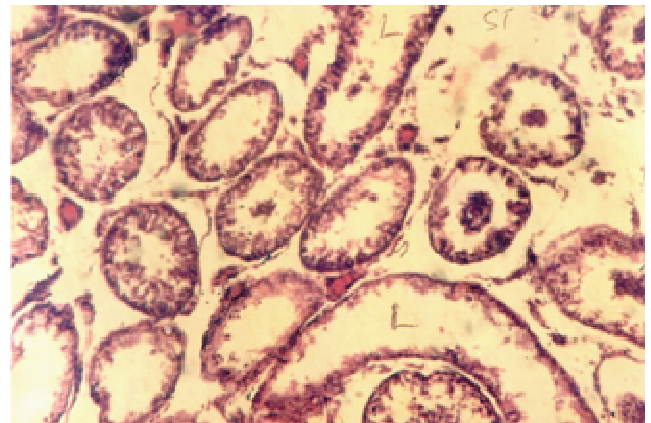


Figure 2. Section through testis of control rats. Completely differentiated seminiferous tubules.

H and E (X 100)



H and E (X 400)

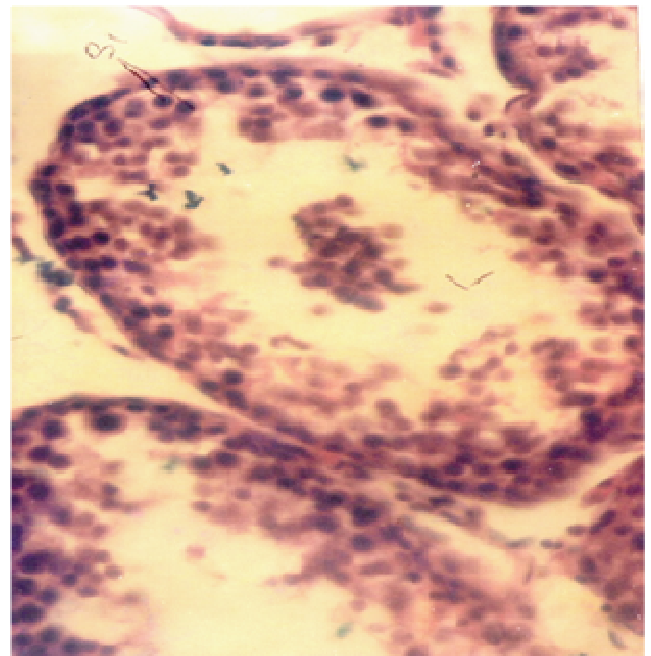


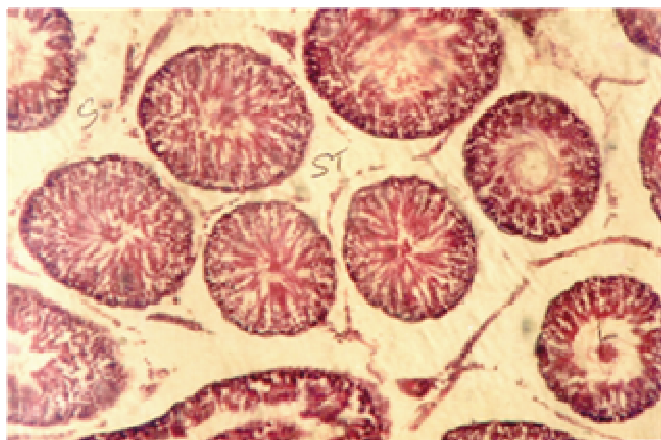
Figure 3. Section through testis of varicocelized rats without vitamin C treatment. Marked degeneration of the germinal epithelium.

that had vitamin C following varicocele induction showed fairly preserved seminiferous tubules and stroma architecture.

DISCUSSION

The results from the present study showed a derangement of the growth and reproductive functions of the animals. The gain in live body weight of the control rats meant that the rats were still in the active growth phase.

H and E (X 100)



H and E (X 100)

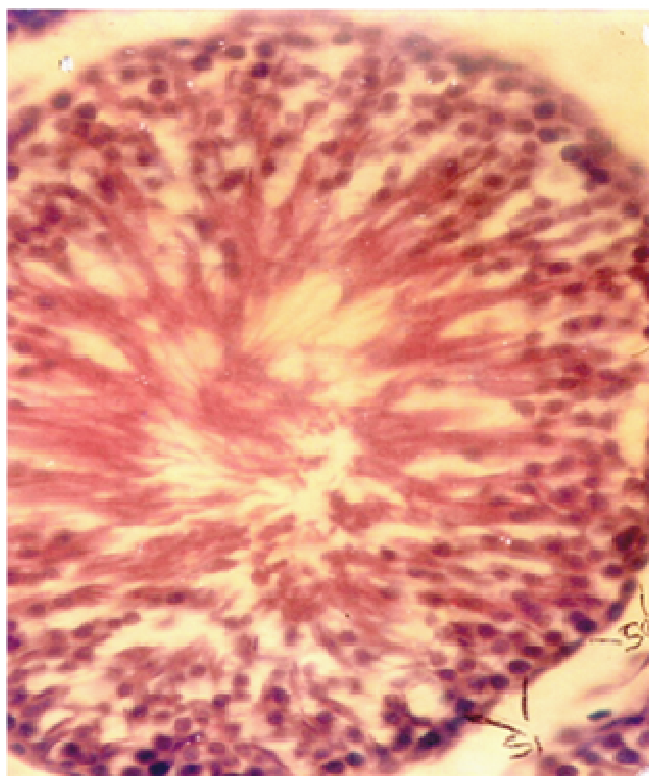

Figure 4. Section through testis of varicocele rats with vitamin C treatment. Largely preserved seminiferous tubule and stroma architecture.

The loss in live body weight of the experimental groups indicates that artificial varicocele has a negative effect on the body metabolic process (Ozdamar et al., 2004). The procedure for achieving artificial varicocele confers a

conspicuous level of stress on the rats. This stress could affect their metabolic process leading to losses in live weights observed in this study.

The lower testes weights in varicocele compared to the control corroborate the report of Suzuki and Sofikitis (1999). Semercioz and Onor (2003) also reported degenerative changes in the seminiferous epithelium of testes that were made varicocele, due to the effects of heat from venous stasis on the spermatogenic cells within the epithelium leading to loss in testicular weight. The findings of largely normalized testicular weights in animals that had vitamin C following experimental varicocele indicate a protective role.

Varicocele which is a leading cause of male infertility is associated with increased production of spermatozoal ROS. Irrespective of the infertility status, it was identified that there is a strong relationship between sperm dysfunction and varicocele (Lewis et al., 1995; Hendin et al., 1999). Indeed Hendin et al. (1999) reported a 4-fold increase in the frequency of elevated ROS generation in the incidental varicocele group compared to their control patients.

The results from our present study showed a moderate oligospermia ($23.25 \pm 5.07 \times 10^6$ /mL) in the varicocele rats that had vitamin C. This is a significant improvement over the marked oligospermia ($1.34 \pm 4.80 \times 10^6$ /mL) observed in varicocele rats that were not given vitamin C. This confirms the moderating effect of vitamin C as a potent antioxidant and a free radical scavenger (Bjelakovic, 2007). Furthermore, treatment with vitamin C improved bilateral testicular functions and helped the epididymal sperm maturation process as indicated by the significantly higher cauda epididymal sperm motility. Administration of vitamin C may support the natural antioxidant mechanism of testicular tissue and partly protects the tissue damage due to induction of varicocele. However it should be noted that despite proven benefits of vitamin C administration, the values of quantitative and qualitative sperm parameters remain significantly lower than those of the control group.

The ameliorating effects of vitamin C are further demonstrated by the significant improvement in the histological profiles of varicocele with vitamin C group when compared to the testicular morphology of the varicocele alone group. As shown in our results, varicocele brought about a significant reduction in the serum testosterone levels. This indicates a gross derangement of the Leydig cells since delicate alterations in Leydig cell secretory function may not be accompanied by alterations in peripheral serum androgen levels (Saypol et al., 1981).

It is noteworthy however that there was no significant decline in the serum levels of testosterone in the varicocele with vitamin C group when compared to the control. This provides the evidence that the rejuvenating role of vitamin C in varicocele testis is both on the spermatogenic and steroidogenic functions.

Conclusion

In conclusion, our study showed a protective effect of vitamin C on testicular histology and physiology. Although varicocelectomy is considered as a highly effective treatment of infertility due to varicoceles, a significant number of men remain infertile after varicocelectomy. The possibility of vitamin C supplementation in this subset of infertile men could be considered.

REFERENCES

- Bjelakovic G (2007). Mortality in randomized trials of antioxidant supplements for primary and secondary prevention: systematic review and meta-analysis. *JAMA* 297(8): 842-857.
- Hendin BN, Kolettis PN, Sharma RK, Thomas A (1999). Varicocele is associated with elevated spermatozoal reactive oxygen species production and diminished seminal plasma antioxidant capacity. *J. Urol.* 161: 1831-1834.
- Henry MP, Howard SS, Turner TT (1986). Repair of experimental varicoceles in rats. Long-term effects on testicular blood flow and temperature and Caudaepididymal sperm concentration and motility. *J. Androl.* 7: 271-276.
- Hudson RW (1988). The endocrinology of varicocele. *Fertil. Steril.* 49: 199-208.
- Kass EJ, Stork BR, Steinert BW (2001). Varicocele in adolescence induces left and right testicular volume loss. *BJU Int.* 87: 499-501.
- Lewis SE, Boyle PM, McKinney KA, Young IS, Thompson W (1995). Total infertile men. *Fertil Steril.* 64: 865.
- McCluskey SE (1985). Which Vertebrates Make Vitamin C? (PDF). *Origins* 12(2): 96-100.
- Ozdama RAS, Soyulu ALT, Culha M, Ozden M, Gokal PA (2004). Testicular Oxidative stress. Effects of experimental varicocele in adolescent rats. *Urol. Int.* 73: 3437.
- Ozokutan BH, Kucukaydin M, Muhtaroglu S, Tekin Y (2000). The role of nitricoxide in testicular ischemia-reperfusion injury. *J. Pediatr. Surg.* 35: 101-103.
- Padayatty S, Katz A, Wang Y, Eck P, Kwon O, Lee J, Chen S, Corpe C, Dutta A, Dutta S, Levine M (2003). Vitamin C as an antioxidant: evaluation of its role in disease prevention" (PDF). *J. Am. Coll. Nutr.* 22(1): 18-35. PMID 12569111.
- Saalu LC, Togun VA, Oyewopo AO, Raji Y (2006). Artificial cryptorchidism and the moderating effect of melatonin in Sprague-Dawley rats. *J. Appl. Sci.* 6(14): 2889-2894.
- Saalu LC, Oluyemi KA, Omotuyi IO (2007). α -Tocopherol (vitamin E) attenuates the testicular toxicity associated with experimental cryptorchidism in rats. *Afr. J. Biotechnol.* 6(12): 1373-1377.
- Santoro G, Romeo C, Impellizzeri P, Cutroneo G, Trimarchi F (2001). Nitricoxide synthase patterns in normal and varicocele testis in adolescents. *BJU Int.* 88: 967-973.
- Saypol DC, Howards SS, Turner TT, Miller ED (1981). Influence of Surgically induced Varicocele on testicular Blood flow, temperature and histology in adult rats and dogs. *J. Clin. Invest.* 68: 39-45.
- Semercoz A, Onor RO (2003). Effect of melatonin on testicular tissue nitricoxide level and antioxidant enzyme activities in experimentally induced left varicocele. *Neuroendocrinol. Lett. Nos* 1/2 Feb-Apr. 24: 45-50.
- Sharma RK, Agarwal A (1996). Role of reactive oxygen species in male fertility. *Urology* 48: 835-838.
- Sofikitis N, Miyagawa I (1992). Experimental models for the study of varicocele: A selected review. *Jpn. J. Fertil. Steril.* 38: 168-177.
- Suziki N, Sofikitis N (1999). Protective effects of antioxidants on testicular fractions of varicocele rats. *Yonago Acta. Med.* 42: 87-94.
- World Health Organization (WHO) (1992). The influence of varicocele on parameters of fertility in a large group of men presenting to infertility clinics. *Fertil Steril.* 57: 1289-1293.