

Full Length Research Paper

## Ameliorative effect of *Lentinus squarrosulus* mycomeat against *Pseudomonas aeruginosa* infection using albino rat as animal model

Bamigboye C. O.\* and Oloke J. K.

Department of Pure and Applied Biology (Microbiology Unit), Ladoko Akintola University of Technology, P.M.B 4000, Ogbomoso, Oyo State, Nigeria.

Received 4 December, 2014; Accepted 13 May, 2016

The increasing awareness of inherent therapeutic and prophylactic benefits of some higher fungi and their products has been the recent trend for improving a healthy vigour. Mycomeat is a mushroom derived 'meat-like' product produced using solid state fermentation technique. Previous research in this group revealed mycomeat as a potentially useful nutraceutical. This study seeks to explore the potential of mycomeat as a therapeutic agent against *Pseudomonas aeruginosa* infections. Three concentrations (83.3, 166.6 and 250 mg/kg body weight) of powdered mycomeat were prepared and administered to *P. aeruginosa* infected wistar rats. Morphological appearance and behavior of the rats were used as the assessment method for adverse reactions. After a period of 26 days, the rats were sacrificed with the liver, spleen and testes aseptically excised for histopathological analysis, the sperm count and sperm motility assay was carried out. Histopathological analysis revealed the testis of therapeutic group administered with 83.3 mg/kg as having a normal seminiferous tubule, while other organs were adversely affected. The group administered with 166 mg/kg of mycomeat has a normal hepatocyte, normal seminiferous tubule and splenic cells. Results from the therapeutic group were consistently better than the prophylactic group. The untreated group showed anomaly in the three organs inspected. The sperm count but not motility was significantly higher in the treated group than that observed in the positive and negative control group. This study was able to establish that mycomeat could be used to preserve body organs, at a dose of 166 mg/kg body weight. It can also be used as a birth control nutraceutical for males.

**Key words:** Mushroom, *Lentinus subnudus*, histopathology, birth control, fertility.

### INTRODUCTION

*Pseudomonas aeruginosa* is a ubiquitous gram-negative bacterium that is virulent towards a wide range of organisms, including bacteria, plants, insects, and mammals (Plotnikova et al., 2000). *P. aeruginosa* is

\*Corresponding author. E-mail: kemmai\_me@yahoo.com. Tel: +2347031068220.

increasingly recognized as an emerging opportunistic pathogen of clinical relevance. In humans, *P. aeruginosa* chronically infects the lungs of most cystic fibrosis patients, causing serious infections of burn wounds and eye lesions, and systemic infections in immunocompromised individuals (Holder, 1993). The bacterium's pathogenicity is displayed via its secreted and surface-associated virulence factors and the complexity of the regulatory unit controlling these factors. *P. aeruginosa* is also known to be resistant to most antibiotics. George et al. (1989) established that the oral dose of *P. aeruginosa* required to establish colonization in a healthy subject is high but not impossible. The study by Mena and Gerba (2009) showed that the risk of colonization from ingesting *P. aeruginosa* in drinking water is low and slightly higher if the subject is taking an antibiotic resisted by *P. aeruginosa*. Its occurrence in drinking water is related to its ability to colonize biofilms in faucets, showerheads etc. *P. aeruginosa* could cause pneumonia, urinary tract infections, gastrointestinal infections and endocarditis. Although, its mode of acquisition is still much controversial, Boyer et al. (2011) reported that contaminated tap water could be associated with *P. aeruginosa* acquisition. The colonization of the respiratory tract could be exogenous or endogenous such as from the intestine, the oropharynx and the gastric compartment (Forestier et al., 2008).

The liquid mycelia extract of *Lentinus squarrosulus* is known to have ulcer prevention and healing capabilities in rats, this establishes that this mushroom species is not only edible and nutritious but also possess tonic and medicinal qualities (Omar et al., 2011). Traditionally, mushrooms are used for nutritional, medicinal and mythological benefits in Nigeria (Osemwegie et al., 2006). Globally, the level of mushroom nutraceuticals established mushrooms as good health food and reports abound on their use for the treatment of malnutrition in infants, diabetes, obesity or hyperlipidemia, sterility, anemia, mumps, fever and protein deficiency (Idu et al., 2007). The presence of polysaccharides in mushrooms could make them useful as natural health promoters against parasites, bacteria and viruses (Oei, 2003). Both fruiting body and the mycelium of mushrooms contain compounds with wide ranging antimicrobial activities. They are rich sources of natural antibiotics, where the cell wall glucans are well known for their immunomodulatory properties, and many of the externalized secondary metabolites combat bacteria, fungi, and viruses (Collins and Ng, 1997). Our previous study on mycomeat production using *Lentinus squarrosulus* revealed it is nutritious and could be harnessed as a useful nutraceutical. However, reports on mycomeat generally are very few and to the best of our knowledge, no report on its therapeutic efficacy has been reported till date. This research therefore seeks to establish the *in-vivo* efficacy of mycomeat against *P. aeruginosa* infection in animal model.

## MATERIALS AND METHODS

### Mycomeat production

Mycomeat was prepared as described in our previous study (Bamigboye et al., 2013). Briefly, *L. squarrosulus* was cultured on soymilk residue at 25°C until full ramification was obtained. The mycomeat produced was harvested, oven dried and manually milled.

### Bacterial suspension

Pathogenic *P. aeruginosa* from the ear swab of a hospitalized patient was obtained from Bowen University Teaching Hospital, Ogbomoso, Oyo State, Nigeria and sub-cultured as research demands.

### *In-vivo* antimicrobial assay

All the applicable guidelines for the care and use of animals were followed in the study. Seven days prophylactic and 1 h post infection effects of mycomeat on *P. aeruginosa* were investigated using the method previously described by Oke (2006).

### Seven days prophylactic experiment

Eighteen, 16-weeks old albino rats were fed on pellets and sterile water *ad libitum*. They were divided into three groups, Set A<sub>1</sub>, A<sub>2</sub> and A<sub>3</sub> administered with 83.3 mg/kg bodyweight of mycomeat, 166.6 mg/kg bodyweight and 250 mg/kg bodyweight, respectively. Seven days post mycomeat administration, an aliquot of (4.0×10<sup>7</sup> ml) bacterial suspension was galvaged into each animal. The rats were observed for 26 days, after which they were sacrificed by cervical dislocation. The liver, spleen and testes were excised for histopathological analysis, sperm motility and sperm count was also analysed.

### One-hour post bacterial administration/ therapeutic experiment

Aliquot of (4.0×10<sup>7</sup> ml) bacterial suspension was administered orally into each of twenty-four animals. After 1 h, they were divided into four groups of 6 each, Set B<sub>1</sub>, B<sub>2</sub> and B<sub>3</sub> were treated as above. The control group was administered with 0.2 ml of (4.0×10<sup>7</sup> ml) bacterial suspension alone without treatment (Cp). Other control groups were administered with mycomeat suspension alone (Cm) and the last group was given feed and water only (C<sub>01</sub>). The rats were followed for 26 days, after which they were sacrificed by cervical dislocation. Post- infection assay was done by using the method of Majolagbe et al. (2013) to establish the colonization of the test organism.

### Histological studies

The liver, spleen and testes were excised for histopathological analysis, sperm motility and sperm count were also carried out. The organs were preserved in 10% formalin for histological studies so as to detect pathological changes.

### Adverse event assessment methods

All the rats were daily inspected visually for possible morphological

**Table 1.** Sperm analysis for the therapeutic treatment group along with controls.

Group	Sperm count ( $\times 10^6$ / ml)	Sperm motility (%)
83.3 mg/kg.bd.wt	53.90 <sup>a</sup> ±0.90	79.9 <sup>b</sup> ±0.95
166.6 mg/kg.bd.wt	48.80 <sup>b</sup> ±7.00	78.7 <sup>b</sup> ±1.30
250.0 mg/kg.bd.wt	54.50 <sup>a</sup> ±0.70	71.7 <sup>c</sup> ±0.25
C <sub>p</sub>	47.1 <sup>b</sup> ±3.10	74.2 <sup>f</sup> ±1.50
C <sub>m</sub>	53.9 <sup>a</sup> ±0.50	63.0 <sup>h</sup> ±1.25
C <sub>01</sub>	51.80 <sup>ab</sup> ±1.00	90.7 <sup>a</sup> ±0.70

\*Means with different superscript within a column are significantly different at P<0.05. C<sub>p</sub>, group administered with *Pseudomonas aeruginosa* only; C<sub>m</sub>, group administered with mycomeat only; C<sub>01</sub>, feed and water only.

**Table 2.** Sperm analysis for the prophylactic treatment group along with controls.

Group	Sperm count ( $\times 10^6$ / ml)	Sperm motility (%)
83.3 mg/kg.bd.wt	46.9 <sup>a</sup> ±0.90	84.5 <sup>d</sup> ±1.20
166.6 mg/kg.bd.wt	49.5 <sup>ab</sup> ±0.70	77.5 <sup>e</sup> ±3.10
250.0 mg/kg.bd.wt	51.4 <sup>ab</sup> ±1.00	68.4 <sup>g</sup> ±1.65
C <sub>p</sub>	47.1 <sup>a</sup> ±3.10	74.2 <sup>f</sup> ±1.50
C <sub>m</sub>	53.9 <sup>b</sup> ±0.50	63.0 <sup>h</sup> ±1.25
C <sub>01</sub>	51.8 <sup>ab</sup> ±1.00	90.7 <sup>c</sup> ±0.70

\*Groups with different superscript within a column are significantly different at P<0.05. C<sub>p</sub>, Group administered with *P. aeruginosa*; C<sub>m</sub>, group administered with mycomeat; C<sub>01</sub>, feed and water only.

changes; agility, physical appearance and perceived strength.

### Statistical analysis

The result for sperm count and sperm motility were expressed as the mean ±SD. Means were analysed using a one-way analysis of variance, followed by the Duncan Multiple Range Test to determine significant differences in all the parameters. Differences with values of P<0.05 were considered statistically significant.

## RESULTS

### Morphological changes

The rats treated therapeutically with mycomeat appeared very agile, stronger, well-fed and much better than both the prophylactic and untreated but infected control rats. The untreated group appeared haggard, skinny and aggressive. This coupled with the re-isolation of the test organism confirmed that *P. aeruginosa* was able to colonize and initiate infection.

### Sperm count and sperm motility

Sperm analysis for the therapeutic treatment group along with controls is as shown in Table 1 while Table 2 shows

the sperm analysis for the prophylactic group along with controls. The sperm count in the C<sub>m</sub> group was significantly higher ( $53.9 \times 10^6$ ) than that of the control group (C<sub>01</sub>), but significantly have the same effect with the group therapeutically treated with 83.3 and 250.0 mg/kg.bd.wt (Table 1). However, the sperm motility was lower than the group given feed and water only; this could possibly result from the pH of the mycomeat.

The group administered with *P. aeruginosa* alone (C<sub>p</sub>) had a significantly lower sperm count, and significantly have the same effect with that of Group B<sub>2</sub> (Table 1). Table 2 also shows that the sperm count for A<sub>1</sub> administered with 83.3 mg/kg body weight is not significantly different from that of C<sub>p</sub>. The sperm motility for the clean control group (C<sub>02</sub>) is significantly higher than that obtained for other groups (Tables 1 and 2). Groups B<sub>1</sub> and B<sub>2</sub> significantly had a lowered sperm motility (Table 1) than that of the clean control group (C<sub>02</sub>), likewise Groups B<sub>3</sub> and C<sub>01</sub> (Table 1). As shown in Table 3, the therapeutic group appeared better than the prophylactic group.

### Histopathological studies

The liver photomicrographs for the prophylactic group showed evidence of vascular congestion in the various concentrations used; however the group prophylactically

**Table 3.** Pathological conditions associated with the liver, spleen and testis of the experimental groups and controls.

Parameter	Liver			Spleen		Testis		
	Haemorrhage	Fatty degeneration	Vascular congestion	Fatty degeneration	Cellular necrosis	Tubular hyperplasia	Mild edema	Cellular degeneration
A <sub>1</sub>	+++	-	+++	+++	+	++	-	-
A <sub>2</sub>	+	-	+	+++	+	+	-	-
A <sub>3</sub>	-	-	++	+++	+	-	+	-
B <sub>1</sub>	-	+	-	+++	++	-	-	-
B <sub>2</sub>	-	-	-	-	-	-	-	-
B <sub>3</sub>	++	++	-	+++	-	+	-	+
C <sub>p</sub>	-	++	-	+++	-	++	-	+++
C <sub>m</sub>	-	++	-	++	-	++	-	++
C <sub>01</sub>	-	-	-	+	-	-	-	-

+++; severe; ++, moderate; +, mild; -, absent. C<sub>p</sub>, Group administered with *P. aeruginosa*; C<sub>m</sub>, group administered with mycomeat; C<sub>01</sub>, feed and water only. A<sub>1</sub>- Group prophylactically administered with 83.3 mg/kg.bd.wt, A<sub>2</sub>- Group prophylactically administered with 166.6 mg/kg.bd.wt, A<sub>3</sub>- Group prophylactically administered with 250.0 mg/kg.bd.wt, B<sub>1</sub>- Group therapeutically administered with 83.3 mg/kg.bd.wt, B<sub>2</sub>- Group therapeutically administered with 166.6 mg/kg.bd.wt, B<sub>3</sub>- Group therapeutically administered with 250.0 mg/kg.bd.wt.

treated with 166.6 mg/kg.bd.wt of mycomeat (A<sub>2</sub>) revealed normal hepatocyte (Plate 1). The spleen for group A<sub>1</sub> showed severe fatty degeneration coupled with cellular necrosis (Plate 2). The sets prophylactically treated with 250.0 mg/kg.bd.wt however revealed a normal seminiferous tubule as shown on Plate 3. The organs of the group therapeutically treated with 166.6 mg/kg.bd.wt are normal showing that mycomeat can preserve the cells of the studied organs at this concentration.

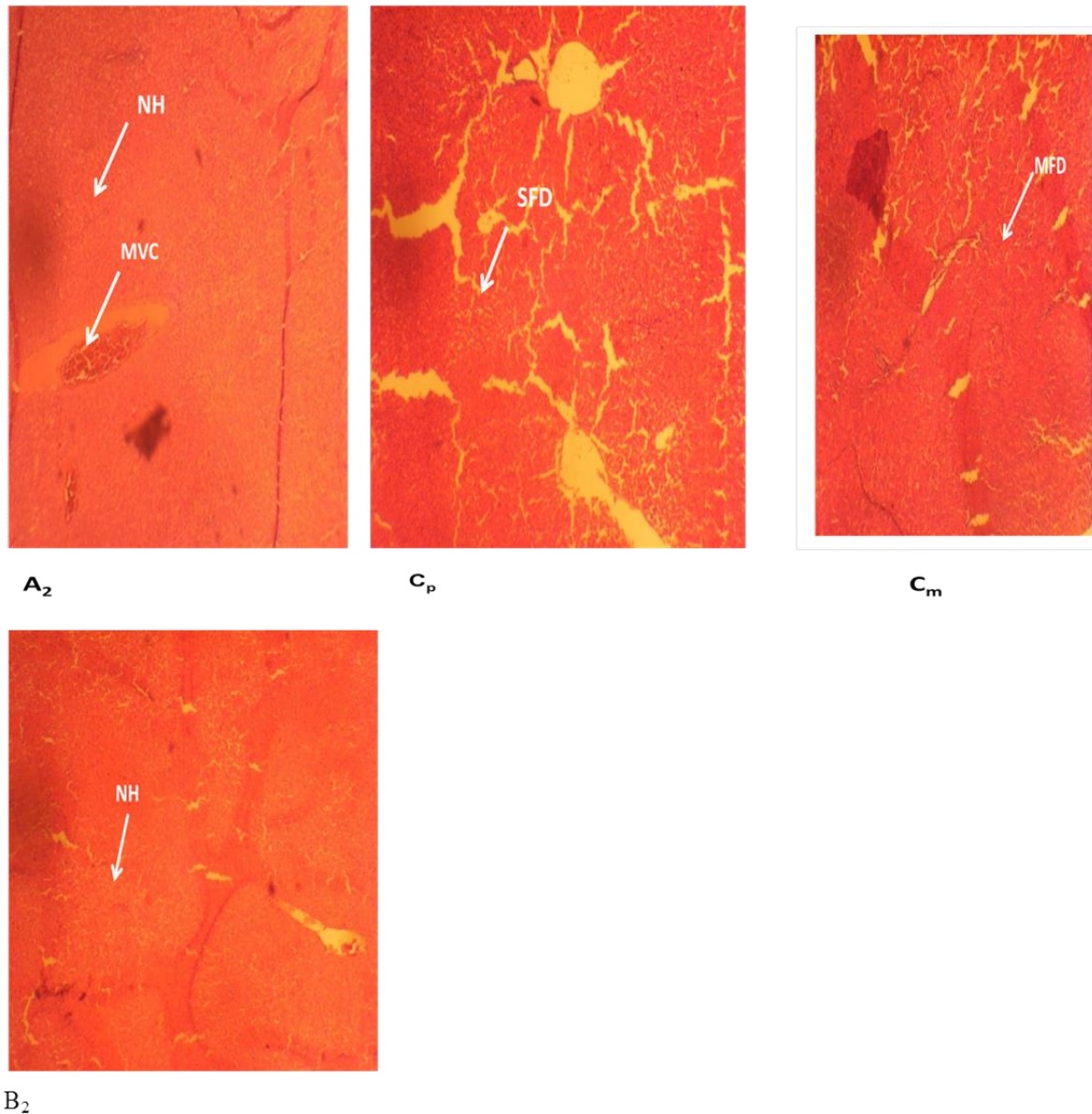
## DISCUSSION

The study reveals the potential of mycomeat as a nutraceutical. Mushroom has long been recognized as having several medicinal benefits, however mushroom growing requires great expertise, techniques and investments. The use of mushroom mycelia offers an added advantage over the use of mushroom itself; this include lesser space, shorter production time, less risk of contamination and almost the same medicinal value conferred by the corresponding fruit body. In this study, the medicinal effect of mycomeat against *P. aeruginosa* was established. The histopathological study of the experimental liver revealed normal hepatic cells in both the prophylactic and therapeutic group, as compared to the control group. The mechanisms of the hepatoprotective effects are still not clearly defined. However, it is probable that antioxidants, phenolics and radical scavenging activities could be responsible as *L. squarrosulus* is a versatile organism known to secrete a great amount of extracellular polysaccharide into its

growth substrate (unpublished data). It has been suggested that antioxidant and radical scavenging activity, modulation of nitric oxide production, maintenance of hepatocellular calcium homeostasis, and immunomodulatory effects might be involved in hepatoprotection (Wasser, 2005). The therapeutic group galvaged with 166.6 mg/kg.bd.wt were also noted to have normal splenic cells while the prophylactic group showed a severe fatty degeneration, the reason for this is not clear.

Interestingly, the sperm count of the group therapeutically treated showed values that were not dose dependent but significantly higher than the untreated group and the group given feed and water only. However, the sperm motility assay showed a dose-dependent relationship, the higher the dose, the lower the motility of the sperm cells; with all the doses showing a significantly different motility from those of group C<sub>01</sub>. It is probable that the acidic pH of mycomeat contributed to the reduction in the sperm motility; however, mycomeat clearly supported increased mitotic activity of the sperm cells. This fact is supported by the histopathology study of the testis of group C<sub>m</sub> showing an increased number of necrotic sperm cells. An amendment of the pH before administration might lead to fertility improvement, since impairment of spermatogenesis as well as changes like decrease in pH, hypotonic environment, and chemical substances like mucoproteins, alkaline phosphatase and acid phosphatase in spermatogenic cells might lead to the formation of non-viable spermatozoa (Kashinathan et al., 1972).

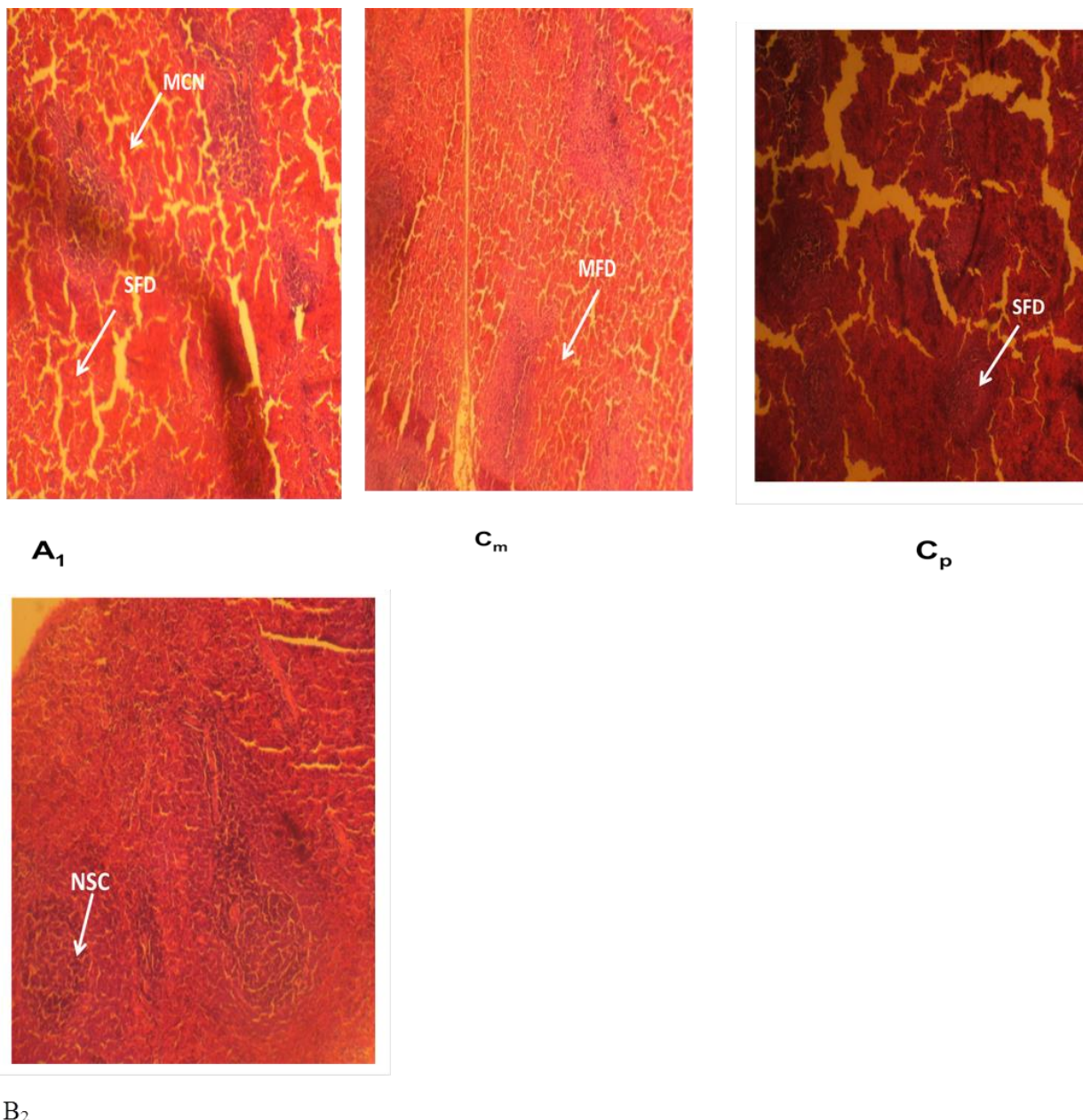
Valproic acid and carbamazepine has been found to have a similar result on sperm motility. Cohn et al. (1982) used valproic acid and carbamazepine, leading to a



**Plate 1.** Histological studies of liver of rat in the prophylactic (166.6 mg/kg), therapeutic group (B<sub>2</sub>-166.6 mg/kg) along with controls (C<sub>p</sub>, Group administered with *P. aeruginosa*; C<sub>m</sub>, group administered with mycomeat). MVC, moderate vascular congestion; MFD, moderate fatty degeneration; SFD, severe fatty degeneration; NH, normal hepatocyte.

reduced sperm content and motility in the experimental rats. On the contrary, Aboua et al. (2012), reported that the intake of red palm oil diet can help protect the male sperm function, leading to improved fertility. A previous research by Chang et al. (2008) found that the supplementation of diet with *Cordyceps militaris* lead to an increased sperm quality and quantity. The report of Khaki et al. (2009) on the spermatogenesis and sperm parameters of rats showed an increase in sperm percentage, motility and viability when ginger was used. Mycomeat will be applicable in animal husbandry, where meat production is preferred to fertility. However, since

there is limited birth control strategy for males, further research on mycomeat can find it useful in countries experiencing overpopulation as a means of birth control. Nevertheless, the effect of mycomeat on the female reproductive system was not covered in this research and could be a future research to be looked into. This study has revealed that *P. aeruginosa* infections could possibly affect some organs, including liver, spleen and testis and could play a part in infertility. The mechanism of action employed by *P. aeruginosa* is still unclear; however *P. aeruginosa* is known to produce hydrogen cyanide (HCN) maximally in the late exponential and early stationary



**Plate 2.** Histological studies of spleen of rats in the prophylactic (83.3 mg/kg - A<sub>1</sub>), therapeutic (B<sub>2</sub>-166.6 mg/kg) and control groups (C<sub>p</sub>, Group administered with *P. aeruginosa*; C<sub>m</sub>, group administered with mycomeat). MCN, Mild cellular necrosis; SFD, severe fatty degeneration; MFD, mild fatty degeneration; NSC, normal splenic cells.

phase under microaerophilic conditions (Blumer and Haas, 2000).

### Conclusion

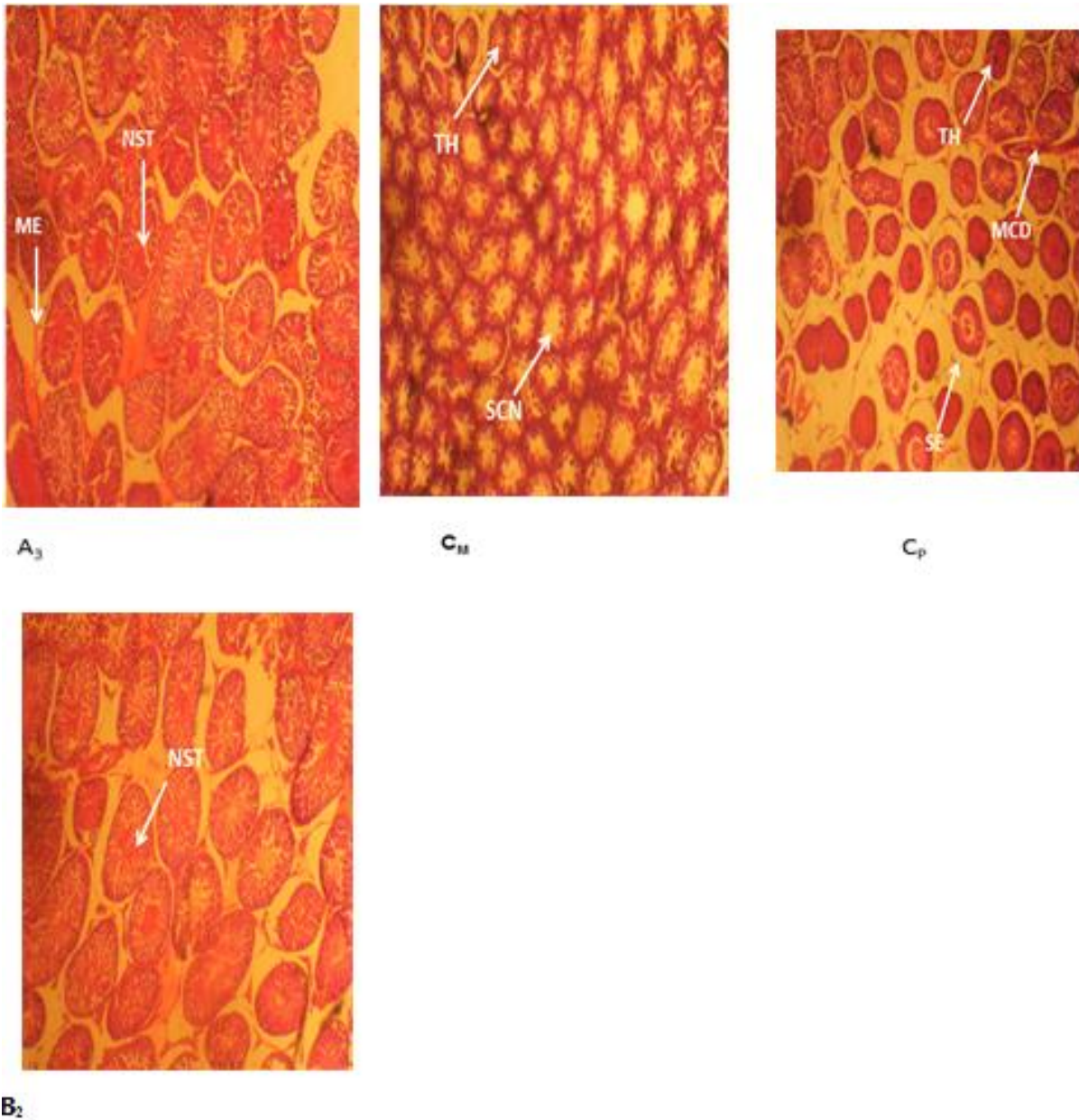
This study was able to establish that mycomeat could be useful in preserving body organs, at a dose of 166 mg/kg body weight. It can also be used as a birth control neutracetical for males and in animal husbandry for increasing productivity as induced by castration.

### Conflict of Interests

We declare that there is no conflict of interest whatsoever as regards this research work.

### ACKNOWLEDGEMENTS

The author appreciates the input of Mr Ayodele S. and Mr Gabriel O. who painstakingly contributed to the success of the research work. Likewise, Mr Owolabi Gbenga for



**Plate 3.** Histological studies of testis of rats in the prophylactic group (A<sub>3</sub>-250 mg/kg), therapeutic group (B<sub>2</sub>-166.6 mg/kg) along with controls (C<sub>p</sub>, Group administered with *P. aeruginosa*; C<sub>m</sub>, group administered with mycomeat). ME, Mild edema; NST, normal seminiferous tubule; TH, tubular hyperplasia; MCD, mild cellular degeneration; SCN, severe cellular necrosis; SE, Severe edema.

the useful input in result interpretation.

## REFERENCES

- Aboua YG, Brooks N, Mahfouz RZ, Agarwal A, Du Plessis SS (2012). A red palm oil diet can reduce the effects of oxidative stress on rat spermatozoa. *Andrologia* 44:32-40.
- Bamigboye CO, Oloke JK, Adebayo EA, Majolagbe ON, Ayandiran TA, Adegunlola EO (2013). Mycomeat production through the solid state fermentation of soymilk waste by *lentinus subnudus*. *J. Nat. Sci. Res.* 3:88-93.
- Blumer C, Haas D (2000). Mechanism, regulation and ecological role of bacterial cyanide biosynthesis. *Arch. Microbiol.* 173:170-177.
- Chang Y, Jeng KC, Huang KF, Lee YC, Hou CW, Chen KH, Cheng FY, Liao JW, Chen YS (2008). Effect of Cordyceps Militaris Supplementation on Sperm Production, Sperm Motility and Hormones in Sprague-Dawley Rats. *Am. J. Chin. Med.* 36(5):849-859.
- Cohn DF, Homonnai ZT, Gedalia FP (1982). The effect of anticonvulsant drugs on the development of male rats and their fertility. *J. Neurol. Neurosurg. Psychiatry* 45:844-846.
- Collins RA, Ng TB (1997). Polysaccharopeptide from *Coriolus versicolor* has potential for use against Human immunodeficiency virus type I infection. *Life Sci.* 60:383-387.

- Forestier C, Guelon D, Cluytens V, Gillart T, Sirot J, De Champs C (2008). Oral probiotic and prevention of *Pseudomonas aeruginosa* infections: a randomized, double blind, placebo controlled pilot study in intensive care unit patients. *Crit. Care* 12(3):R69.
- Holder IA (1993). *Pseudomonas aeruginosa* burn infections: pathogenesis and treatment, 275–295. In: Campa M., Bendinelli M., and Friedman H. (ed.), *Pseudomonas aeruginosa* as an opportunistic pathogen. Plenum Press, New York.
- Idu M, Osemwegie O, Timothy O, Onyibe HI (2007). A survey of plants used in traditional healthcare by Waja tribe Bauchi State, Nigeria. *Plant Arch.* 7(2):535-538.
- Kashinathan S, Ramakrishnan S, Basu SL (1972). Antifertility effect of *Ocimum Sanctum* L. *Indian J. Exp. Biol.* 10:23-25.
- Khaki A, Fathiazad F, Nouri M, Afshin Khaki A, Ozanci CC, Ghafari-Novin M, Hamadeh M (2009). The effects of Ginger on spermatogenesis and sperm parameters of rat. *Iranian J. Reprod. Med.* 7(1):7-12.
- Majolagbe ON, Oloke JK, Adebayo EA, Adewoyin AG, Ayandele A, Bamigboye CO (2013). Study on the Antibacterial Activity of Exopolysaccharides of *Lentinus subnudus* using swiss albino rats as animal model. *Am. Eurasian J. Sci. Res.* 8(1):47-52.
- Mena KD, Gerba CP (2009). Risk assessment of *P. aeruginosa* in water. *Rev. Environ Contam. Toxicol.* 201:71-115.
- Oei P (2003). Mushroom cultivation, appropriate technology for mushroom growers (3<sup>rd</sup> edition), Backhuys Publisher, Leiden, The Netherlands. pp. 46-106.
- Oke AJ (2006). Investigation of Immunomodulatory properties of Protein A from a Local strain of *Staphylococcus aureus*, Ph. D thesis Dissertation, Ladoke Akintola University of Technology, Ogbomosho.
- Omar MNA, Abdullah N, Kuppusamy UR, Abdulla MA, Sabaratnam V (2011). Nutritional composition, antioxidant activities, and antiulcer potential of *Lentinus squarrosulus* (Mont.) mycelia extract. *Evidence Based Complementary Altern. Med.* Volume 2011 (2011), Article ID 539356, 8 p.
- Osemwegie OO, Eriyaremu EG, Abdulmalik J (2006). A survey of macrofungi in Edo/Delta region of Nigeria, their morphology and uses. *Glob. J. Pure Appl. Sci.* 12(2):149-157.
- Plotnikova JM, Rahme LG, Ausubel FM (2000). Pathogenesis of the human opportunistic pathogen *Pseudomonas aeruginosa* PA14 in *Arabidopsis*. *Plant Physiol.* 124:1766-1774.
- Wasser SP (2005). Reishi or Ling Zhi (*Ganoderma lucidum*). *Enc. Diet. Suppl.* pp. 603-623.