

*Full Length Research Paper*

## **Teratogenic effect of isotretinoin on the morphology and palate development in rat fetuses**

**Ofusori, D. A.<sup>1\*</sup>, Adelakun A. E.<sup>2</sup>, Jimoh, S. A.<sup>3</sup>, Komolafe A.O<sup>4</sup>, Falana B. A.<sup>4</sup>, and Abayomi T. A.<sup>4</sup>**

<sup>1</sup>Department of Anatomy, School of Basic Medical Sciences, Igbinedion University, Okada, P.M.B 0006, Benin City, Edo State, Nigeria.

<sup>2</sup>Department of Chemistry, Faculty of Science, University of Lagos, Akoka, Nigeria.

<sup>3</sup>Department of Human Anatomy, Faculty of Basic Medical Sciences, University of Ilorin, Ilorin, Nigeria.

<sup>4</sup>Department of Anatomy and Cell Biology, Faculty of Basic Medical Sciences, Obafemi Awolowo University, Ile-Ife, Osun State. Nigeria.

Accepted 2 November, 2007

**The effect of isotretinoin currently used in dermatological treatments was investigated on the morphology and palate development during organogenesis in rat fetuses. This was in an attempt to evaluate the morphological implications associated with isotretinoin consumption. The animals were randomly divided into groups: A, B and C. Group A was further divided into subgroups: A1 and A2 and administered orally with 35 and 70 mg of isotretinoin (dissolved in vegetable oil) per kg of average body weight on day 11 of gestation. The same subdivision and administration goes for groups B and C, but on days 12 and 13, respectively. The control group received an equivalent volume of vegetable oil for each group on gestational days: 11, 12 and 13. After delivery, the fetuses were weighed and studied morphometrically and microscopically. The results revealed that group A had most of the primary palate affected (78.61 and 88.89% for subgroups 1 and 2, respectively); group B had most of the secondary palate affected (50.00 and 71.43% for subgroups 1 and 2, respectively) while majority of the fetuses in group C only showed mild malformation both in the primary and secondary palate (28.57 and 35.72% for sub groups 1 and 2, respectively). The data from morphometric parameters showed that the effect of isotretinoin on the fetuses is dose dependent. Isotretinoin should therefore be taken with caution especially by pregnant women during the first and second trimester of pregnancy.**

**Key words:** Palate, isotretinoin, morphometry, morphology, development, fetuses.

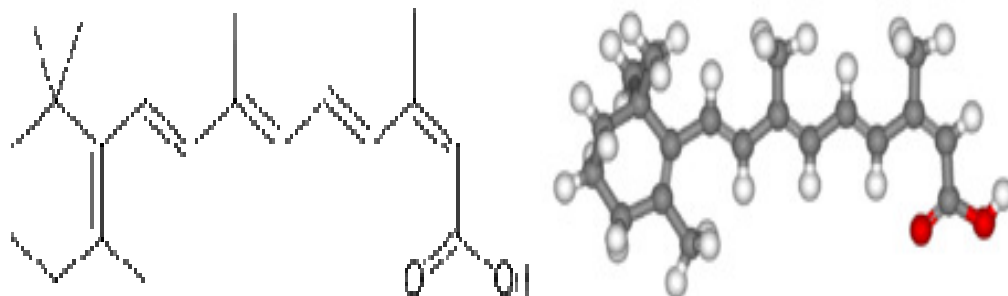
### **INTRODUCTION**

Teratology is the study of abnormal development. It is an aspect of science that studies the how and why of abnormal development. The mystery behind teratology is that certain stages of embryonic development are more vulnerable to disruption than others. Gregg (1941) provided an audience that an environmental influence (rubella virus) could cause cataracts and other developmental disruptions if it was present during the critical period of human development of the eyes, ears and heart. It was however the observation of (Kirschner and

LaRossa, 2000) that focused attention on the role of drugs in the ethnology of human birth defect. Isotretinoin is a medication used for the treatment of severe acne. It is sometimes used in prevention of certain skin cancers. It is a retinoid, meaning it derives from vitamin A and is found in small quantities naturally in the body. Oral isotretinoin is marketed under various trade names, most commonly Accutane.

Isotretinoin is still being employed tropically and systemically in dermatological treatments even after it has become evident that it caused vital side effect (Amichai et al., 2006). Retinoic acid, a derivative of vitamin A just as isotretinoin, has been reported to result in delayed palatal shelf elevation and subsequent clefts in the secondary palate (Hendrickx et al., 1980). Going by the dynamic and

\*Corresponding author. E-mail: davidofus234@yahoo.com . Tel: +234-803-445-5715.



**Figure 1.** The chemical structure of isotretinoin. (2Z,4E,6E,8E)-3,7-dimethyl-9-(2,6,6-trimethyl-1-cyclohexenyl)nona-2,4,6,8-tetraenoic acid.

complexity in palate development, Hendrickx et al. (1980) were not surprised that the system is susceptible to change in retinoic levels. This is because it was evidenced that experimental manipulation of retinoic status during development alters normal transforming growth factor beta (TGF-beta) status. Eleny et al. (2001) compared the tooth germs of the first maxillary and mandibular molars of fetal mice subjected to isotretinoin. The results showed that the epithelial cells and the first molar germs of the isotretinoin-treated animals showed delay development. Retinoic acid is teratogenic in humans at very low doses. The critical exposure time is between 3 - 5 weeks of pregnancy, often before the woman knows she is pregnant. Isotretinoin is the active ingredient in Accutane®, a drug used to treat severe acne (Chee Hong and Isaac, 2003). Since its introduction in September 1982, an estimated 160,000 women of child bearing age have ingested the drug. Between 1982 and 1987, approximately 900 - 1,300 malformed children, 700 - 1000 spontaneous abortion and 5000 - 7000 elective abortions are due to Accutane® (O'Donnell, 2003). The structural analogues of vitamin A which include isotretinoin and tretinoin are different just in the acid tail direction (Giovanna, 1992). The chemical structure of isotretinoin is presented in Figure 1.

The effect of isotretinoin on the secondary palate has been studied by the following authors: Lorente et al. (1978), Kronmiller et al. (1992), Webster et al., (1986) and Ofusori (2003). The literature is almost completely lacking in information about definitive effect of isotretinoin on the morphology of the fetuses including cleft lip and cleft (primary) palate. On the other hand, all the reports were centered on the secondary palate. Lammer et al (1985) also reported that the exposure of retinoic acid during pregnancy may result in craniofacial alterations which include cleft in the secondary palate.

Since drugs that are systemic dependent can present an anomaly in developing structures, we set to investigate the teratogenic effect of isotretinoin on the closure between maxillary prominences and the medial nasal prominences, palatal shelves elevation and morphological alterations in rat fetuses during organogenesis. This

is in line with the conclusion of Eun-Hwang et al., (1996) who revealed that craniofacial anomaly (cleft palate in particular) could be observed postnatally while elevated maternal serum alpha-fetoprotein is a useful tool for pre-natal cleft palate detection.

## MATERIALS AND METHODS

### Care of the animals and experimental design

Thirty six adult female albino rats (Wistar strain) weights between 150 - 200 g were used for the experiment. They were maintained with granular ration (Bendel feeds, Ilorin, Nigeria) and provided with water *ad libitum*. The environmental condition is as follows: temperature of 20°C and relative humidity of approximately 50%. The animals were randomly assigned into groups A, B and C (n = 12). The animals were acclimatized for two weeks in the animal holdings of Department of Human Anatomy University of Ilorin, Nigeria. Group A was further subdivided into A1 and A2 (n = 4) and administered orally (using metallic oropharyngeal canula and calibrated hypodermic syringe) with 35 and 70 mg of isotretinoin (dissolved in vegetable oil) per kg of average body weight on day 11 of gestation. The same subdivision and administration goes for groups B and C, but on days 12 and 13 respectively. The control group for each group (n = 4) received an equivalent volume of vegetable oil on gestational days 11, 12 and 13. The care and handling of the animals conform to the rules and guidelines of the animal right committee of the University of Ilorin, Ilorin, Nigeria.

### Procedure for mating animals

Vagina smear test was first taken on a daily basis prior to mating. This was done to observe the ovulating circle of the female rats. These smears were examined under light microscope to identify the cells and monitor the stage of the estrus circle. This was being carried out between the hours of 7 - 9 am every day (Mandi, 1951). The predominant presence of uniformly large nucleated epithelial cells indicated pro estrus stage, large squamous cells which are leave-like in shape (cornified cells) indicated estrus stages (ovulation has occurred) and predominant presence of leucocytes with or without epithelial cells indicated the diestrus stage I and II which is the longest. The normal estrus cycle takes a total period of about 4 - 5 days. At the proestrus stage is when the male Wistar rats were introduced in order to mate the female. Normal vagina smear were still carried out after the introduction of the male. This

**Table 1.** Maternal average weight record before pregnancy and after delivery (g).

Group	Parameter	Control	Subgroup 1	Subgroup 2
A	Initial weight	161.3	153.5	153.3
	Final weight	163.1	149.2	148.0
B	Initial weight	178.6	163.3	161.0
	Final weight	180.2	158.3	154.5
C	Initial weight	157.3	166.6	150.0
	Final weight	160.5	162.3	145.5

**Table 2.** Crown-rump length (mm) and the weight (g) of the rat fetuses (mean  $\pm$  SEM).

Group	Parameter	Control	Subgroup 1 (35 mg/kg)	Subgroup 2 (70 mg/kg)
A	C-R	22.32 $\pm$ 0.01	20.01 $\pm$ 0.02*	19.47 $\pm$ 0.23* **
	WT	1.11 $\pm$ 0.07	0.94 $\pm$ 0.05*	0.92 $\pm$ 0.06*
	NO	6	14	18
B	C-R	22.31 $\pm$ 0.08	20.76 $\pm$ 0.19*	20.16 $\pm$ 0.22* **
	WT	1.13 $\pm$ 0.07	1.05 $\pm$ 0.08*	1.00 $\pm$ 0.11*
	NO	5	14	14
C	C-R	22.32 $\pm$ 0.06	21.10 $\pm$ 0.17*	21.00 $\pm$ 0.18* **
	WT	1.14 $\pm$ 0.05	1.12 $\pm$ 0.19	1.02 $\pm$ 0.08*
	NO	3	14	14

C-R = Crown-rump; WT = weight; NO = numbers of litters. \*P<0.05 (significant) vs. control; \*\*P<0.05 (significant) subgroup 1 vs. subgroup 2.

was being aimed at detecting the presence of spermatozoa in the smear and the day when spermatozoa were observed or vagina plug noticed was taken as the first day of pregnancy and based on this, the age of the pregnancy was determined.

#### Collection of fetuses

The animals were weighed before pregnancy and after delivery. At the end of the gestational days, the number of viable fetuses was recorded. The crown-rump length of the fetuses were taken using a flexible tape measure and recorded to the nearest millimeter. The weight of the fetuses and the placenta were taken using a sensitive (P153) Metler balance and recorded to the nearest grams. The head of the fetuses were decapitated and the regional craniofacial anormally studied using Celestron dissecting microscope (Ritchie and Webster, 1991). All the fetuses were critically observed for any morphological alteration or resorption.

#### Statistical analysis

Values of some data were expressed as mean  $\pm$  SEM and analyzed by students' t-test using statistical software STATISTICA VERSION 5. Differences below the 0.05 (P <0.05) were considered significant.

## RESULTS

### Maternal observation

During the period of administration to the end of gesta-

tion, a drop in the fur of the treated groups was noticed. This observation was concomitant with a loss in weight in the animals. The loss in weight in the treated animals was observed to be dose dependent (Table 1).

### Fetal observation

A close observation of the experimental fetuses showed that most of the fetuses present some adverse condition of ill health. Even though all the fetuses were viable (Table 4), there is weight loss in the treated group as compared with the control (Table 2). The weight loss is dose dependent as the weights of the animals in subgroup 2 (administered with 70 mg/kg of isotretinoin) were significantly different from those in subgroup 1 (Table 2). The mean weights of the placenta were observed to be low in subgroup 1 and control (Table 3). Fetuses got from group A were observed and the primary palate was mostly affected. Animals with bilateral cleft lip with cleft palate (BCLP) were higher in percentage than unilateral cleft lip with cleft palate (UCLP) (Table 4). Fetuses got from group B had more of their secondary palate affected; this was noticed to be dose dependent (Table 4). The extent of malformation in both the primary and secondary palate from fetuses in group C was mild i.e. less than 50% (Table 4) while most of the fetuses showed no malformation.

**Table 3.** Weights of the rat placenta (g) (mean  $\pm$  SEM).

Group	Control	Subgroup 1 (35 mg/kg)	Subgroup 2 (70 mg/kg)
A	2.22 $\pm$ 0.14	1.88 $\pm$ 0.12*	1.84 $\pm$ 0.10*
B	2.26 $\pm$ 0.15	2.10 $\pm$ 0.16*	2.00 $\pm$ 0.22*
C	2.28 $\pm$ 0.10	2.26 $\pm$ 0.38	2.04 $\pm$ 0.16*

n= 7; \*P<0.05 (significant) vs. control.

**Table 4.** Combination of various abnormalities of the palate and other abnormalities in rat fetuses.

Group		Viable fetuses		BCLP		UCLP		NC		CSP		BCP		UCL		MA	
		r.f	(%)	r.f	(%)	r.f	(%)	r.f	(%)	r.f	(%)	r.f	(%)	r.f	(%)	r.f	(%)
A	Control	6.00	100	0.00	0.00	0.00	0.00	6.00	100	0.00	100	0.00	0.00	0.00	0.00	0.00	0.00
	Sub G. 1	14.00	100	6.00	42.90	5.00	35.71	2.00	14.29	1.00	7.14	0.00	0.00	0.00	0.00	0.00	0.00
	Sub G. 2	18.00	100	10.00	55.56	6.00	33.33	1.00	7.14	1.00	7.14	0.00	0.00	0.00	0.00	0.00	0.00
B	Control	5.00	100	0.00	0.00	0.00	0.00	5.00	100	0.00	100	0.00	0.00	0.00	0.00	0.00	0.00
	Sub G. 1	14.00	100	2.00	14.29	3.00	21.43	2.00	14.29	7.00	50.00	0.00	0.00	0.00	0.00	0.00	0.00
	Sub G. 2	14.00	100	1.00	7.14	1.00	7.14	2.00	14.29	10.00	71.43	0.00	0.00	0.00	0.00	0.00	0.00
C	Control	3.00	100	0.00	0.00	0.00	0.00	3.00	100	0.00	100	0.00	0.00	0.00	0.00	0.00	0.00
	Sub G. 1	14.00	100	1.00	7.14	1.00	7.14	10.00	71.43	2.00	14.29	0.00	0.00	0.00	0.00	0.00	0.00
	Sub G. 2	14.00	100	2.00	14.29	1.00	7.14	8.00	57.14	2.00	14.29	0.00	0.00	0.00	0.00	0.00	0.00

BCLP = Bilateral cleft lip with cleft palate; UCLP = unilateral cleft lip with cleft palate; NC = no cleft at all; CSP = cleft of the secondary palate; BCL = bilateral cleft lip only; UCL = unilateral cleft lip only; MA = any other Morphological abnormalities; r.f = raw figure.

## DISCUSSION

This study investigated the teratogenic effect of isotretinoin currently used in dermatological treatment on the fetuses of animals subjected to 35 and 70 mg of isotretinoin per kg average body weight on days 11, 12 and 13 of gestation. This was in an attempt to verify the effect of the systemic use of isotretinoin on the merging of the maxillary prominences with the medial nasal prominences, the elevation of the palatal shelves and the possibilities of other morphological resorptions. Although the mechanism of action of isotretinoin leading to the drop in fur of the treated

group is still unclear but it is known that like other retinoids, isotretinoin works by altering DNA transcription (Bremner, 2003).

This effect decreases the size and output of sebaceous glands, makes the cells that are sloughed off into the sebaceous glands less sticky, and therefore less able to form comedones. A loss in the weight of the maternal after delivery as compared to the weight before gestation and the control group (Table 1) could be a symptom of ill health which must have been caused by the release of free radicals. This is related to the investigation of Akpantah et al. (2006) who also discovered the same symptom in Sprague-Dawley

rat administered with alcohol. Halliwell and Gutteridge (1999) also related systemic toxicity to the release of free radicals and hence a loss in weight which is an index of ill health. Although Kocchar and Penner (1987) said this drug has a low toxicity in pregnant mice, they also concluded that continuous use of this drug might cause defect in organs. The same toxicity was reflected in the significant weight loss in the fetuses of the treated group as compared with the control (Table 2). This weight loss is concomitant with the reduction in the crown-rump length of the fetuses (Table 2). This suggests that even though all the fetuses are viable (Table 4), administration of

isotretinoin at certain critical period is teratogenic (Webster et al., 1986). The work of Kocchar (1967) which affirms the ability of isotretinoin to cross the placenta, explains the reason for the weight loss (Table 3).

The mechanism of action of isotretinoin on the placenta has not been completely elucidated, but may be connected with the reduction in the fibers of the connective tissues in the villus core of the placenta membrane (Sadler, 1995). These fibers which are expected to provide the placenta with the pulsatile flow of the exchanged metabolites and gaseous products between maternal and fetal blood stream must have been impeded by the systemic presence of isotretinoin. The weight loss in the placenta of the treated group is dose dependent ( $P > 0.05$ ) which affirms its severity when taken in high quantity. Shalita et al. (1983) on their work on the teratogenic effect of isotretinoin in humans, revealed that it cause multiple lesions as congenital malformation. It was, however, not surprising when congenital malformation of the palate with cleft lip was the aftermaths of this investigation. The effect of isotretinoin on primary palate which is lacking in information was studied together with the philtrum and the secondary palate.

Data from the results (Table 4) showed that group A which was administered with isotretinoin on day 11 of gestation, had more of their primary palate malformed. Bilateral cleft lip with cleft palate was predominant (78.61 and 88.89% for subgroups 1 and 2, respectively). This could be due to the teratogenic influence of isotretinoin on the crest cells migrating into the region of fusion of the maxillary prominences with the medial nasal prominences on both sides (Sadler, 1995) consequently preventing the mesenchymal masses in the maxillary prominences to meet and unit with the merged medial nasal prominences. Fetuses got from group B had most of their secondary palate affected (50.00 and 71.43% for subgroups 1 and 2, respectively) (Table 4). This may be related to the administration of isotretinoin at the critical period when the palatal shelves are to elevate.

The works of Webster et al. (1986) and Ritchie and Webster (1991) revealed that this drug *in vitro* or *in vivo* administered 6 h before cell migration from the neural crest was sufficient to induce severe defects in the second branchial arch in the great majority of the exposed embryos. Fetuses from group C had only mild malformation both in the primary and secondary palate (28.57 and 35.72% for sub groups 1 and 2 respectively). The reasons for this is still being investigated, but it is believed to be due to successful migration of some crest cells before the presence of the teratogen (isotretinoin) which eventually arrested further migration of the crest cells and hence, inhibit development of the structures involved.

The result also revealed that there are no external assaults on the fetuses by isotretinoin; but that does not mean other organs in the body are not vulnerable if the

teratogen (isotretinoin) is present during organogenesis. This therefore calls for more investigation. In conclusion, cystic acne, skin cancers and other related infections common with pregnant women should be courteously treated if isotretinoin is to be employed at all; most especially during the first and second trimester of pregnancy.

## ACKNOWLEDGEMENT

The authors are sincerely grateful to the staff of the Biochemistry Department, University of Ilorin, Ilorin, Nigeria for their enormous contribution during the research work.

## REFERENCES

- Akpantah AO, Olabiyi OA, Oremosu AA, Noronha CC Okanlawon AO (2006). Assessment of the antioxidant potential of alcoholic extract of *Garcinia kola* seed in alcohol induced testicular oxidative stress in Spague-Dawley rat. *Nig. J. Health BioMed Sci.* 5(1): 37-42.
- Amichai B, Shemer A, Grunwald M (2006). "Low-dose isotretinoin in the treatment of acne vulgaris". *J. Am. Acad. Dermatol.* 54 (4): 644-6.
- Bremner JD (2003). Does isotretinoin cause depression and suicide? *Psychopharmacol Bull;* 37(1):64-78.
- Chee Hong N, Isaac S (2003) The association between depression and isotretinoin use in acne, *Austr. N. Z. J. Psychiatry* 37(1): 78-84.
- Di-Giovanna JJ (1992). Retinoids for the future: oncology. *J Acad Dermatol* 27: 534-537.
- Eleny BR, Karina GS, Maria AJ (2001). effect of isotretinoin on tooth germ and palate development in mouse embryos. *Braz. Dent. J.* 12(2): 115-119 ISSN 0103-6440
- Eun-Hwang J, Jae-Sook R, Chi-Seok A (1996). Elevated maternal serum Alpha-Fetoprotein in cleft lip and palate. *Chungbuk Med. J.* 6(1): 149-153.
- Gregg NM (1941). Congenital cataract following German measles in mothers. *Trans ophthalmol Soc Aust.* 3: 35.
- Halliwell B, Gutteridge M (1999). *Reproduction and oxidative stress. Free radicals in Biology and Medicine* 2<sup>nd</sup> ed. Oxford Uni. Press. New york; 522-529.
- Hendrickx AG, Silverman S, Pellegrini M, Steffek AJ (1980). Teratological and radiocephalometric analysis of craniofacial malformation induced with retinoic acid in "Rhesus monkeys". *Teratology;* 22: 13-22.S
- Hong Ng C, Schweitzer I (2003). The association between depression and isotretinoin use in acne *Australian and New Zealand Journal of Psychiatry* 37 (1): 78-84.
- Kirschner RE, LaRossa D (2000). Syndromic and other congenital anomalies of the head and neck. *Otolaryngologic Clinics of North America.* 33 (6): 1191-1215.
- Kocchar DM (1967). Teratogenic activity of retinoic acid. *Acta. Pathol. Microb. Scand;* 70:398-404.
- Kocchar PM, Penner JD (1987). Development effect of Isotretinoin and 4-oxo-isotretinoin: The role of metabolism in teratogenicity. *Teratology;* 36: 65-75.
- Kronmiller JE, Upholt WB, Koller GJ (1992). Retinol alters murine odontogenesis patterning and prolongs EGFm RNA expression in vitro. *Arch. Oral. Biol.* 37:129-138.
- Lammer EJ, Chen DT, Hoar RM, Agnish ND, Benke PJ, Braun JT (1985). Retinoic acid embryopathy. *N. Engl. J. Med.*, 313: 837-41.
- Lorente CA, Miller SA (1978). Vitamin A induction of cleft palate. *Cleft palate J;* 15: 378-385.
- Mandi AM (1951). Cyclic changes in the vaginal smear of adult varietotomized rat. *J. Exp. Biol.* 28: 585-592.
- O'Donnell J (2003). Overview of existing research and information linking isotretinoin (accutane), depression, psychosis, and suicide. *Am. J. Ther.* 10(2):148-59.

- Ofusori DA (2003). Effect of different concentrations of isotretinoin on palate development in rat fetuses. B Sc. Thesis, University of Ilorin, Ilorin, Nigeria.
- Ritchie H, Webster WS (1991). Parameters determining isotretinoin teratogenicity in rats' embryo culture. *Teratology* 43:71-81.
- Sadler TWE (1995). *Langman's medical embryology* 7<sup>th</sup> ed. pp. 333-340.
- Shalita AR, Cunningham WJ, Leyden JJ, Pochi PE, Staruss JS (1983) Isotretinoin treatment of acne and related disorders: An update. *J Am Acad Dermatol*; 9:629-638.
- Webster WS, Johnston ST, Lammer GJ, Sulikk KK (1986) Isotretinoin embriopathy and cranial neural crest. An *in vivo* study. *J. Craniofac. Genet Dev Bio*; 6: 211-222.