

Full Length Research Paper

Role of green tea on nicotine toxicity on liver and lung of mice: Histological and morphometrical studies

Azza M. Gawish^{1*}, Aliaa M. Issa¹, Nahed S. Bassily² and Sherin M. Manaa²

¹Department of Zoology, Faculty of Science, Cairo University, Egypt.

²National Organization for Drug Control and Research, Dokki – Giza, Egypt.

Accepted 29 August, 2011

Nicotine is the more abundant component in cigarette smoking. The natural diet contains a variety of compounds, such as green tea that exhibit protective effects towards different toxicities. Nicotine is firstly metabolized in liver, and the lung is the main target organ susceptible to smoking; so, this study was aimed to investigate the effects of nicotine on this organs using histopathological and morphometrical methods and study the protective effect of green tea against toxicity of nicotine. Four groups of the male Swiss albino mice were used: untreated control group; nicotine-treated group (2.5 mg/kg/day); green tea-treated group (40 mg/kg/day); and nicotine and green tea intraperitoneally treated group for 28 days. The histological examinations of this study revealed a damage and degeneration in the lung and liver tissues of the nicotine treated animals. Green tea administration to nicotine-treated mice showed reduction in the tissues damage associated with the nicotine administration. Green tea administration to nicotine-treated mice ameliorated the increase in the size of nucleus of liver and restored the normal distribution of elastic fibers in lung. These results, along with previous observations, suggest that green tea may be useful in combating tissue injury that is a result of nicotine toxicity. Hence, the intake of green tea might suppress the toxicity and mutagenic activity of nicotine.

Key words: Nicotine, green tea, cigarette smoking, toxicity, apoptosis.

INTRODUCTION

Nicotine is a naturally occurring alkaloid found in the nightshade family of plants (*Solanaceae*), predominantly in tobacco plant (*Nicotiana tabacum*) (Wu et al., 2002). Hellermann et al. (2002) recorded that the LD₅₀ of nicotine was 50 mg/kg for rats and 3 mg/kg for mice; 40 to 60 mg and 0.5 to 1.0 mg/kg could be lethal for adult humans. Nicotine and its metabolites are also being investigated and researched for the treatment of a number of disorders such as Alzheimer's disease (Hecht, 2003). Nicotine has many effects such as on heart rate, brain excitation, and blood pressure (Shivij et al., 2006).

Wu et al. (2002) reported that nicotine induced a wide range of biological effects and is a major risk factor in the development of chronic obstructive lung diseases, cardio-

vascular disorders and lung cancer. Nicotine through smoking, induced an inflammatory response in the lung and plays a role in pathogenesis of obstructive pulmonary diseases (Carpagnano et al., 2003; Hackett et al., 2003). Apoptosis is strongly induced in alveolar epithelium exposed to smoking (Piipari et al., 2000). During smoking, nicotine is rapidly absorbed into the circulatory system where more than 80% is metabolized in the liver (El – Zayadi, 2006). Nicotine is absorbed through the lungs and eliminated from the blood. The rapid elimination of nicotine has been attributed to its metabolism, as well as distribution to some tissues (Carpagnano et al., 2003).

Liver is an important organ that has many tasks, and is responsible for processing drugs, alcohol and other toxins to remove them from the body. Nicotine from heavy smoking increases the risk of developing hepatocellular carcinoma (HCC), chronic liver diseases and finally hepatocellular carcinoma. In addition, nicotine

*Corresponding author. E-mail: Azzagawish@gmail.com.

increases the production of pro-inflammatory cytokines that would be involved in liver cell injury (El -Zayadi 2006). Also, nicotine is known to induced oxidative stress and depletes antioxidant defense mechanisms; produced reduction in glutathione peroxidase in circulation, lung, liver and kidney of nicotine-treated animals (Yildiz, 2004; Muthukumaran et al., 2008). Nicotine also increases both free fatty acid release from the liver and the hepatic synthesis of very low-density lipoproteins; also maternal nicotine exposure induced oxidative stress and causes histopathological changes in the lung and liver of lactating offspring (El-Sokkary et al., 2007). Ozukutat et al. (2005) reported that nicotine induces oxidative stress both *in vitro* and *in vivo* and depleted antioxidant defense mechanisms through reduction of glutathione peroxidase in liver, lung and kidney.

Green tea is a rich source of polyphenols, which are antioxidants in nature. Among the various types of tea, green tea contains a relatively high level of polyphenols, which consist of avanol monomers (.avan-3-ols), also referred to as catechins (Chen et al., 2002). Natural antioxidants, such as polyphenols from green tea extracts, have recently attracted considerable attention for preventing oxidative stress-related diseases including cancers, cardiovascular diseases and degenerative diseases (Ogura et al., . 2008). Among the various types of tea, green tea which contains a relatively high level of polyphenols, consist of catechins (Chen et al., 2002; Sriram et al., 2008). Animal-model studies have associated green tea consumption with health benefits, including decreased risk of inflammation (Chan et al., 1997; Katiyar et al., 2001). *In vitro* study showed that green tea polyphenols can reduce DNA strand breakage induced by cigarette smoke in cultured human bronchial cells (Leanderson et al., 1997). The results demonstrate that green tea can significantly reduce DNA damage caused by polyphenols (Zhong et al., 2002).

Tea polyphenols showed a protection role against liver injury in many animal models of liver diseases, liver fibrosis, and hepatic ischemia-reperfusion injury (Zhong et al., 2002; Chen et al., 2002). Histological and hepatic examination revealed that EGCG significantly arrested the progression of hepatic fibrosis and partially the formation of lipid peroxidative products (Zhen et al., 2007). Antioxidant properties, ROS scavenging, and cell function modulation of flavonoids could account for the large part of their pharmacological activity (Sriram et al., 2008). It was demonstrated that drinking green tea with high catechin content help to prevent and/or attenuate the development of fibrosis in hepatitis among dogs (IBA et al., 1998). Green tea is a popular beverage consumed worldwide, and it also possesses chemopreventive effects in a wide range of target organs in rodent carcinogenesis models (Safe et al., 1999; Yokozawa et al., 2004). The objective of this study was to evaluate the toxic effects of nicotine on lung and liver and the possible protective effects of naturally occurring antioxidants (the green tea)

using histological and histomorphometrical techniques.

MATERIALS AND METHODS

Experimental animals

The experimental animals used in this study were male Swiss albino mice. 80 male Swiss albino mice aged nine to 12 weeks and weighing 25 to 30 g were used throughout the study. Animals were fed commercially prepared diet and had free access to tap water. All mice were kept under the same experimental condition, fed standard diet, and water was available *ad libitum*. After one-week acclimatization period, the selected animals of nearly a similar weight were divided into four experimental groups so as to keep more or less the same mean body weight within the individual groups. The selected animal groups (five animals per each group) were treated as follows: control group: each animal in this group was injected intraperitoneally with distilled water (1 ml/ day) for successive 28 days and handled on the same conditions; nicotine-treated group (NI): each mouse in this group was given intraperitoneally nicotine (2.5 mg/kg/day) for successive 28 days; green tea-treated group: for successive 28 days, each mouse in this group was injected i.p. with freshly prepared green tea extract (40 mg/kg body weight/day); nicotine-green tea-treated group: each animal in this group was given i.p. of nicotine (2.5 mg/kg/day) at the same dose as group 1 with green tea extract (40 mg / kg body weight) at the dose as for the second group for successive 28 days.

Chemicals

The treated chemicals in the experiment were nicotine ((S)-3-(1-methyl-2-pyrroli- danyl) pyridine) and green tea extract. Nicotine was supplied as colorless liquid, from the Faculty of Pharmacy, Cairo University, Egypt. The mean LD₅₀ for intraperitoneally nicotine to 8-week-old (29.6 g) mice was reported as 12.5 mg/kg or/and dose of nicotine equals to 1/5 of LD₅₀. Green tea extract was supplied in the form of tablets obtained from the Technomad Groups Company, Egypt; they were soluble in water.

Experimental design

Five mice from each group were scarified by cervical dislocation at the end of 1, 2, 3, and 4 weeks (7th, 14th, 21th and 28th days) of the experimental period and decapitated; two femurs were removed and stripped clean of muscle for cytogenetical examination. Also, lung, liver and testes were also sampled and kept in aqueous bouin for histological, histochemical and morphometrical examinations.

Experimental analysis

Histopathological examinations

For histological and morphometrical evaluation, lungs and livers of all animals groups were collected. They were fixed in aqueous Bouin solution, dehydrated through series of alcohols, cleared in xylene and then embedded in paraffin wax. 5 μ thickness paraffin sections were prepared and mounted on clean slides. For histopathological study, sections were stained with Ehrlich's haemotoxylin and counterstained with eosin according to Bancrot and Gamble (2002). A number of photomicrographs were taken at known magnification.

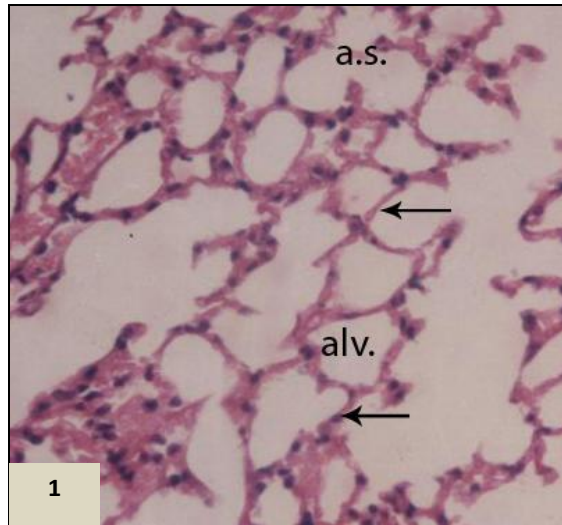


Figure 1. Micrograph of lung section in normal mouse showing the lung architecture with thin interalveolar septa (arrow) and regular alveolar sacs (a.s.). (H & E, 200x).

Image analysis

The data were obtained using Leica Qwin 500 Image Analyzer Computer System (England). The image analyzer consisted of a colored video camera, colored monitor, hard disc of IBM personal computer connected to the microscope, and controlled by Leica Qwin 500 software. The image analyzer was first calibrated automatically to convert the measurement units (pixels) produced by the image analyzer program into actual micrometer units. Using the measuring field menu, the area, percentage area and standard measuring frame of a standard area equal $7286.78 \mu\text{m}^2$ were chosen from the parameters. In each chosen field, the elastic fibers stained with orcein were enclosed inside the standard measuring frame and then they were masked by a blue binary colour to be measured. These measurements were done using an objective lens of magnification 40, that is, of total magnification 400. Ten readings were obtained in each specimen. Using the measuring menu, the liver cells nuclei were measured in ten fields for each specimen using the same magnification. The data obtained were subjected to statistical analysis using Duncan's Test.

RESULTS

Histopathological observations

Lung

Lung sections of untreated animals showed normal lung architecture with thin interalveolar septa and clear alveoli, alveolar sacs and normal alveolar septa with regular air sacs. The interalveolar spaces may be extremely narrow (Figure 1). The histological examination of lung tissue of mice treated with nicotine throughout all the intervals of the experiment revealed variable degrees of alterations. Nicotine treatment at the dose level of 2.5 mg/kg showed variable histological changes in which the alveolar septa

appeared increased in thickening with mild inflammation compared with control group. The alveoli showed extensive destruction of their walls resulting in the formation of enlarged, irregular air space and the architecture of the lung was not preserved. Also, dilated congested blood vessels were detected in intralveolar septa (Figure 2). After two weeks of treatment, the thickening of septa and irregularity and enlargement of air sacs were increased compared to previous stage. In addition, also marked dilated congested blood vessels and inflammatory cells infiltration were prominent features observed (Figure 3). At three weeks interval of experiment, the lung section showed the same changes as those of two weeks with marked deterioration in the whole lung tissue. This was evidenced with disappearance of the alveolar septa in most areas, increased irregularity and size of air sacs and destruction of normal tissue pattern. Also, inflammatory cells observed could be seen (Figure 4).

Lung sections of the mice treated with green tea after intoxication of nicotine after two weeks of treatment showed some amelioration in its architecture. This was manifested by almost normal appearance of most air sacs and interalveolar septa due to decrease in thickening of interalveolar septa and most of air sac returned to normal shape and size. Foci of inflammatory infiltration in interalveolar septa could be noticed (Figure 5). At three weeks interval, lung sections showed more amelioration in its architecture with more or less normal interalveolar septa and reduction of focal inflammatory cells compared to nicotine group at same interval of treatment; also, normal appearance of air sacs but still irregular in shape than normal (Figure 6). On the other hand, histological examination of lung section of mice treated with green tea revealed normal lung architecture, thin septa and regular air spaces, and nearly similar to the control. Focal inflammatory cells in interalveolar septa were noticed compared to the control (Figures 7 and 8).

Liver

Examination of H & E sections of the liver of the control group showed normal liver structure (Figure 9). At one week of treatment with nicotine, the liver section appeared with mild vacuolization and slight enlargement of their nuclei. This also showed mild number of Kupffer cells (Figure 10). After three weeks of treatment, many vacuoles were observed in most of the hepatocytes. Also, the nucleus-cytoplasmic ratio was changed and the hepatic sinusoids narrowed in some areas compared to previous stage (Figure 11). At four weeks of treatment, the liver section appeared with variable changes and marked injury. These changes were evidenced by disruption of tissue architecture, and sever vacuoles degeneration in the majority of hepatocytes. Also, the blood sinusoids disappeared in most areas of hepatic tissue and increased Kupffer cells compared to previous

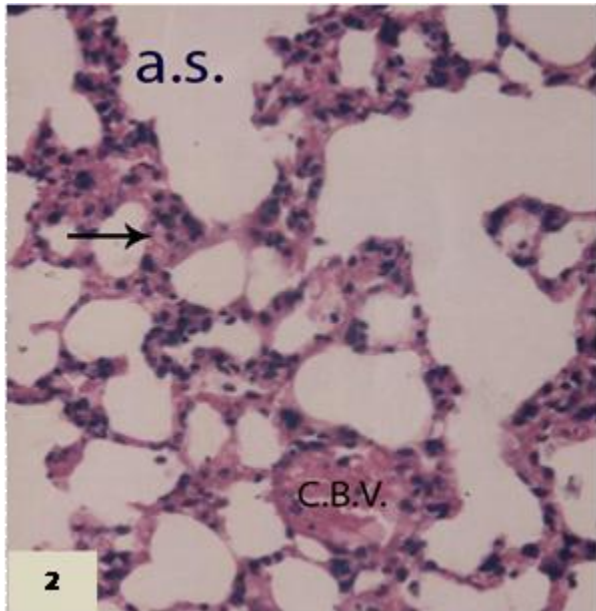


Figure 2. Micrograph of lung section of mouse treated with 2.5 mg/kg nicotine for a week showing mild proliferation of cells of alveoli septa with mild inflammation (arrows) and enlargement of irregular air sac (a .s.). (H & E, 200x).

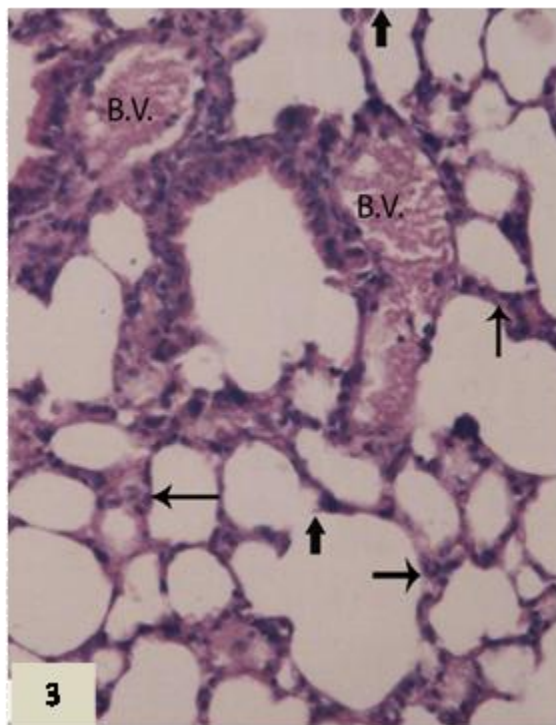


Figure 3. Micrograph of lung section of mice treated with 2.5 mg/kg nicotine for two weeks showing thickened septa (thin arrow) and marked dilated congested blood vessels in the alveolar septa (B.V.). Marked irregular air spaces (a.s.) and rupture of the walls of some alveoli (thick arrow). (H & E, 200x).

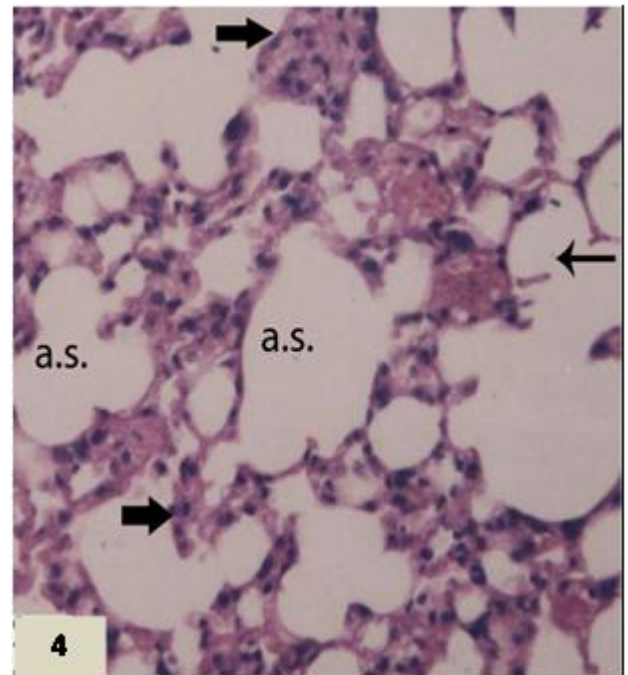


Figure 4. Micrograph of lung section of mice treated with 2.5 mg/kg nicotine for three weeks showing disappearance of some alveolar septa (thin arrow) and other with thickened walls (thick arrow). Also, enlarged air spaces appeared (a.s.). All figures: (H & E, 200x).

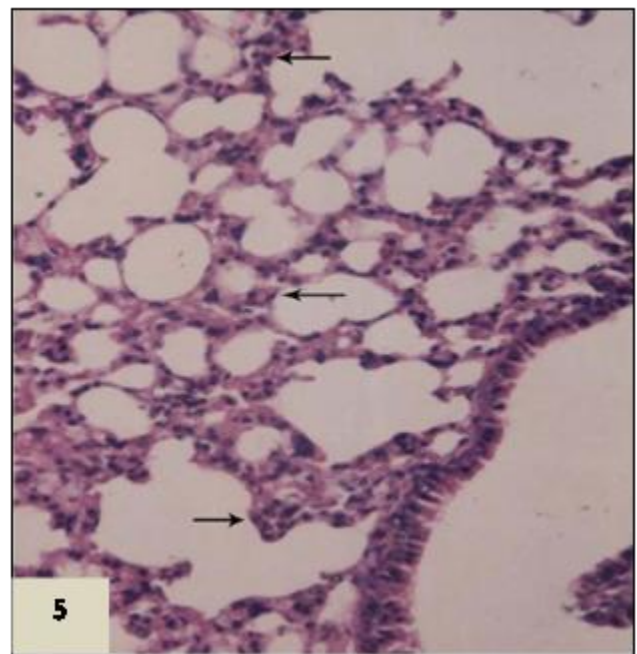


Figure 5. Micrograph of lung section treated with 40 mg/kg of green tea after intoxication with 2.5 mg/kg nicotine for two weeks showing more or less normal appearance of interalveolar septa with mild infiltration of inflammatory cells (arrow), and most of air space appeared normal and regular (a .s.). (H & E, 200x).

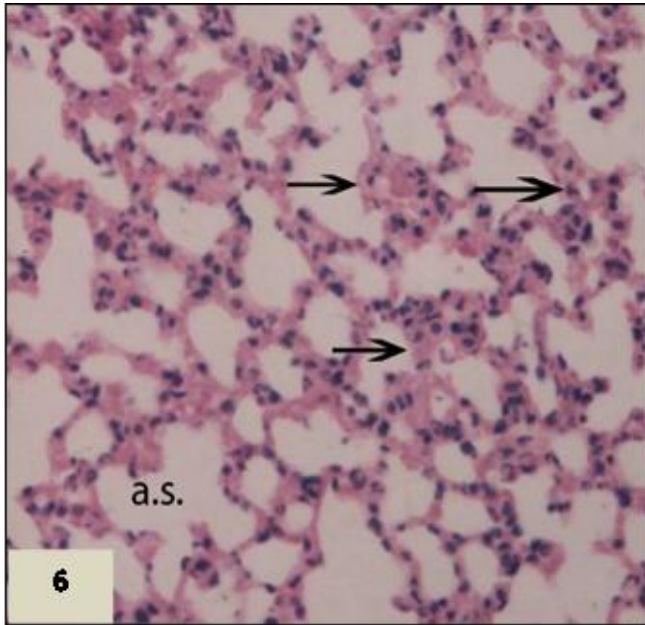


Figure 6. Micrograph of lung section of male mouse treated with 40 mg/kg green tea after 2.5 mg/kg nicotine for three weeks showing few air sacs seemed irregular in size (a .s.), thin septa with limited inflammatory cells infiltration (arrow). (H & E, 200x).

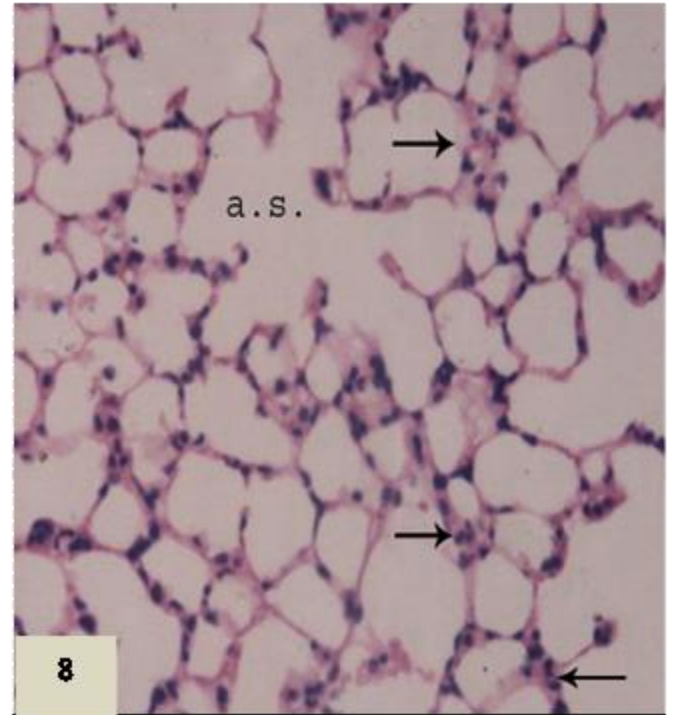


Figure 8. Micrograph of lung section of mouse treated with green tea for four weeks showing thin alveolar septa (arrow). (H & E, 200x).

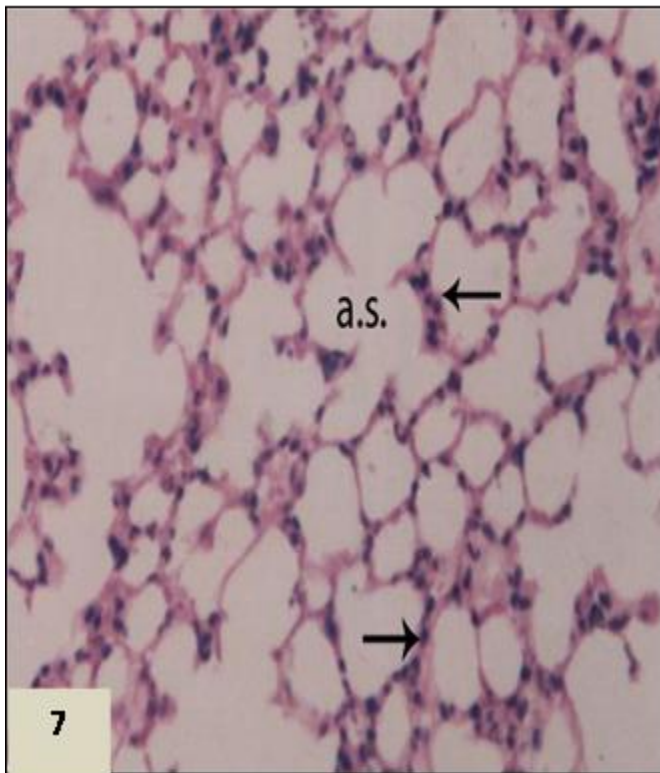


Figure 7. Micrograph of lung section of mouse treated with 40 mg/kg green tea for three weeks showing normal lung structure with mild inflammatory cells in thin alveolar septa (arrow) and most of air sac had normal appearance (a.s.). (H & E, 200x).

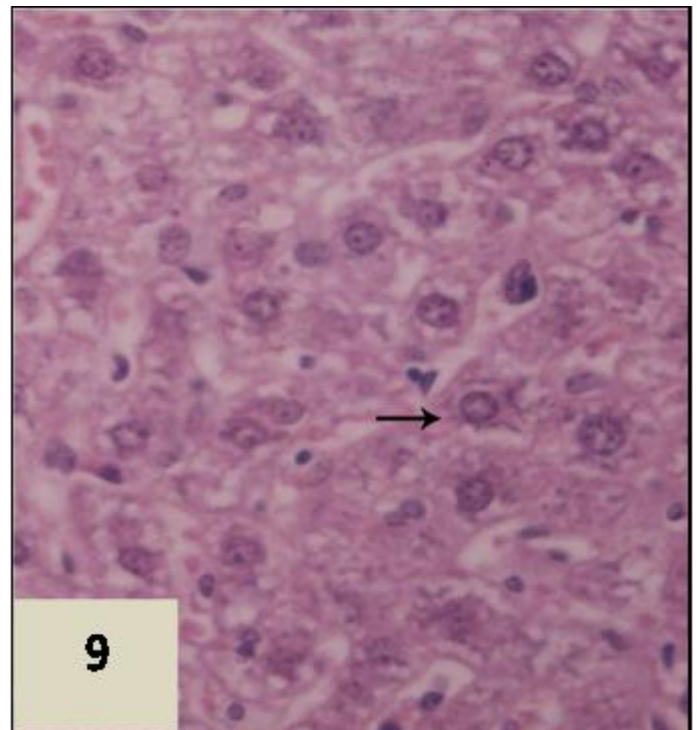


Figure 9. Micrograph of liver section of mice in normal group showing a normal liver structure with normal hepatocytes (arrow). (H&E, 200x).

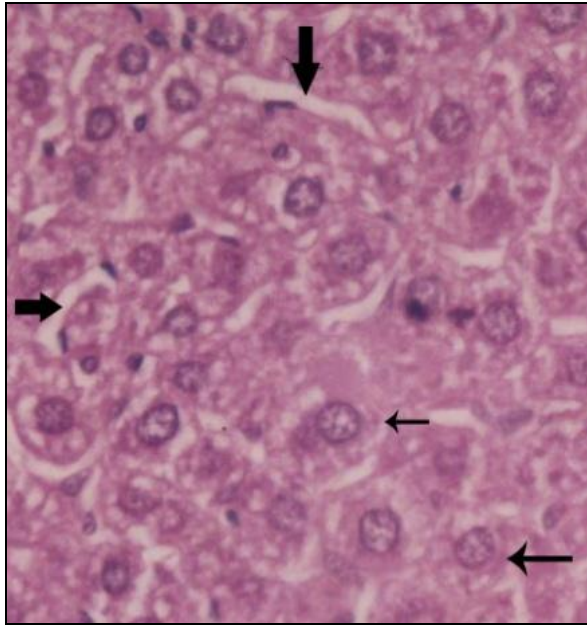


Fig. (10): Micrograph of liver section of mouse daily treated with nicotine for one weeks showing moderate vacuolation (thin arrow) in some of hepatocytes, more or less normal structure of liver and more distributed Kupffer cells (thick arrow). (H & E, X 200).

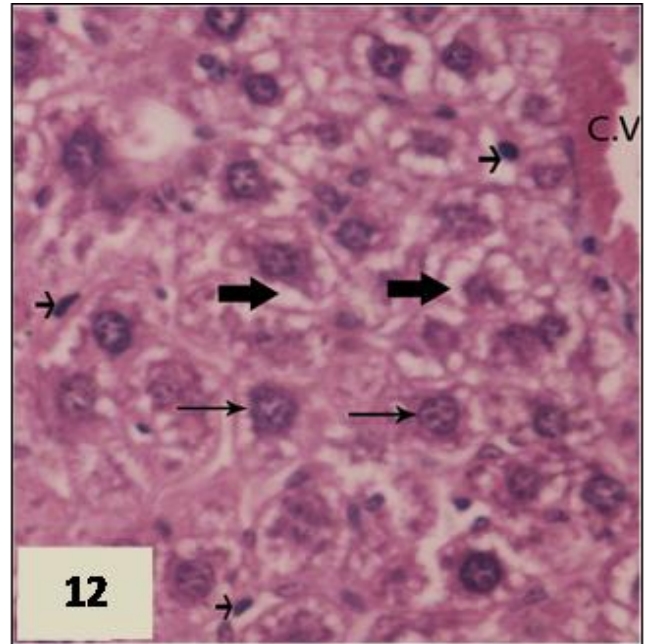


Figure 12. Micrograph of liver section treated with nicotine for four weeks showing a mild to moderate vacuolation in cytoplasm of hepatocytes (thick arrow) and round nuclei (thin arrow). (H & E, 200x).

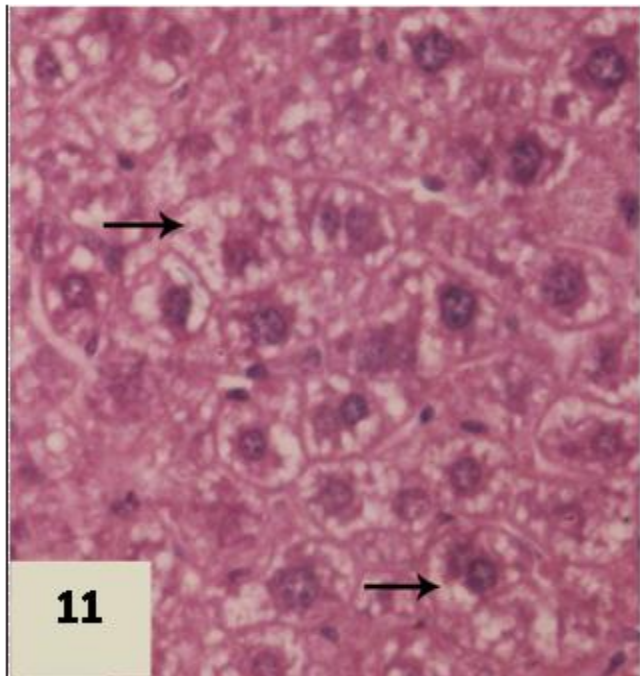


Figure 11. Micrograph of liver section treated with nicotine for three weeks showing a normal liver structure with a few vacuolation (arrow) in some of hepatocytes and focal inflammation. (H & E, 200x).

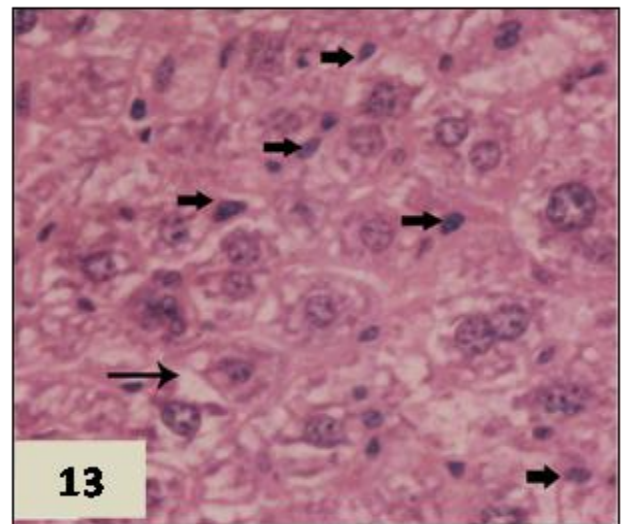


Figure 13. Micrograph of liver section treated with green tea concomitantly with nicotine for three weeks showing normal hepatocytes (thin arrow), focal congested sinusoids (thick arrow) and mild to moderate vacuolation (arrow with large head). (H&E, 200x).

stages of nicotine treatment and control stages (Figure 12).
Treatment with (2.5 mg/kg) nicotine and (40 mg/kg)

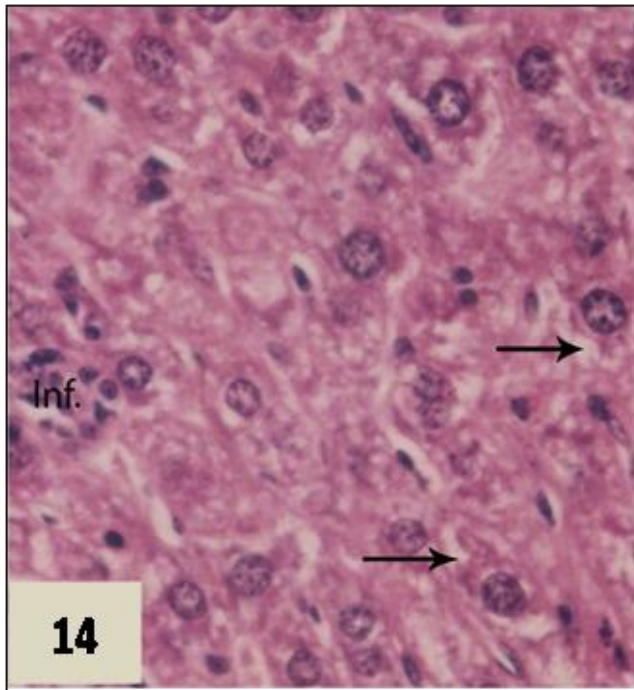


Figure 14. Micrograph of liver section treated with green tea concomitantly with nicotine for four weeks showing a normal liver structure with a few vacuolation and low depletion in cytoplasm (arrow) and focal inflammatory inflammation (IF.). (H&E, 400 \times).

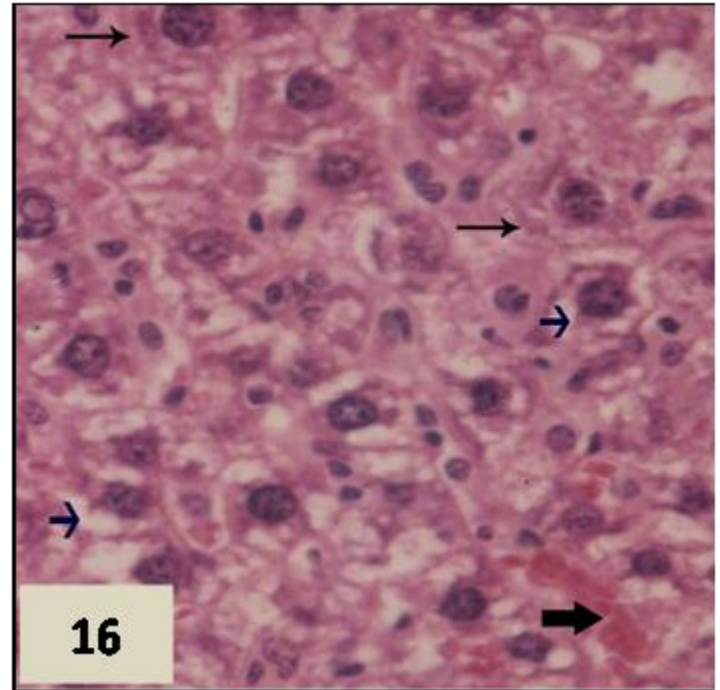


Figure 16. Micrograph of liver section treated with green tea for four weeks showing normal hepatocytes with focal congested sinusoids (thick arrow) and mild moderate fatty degeneration. (H&E, 400 \times).

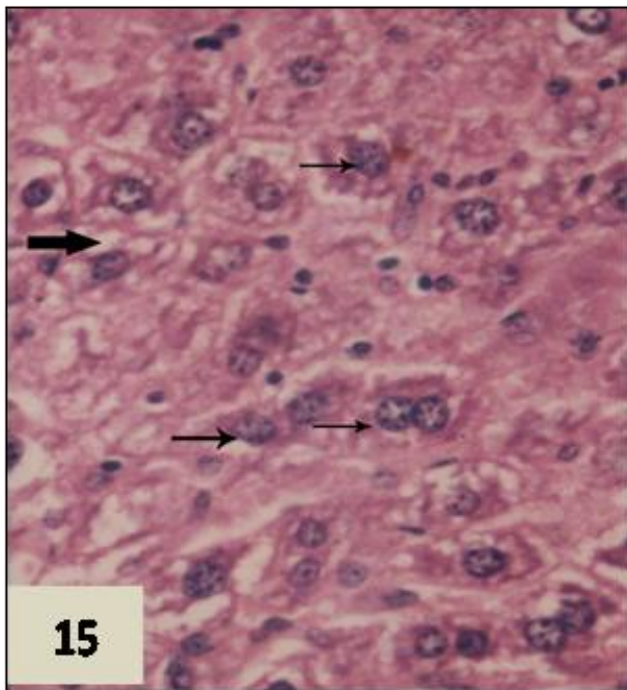


Figure 15. Micrograph of liver section treated with green tea for three weeks showing a mild to moderate fatty degeneration in cytoplasm of hepatocytes (thick arrow) and vesicular round nuclei (thin arrow) (H&E, 400 \times).

green tea showed normal liver structure with normal apparent and decrease in hepatocytes vacuolization compared with nicotine group, at three weeks of treatment; the liver sections showed much amelioration in the liver tissue compared to nicotine groups (Figure 13). At the end of the experiment, green tea reduced liver injury due to nicotine toxicity and largely suppressed activation of Kupffer cells and restored more or less normal size of nucleus and sinusoidal space. The sizes of nucleus, number of nucleolus, appeared compared to nicotine treated group at same stage of treatment (Figure 14). At third week of treatment with green tea alone, similar architecture to the control group such as vesicular round nuclei with mild fatty degeneration or vacuolation in focal area of hepatocytes was exhibited (Figure 15). At four weeks of treatment with green tea, liver section indicated normal liver histology and architecture (Figure 16).

Morphometric results

Table 1 and Figure 17 represented the morphometric changes of elastic fiber of liver in male albino mice during daily treatment with nicotine (2.5 mg/kg) and/or green tea (40 mg/kg). In the normal group, all Swiss albino mice had normal distribution in elastic fiber and no significant change was presented along all interval of experiment.

Table 1. Effect of nicotine and/or green tea on the % area of elastic fiber (μm^2) in lung section of Swiss albino mice.

Time of treatment	Experimental group			
	Control	Nicotine	Green tea	Nicotine-green tea
Week 1	4.49 ± 0.68 ^{Aa}	2.44±0.41C ^{Ba}	4.60±0.68 ^{ABa}	2.82 ± 0.95 ^{ABa}
Week 2	4.61 ± 1.38 ^{Aa}	2.09±0.530 ^{Aa}	4.90±0.70 ^{Aa}	2.97 ± 2.62 ^{Aa}
Week 3	4.55± 0.66 ^{Aa}	1.82±0.30 ^{Ba}	4.80±0.65 Aa	4.19 ± 1.023 ^{Aa}
Week 4	4.65 ± .622 ^{BAa}	1.64±0.46 ^{Ba}	4.90±0.82 ^{Aa}	4.57 ± 1.7 ^{1 BAa}

P < 0.05 is significant; P < 0.01 is highly significant. Numbers of experimental animals were five in all groups. Values are mean ± SE. Capitals letter compared between control treated groups, nicotine treated group, nicotine-green tea treated group and green tea treated group; small letter, compared within group of each group.

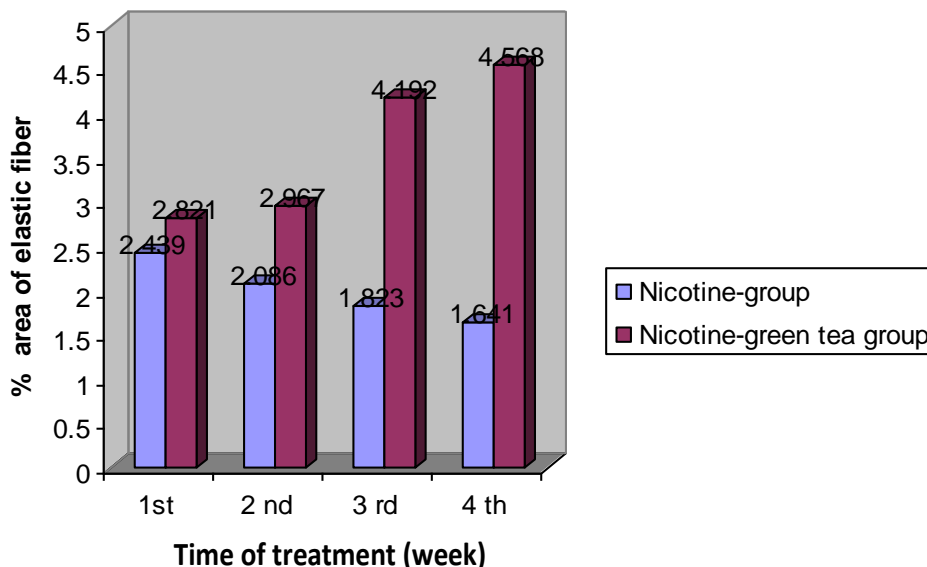


Figure 17. Effect of green tea administration on area of elastic fiber in lung of nicotine intoxicated male albino mice.

Table 2. Effect of nicotine and/ or green tea on the area of nucleus of liver section of Swiss albino mice.

Time of treatment	Experimental group			
	Control	Nicotine	Green tea	Nicotine-green tea
Week 1	51.55 ± 0.68 ^{Ba}	72.51±7.95 ^{Ac}	47.74±3.85 ^{Ba}	54.76 ± 2.84 ^{Bb}
Week 2	48.19± 5.58 ^{Ca}	88.31±4.21 ^{Abc}	46.43±4.50 ^{Ca}	67.25± 2.72 ^{Bba}
Week 3	53.16 ± 4.84 ^{Ba}	108.58±14.11 ^{Aba}	47.32±5.32 ^{Ba}	70.76±7.07 ^{Ba}
Week 4	51.61 ± 5.64 ^{Ba}	129.03±16.37 ^{Aa}	50.89±3.90 ^{Ba}	65.32±4.21 ^{Bba}

(P < 0.05) is significant; (P < 0.01) is highly significant. Numbers of experimental animals were 5 in all groups. Values are mean ± SE. Capitals letter, compared between control treated group, nicotine treated group, nicotine-green tea treated group and green tea treated group; small letter compared within group of each group.

Nicotine intoxicated group obtained insignificant and gradual decrease of elastic fiber throughout all the tested experimental period. In nicotine treated group, the recorded data showed significant decrease in the elastic fiber post first and second weeks of the experimental

compared to the control group (2.439±0.409 vs. 4.486 ±0.680 μm^2 , (P<0.05) but after second weeks of the treatment, the values recorded were insignificant. The two last intervals of the experimental showed highly significant decrease (1.823±0.299 and (1.641±0.455);

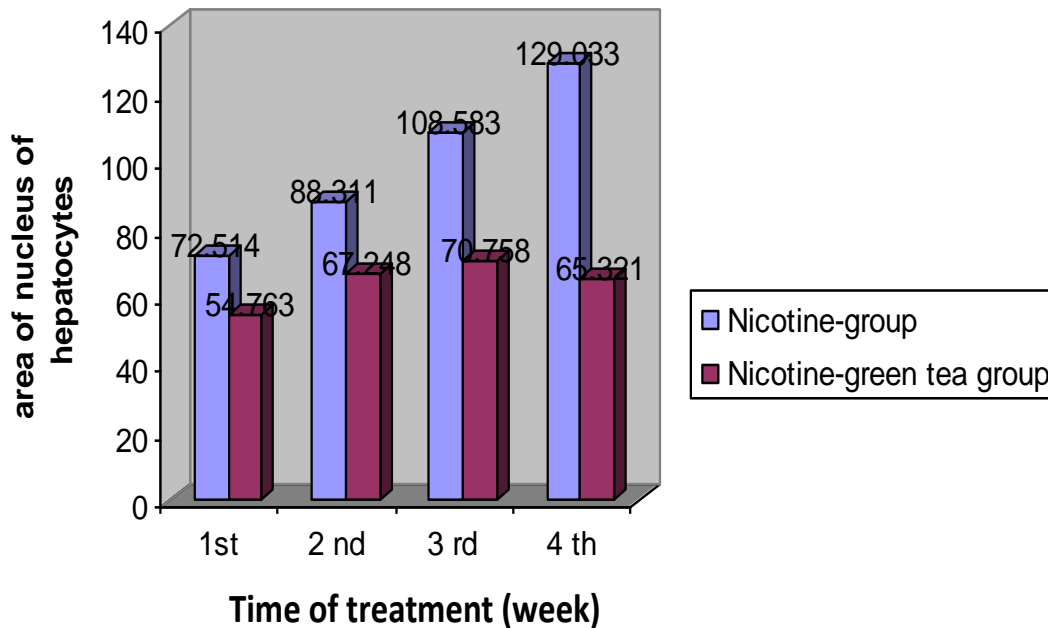


Figure 18. Effect of green tea administration on area of nucleus in hepatocytes of liver of nicotine intoxicated male albino mice.

($P < 0.05$). Administration of green tea to nicotine treated group showed amelioration in the elastic fiber. As compared to nicotine treated group, the data showed insignificant and gradual increase in elastic fiber over the first and second experimental interval attained (2.821 ± 0.948 ; $P < 0.05$; 2.967 ± 2.616), but significantly increased after three weeks of treatment (4.192 ± 1.023). Injection of green tea, till the fourth week showed nearly complete amelioration of elastic fiber area, after the fourth week of the experiments; showed increase in elastic fiber but was not significant respectively. The amelioration effect of green tea was gradual and showed insignificant increase in nicotine treated group with increase in the time of administration of green tea.

Green tea injection to albino mice showed normal distribution of elastic fibers and no significant difference in the area of elastic fiber over all intervals of the experiment were attained compared to the control level (4.596 ± 0.676^2), (4.895 ± 0.969), (4.798 ± 0.654), (4.900 ± 0.817), and ($P < 0.05$) along the four weeks respectively. From the above data, we conclude that green tea affects nicotine and showed amelioration to the nicotine toxicity effect on amount and disruptions of elastic fiber in lung of male albino mice.

Table 2 and Figure 18 represent the morphometric changes of area of nucleus in liver of male Swiss albino mice during daily treatment with nicotine (2.5 mg/kg) and /or green tea (40 mg/kg). In the normal group, all Swiss albino mice had normal distribution in nucleus area of liver and no significant change was presented along all interval of the experiment. In nicotine treated group,

gradual, highly-significant increase of nucleus area in liver as well as increase in time of the experiment was obtained. The values were 72.514 ± 7.945 , 88.311 ± 4.208 , $108.583 \pm 14.114 \mu\text{m}^2$ and $129.033 \pm 16.374 \mu\text{m}^2$ ($P < 0.05$) post first, second, third and fourth weeks of the experimental respectively. As compared to the control level, the data showed significant or highly significant and gradual increase in area of nucleus in liver all over the experimental interval. First week of nicotine treatment showed significant increase (72.514 ± 7.945 vs. $51.553 \pm 0.680 \mu\text{m}^2$; $P < 0.05$) but with increased time of treatment till the fourth weeks, it showed highly significant increase.

On the other hand, daily green tea administration to nicotine treated group obtained ameliorative effect on the area of nucleus in the liver. Compared to nicotine group, the first week and third week values showed significant decreased [54.763 ± 2.841 vs., $72.514 \pm 7.945 \mu\text{m}^2$; ($P < 0.05$); (70.758 ± 7.074 vs., $108.583 \pm 14.114 \mu\text{m}^2$)] but the second week showed highly significant decreased in area of nucleus of the liver (67.248 ± 2.722 vs., $88.311 \pm 4.208 \mu\text{m}^2$). Continuous injection of green tea with nicotine green tea, till the fourth weeks showed nearly complete amelioration of area of nucleus, and the morphometric measurements at such period showed highly significant decreased; (65.321 ± 4.208 , $129.033 \pm 16.374 \mu\text{m}^2$). The amelioration effect of green tea was gradual, and was insignificantly increased in nicotine intoxicated group with increased time of administration of green tea with nicotine. Individual green tea injection to albino mice showed no significant difference in the area of nucleus over all intervals of the

experiment attained compared to the control level.

DISCUSSION

The histological examination of lung tissue of mice treated with nicotine throughout all intervals of the experiment revealed variable degree of alterations. Toxic influences of nicotine can be seen in the structural appearance changes of tissues of treated animals. In this investigation, we study the toxicity of nicotine as well as the possible protective effect of green tea at the tested dose level by daily interaperitoneal injection on some organs of Swiss albino mice.

Our results demonstrate that many alterations in the pulmonary structures can be caused by four weeks of nicotine (2.5 mg/kg/day) injection. In this study, the histological examinations of lung tissue of mice treated with nicotine throughout the experimental intervals revealed variable degrees of alterations. This was evidenced by the thickening of interalveolar septa extensive destruction of wall of the alveoli and formation of enlarged, irregular air space. In addition, the architecture of the lung was not preserved as marked dilated congested blood vessels and inflammatory infiltration were prominent features observed. After four weeks of nicotine injection, the lung is the primary organ that becomes exposed to cigarette smoke and is highly susceptible to free radical generation (El-Sokkary et al., 2007). Lung sections appeared with variable changes and marked injury. Loss of architecture of lung, irregular and enlarged air spaces, inflammatory infiltrations and marked thickening of alveolar septa were dominant in majority of the lung tissue. Sheng et al. (2001) showed that nicotine injury may be proportional to the exposure time and the high severe liver damage can be explained by a higher plasma concentration of nicotine in mice. The alteration in pulmonary structure was improved by previous studies (Valença et al., 2004; Demiralayet al., 2006) which suggest that few septa fragments were thickened, and many enlarged airspaces were detected, in accordance with the pathologist's definition of emphysema as a condition of the lung characterized by abnormal permanent enlargement of the airspaces distal to terminal bronchioles, accompanied by destruction of alveolar septa.

Selim and Ibrahim (2004) and Di Paola et al. (2005) suggested that nicotine caused conspicuous pathological lesions in the pulmonary tissue. Trombino et al. (2004) and Luqman and Rizvi (2006) showed presence of interstitial infiltration of inflammatory cells (Polymorphonuclear leucocytes, macrophages, plasma cells), degenerative changes in the interstitial cells and alveolar epithelial cells. In this study, a destruction of alveolar tissue (septa) and/or alveolar walls and formation of enlarged, irregular air sac may be attributed to chronic

inflammation caused by nicotine administration (Piipari et al. 2000; Park et al., 1998). Many studies showed that lung inflammation is associated with enhanced expression of proinflammatory cytokines which serve as intercellular signals that recruit cells and modulate cell function. Cytokines produced predominantly by activated macrophages and lymphocytes mediate many inflammatory processes (Di Paola et al., 2005). In the present study, the histopathological changes in the liver of nicotine-treated mice suggest additional specific pathogenic pathway may be involved in nicotine hepatotoxicity and liver cell injury may be attributed to iron overload with consequent iron deposition in hepatocytes (El-Zayadi, 2006).

During smoking, nicotine is rapidly absorbed into the circulatory system and metabolized in the liver by cytochrome P450. Additional specific pathogenic pathway may be involved in nicotine hepatotoxicity, as reported by El-Zayadi (2006), Yildiz (2004) and Muthukumaran et al. (2008) that an association between nicotine and liver cell injury may be attributed to iron overload with consequent iron deposition in hepatocytes. In addition, liver cell injury, inflammation and activation of Kupffer cells may be attributed to pro-inflammatory cytokines (El-Zayadi, 2006). The histological damage caused by nicotine in this study by the administration of nicotine may be attributed to depletion in glutathione (GSH) level and glutathione peroxidase activity (Neogy et al., 2008). On the other hand, green tea attenuates histological damage by increasing the level of GSH (Yumei et al., 2006; Helieh and Theresa, 2008). Exposure to nicotine caused significant decrease in hepatic superoxide dismutase (SOD) levels (Muthukumaran et al., 2008; Sheng et al., 2001). Decrease in SOD activities reflects those of histological changes; due to the oxidative stress-induced hepatic damage (Sheng et al., 2001; Polavarapu et al., 1999).

The development of nicotine-induced hepatic injury altered the redox state with a decreased hepatic glutathione and increased the formation of lipid peroxidative products, which were partially normalized by treatment with EGCG, respectively (Zhen et al., 2007). Administration of green tea partly normalized the activity of enzymes and the level of non-enzymatic antioxidants. Augustyniak et al. (2005), Ji et al. (1997) and Sudheer et al. (2007) revealed a significant increase in the expression of cyclooxygenase-2 and NF- κ B in lung and liver of nicotine-treated rats. Other factors involved in this chain reaction are reactive oxygen species (ROS) that contribute to tissue destruction in several inflammatory complications (Helieh and Theresa, 2008). Other investigation showed that, the generation of oxidative and nitrosative species, which exert their effects both directly and indirectly, is an important contributor to inflammatory injury (Demiralayet al., 2006; El-Sokkary et al., 2007; Schwartz et al., 2005).

The degree of beneficial effects of green tea against

toxicity of nicotine depends on the time of treatment. The concentration of green tea constituent on human plasma increased with increased time of treatment but recent evidences *in vitro*, animal and human trial studies indicated the possibility that the consumption of green tea may reduce the risk of lung cancer among smokers (Schwartz et al., 2005). The amelioration effect of green tea on nicotine toxicity may be attributed to anti-inflammatory and antioxidant properties (Varilek et al., 2001; Patra et al., 2008) and the free radicals scavenging properties (Neogy et al., 2008) through decreased lipid peroxidation and suppressed oxidative damage; both caused oxidative damage in nicotine treatment animals (Ogura et al., 2008).

Zhen et al. (2007) concluded that tea catechins were absorbed from the small intestine and the main component of tea catechin, epigallocatechin gallate, was widely distributed in several tissues including the liver and kidney. It has been proved that antioxidant properties of catechins are connected to the inhibition of free radical generation, free radical scavenging abilities, and metal ion chelating properties (Chen et al., 2002). The protective effects of green tea extract against nicotine toxicity are due to combination of several different mechanisms, including modulation of expressions of anti-oxidative systems, direct scavenging of free radicals (Cemeli et al., 2009), reduction of the levels of several markers of oxidative stress; reduce lipid peroxidation and reduce DNA strand breakage induced by cigarette smoke in cultured human bronchial cells (Sriram et al., 2008). The ability of green tea to act as radical scavenger and chelated transitional metals such as iron may be of major significance for the treatment of nicotine-induced pulmonary injury. Knekt et al. (2005) obtained that the lung tissue injury can be caused by nicotine toxicity and protection of tissues against reactive oxygen species caused by green tea.

Morphometrical studies

In this study, the toxicity of nicotine to Swiss albino mice was shown to cause insignificant and gradual decrease of elastic fiber in lung throughout all the tested experimental period. The reduction in elastic fiber which was recorded in lung tissues, were investigated as the macrophages produce proteases exerting a highly proteolytic role in the lung, and some were capable of inhibiting or inactivating or even degrading α 1-protease inhibitor and other antiproteases, largely contributing to the elastolytic process (Valença et al., 2004). Also, nicotine increased the production of matrix metallo-proteinases through the release of fibroblast growth factor and endothelin from endothelial cells.

Other investigation revealed that decrease or degradation of elastic fiber in nicotine treated mice may

be attributed to the effect of neutrophil elastase (NE) secreted by neutrophil. Cigarette smoking acts as a local irritant, causing increased numbers of neutrophils directly promoting neutrophil elastase release from them. One of the proteolytic activities used by neutrophils at the site of inflammation is NE, which has the potential to preferentially disrupt the elastic network (Dona et al., 2003).

On the other hand, administration of green tea to nicotine treated group showed some improvement in the elastic fibers. The amelioration effect of green tea was gradual, and insignificantly increased in nicotine treated group with increase in the time of administration of green tea with nicotine. In addition, the results show that the elastic fiber decreased partially due to green tea administration which may be attributed to the reduced number of neutrophil, macrophage and reduced secretion of neutrophil elastase (Sriram et al., 2008; Di Paola et al., 2005). Sartor et al. (2002) attributed the effect of green tea on elastic fibers in nicotine treated group to the inhibition of metallo-elastase and serine-elastase, which are secreted by macrophages.

Hence, it is widely accepted that antioxidants, either endogenous or from the diet, play a key role in preserving health. Green tea is able to quench radical species generated in situations of oxidative stress, either triggered by pathologies or nicotine; green tea also decrease most of the pathological lesions in lung tissue.

In addition, green tea extract have ameliorated reduction in elastic fiber caused by toxicity of nicotine.

Area of nuclei of hepatocytes

In this study, nicotine intoxicated group obtained gradual, highly-significant increase of nucleus area of hepatocytes in the liver as time of the experiment increased. In nicotine treated mice, the data showed significant and gradual increase in area of nucleus in liver all over the experimental interval attained. On the other hand, administration of green tea to nicotine treated group indicated gradual, insignificant ameliorative effect on the area of nucleus in the liver. Supplementation of green tea with nicotine till the fourth weeks showed nearly complete improvement of the area of nuclei of the hepatocytes.

Morphometrical changes in the nucleus of hepatocytes observed in this study may be attributed to the genotoxicity properties of nicotine (Adluri et al., 2008). There are many evidences that cellular damage occurs with nicotine exposure and is associated with an imbalance in the cellular oxidant-antioxidant system (Sheng et al., 2001). Nicotine oxidative stress occurs when there are excess free radicals and/or low antioxidant defense, and result in chemical alteration of biomolecules causing structural and functional modification (Neogy et al., 2008). Also, the mechanism may involve the decrease of lipid peroxidation (Yuan et

al., 2007). Green tea is composed of at least 10 to 20% polyphenol which are powerful antioxidants, capable of scavenging H_2O_2 and superoxide anion, induced cytotoxicity and mutagenicity. Catechins have also been found to decrease iron-mediated lipid peroxidation and attenuate toxicity to iron-treated hepatocytes as well as to remove iron from iron-loaded hepatocytes (Sheng et al., 2001).

In conclusion, the results of this study indicate the efficiency of green tea on restoring more or less the original appearance of liver tissue. The results of this study demonstrate that treatment of mice with green tea extract had a marked protective effect against nicotine toxicity.

REFERENCES

- Adluri R, Sudheer A, Shanmugavel M, Nagarajan D, Halagowde D, Venugopal P, Menon A (2008). Influence of ferulic acid on nicotine induced lipid peroxidation, DNA damage and inflammation in experimental rats as compared to *N*-acetylcysteine. *Toxicology*, 15: 354-355.
- Augustyniak A, Waszkiewicz E, Skrzydlewska E (2005). Preventive action of green tea from changes in liver antioxidant abilities of different aged rats intoxicated with ethanol. *Nutrition*, 21: 925-932.
- Bancroft JD, Gamble S (2002). *Theory and Practice of Histological Techniques*. Fourth Edition, Queen's Medical Center, Nottingham, Uni. Hospi. NHS Trust.
- Carpagnano GE, Kharitonov SA, Faschino-Brbaro MP, Resta O, Gramiccioni E, Barnes PJ (2003). Increased inflammatory markers in the exhaled breath Condensate of cigarette smokers. *Eur. Respir. J.* 21(4): 589-593.
- Cemeli E, Baumgartner A, Anderson D (2009). Antioxidants and the Comet assay. *Mutat. Res.* 681: 51-67.
- Chan MM, Fong D, Ho CT, Huang I (1997). Inhibition of inducible nitric oxide synthase gene expression and enzyme activity by epigallocatechin gallate, a natural product from green tea. *Biochem. Pharmacol.* 54: 1281.
- Chen L, Yang X, Jiao H, Zhao B (2002). Tea catechins protect against lead induced cytotoxicity, lipid peroxidation, and membrane fluidity in HepG2 cells. *Toxicol. Sci.* 69: 149-156.
- Demiralay R, Gursan N, Erdem H (2006). The effects of erdosteine, *N*-acetylcysteine, and vitamin E on nicotine induced apoptosis of pulmonary cells. *Toxicology*, 219: 197-207.
- Di Paola R, Mazzon E, Muià C, Genovese T, Zaffini MR, Suzuki H, Cuzzocrea S (2005). Green tea polyphenol extract attenuates lung injury in experimental model of carrageenan induced pleurisy in mice. *Resp. Res.* 6: 66-74.
- Dona M, Dell'Aica I, Calabrese F, Benelli R, Monica Morini, MA, Spiridione G (2003). Neutrophil Restraint by Green Tea: *J. Immuno.* 170: 4335-4341.
- EI-Zayadi AR (2006). Heavy smoking and liver. *World J. Gastroenterol.* 12(38): 6098-6101.
- EI-Sokkary GH, Cuzzocrea S, Reiter RJ (2007). Effect of chronic nicotine administration on the rat lung and liver: Beneficial role of melatonin. *Toxicology*, 239: 60-67.
- Hackett NR, Heguy A, Harvey BG, O'Connor TP, Luettich K, Flieder DB, Kaplan R, Crystal RG (2003). Variability of antioxidant related gene expression in the airway epithelium of cigarette smokers. *Am. J. Respir. Cell Mol. Biol.* 29(3): 331-43.
- Hecht SS (2003). Tobacco carcinogens, their biomarkers and tobacco induced cancer. *Nat. Rev. Cancer*, 3: 733-744.
- Helieh S, Theresa SC (2008). Green tea Polyphenols Down regulates cyclooxygenase and Bcl-2 Activity in Acetaminophen induced Hepatotoxicity. Springer Sciences Media, LLC.
- Hellermann GR, Nagy S, Kong X, Lockey RF, Mohaptra SS (2002). Mechanism of cigarette smoke condensate induced acute inflammatory response in human bronchial epithelial cells. *Respir. Res.* 3: 22-30.
- Iba MM, Scholl H, Fung J, (1998). Induction of pulmonary CYP1A1 by nicotine. *Xenobiotica*, 28: 827-843.
- Ji BT, Shu XO, Linet MS, Zheng W, Wacholder S, Gao YT, Ying DM, Jin F (1997). Paternal cigarette smoking and the risk of childhood cancer among offspring of nonsmoking mothers. *J. Natl. Cancer Inst.* 89: 238-244.
- Katiyar SK, Afaq F, Perez A, Mukhtar H (2001). Green tea polyphenol Induced oxidative stress. *Carcinogenesis*, 22: 287.
- Knekt P, Kumpulainen J, Jrvinen R, Rissanem H, Helifvaara M, Reunanen A, Kovacic P, Cooksy A (2005). I minimum metabolite mechanism for nicotine toxicity and addiction: oxidative stress and electron transfer. *Med. Hypoth.* 64: 104-111.
- Leanderson P, Faresjo AO, Tagesson C (1997). Green tea polyphenols inhibit oxidant induced DNA strand breakage in cultured lung cells. *Free Radic. Biol. Med.* 23: 235-42.
- Luqman S, Rizvi SI (2006). Protection of lipid peroxidation and carbonyl formation in proteins by capsaicin in human erythrocytes subjected to oxidative stress. *Phytother. Res.* 20: 303-306.
- Muthukumaran S, Sdheer AR, Menon VP, Nalini N (2008). Protective effect of quercetin on nicotine induced prooxidant and antioxidant imbalance and DNA. *13(5):217-24.*
- Neogy S, Mahapatra S, Mandal SK, Somenath R (2008). Amelioratory effect of *Andrographis paniculata* Nees on liver, kidney, heart, lung and spleen during nicotine induced oxidative stress. *Environ. Toxicol. Pharma.* 25: 321-328.
- Ogura R, Ikeda N, Yuki K, Morita O, Saigo K, Blackstock C, Nishiyama N, Kasamatsu T (2008). Genotoxicity studies on green tea catechin. *Food Chem. Toxicol.* 46: 2190-2200.
- Ozokutat BH, Ozkan KU, Ibrahim CF, Guldur E, Kilinc MS, Inan F (2005). Effects of maternal nicotine exposure during on breast-fed rat pups. *Biol. Neonats.* 88(2): 113-117.
- Park EM, Park YM, Gwak YS (1998). Oxidative damage in tissues of rats exposed to cigarette smoke. *Free Radic. Biol. Med.* 25: 79-86.
- Patra SK, Rizzi F, Silva A, Rugina DO, Bettuzzi S (2008). Molecular targets of (-)-epigallocatechin-3-gallate (EGCG): specificity and interaction with membrane lipid rafts. *J. Physiol. Pharmacol. Rev.* 59(9): 217-235.
- Piipari R, Savela K, Nurminen T, Hukkanen J, Raunio H, Hakkola J, Mantyla T, Beaune P, Edwards RJ (2000). Expression of CYP1A1, CYP1B1 and CYP3A, and polycyclic aromatic hydrocarbon DNA adduct formation in bronchoalveolar macrophages of smokers and non-smokers. *Int. J. Cancer.* 86: 610-616.
- Piipari R, Savela K, Nurminen T, Hukkanen J, Raunio H, Hakkola J, Mantyla T, Beaune P, Edwards RJ, Boobis AR, Anttila S (2000). Expression of CYP1A1, CYP1B1 and CYP3A, and polycyclic aromatic hydrocarbon-DNA adduct formation in bronchoalveolar macrophages of smokers and non smokers. *Int. J. Cancer,* 86: 610-616.
- Safe S, Wargovich MJ, Lamartiniere CA, Mukhtar H (1999). Symposium on mechanism of action of naturally occurring anticarcinogens. *Toxicol. Sci.* 52: 1-8.
- Sartor L, Pezzato E, Garbisa S (2002). Epigallocatechin-3-gallate inhibits leukocyte elastase: phytofactor for hindering inflammation, emphysema and invasion. *J. Leukocyte Biol.* 71: 73-85.
- Schwartz JL, Baker V, Larios E, Chung FL (2005). Molecular and cellular effects of green tea on oral cells of smokers: a pilot study. *Mol. Nutr. Food Res.* 49: 43-51.
- Selim M, Ibrahim IA (2004). The efficacy of melatonin in ameliorating the deleterious effects caused by nicotine in the pulmonary tissue of rats. *Egypt. J. Med. Lab. Sci.* 13 (2): 324-433.
- Sheng HB, Tsan Yuen IS, Leung So HL, Cho CH (2001). Hepatotoxicity of Prenatal and Postnatal Exposure to Nicotine in Rat Pups. *Exp. Biol. Med.* 226(10): 934-939.
- Shivij SB, Camilo A, Moncada AB, Clarkson Jr, Salim M (2006). Effect of nicotine on lung S-Adenosylmethionine and development of Pneumocystis Pneumonia. *J. Biol. Chem.* 280(15): 15219-15228.
- Sriram N, Kalayarasan S, Sudhandiran G (2008). Enhancement of antioxidant defense system by epigallocatechin-3-gallate during bleomycin induced experimental pulmonary fibrosis. *Biol. Pharm.*

- Bull. 31(7): 1306-1311.
- Sudheer AR, Muthukumar S, Kalpana C, Menon VB (2007). Protective effect of ferulic acid on nicotine induced DNA damage and cellular changes in cultured rat peripheral blood lymphocytes: A comparison with *N*-acetylcysteine. *Toxicol. Vitro.* 21: 576–585.
- Trombino S, Cesario A, Margaritora S, Granone P, Motta G, Falugi C, Russo P (2004). Alpha7-nicotinic acetylcholine receptors affect growth regulation of human mesothelioma cells: role of mitogen-activated protein kinase pathway. *Cancer Res.* 64:135- 38.
- Valença SS, Da Hora K, Castro P, Moraes VG, Carvalho L, Porto LC. (2004). Emphysema and metalloelastase expression in mouse lung induced by cigarette smoke. *Toxicol. Pathol.* 32(3): 51-56.
- Varilek GW, Yang F, Lee EY, DeVilliers WJ, Zhong J, Oz HS, Westberry KF, McClain CJ (2001). Green tea polyphenol extract attenuates inflammation in interleukin-2-deficient mice, a model of autoimmunity. *J. Nutr.* 131(7): 20-34.
- Wu YP, Kita K, Suzuki N (2002). Involvement of human heat shock protein in nicotine induced apoptosis. *Int. J. Cancer.* 90(100): 37-42.
- Yildiz D (2004). Nicotine, its metabolism and an overview of its biological effects. *Toxicol.* 43: 619–632.
- Yokozawa T, Rhyu DY, Cho EJ (2004). Epigallocatechin-3-O-gallate ameliorates the damages related to peroxynitrite production by mechanism distinct from those of other free radical inhibitors. *J. Pharma. Pharmacol.* 56: 231-239.
- Yuan JM, Gao YT, Yang CS, Yu MC (2007). Urinary biomarkers of tea polyphenols and risk of colorectal cancer in the Shanghai Cohort study. *Int. J. Cancer.* 120: 1344–1350.
- Yumei F, Zhou Y, Zheng S, Chen A (2006). The antifibrogenic effect of (-)- epigallocatechin gallate results from the induction of de novo synthesis of glutathione in passaged rat hepatic stellate cells. *Lab. Invest.* 86: 697–709.
- Zhen M, Wang O, Huang X, Cao L, Chen X, Sun K, Liu Y, Li W, Zhang L (2007). Green tea polyphenol epigallocatechin-3-gallate inhibits oxidative damage and preventive effects on carbon tetrachloride induced hepatic fibrosis. *J. Nutr. Bioch.* 18: 795–805.
- Zhong Z, Froh M, Connor HD, Li X, Conzelmann LO, Ronald PM, John JL, Ronald GT (2002). Prevention of hepatic ischemia reperfusion injury by green tea extract. *Am. J. Physiol. Gastro.* 283: G957–G964.