

Full Length Research Paper

Effect of cadmium chloride and ascorbic acid exposure on the vital organs of freshwater Cyprinid, *Labeo rohita*

Abdul Latif¹, Muhammad Ali², Rahila Kaoser³, Rehana Iqbal¹, Kashif Umer¹, Muhammad Latif¹, Shazia Qadir¹ and Furhan Iqbal^{1*}

¹Institute of Pure and Applied Biology, Zoology Division. Bahauddin Zakariya University Multan 60800, Pakistan.

²Institute of Biotechnology. Bahauddin Zakariya University Multan 60800, Pakistan.

³Department of Chemistry, Bahauddin Zakariya University Multan 60800, Pakistan.

Accepted 28 March, 2012

The present study was carried out to evaluate the impact of sub lethal concentrations of heavy metal, cadmium chloride ($\text{CdCl}_2 \cdot \text{H}_2\text{O}$), ascorbic acid (vitamin C) and their combination on *Labeo rohita*. The effect was investigated on the basis of histopathological examinations of control and experimental groups exposed to heavy metal. The acute semi statistical toxicity test for *L. rohita* revealed 96 h LC_{50} value 22.92 mg L^{-1} for cadmium chloride ($\text{CdCl}_2 \cdot \text{H}_2\text{O}$). 215 fingerlings of *L. rohita* were exposed to three different experimental conditions for 96 h: 11.46 mg L^{-1} $\text{CdCl}_2 \cdot \text{H}_2\text{O}$, or 450 mg Kg^{-1} ascorbic acid or combination of both these doses. No alterations were observed in gill sections upon comparison between treated and untreated groups. Congestion in sinusoids, fatty change, an increase in Kupffer cells and intrahepatic lymphocytes was observed in $\text{CdCl}_2 \cdot \text{H}_2\text{O}$ treated group. In kidney sections of heavy metal treated group, degeneration of the glomerular tissue, occlusion in tubular lumen and necrosis were observed. Similar changes but in less severe form, as described above, were observed in the fish exposed to combination of $\text{CdCl}_2 \cdot \text{H}_2\text{O}$ and ascorbic indicating that ascorbic acid do detoxify the effect of heavy metal to some extent. Our results indicate that cadmium chloride ($\text{CdCl}_2 \cdot \text{H}_2\text{O}$), if present in fresh water bodies, may act as strong toxic agent for *L. rohita*.

Key words: *Labeo rohita*, cadmium chloride ($\text{CdCl}_2 \cdot \text{H}_2\text{O}$), ascorbic acid, histopathology.

INTRODUCTION

Heavy metals are beneficial for living organisms under normal conditions but they tend to be toxic when their concentrations cross the established safe limits (Farombi et al., 2007; Patel and Bahadur, 2011). Presently, heavy metal environmental pollution becomes an alarming signal and global issue for man, as it may cause deleterious and adverse effects on the existing natural ecological balance of the recipient environment (Vutukuru, 2005). The diverse causative factors and the sources of contamination of the essential and non-essential heavy metals, such as zinc, copper, cadmium, in aquatic environment are numerous that is, increased urbanization, expansion of industrial activity, industrial wasteful effluents, exploration of natural resources, muni-

cipal wastes, and frequent use of automobiles (Ashraj, 2005; Vosyliene and Jankaite, 2006; Vinodhini and Narayanan, 2008; Saxsena and Garg, 2011). Besides these, the most common source of heavy metal toxicity is from dental amalgam fillings and other metal dental appliances (Farombi et al., 2007). It is informed that these heavy metals when present in high enough concentrations interfere in the metabolic disciplines, inducing thereby the chronic stress conditions that have negative effect on the lives of the living organisms; because they decline the life sustaining physico-chemical properties of the environment (Patel and Bahadur, 2011; Baki et al., 2011). Biochemical effects of essential and non-essential heavy metals like cadmium, mercury, and lead on fish and other aquatic animals have recently been the topic of interest, because freshwater bodies in developing countries like India and Pakistan are tending to be highly contaminated by the direct or indirect discharge of untreated waste, dumping of industrial effluent and run-

*Corresponding author. E-mail: furhan.iqbal@bzu.edu.pk. Tel: 0092-61-9210053. Fax: 0092-61-9210098.

off from agricultural fields (Uysal and Emre, 2011; Patel and Bahadur, 2011; Saxsena and Garg, 2011).

In fish, gills, liver, and kidneys are pivotal organs primarily involved in respiration, osmoregulation, detoxification, biotransformation and excretion respectively (Iqbal et al., 2004; Waqar, 2006; Vesey, 2010). The kinds of histopathological abnormalities observed most commonly in fish are hepatic and renal lesions upon exposure to heavy metals (Iqbal et al., 2005). These abnormalities are important for evaluating the biological effects of metal contamination because numerous field and laboratory studies have established a putative cause/effect relationship between the prevalence of hepatic and renal lesions and exposure of fish to heavy metal toxicity (Wang et al., 2004; Uysal and Emre, 2011; Patel and Bahadur, 2011; Gernhofer et al., 2001).

Cadmium toxicity is pronounced because its concentrations are continuously increasing in the environment. Its biological role in living organisms is unknown although it is the major contaminant of aquatic ecosystems, causing thereby detrimental effects on aquatic organisms (Jiraungkoorskul et al., 2006). Other sources of aquatic contamination with cadmium are diverse, for example, the use of cadmium as a coloring agent, acting as stabilizer, in mining and smoldering units, metallurgical operation, electroplating industries manufacturing vinyl plastics, electrical contacts, metallic, plastic pipes, paper, ceramic industries, pigments and in alloy mixtures (Gupta et al., 2003; Drastichova et al., 2004; Patro, 2006).

Ascorbic acid (vitamin C) is an indispensable co-nutrient in aqua-feeds and an essential nutrient for a number of aquatic animals (Patro, 2006). It is strong reducing agent in various tissues and it is required to balance the cellular and biochemical, physiological processes, including growth, immunity, and reproduction of different animals including fish. It is also informed that vitamin C may act as anti carcinogenic and anti mutagenic. It has been reported that high levels of ascorbic acid are efficient in reducing toxicity, preventing disease and enhancing fish tolerance to environmental stress (Wang et al., 2004).

Rauf et al. (2011) reported in Pakistan that, the level of cadmium in various freshwater bodies such as in River Ravi is in range of 2.46 to 8.52 mg/L which is alarming and will affect the aquatic life. Little information is available regarding the effect of cadmium on the histology of vital organs in *Labeo rohita*, the commercially most important carp species in Pakistan. Present study was designed to investigate the detrimental effect of CdCl₂ on the vital organs, gill, liver and kidneys of *L. rohita* and to determine whether ascorbic acid plays a role to balance or reduce the damage done by the heavy metal.

MATERIALS AND METHODS

Animal collection

215 juveniles of freshwater Cyprinid fish, *L. rohita*, of both sex

(body length 7.265 + 1.521 cm and body weight 9.571 + 1.536 g) were obtained from the Faheem fish farm, Mattital Road, Multan and were transported to Fisheries Laboratory, Institute of Pure and Applied Biology at Bahauddin Zakariya University, Multan, (Punjab), Pakistan and acclimatized for 30 days to laboratory conditions. All the experimental procedure and fish handling protocols were approved by Ethical Committee of Zoology Department.

The physicochemical characteristics of water were measured daily, according to the experimental procedures described in Standard Methods for the Examination of Water and Wastewater (APHA, 1998). A 16:8 h light-dark cycle was maintained throughout the experiment. Fish was fed twice a day with 30% protein containing commercial fish food. The quantity of food was 3.5% of the initial body weight per day.

LC₅₀ determination

For determination of 96 h LC₅₀ values, each group of 22 juveniles of *L. rohita* was exposed to one of the 11 concentrations; 1.5, 2.0, 2.5, 3.0, 4.5, 6.0, 8.5, 10.5, 15.0, 20.5 and 25.5 mg/L of cadmium chloride [Cd Cl₂.H₂O]. Fish mortality was observed after 12, 24, 36, 48, 60, 72, 84, and 96 h. LC₅₀ values were calculated following Iqbal et al. (2005).

Experimental design

Fish were exposed to sub lethal concentration, 11.46 mg L⁻¹, of cadmium chloride (CdCl₂.H₂O). Groups, each containing 32 *L. rohita* were exposed to one of the following four treatments: Group 1, heavy metal free distilled water; group 2, 11.46 mg L⁻¹ CdCl₂.H₂O; group 3, 450 mg kg⁻¹ body weight of ascorbic acid and group 4, combination of 11.46 mg L⁻¹ CdCl₂.H₂O and 450 mg kg⁻¹ body weight of ascorbic acid. All experiments were carried out in semi-static systems with water renewal after every 12 h following Little and Brewer (2001).

Histological study of the vital organs

At the end of experiments, gill, liver and kidney were surgically removed from each treated and untreated fish, sliced and fixed in fixative solution (containing ethanol, formaldehyde and glacial acetic acid: 1:3:7) followed by dehydration in ethanol, clearing in Cedar wood oil and embedding in Paraffin (Iqbal et al., 2005). Sections of 2 μm were then cut at a microtome and stained with hematoxylin-eosin. Light microscopy was performed and stained section was photographed under photomicroscope.

RESULTS

LC₅₀ Value of CdCl₂.H₂O

The 96 h LC₅₀ value for experimental group of *L. rohita* treated with cadmium chloride was 22.92 mg/L. In a separate experimental series (data not shown), groups of 22 juveniles of *L. rohita* were exposed to one of the 11 concentrations of ascorbic acid 50, 100, 150, 200, 250, 300, 350, 400, 450, 500 and 550 mg kg⁻¹ body weight along with sub lethal (11.46 mg/L) concentration of cadmium chloride to investigate whether ascorbic acid minimizes the detrimental effect of heavy metal or not. It was observed that 450 mg kg⁻¹ body weight of ascorbic

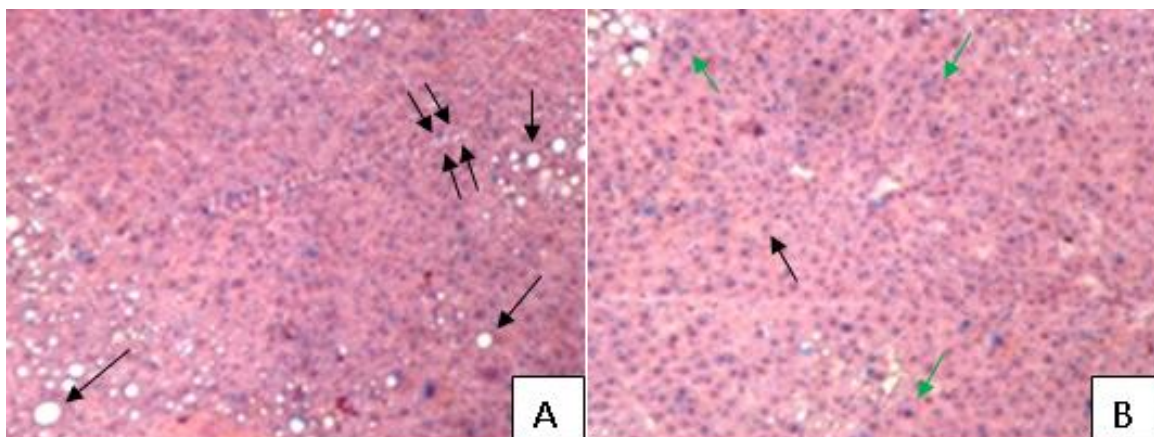


Figure 1. Sections (2 μm thick) of liver of the control fresh water Cyprinid, *L. rohita*. (A) Central vein (arrow) and sinusoids (double arrow). (B) Hepatocytes (black arrow) and Kupffer cells (green arrow).

acid may reduce the detrimental effect of cadmium chloride.

Histological changes in gill structure

Light microscopic examination of the photomicrograph of the vertical section of the gills revealed no significant alteration in the arrangement of primary and secondary lamellar processes of control and experimentally treated groups. The primary gill lamellae in the microscopic sections showed the normal anatomy with quite flat leaf like structures having a central rod like supporting axis and a row of secondary gill lamellae on each side of it. The secondary lamellae (SL) were equally spaced along the columnar structures with intact cellular layer attached at their bases with the primary lamellae and free at their distal ends. The normal secondary lamellar epithelium was simple, consisting of a thin single sheet of epithelial cells, blood vessels and a row of pillar cells. The region between the two adjacent secondary gill lamellae is known as inter-lamellar region and it did not exhibit any abnormality in the normal structure in control and treated groups of fish.

Histological changes in liver

Liver is composed of roundish polygonal hepatocytes, within the network of minute canalicules, containing centrally placed spherical large prominent nucleus. In liver histology of control group (Figure 5a), the bile duct, blood capillaries, and sinusoids were randomly distributed. The sinusoids were filled with erythrocytes. The hepatocytes around the central vessels appear to be lightly arranged in a rosette like pattern with approximately 10 to 12 cells in each group (Figure 1).

Hepatic tissues of the fish exposed to cadmium chloride showed high degree of congestion of central

vein, resulting to hemorrhage and fatty change was prominent along with darkly stained hepatocytes. An increase of Kupffer cells and intrahepatic lymphocytes was also observed (Figure 2).

No change in hepatocytes, their nuclei and Kupffer cells was observed when liver histology was compared between ascorbic acid treated group and untreated (control) fish (Figure 3).

In group 4, where fish were treated with combination of cadmium chloride and ascorbic acid, similar abnormalities were observed in liver histology as those observed in the cadmium treated group but these changes were less severe indicating that ascorbic acid does detoxify the effect of heavy metal to some extent (Figure 4).

Histological changes in kidneys

The most prominent alterations investigated in the kidneys of *L. rohita* were the degeneration of the glomerular tissue, occlusion tubular lumen and necrosis in the series of cadmium chloride treated groups (Figure 5b), but the sections of the kidneys of ascorbic acid treated groups showed normal histology (Figure 5c). It was interesting in our findings that less severe impact of cadmium chloride was observed when applied in combination with ascorbic acid to treated groups (Figure 5d).

DISCUSSION

Cadmium, a non-essential, non-biodegradable heavy metal has been included in the "Black list", because cadmium exerts most of their toxicity by destroying important proteins by stealing off sulphur from them, many of which are enzymes, hormones, or cell receptors (Mason, 1996) while ascorbic acid is best known for its antioxidant activity in its mode of action, by protecting the

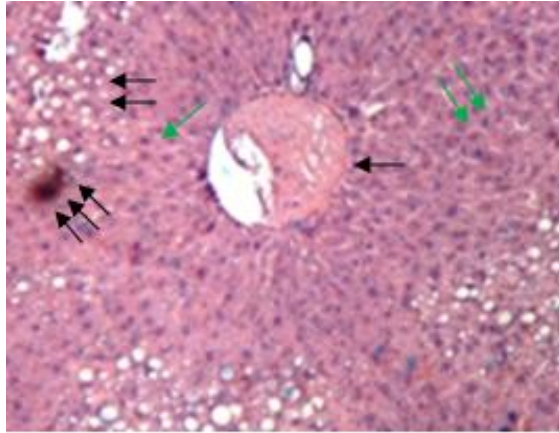


Figure 2. Sections (2 μm thick) of liver of the cadmium chloride treated fresh water Cyprinid, *L. rohita*. Congestion of central vein, resulting in hemorrhage (single arrow) and fatty change (double arrow) and dark stained hepatocytes (triple arrow). An increase of Kupffer cells (green arrow). An increase in intrahepatic lymphocytes (double green arrow).

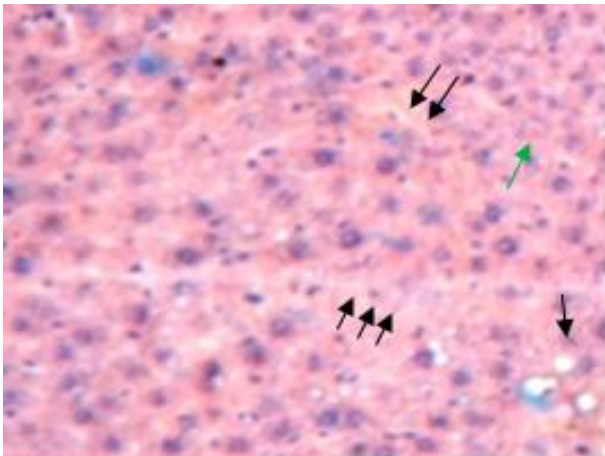


Figure 3. Sections (2 μm thick) of liver of the ascorbic acid treated fresh water Cyprinid, *L. rohita*. Central vein (single arrow) and sinusoids (double arrow). Hepatocytes (triple arrow) and Kupffer cells (green arrow).

structure and membrane fluidity of biological system. The aim of the present study was to determine if ascorbic acid supplementation nullifies the damage caused by cadmium chloride to the histology of gill, liver and kidney of *L. rohita*.

In fish, the gills remain in direct contact with the immediate external environment, thus they are useful biomarkers for any change in the quality of water, as they are sensitive to any detrimental changes (Mazon et al., 2002; Fernandes and Mazon, 2003; Patel and Bahadur, 2011). No prominent alteration in gill histology was observed in present study. Our results are contradictory to Ribeiro et al. (2000) and Martinez et al. (2004) who

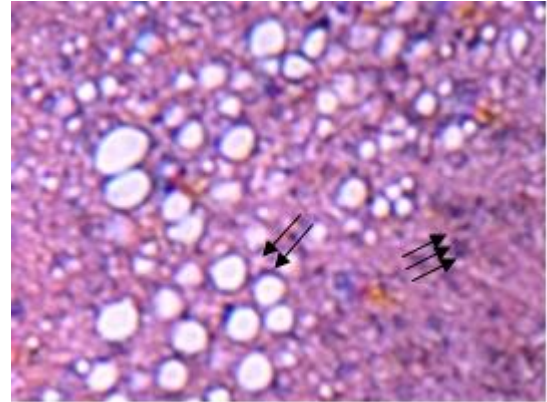


Figure 4. Sections (2 μm thick) of liver of the cadmium chloride and ascorbic acid treated fresh water Cyprinid, *L. rohita*. Fatty change (double arrow) and dark stained hepatocytes (triple arrow).

had reported visible changes in gill structure upon heavy metal exposure in fish.

Our study reveals that cadmium chloride had detrimental effects on the liver histopathology of *L. rohita*. Cadmium can be taken up by the candidate fish through at least four routes; the food ingestion, simple diffusion via gills pore, through drinking process and by intestinal or skin absorption (Sindayigaya et al., 1994; Fanta et al., 2003). The hepatocytic abnormalities were observed by a number of researchers following exposure of various heavy metals including cadmium; these heavy metals show affinity to interact with legends in proteins particularly; enzymes and these may retard their biochemical and physiological activities in living organisms, thus causing adverse effects in them (Filho et al., 2001; Fanta et al., 2003; Samanta et al., 2005; Patel and Bahadur, 2011). We have observed sinusoidal dilatation in fish exposed to cadmium chloride. Nobuyoshi et al. (2005) has reported that the liver being the detoxification center of the body receives cadmium quickly and frequently hence it suffers from increased arterial flow leading to sinusoidal dilatation. In our study, an increase of intrahepatic lymphocytes (Kupffer cells) and fatty change were observed in cadmium treated fish, indicating that the liver is severely affected by the toxic chemical leading to the loss of typical metabolism. Our results are in agreement with Wang et al. (2004) and Palacios et al. (2000) who had observed that the lymphocytes were directly or indirectly involved in the immunopathogenesis of chronic or acute liver diseases.

The fish kidneys are one of the first and foremost organs to be affected by the detrimental effects of the metals toxicity in water (Thophon et al., 2003). In the present study, degeneration of the glomerular tissue, parenchymatous cells, occlusion tubular lumen and necrosis were observed which are the most probable changes in the fish kidneys, caused by water borne metal contamination. These results are in agreement with

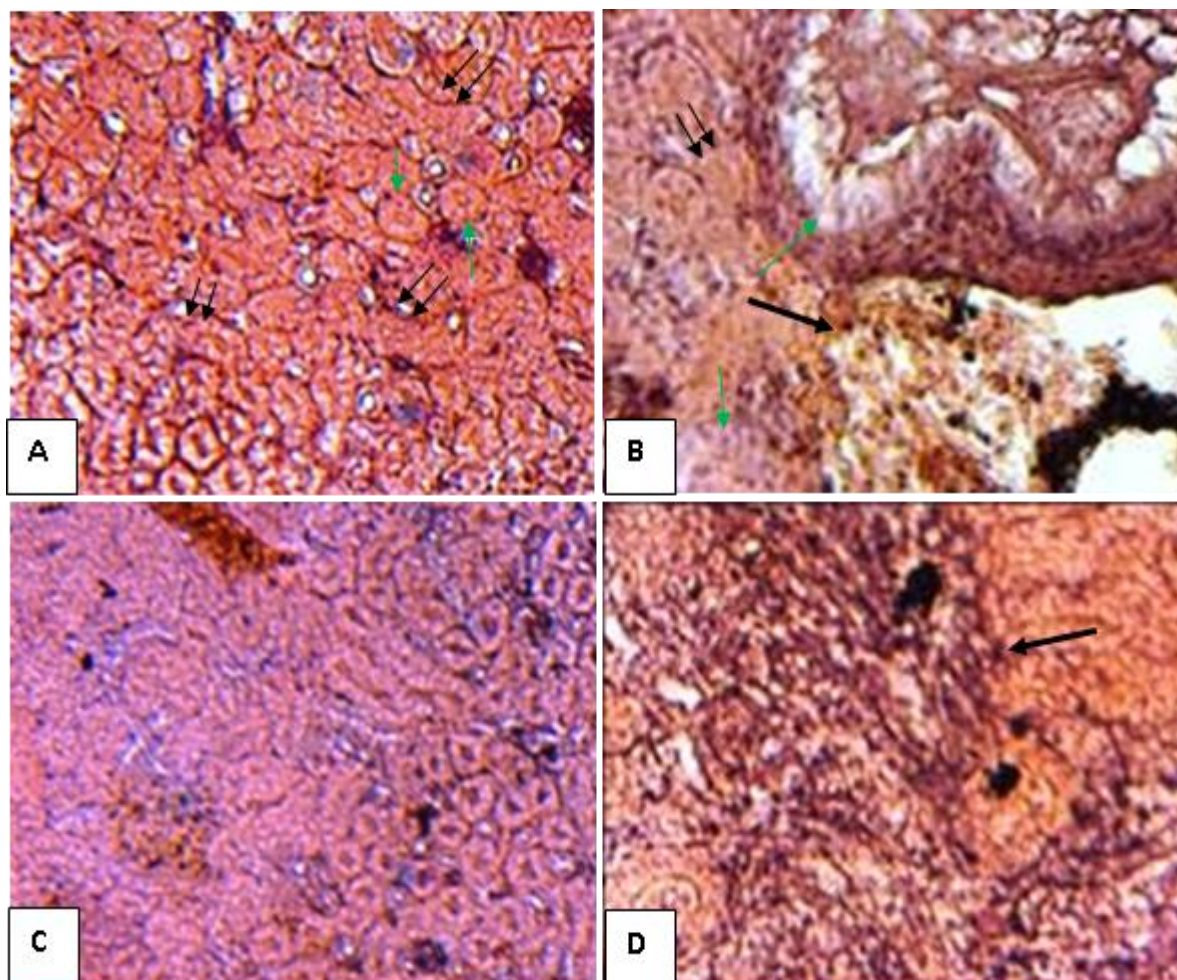


Figure 5. Sections (2 μ m thick) through kidney of *L. rohita*. A, Control group: normal kidney histology. Normal glomerulus (green arrow) and normal proximal tubule (double arrow). B, Kidney section of fish exposed to $\text{CdCl}_2 \cdot \text{H}_2\text{O}$; arrow showing degeneration of the glomerular tissue (black arrow), necrosis and apoptotic cells (double arrow) and occlusion tubular lumen (green arrow). C, Kidney section of fish exposed to ascorbic acid, showing normal kidney histology. D, Kidney section exposed to both $\text{CdCl}_2 \cdot \text{H}_2\text{O}$ and ascorbic acid, arrow showing the glomerular degeneration and necrosis. All photographs are taken X400 of original.

findings of Reimschuessel (2001), Veiga et al. (2002), Pacheco and Santos (2002) and Thophon et al. (2003). The induction of tubular degeneration, coupled with the presence of necrosis in the kidney in our study indicates that the kidneys had suffered detrimental damage induced by the exposure of cadmium. The development of new nephrons in fish continues throughout life (Reimschuessel, 2001). During the process of recovery of damaged kidney in fish, an increase in the frequency of new nephrons and regeneration of tubules has been reported previously (Hinton and Lauren, 1990; Cormier et al., 1995; Reimschuessel, 2001). In our study, new nephrons were observed relatively less. It might be suggested that the short period of metal exposure had not been sufficient to start the process of regeneration, as this process of regeneration of nephrons normally takes a period ranging from two to four weeks after the exposure

to the pollutants (Reimschuessel, 2001) and could be completed even in two months (Gernhofer et al., 2001).

Conclusion

Our results conclude that histopathology is a powerful biomarker for evaluating the quality of the environment. We had observed that cadmium chloride may act as strong toxicant for the commercially most important fish in Pakistan, *L. rohita*, as it severely affects the histology of liver and kidney, and ascorbic acid supplementation do detoxify the effect of heavy metal to some extent.

REFERENCES

APHA, (1998). bb Standard methods for examination of water and

- wastes. 12th ed. Washington, DC: Join Editorial board. p. 18-21
- Ashraj W (2005). Accumulation of heavy metals in kidney and heart tissues of *Epinephelus microdon* fish from the Arabian Gulf. Environ. Monit. Assess. 101(1-3): 311-316.
- Baki AS, Dkhil MA, Al-Quraishy S (2011). Bioaccumulation of some heavy metals in tilapia fish relevant to their concentration in water and sediment of Wadi Hanifah, Saudi Arabia. Afr. J. Biotechnol. 10(13): 2541-2547.
- Cormier SM, Neihsel TW, Wersing P, Racine RN, Reimschuessel R (1995). New nephron development in fish from polluted waters: a possible biomarker. Ecotoxicology, 4: 157-168.
- Drastichova J, Svobodova Z, Luskova V, Machova J (2004). Effect of cadmium on hematological indices of common carp (*Cyprinus carpio*). Bull. Environ. Contamin. Toxicol. 72(4): 725-735.
- Fanta E, Rios FS, Romao S, Vianna ACC, Freiburger S (2003). Histopathology of the fish *Corydoras paleatus* contaminated with sub lethal levels of organophosphorus in water and food. Ecotoxicol. Environ. Saf. 54: 119-130.
- Farombi EO, Adelowo OA, Ajimoko YR (2007). Biomarkers of oxidative stress and heavy metal levels as indicators of environmental pollution in African Cat fish (*Clarias gariepinus*) from Nigeria Ogun River. Int. J. Environ. Res. Pub. Health, 4(2): 158-165.
- Fernandes MN, Mazon AF (2003). Environmental Pollution and Fish Gill Morphology. Science Publishers, Enfield, USA.
- Filho D, Torres MA, Tribess TB, Pedrosa RC, Soares CHL (2001). Influence of season and pollution on the antioxidant defenses of the cichlid fish Acara (*Geophagus brasiliensis*). Brazil. J. Med. Biol. Res. 34: 719-726.
- Gernhofer M, Pawet M, Schramm M, Muller E, Triebkorn R (2001). Ultrastructural biomarkers as tool to characterize the health status of fish in contaminated streams. J. Aquat. Ecosyst. Stress Rec. 8: 241-260.
- Gupta DK, Rai UN, Singh A, Inouhe M (2003). Cadmium accumulation and toxicity in *Cicer arietinum* L. Poll. Res. 22: 457-463.
- Hinton DE, Lauren DJ (1990). Liver structural alterations accompanying chronic toxicity in fishes: potential biomarkers of exposure. Boca Raton, Lewis Publishers, USA. p. 112-117
- Iqbal F, Qureshi IZ, Ali M (2005). Histopathological changes in liver of farmed Cyprinid fish, *Cyprinus carpio*, following nitrate exposure. Pak. J. Zool. 37(4): 297-300.
- Iqbal F, Qureshi IZ, Ali M (2004). Histopathological changes in kidney of common carp, *Cyprinus carpio*, following nitrate exposure. J. Res. Sci. B. Z. Univ. Multan., 15(4): 411-418.
- Jiraungkoorskul W, Sahaphong S, Kangwanransan N, Kim M (2006). Histopathological Study: The Effect of Ascorbic Acid on Cadmium Exposure in Fish (*Puntius altus*). J. Fish. Aquat. Sci. 1(2): 191-199.
- Little EE, Brewer SK (2001). Target Organ Toxicity in Marine and Freshwater Teleosts New Perspectives: Toxicology and the Environment. Taylor, Francis, London. p. 64-69
- Martinez CBR, Nagae MY, Zaia CTBV, Zaia DAM (2004). Morphological and physiological acute effect of lead in the neotropical fish *Prochilodus lineatus*. Brazil. J. Biol. 64(4): 797-807.
- Mason CF (1996). Biology of freshwater pollution. Longman, U.K. p. 184-187
- Mazon AF, Pinheiro GHD, Fernandes MN (2002). Hematological and physiological changes induced by short-term exposure to copper in the freshwater fish, *Prochilodus scrofa*. Brazil. J. Biol. 62(4A): 621-631.
- Nobuyoshi O, Hisaya N, Kazuo I, Saori N, Yoshinoro I, Makoto O, Isao O (2005). Telangiectatic focal nodular hyperplasia of the liver in the perinatal period: Case report. Pediatr. Dev. Pathol. 8: 581-586.
- Ribeiro, OCA., Pelletier E, Pfeiffer WC, Rouleau C (2000). Comparative uptake, bioaccumulation, and gill damages of inorganic mercury in tropical and nordic freshwater fish. Environ. Res. 83: 286-292.
- Pacheco M, Santos MA (2002). Biotransformation, genotoxic and histopathological effects of environmental contaminants in European eel (*Anguilla anguilla* L.). Ecotoxicol. Environ. Saf. 53: 331-347.
- Palacios PS, Biagianti-Risbourg S, Vernet G (2000). Biochemical and (ultra)structural hepatic perturbations of *Brachyodanio rerio* (Teleostei, Cyprinidae) exposed to two sublethal concentrations of copper sulphate. Aqua. Toxicol. 50: 109-124.
- Passow H, Rothstein A, Clarkson TW (1961). The general pharmacology of the heavy metals. Pharmacol. Rev. 13: 185-224.
- Patel JM, Bahadur A (2011). Histopathological Manifestations of Sub Lethal toxicity of Copper Ions in *Catla catla*. Am. Eur. J. Toxicol. Sci. 3(1): 01-05.
- Patro L (2006). Toxicological effects of cadmium chloride on Acetyl cholinesterase activity of freshwater fish, *Oreochromis mossambicus* Peters. Asia. J. Exp. Sci. 20(1): 171-180.
- Rauf A, Javed M, Ubaidullah M, Abdullah S (2011). Assessment of Heavy Metals in Sediments of the River Ravi, Pakistan. Int. J. Agric. Biol. 2: 197-200.
- Reimschuessel R (2001). A fish model of renal regeneration and development. Ilar. J. 42: 285-291.
- Samanta S, Mitra K, Chandra K, Saha K, Bandopadhyaya S, Ghosh A (2005). Heavy metals in water of the Rivers Hoogley and Haldi and their impact on fish. J. Environ. Biol. 26(3): 517-523.
- Saxena R, Garg P (2011). Vitamin E provides protection against *In vitro* oxidative stress due to pesticide (Chlorphrifos and Endosulfan) in goat RBC. GERF Bull. Biosci. Article, press.
- Sindayigaya E, Van Cauwenbergh R, Robberecht H, Deelstra H (1994). Copper, zinc, manganese, iron, lead, cadmium, mercury and arsenic in fish from Lake Tanganyika, Burundi. Sci. Total Environ. 144: 103-15.
- Thophon S, Kruatrachue M, Upathan ES, Pokethitiyook P, Sahaphong S, Jarikhuan S (2003). Histopathological alterations of white seabass, *Lates calcarifer* in acute and subchronic cadmium exposure. Environ. Pollut. 121: 307-320.
- Uysal K, Emre Y (2011). Bioaccumulation of copper, zinc, manganese, iron and magnesium in some economically important fish from the western shores of Antalya. Life Sci. Biotechnol. 1: 95-102.
- Veiga ML, Rodrigues EL, Pacheco FJ, Ranzani-Paiva MJT (2002). Histopathologic changes in the kidney tissue of *Prochilodus lineatus*, 1836 (Characiformes, Prochilodontidae) induced by sublethal concentration of Trichlorfon exposure. Brazil. Arch. Biol. Technol. 45: 171-175.
- Vesey DA (2010). Transport pathways for cadmium in the intestine and kidney proximal tubule: Focus on the interaction with essential metals. Toxicol. Lett. 198(1): 13-19.
- Vinodhini R, Muthuswamy N (2008). Effect of heavy metals induced toxicity on metabolic biomarkers in common carp, *Cyprinus carpio*. Maejo Int. J. Sci. Technol. 2: 192-200.
- Vosyliene MZ, Jankaite A (2006). Effect of heavy metal model mixture on rainbow trout biological parameters. Ecol. 4: 12-17.
- Vutukuru SS (2005). Acute effects of Hexavalent chromium on survival, oxygen consumption, hematological parameters and some biochemical profiles of the Indian Major carp, *L. rohita*. Int. J. Environ. Res. Public Health, 2 (3): 456- 462.
- Wang J, Holmes TH, Cheung R, Greenberg HB, He XS (2004). Expression of chemokine receptors on intrahepatic and peripheral lymphocytes in chronic hepatitis C infections: its relationship to liver inflammation. Environ. Int. 5: 605-609.
- Waqar A (2006). Levels of selected heavy metals in Tuna fish. Arab. J. Sci. Eng. 31(1A): 89-92.