

Full Length Research Paper

Histopathologic and apoptotic effect of nanosilver in liver of broiler chickens

Akradi Loghman^{1*}, Sohrabi Haghdoust Iraj¹, Djeddi Ali Naghi² and Mortazavi Pejman¹

¹Department of Pathology, Faculty of Specialized Veterinary Sciences, Science and Research Branch, Islamic Azad University, Tehran, Iran.

²Department of Clinical Science, Faculty of Veterinary Medicine, Sanandaj Branch, Islamic Azad University, Sanandaj, Iran.

Accepted 19 September, 2011

Silver nanoparticles can destroy bacteria, viruses and fungi; therefore, it is recommended as a disinfectant and can be used as a drug in the treatment of some non-curable viral disease in livestock. The aim of the present investigation was to study the effects of nanosilver induced toxicity on the liver of broiler chickens. This study was carried out on 240 one-day-old male broiler chickens (Ross 308) in a completely randomized design (CRD) in four treatments at 0 (control), 4, 8 and 12 ppm levels of silver nanoparticles that was added daily to the drinking water with four repetitions within 16 separate cages and 15 birds in each pen. At the end of the experiment (day 42), 32 chicks were randomly selected and slaughtered thereafter, H&E, terminal deoxynucleotidyl transferase dUTP nick end labeling (TUNEL) staining and light microscope was used to examine livers. Liver histopathology and H&E staining showed dose depended changes such as fatty degeneration, sinusoidal congestion, central vein dilatation, necrosis in hepatocytes and fibrosis. TUNEL staining showed significant ($p < 0.01$) increase of apoptotic cells in groups 3 (8 ppm) and 4 (12 ppm). Data were statistically analyzed using ANOVA. Lesions and apoptotic cells in groups 3 (8 ppm) and 4 (12 ppm) were more severe than in group 2 (4 ppm). It can be concluded that higher concentrations of nanosilver (8 and 12 ppm) can induce sever lesions in chickens liver.

Key words: Broiler chicks, liver, histopathology, immunohistochemistry, TUNEL.

INTRODUCTION

Nanoparticles mean particles of size in the range of 1 to 100 nm. When a macroscopic object is made into nanoparticles, its physical and chemical properties change greatly when compared with the normal materials. Nanomaterials are widely used in many fields such as the chemical industry and biomedicine. Nanosilver is one of the most commonly used nanomaterials because of its

strong disinfectant properties (Chen et al., 2007). It has much stronger germicidal capability which can kill up to 650 different types of bacteria (Kim et al., 2007). The inhibitory effect of ionic silver is due to several biological events such as attachment to cell membranes, its adsorption to the negatively charged bacterial cell wall, changes of membrane permeability, generating reactive oxygen species (ROS) and de-activating cellular enzymes. These features may be having negative effects on health and the environment, and lead to high toxicity of nanosilver (El-ansary and Al-Daihan, 2008).

Nanosilver solution is composed of colloidal suspensions of silver ions and is more stable than other solutions. Silver nanoparticles can destroy many kinds of bacteria, viruses and fungi and it is recommended that it can be used in the treatment of certain viral diseases in animals like Influenza and Newcastle (Ahari et al., 2008). However, this substance, like many other drugs has side

*Corresponding author. E-mail: lakradi@iausdj.ac.ir or loghmanakradi@yahoo.com.

Abbreviations: CRD, Completely randomized design; ROS, reactive oxygen species; nm, nanometer; JNK, c-Jun N-terminal kinase; ppm, part per million; NS, nanosilver; ALP, alkaline phosphatase; TNF, tumor necrosis factor; IL-12, Interleukin-12; TUNEL, terminal deoxynucleotidyl transferase dUTP nick end labeling; H&E, Hematoxylin and Eosin.

Table 1. Statistical analysis of apoptotic effect of nanosilver. There is no significant difference between treatment1 (4 ppm) and control group ($P>0.05$) but differences between treatments 2 and 3 with the control group is significant ($P<0.01$).

| Treatment | Control | Tr.1 (4 ppm) | Tr.2 (8 ppm) | Tr.3 (12 ppm) |
|--------------------|---------------|-----------------|-----------------|------------------|
| Apoptosis \pm SD | 1 ± 0.7^b | 1.8 ± 0.8^b | 8.6 ± 2.7^a | 10.2 ± 2.8^a |

effects and pathologic effect on living tissues. Drugs that enter the body are metabolized in liver and often excreted through the kidneys, and then they are affected more than other tissues.

As a result of nanosilver special characteristic of killing bacteria, antimicrobial materials containing nanosilver are becoming increasingly important because of their wide range of applications. Despite the widespread use of nanosilver products, relatively few studies have been undertaken to determine the biological effects of nanosilver exposure. The purpose of this present study was to evaluate the toxicity of nanosilver and to observe pathological and morphological changes in the liver of broiler chickens by an optical microscope.

MATERIALS AND METHODS

This research was carried out on 240 one-day-old male broiler chicks (Ross 308) in a completely randomized design (CRD) in four treatments at 0 (control), 4, 8 and 12-ppm levels of silver nanoparticles that was added daily to drinking water with four repetitions within 16 separate cages and 15 birds in each pen. Factors such as temperature, light, water, ventilation, nutrition and vaccination were similar for all treatments. Nanosilver used in this study was nanocid (Nanocid L2000) containing 4000 ppm per liter silver nano-particles with average size of 18 nm. Diet of chickens was prepared as starter (0 to 21 days) and grower (42 to 21 days) based on corn and soybean meal and was available to all treatments. Vaccination programs for all treatments include bronchitis, influenza, Newcastle and Gumboro.

At the end of the growing period (day 42), two chickens from each cage with the average weight was slaughtered and tissue samples were immediately isolated from liver and were fixed in 10% buffered formalin. Samples were taken to the laboratory, after tissue processing and cutting, they were placed on glass slides, and stained with H&E for review of tissue lesions. Apoptotic effects of nanosilver was investigated by using immunohistochemistry method of indirect streptavidin biotin peroxidase TUNEL assay (Dead End™ Colorimetric TUNEL System G7130, promega), and nuclear DNA fragments of apoptotic cells were seen as dark brown color in cream or light yellow background.

RESULTS

Histopathologic effect (hematoxylin-eosin staining)

The control group showed healthy liver tissue with no specific lesion (Figure 1A). In the first treatment (4 ppm), infrequent accumulations in the hepatocytes (cell swelling) and hyperemia was seen (Figure 1B). Second and third treatments (8 and 12 ppm) showed dilated

central vein, hyperemia with severe fatty change. In the third treatment (12 ppm), increased connective tissue (fibroplasia) and focal necrosis of hepatocytes was observed (Figure 1D).

Immunohistochemistry method (TUNEL staining)

Nucleus of apoptotic cells was dark brown in color and detectable from other cells. In the control group, the number of these cells was very low (Figure 2E), but in treatment groups, they increased and there was an increase in nanosilver concentration (Figure 2F, G and H).

For counting of the number of apoptotic cells in microscopic sections, apoptotic cells were randomly counted in 10 microscopic fields with magnification of 40. Results were statistically analyzed using ANOVA and Tukey methods. There was no significant difference between first treatment (4 ppm) and control group ($P>0.05$) but differences between second and third treatments with the control group is highly significant ($P<0.01$) (Table 1).

DISCUSSION

There is no consensus on the cytotoxicity of nanosilver, however, most publications do show reduced cell viability following exposure. Additional toxic effects seen in the *in vitro* studies are glutathione depletion, mitochondrial deviations or destruction and damage to cell membranes.

Nanosilver enters the body through the skin, respiratory system and gastrointestinal tract. The most important way to contact it, especially in the gastrointestinal tract is in colloidal form (Chang et al., 2006). Absorbed nanosilvers bind to plasma proteins and can enter the cells. They are distributed in organs such as liver, kidney, heart, lymph nodes, brain, lung, stomach and testicles (Wijnhoven et al., 2009). Absorbed nanosilvers from gastrointestinal tract enter liver through the portal vein and might have impact on the liver since the liver serves as the first checkpoint for everything absorbed before becoming systemic. Liver is able to actively remove compounds from the blood and transform them to chemical forms that can easily be excreted. It is a logical assumption that ingested silver nano-particles might have impact on the liver. Significant amounts of silver in the liver were observed after inhalation (Ji et al., 2007). Its

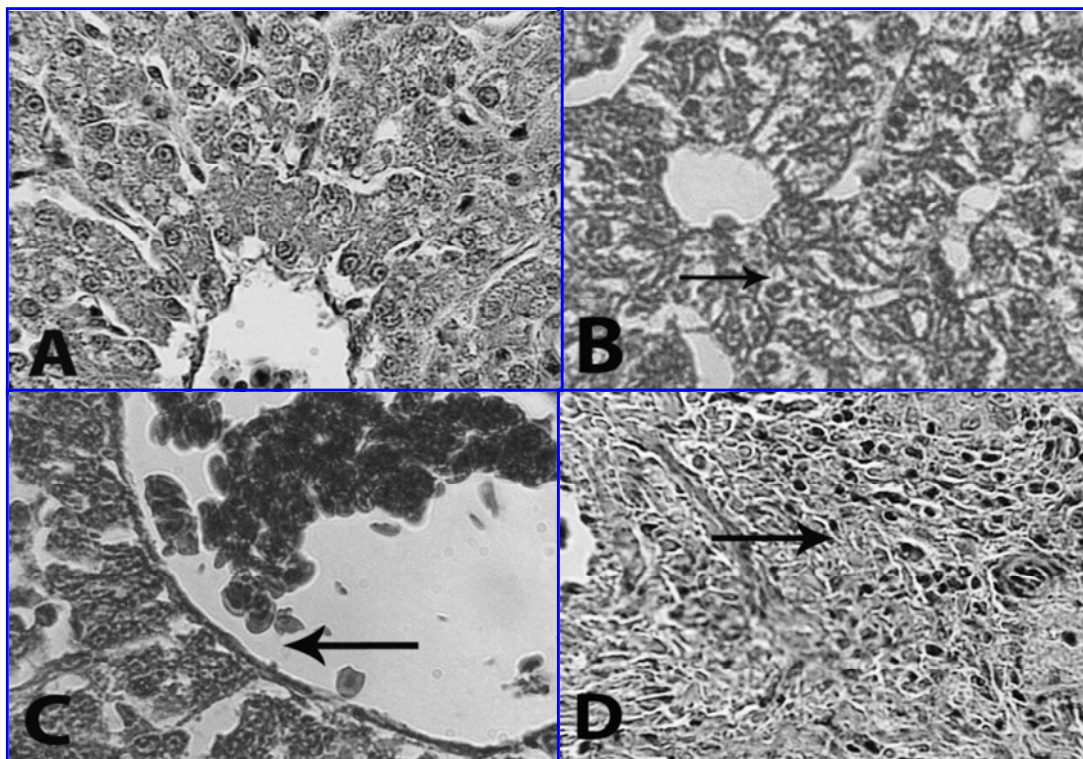


Figure 1. Histopathologic effect of NS on liver. A: Control group with no lesion; B: first treatment (4 ppm) with cell swelling (arrow); C: second treatment (8 ppm) with dilated central vein (arrow); D: third treatments (12 ppm) with fibroplasias (arrow). H&E 400x.

renal excretion via the urine has been detected (Trop et al., 2006). Recently, it has been reported that nano-particles and nano-materials generate free radicals and oxidative stress. The results of researches showed that silver nano-particles could damage different organs and tissue such as liver cells.

Microscopic studies demonstrated that absorbed nano-silver cause mild to severe dose dependent lesions in hepatocytes such as necrosis of liver cells, focal accumulation of inflammatory cells and increase of connective tissue (fibroplasias). Due to toxicity of silver, further study was conducted with reference to its oxidative stress (Xia et al., 2006). Most studies have reported decrease of cellular activities due to glutathione depletion, damage to the mitochondria and cell membrane such as increased levels of liver enzymes following the use of silver-containing wound bond (Trop et al., 2006), toxic effect on rat liver cells due to effect on mitochondrial activity and membrane permeability and toxicity on neuroendocrin cells (Hussain et al., 2006), human respiratory alveolar epithelium (Park et al., 2007), rat alveolar macrophages (Soto et al., 2007), several focal haemorrhages, fibroplasias and reduction of lymphocyte in the lymphoid follicles of Bursa Fabricius (Djeddi et al., 2008).

Hussain et al. (2005) studied the toxicity of silver nano-particles on rat liver cell line (BRL 3A). They found that

the mitochondrial displayed abnormal size, cellular shrinkage and irregular shape. In the study with BRL 3A liver cell line, depletion of GSH level, reduced mitochondrial membrane potential and increased ROS was found in association with mitochondrial perturbation, suggesting that oxidative stress might mediate the cytotoxicity of silver nano-particles.

Braydich-Stolle et al. (2005) reported the toxicity of silver nano-particles on C18-4 cell, a cell line with spermatogonial stem cell characteristics. From the study, it was concluded that the cytotoxicity of silver nano-particles to the mitochondrial activity increased with the increase in the concentration of silver nano-particles. The results show that silver nano-particles were the most toxic with drastic reduction of mitochondrial function, increased membrane leakage, necrosis and induction of apoptosis. Ji et al. (2007) reported a clear dose dependent increase of cytoplasmic vacuolization in liver cells and several cases of hepatic focal necrosis in the high dose groups.

Kim et al. (2008) showed that repeated oral doses of nanosilver for 28 days did induce liver toxicity, as shown by increases in ALP and histopathological observations of dilatation of the central vein, bile-duct hyperplasia and increased foci. Also, nanosilver cause hepatocyte apoptosis in high concentration (more than 8 ppm). This apoptotic effect of nanosilver has been reported in both

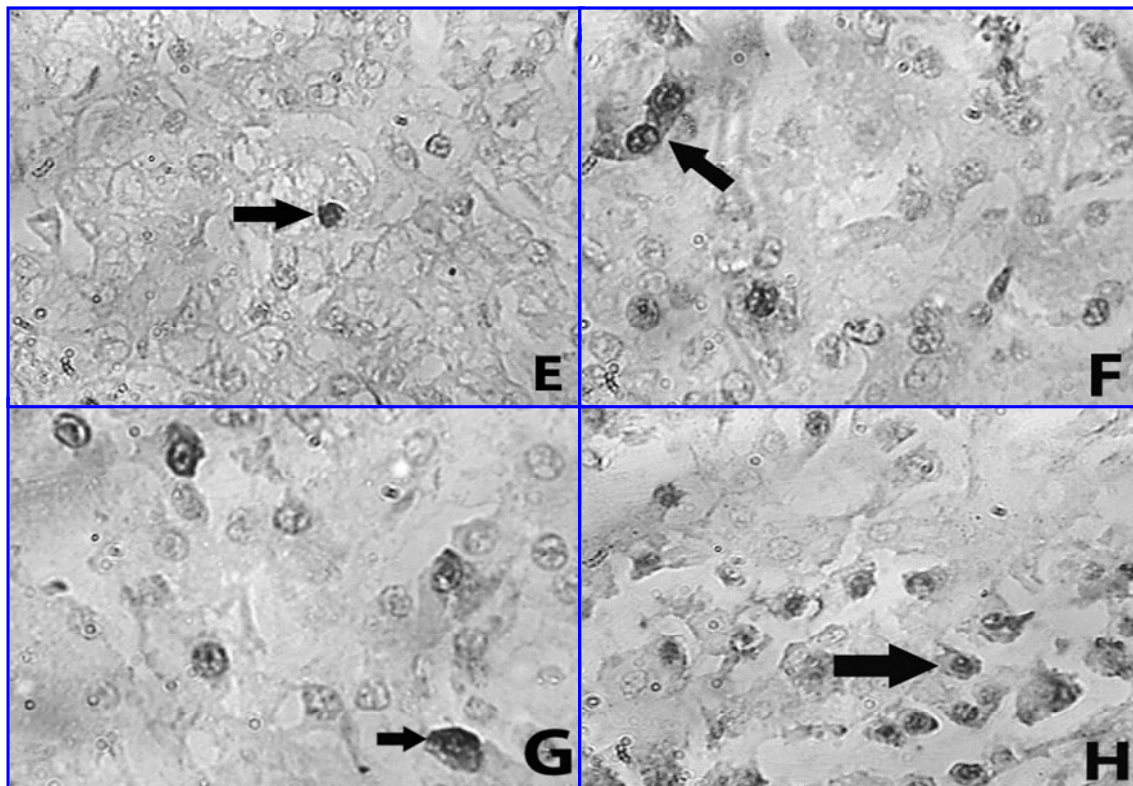


Figure 2. TUNEL staining of liver sections (400x). E: Control group; F: first treatment (4 ppm); G: second treatment (8 ppm); H: third treatments (12 ppm). The nucleus of apoptotic cells is dark brown color (arrow).

cancer and non-cancer cells *in vitro* (Gopinath et al., 2008), in inflammatory cell (Sung et al., 2008) and in fibroblasts due to release of cytochrome c into the cytosol and translocation of Bax to mitochondria. Nanosilver-induced apoptosis was associated with the generation of reactive oxygen species (ROS) and JNK activation, showing that nanosilver acts through ROS and JNK to induce apoptosis via the mitochondrial pathway (Hsin et al., 2008). Over accumulation of ROS can initiate an inflammatory response, perturbation and destruction of the mitochondria takes place. Then, apoptogenic factors like cytochrome C are released and programmed cell death is a final result.

In mice, application of a 1% nano-silver cream inhibited allergic contact dermatitis (Bhol and Schechter, 2005). It was found that the expression of two cytokines (TNF α and IL-12) was suppressed and apoptosis of inflammatory cells but not keratinocytes was induced.

Silver nanoparticles decreased the function of mitochondria and apoptosis or apoptosis-like change of cell morphology also occurred in cell lines following exposure (Braydich et al., 2005; Hussain et al., 2005, 2006). Dysfunction of mitochondria is an early and key step towards apoptosis. Thus, mitochondria seem to be sensitive targets of cytotoxicity of silver nanoparticles. In the study with BRL 3A liver cell line, depletion of GSH level and increased ROS was found in association with

mitochondrial perturbation, suggesting that oxidative stress might mediate the cytotoxicity of silver nanoparticles (Vaidyanathan et al., 2009).

Conclusion

Nanosilver causes argyria and argyriosis in humans and has pathologic effects on liver, kidney, eye, skin, respiratory and digestive system (Drake and Hazelwood, 2005; Nagnder et al., 2008). This study shows its (more than 4 ppm) harmful effect on the liver cells, especially in broilers, and recommended the use of nanosilver as anti microbial agent in poultry industry with caution and that the necessary conditions should be observed.

REFERENCES

- Ahari H, Dastmalchi F, Ghezelloo Y, Paykan R, Fotovat M, Rahmanny J (2008). The application of silver nano-particles to the reduction of bacterial contamination in poultry and animal production. *Food Man. Effic.* 2(1): 49-53.
- Bhol KC, Schechter PJ (2005). Topical nanocrystalline silver cream suppresses inflammatory cytokines and induces apoptosis of inflammatory cells in a murine model of allergic contact dermatitis. *Br. J. Dermatol.* 6: 1235-1242.
- Braydich-Stolle L, Hussain S, Schlager JJ, Hofmann MC (2005). *In vitro* cytotoxicity of nanoparticles in mammalian germline stem cells. *Toxicol. Sci.* 88: 412-419.

- Chang AL, Khosravi V, Egbert B (2006). A case of argyria after colloidal silver ingestion. *J. Cutan. Pathol.* 33: 809-811.
- Chen D, Xi T, Bai J (2007). Biological effects induced by nanosilver particles: *in vivo* study. *Biomed. Mater.* 2: 126-128.
- Djeddi AN, Akrami Mogaddam MA, Ahmadi F, Akradi L, Ashrafi Helan J (2008). Evaluation of the effectiveness of different levels of silver in (Nano scale) on weight gain and Bursa Fabricius development and on its histopathological lesions in broiler chicks. *First International Veterinary Poultry Congress Tehran-Iran.* p. 127.
- Drake PL, Hazelwood KJ (2005). Exposure-related health effects of silver and silver compounds: A Review. *Ann. Occup. Hyg.* 49: 575-585.
- El-Ansary A, Al-Daihan S (2008). On the Toxicity of Therapeutically Used Nanoparticles: An Overview. *J. Toxicol.* 2009. p. 9.
- Gopinath P, Gogoi SK, Chattopadhyay A, Gosh SS (2008). Implications of silver nanoparticle induced cell apoptosis for *in vitro* gene therapy. *J. Nanotechnol.* 19(7): 10.
- Hsin YH, Chen CF, Huang S, Shih TS, Lai PS, Chueh PJ (2008). The apoptotic effect of nanosilver is mediated by a ROS- and JNK-dependent mechanism involving the mitochondrial pathway in NIH3T3 cells. *Toxicol. Lett.* 179(3): 130-139.
- Hussain SM, Hess KL, Gearhart JM, Geiss KT, Schlager JJ (2005). *In vitro* toxicity of nanoparticles in BRL 3A rat liver cells. *Toxicol. in Vitro* 19: 975-983.
- Hussain SM, Javorina MK, Schrand AM, Duhart HM, Ali SF, Schlager JJ (2006). The interaction of manganese nanoparticles with PC-12 cells induces dopamine depletion. *Toxicol. Sci.* 92: 456-463.
- Ji JH, Jung JH, Kim SS, Yoon JU, Park JD, Choi BS, Chung YH, Kwon IH, Jeong J, Han BS, Shin JH, Sung JH, Song KS, Yu IJ (2007). Twenty-eight-day inhalation toxicity study of silver nanoparticles in Sprague-Dawley rats. *Inhal. Toxicol.* 19: 857-871.
- Kim JS, Kuk E, Yu KN, Kim JH, Park SJ, Lee HJ, Kim SH, Park YK, Park YH, Hwang CY, Kim YK, Lee YS, Jeong DH, Cho MH (2007). Antimicrobial effects of silver nanoparticles. *Nanomed.* 3: 95-101.
- Kim YS, Kim JS, Cho HS, Rha DS, Kim JM, Park JD, Choi BS, Lim R, Chang HK, Chung YH, Kwon IH, Jeong J, Han BS, Yul J (2008). Twenty-eight-day oral toxicity, genotoxicity, and gender-related issue distribution of silver nanoparticles in Sprague-Dawley rats. *Inhal. Toxicol.* 20(6): 575-583.
- Nagender RP, Eladia MPM, Josef H (2008). Silver or silver nanoparticles: a hazardous threat to the environment and human health? *J. Appl. Biomed.* 6(3): 117-129.
- Park S, Lee YK, Jung M, Kim KH, Eun-Kyung Ahn NC, Lim Y, Lee KH (2007). Cellular toxicity of various inhalable metal nanoparticles on human alveolar epithelial cells. *Inhal. Toxicol.* 19(1): 59-65.
- Soto K, Garza KM, Murr LE (2007). Cytotoxic effects of aggregated nanomaterials. *Acta. Biomater.* 3: 351-358.
- Sung JH, Ji JH, Yoon JU, Kim DS, Song MY, Jeong J, Han BS, Han JH, Chung YH, Kim J, Kim TS, Chang HK, Lee EJ, Lee JH, Yu IJ (2008). Lung function changes in Sprague-Dawley rats after prolonged inhalation exposure to silver nanoparticles. *Inhal. Toxicol.* 20: 567-574.
- Trop M, Novak M, Rodl S, Hellborn B, Kroell W, Goessler W (2006). Silver coated dressing acticoat caused raised liver enzymes and argyria-like symptoms in burn patient. *J. Traum. Inj. Infect. Crit. Care.* 60: 648-652.
- Vaidyanathan R, Kalishwaralal K, Gopalram S, Gurunathan S (2009). Nanosilver-The burgeoning therapeutic molecule and its green synthesis. *Biotechnol. Adv.* 27(6): 924-937.
- Wijnhoven SWP, Willie JGM, Peijnenburg CA, Werner I, Agnes G, Evelyn HW, Boris R, Bisschops J, Gosens I, De Meent DV, Dekkers S, Wim H, De J, Van Zijverden M, Ane Sips JAM, Geertsma RE (2009). Nanosilver a review of available data and knowledge gaps in human and environmental risk assessment *Nanotoxicol.* 3(2): 109-138.
- Xia T, Kovochich M, Brant J, Hotze M, Sempf J, Oberley T, Sioutas C, Yeh JI, Wiesner MR, Nel AE (2006). Comparison of the abilities of ambient and manufactured nanoparticles to induce cellular toxicity according to an oxidative stress paradigm. *Nano. Lett.* 8: 1794-1807.