

Full Length Research Paper

Types and distribution of mucous cells of the abalone *Haliotis diversicolor*

Guilan Di, Jianbin Ni, Zhaoxia Zhang, Weiwei You, Bo Wang and Caihuan Ke*

State Key Laboratory of Marine Environmental Science, College of Oceanography and Environmental Science, Xiamen University, Xiamen 361005, China.

Accepted 21 February, 2011

The types and distribution of mucous cells of *Haliotis diversicolor* were observed and analyzed using the alcian blue and periodic acid schiffs (AB-PAS) reaction and histological procedures. According to the color of the mucous cells, they were divided into four types: Type I, pure red; type II, pure blue; type III, purple reddish; type IV, blue purple. Most of the mucous cells in the mantle were type II, with cup- or stick-like shape. Gill axis and gill filament epithelia were rich in mucous cells and most of them were type II and III, with circle-, cup- and stick-like shapes. There were a few mucous cells in the pedal epithelia, mainly type II, whereas, the pedal gland had a great density of mucous cells, which were large or small and mainly type II and IV. There were many mucous cells in the epithelia around the mouth, most of which were medium-sized cup-shaped type II. In the esophagus, the number of mucous cells decreased gradually from the anterior to posterior, whereas in the distal intestine mucous cells, there were more than in the proximal one and they were more cup-shaped and circle-shaped, mainly type II.

Key words: *Haliotis diversicolor*; mucous cells, types, distribution.

INTRODUCTION

Abalones are one of the most commercially important species in Asian aquaculture. China is the largest producer of abalone in the world and *Haliotis diversicolor* is one of the most important breeding abalone species in South China. Germplasm degeneration and aggravated environmental pollution have greatly decreased the number of wild abalone and therefore, people have begun to farm abalone. However, abalone farms face serious threat from diseases and many abalone farms have been especially affected by epidemics of viruses and vibriosis. Thus, research must be focused both on the diagnosis of such diseases and also on obtaining resistant animals. The enhancement of abalone immunity is of primary concern.

Abalones lack an adaptive immune response and depend on an innate, non-lymphoid immune system response against microbial invasion (Xue and Xu, 2008). The epidermal mucus is considered to be an important component of innate immunity. Mucus is essential to marine molluscs as a functional substance and is usually a product of various glands mixed with exudates from the molluscan epithelia (Simkiss and Wilbur, 1977). Mucus may function in selective ion transport (Ahn et al., 1988) and act as a barrier to diffusion (Grimm-Jergensen et al., 1986). Gastropod epithelial mucus is often a first line of defense and has been shown to reduce exposure to physical stress and predation (Davies and Hawkins, 1998).

On occasions, such products from several different types of mucocyte combine to produce multifunctional mucus (Shirbhate and Cook, 1987). The mucocyte is a type of gland cell, which has many physiological functions. Mucous cells secrete mucus, containing mucopolysaccharide, glycosidoprotein and all kinds of hydrolases (Harris et al., 1973). Mucus in molluscs serves many purposes, one of which is lubrication (Davies and Hawkins, 1998). Thus, mucous cells lubricate the esophagus through the secretion of muco-

*Corresponding author. E-mail: chke@xmu.edu.cn. Tel: +86 592 2187420. Fax: +86 592 2187420.

Abbreviations: **GAGS**, Glycosaminoglycans; **AMPS**, acid mucopolysaccharide; **NMPS**, neutral mucopolysaccharide; **MMPS**, mixed (acid + neutral) mucopolysaccharide; **MPS**, mucopolysaccharides; **ADMPS**, acid-dominant mucopolysaccharides.

polysaccharides, which facilitates the delivery of food and adheres to food.

Mucocytes used (either directly or indirectly) in particle capture and transport are important for acquisition of particle processing capability in postlarval oysters (Cannuel and Beninger, 2007). Mucocytes and cilia, the known effectors of particle processing on the frontal surface of gills (Beninger et al., 1992; Beninger and St-Jean 1997b; Ward et al., 1993; Beninger and St-Jean, 1997a), are also present on the abfrontal surface.

The major component of molluscan mucus is water (Grenon and Walker, 1980; Davies et al., 1990) which forms from 81.4 to 99.8% (w/w). This leaves 0.2 to 18.6% (w/w) as solid matter which can be divided into two groups: the high molecular weight protein-polysaccharide complexes and the inorganic salts. Genon and Walker (1980) found the inorganic salts formed 3.1% (w/w) of the hydrated pedal mucus of *Patella vulgata*. These protein-polysaccharide complexes have traditionally been split into two groups according to their structure: Glycosaminoglycans (GAGs; often called mucopolysaccharides or proteoglycans) and glycoproteins (Reid and Clamp, 1978).

Mowry (1963) and Vacca (1985) describe the alcian blue and periodic acid Schiff's (AB-PAS) reaction (AB pH 2.5) dyeing method which dyes neutral GAGs blue and acidic GAGs red. In bivalve, the structure of the foot and pedal gland system of *P. vulgata* (Grenon and Walker, 1978), mucous cells of the mantle in the scallop *Chlamys farreri* (Sun et al., 2002), in *Meretrix meretrix* Linnaeus (Ren et al., 2003) and in *Argopectens irradians* (Ren and Fu, 2006) were studied. Most studies on the types and distribution of mucous cells in the mollusc have focused on the gill of bivalve. Ahn et al. (1988) identified mucocytes in *Mytilus edulis*, which contained neutral and acidic GAGs on the lateral gill surfaces and neutral or sulphated GAGs abfrontally. Beninger and Dufour (1996) recorded both mucocytes secreting acidic GAGs and mucocytes secreting neutral GAGs on the gill of *Crassostrea virginica*. Dufour and Beninger (2001) documented the types and distributions of mucocytes on the abfrontal gill surfaces of eight species of bivalves: *M. edulis*, *Modiolus modiolus*, and *Arca zebra*, *Placopecten magellanicus*, *Crassostrea virginica*, *Spisula solidissima*, *Mercenaria mercenaria* and *Mya arenaria*. Gill mucocytes in *C. farreri* (Sun et al., 2002) and oyster *Crassostrea gigas* (Cannuel and Beninger, 2007) were also studied. Mucocytes were divided into acid mucopolysaccharide (AMPS)-containing mucocytes, neutral mucopolysaccharide (NMPS) containing mucocytes and mixed (acid + neutral) mucopolysaccharide (MMPS) containing mucocytes.

In gastropods, there were a few studies about mucous cells. Shirbhate and Cook (1987) identified five types of mucus-secreting cells in the foot of *Littorina littorea*. Two of the five types contain neutral glycosaminoglycans (GAGs), which are one of the major constituents of

mucus, while two of the other three types secrete neutral, sulphated and carboxylated GAGs.

At pH 2.6, the AB method mainly stains acid mucopolysaccharide, whereas, the PAS method mainly stains neutral mucopolysaccharide and if we combine the dyeing results of AB and PAS, this can reflect changes in both the acid mucopolysaccharide and neutral mucopolysaccharide in mucous cells. *H. diversicolor* is gastropod, for now, little work has been done to determine mucocyte distribution, type and density in different tissues of the abalone *H. diversicolor*. We studied the mucous cells of a variety of tissues, carried out routine HE histological procedures staining to the corresponding positions of these tissues. The types and distribution of mucous cells of *H. diversicolor* were observed and analyzed, this contribute to the understanding of the physiological function of mucous cells. In most past studied, mixed mucopolysaccharides is not completely divided into different types. In the present study, mucous cells were divided into type I, type II, type III and type IV, mixed mucopolysaccharides was also divided into type III and type IV. We used histochemical techniques to gain a fuller understanding of the different classes of mucocytes and the distribution of mucous cell in this abalone, using AB-PAS staining.

MATERIALS AND METHODS

Abalone and their maintenance

Live specimens of *H. diversicolor* (3.757 ± 0.163 cm, n =9) were collected from Dongshan Haitian Aquaculture Co., Ltd, Fujian province and were maintained in a laboratory aquarium with a layer of sand at the bottom for 24 to 48 h. Water temperature was kept at 26 to 28°C.

The mantle, foot, gill, slime gland, mouth, esophagus, stomach, intestine, rectum and anus of the abalone (Figure 1) were dissected out and fixed in Bouin's fluid for histological studies. The tissues were dehydrated through an ascending series of ethanol concentrations (LeicaTP1020) and embedded in paraffin wax (LeicaEG1150H). Paraffin masses were cut at a thickness of 5 µm using a LeicaRM2128 rotary microtome. The sections were mounted on glass slides and dried on a LeicaH11220 at 40°C. Sections were dewaxed in xylene and then, hydrated through a descending series of ethanol concentrations. Sections were stained with Ehrlich's hematoxylin and eosin (HE) using a LeicaST5010 automatic dyeing instrument and the routine protocol for the study of general tissues.

The sections were dewaxed in xylene, then washed in running tap water for 2 min before staining with 1% AB 8GX in 3% acetic acid at pH 2.5 for 5 min and washing in running tap water. Next, the sections were oxidized in 0.5% periodic acid for 5 min, washed in running tap water for 10 min and then, rinsed in distilled water for 1 min before the PAS treatment. The sections were then, rinsed with sulphite water (equal volumes of 1% sodium metabisulphite and 0.1 N HCl) three times, washed in running tap water for 10 min and rinsed in distilled water. After aeration agitation, they were rinsed in xylene and then mounted in Harleco synthetic resin.

Examination and assessment of stained sections

Tissues were observed using a LeicaDM4500B microscope. The

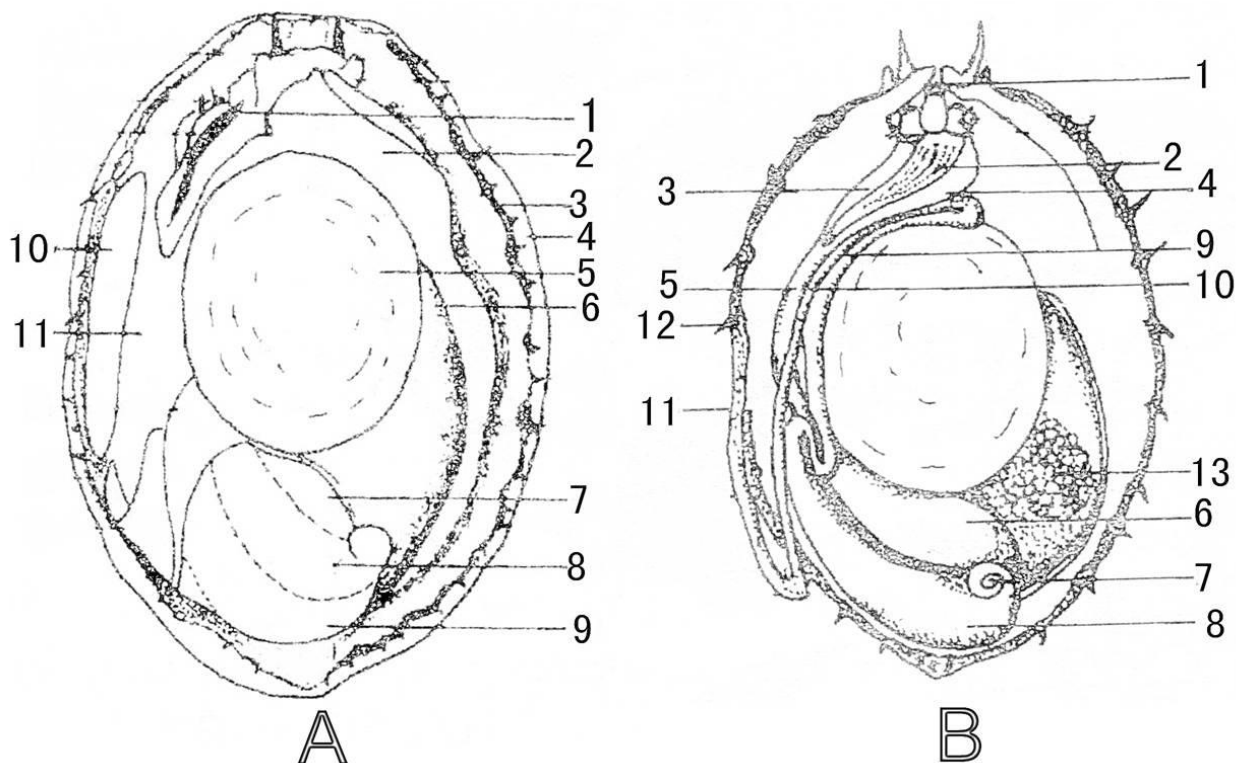


Figure 1. Anatomical structure of the abalone. (A), All of the abalone (decorticated shell, dorsal view). 1. gill; 2. mantle; 3. epipodium; 4. foot; 5. right adductor muscle; 6. horn-like digestive gland; 7. digestive gland; 8. crop; 9. stomach; 10. left slime gland; 11. mantle cavity. (B), Digestive system of the abalone (dorsal view). 1. mouth; 2. radula; 3. left lateral pouch; 4. right lateral pouch; 5. esophagus; 6. crop; 7. stomach caecum; 8. stomach; 9. intestine ascending section; 10. intestine descending section; 11. rectum; 12. anus.

histochemical procedures were carried out on tissue sections from several samples of the abalone and evaluation of staining intensities depended on subjective estimates by the authors, after the examination of several tissue sections.

RESULTS

The distribution of mucous cells was revealed using the HE dyeing method and the types and distributions of mucous cells were also observed using the AB-PAS (AB pH 2.5) dyeing method. Both methods indicated that, the mucous cells were distributed in various organs, including the mantle, gill, foot, slime gland, mouth, esophagus, intestines, rectum and anus, and mostly existed in the epidermis. Based on these observations, the mucous cells belonged to four types: Type I, pure red, PAS positive and AB negative, the cells included neutral mucopolysaccharide; type II, pure blue, PAS negative and AB positive, the cells included acid mucopolysaccharide; type III, purple reddish, PAS positive more than AB, the cells included mixed mucopolysaccharide and were more neutral than acid; and type IV, blue purple, AB positive more than PAS, these cells included mixed mucopolysaccharide and were more acid than neutral ones.

The shapes of the mucous cells are shown in Figure 2. The mucous cells were divided oval or circle-like, cup-like, stick-like and pear-shaped. In general, the mucous cells were frequently distributed, in HE stained sections. Their secretory contents either remained unstained or were weakly basophilic.

Mucous cells in mantle, foot, gill and slime gland of *H. diversicolor* mantle

The mantle is a layer of membrane surrounding the back of the body. In different parts of the inner epithelium and outer epithelium, the shape, size and density of mucous cells were all different. The mucous cells in the epithelium of the mantle were of all four types, but most of them were type II except for a few in type I. The shapes of the mucous cells were diverse and they were oval, cup-shaped, pear-shaped, stick-shaped or fusiform. The distribution of the mucous cells was not uniform in this tissue.

Mucous cells were abundant in the outer epithelium of the mantle (Figure 3 b, to d) and they were divided into four types. The frequency of these four types followed the order: Type II>type IV>type III>type I and most cells were

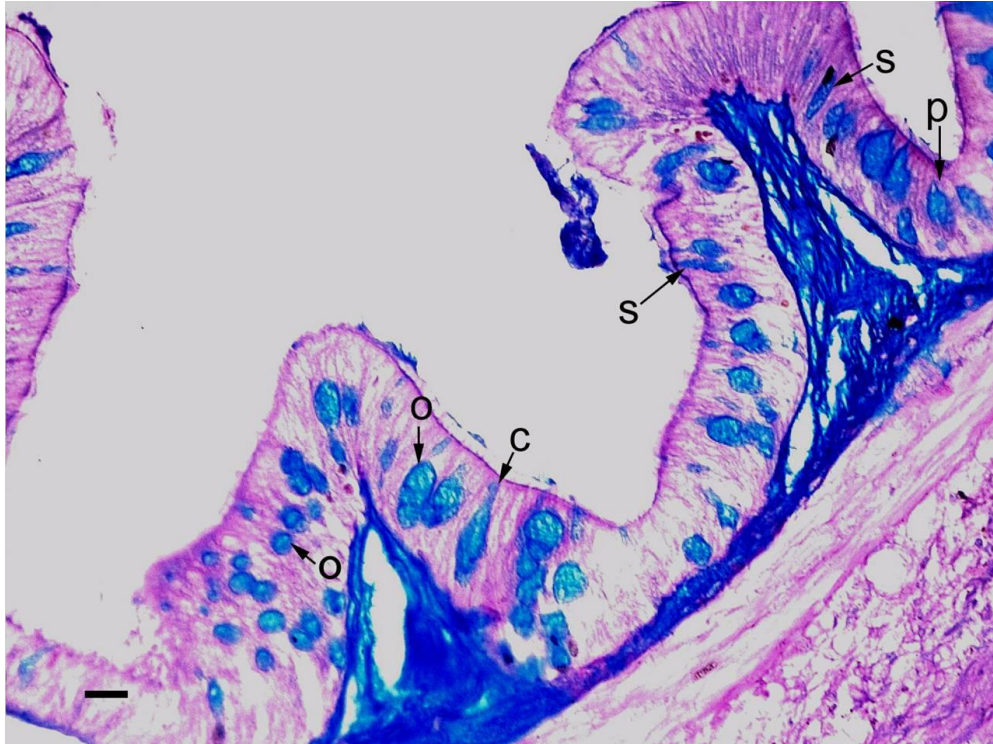


Figure 2. The shape of the mucous cells. O (oval or circle-like); c (cup-like); s (stick-like); p (pear-shaped).

small, mainly in the shape of a circle, a pear or a cup.

The mucous cells in the inner epithelium of the mantle (Figure 3 e to f) were mainly type II, with only a few type I and type IV and they were mainly circle-shaped. A few mucous cells were present in the connective tissue.

Foot

The abalone foot is large and flat, almost equal in size to the shell aperture. It is divided into the epipodium and the under foot, the latter being discoid. A pedal gland existed at the back of the under foot. There were a few mucous cells in the epithelium of the foot (Figure 3i) and all of them were type II and oval. There were many brown particulates also in some of the epithelial cells of the foot.

The pedal gland had a great density of mucous cells, large and small, mainly type III, but some type II and they were mainly in a 'circle' or 'stick' shape. There were also a small number of type IV mucous cells, which were nearly cup-shaped.

Gill

Abalones have two feather-shape gills, including a gill axis and gill filaments. A lot of gill filaments adhere to one end of the gill axis, the outer end is free. The mucous

cells were rich in the epithelia of the gill axis and the filaments. There were all four types of mucous cells, but most of them were type II and III, while a few were type I and IV.

Mucous cells only distribute epithelia of gill axis, most of them were type II, III and IV, with only a few type I. There was a greater density of mucous cells in the epithelium of the gill axis, and they were mainly stick-shaped and cup-shaped (Figure 4 b, c, f, g) and were mostly large cells. One end of the gill axis epithelium had a high density of various types of small mucous cells (Figure 4 c).

There was a greater density of circle-like type II and type III mucous cells at the base of the gill filaments (Figure 4j) and the cells were small. There was a smaller density of type III small mucous cells in the middle of the gill filaments (Figure 4k), but a greater density of type II cup-shaped mucous cells existed at the free-end of the filaments (Figure 4i, k, l); with small numbers of the other three mucous cell types and they were circle-like or irregular in shape.

Slime gland

The slime gland is located in the left side of the mantle. Under a light microscope, the venter of the mantle, where the slime glands are located, was folded into dorsal

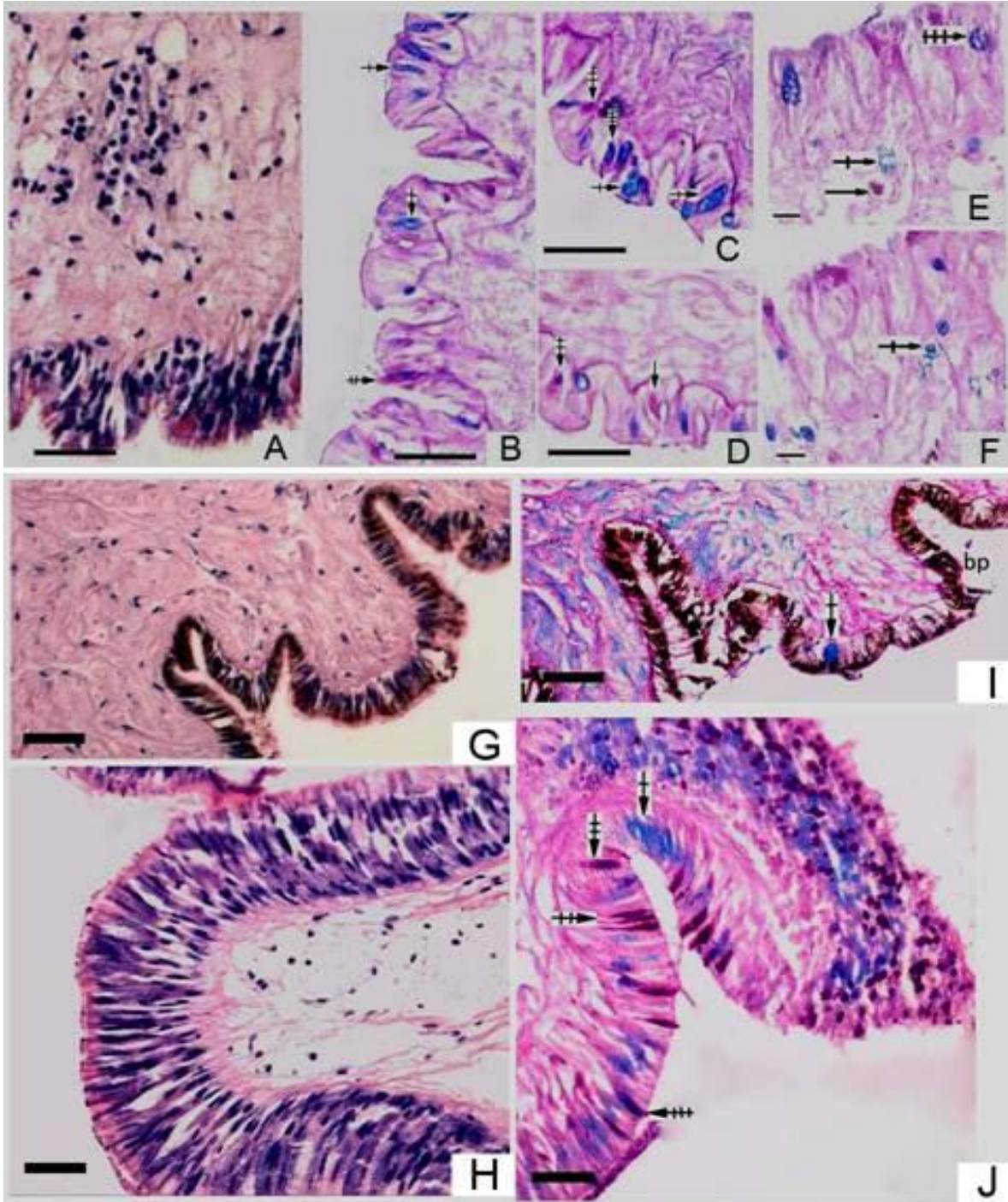


Figure 3. (↑) indicates type I mucous cells; (↑), type II; (↑), type III; and (↑), type IV. The same applies to all the following figures. (A) to (F): Mucous cells in mantle. (A) Hematoxylin and eosin Y (HE), blue showing nuclei; (B) to (D) AB-PAS, showing mucous cells in the outer epithelium of the mantle; (E), (F) AB-PAS, showing mucous cells in the inner epithelium of the mantle, with a few in the connective tissue. $\times 400$. (G) to (J): Mucous cells in foot. (G) HE, showing foot; (H) HE, showing pedal gland; (I) AB-PAS, showing mucous cells of type II. There were many brown particulates in some of the epithelial cells of the foot. bp (brown particulates); (J) showing pedal gland, AB-PAS. $\times 400$. Scale bar = 10 μm .

ridges or irregular grooves. The mucous gland cells were thick and big, PAS-positive, the cytoplasm staining pale

blue was either filled with homogeneous material or was empty and vacuolar, the nucleus was round and some

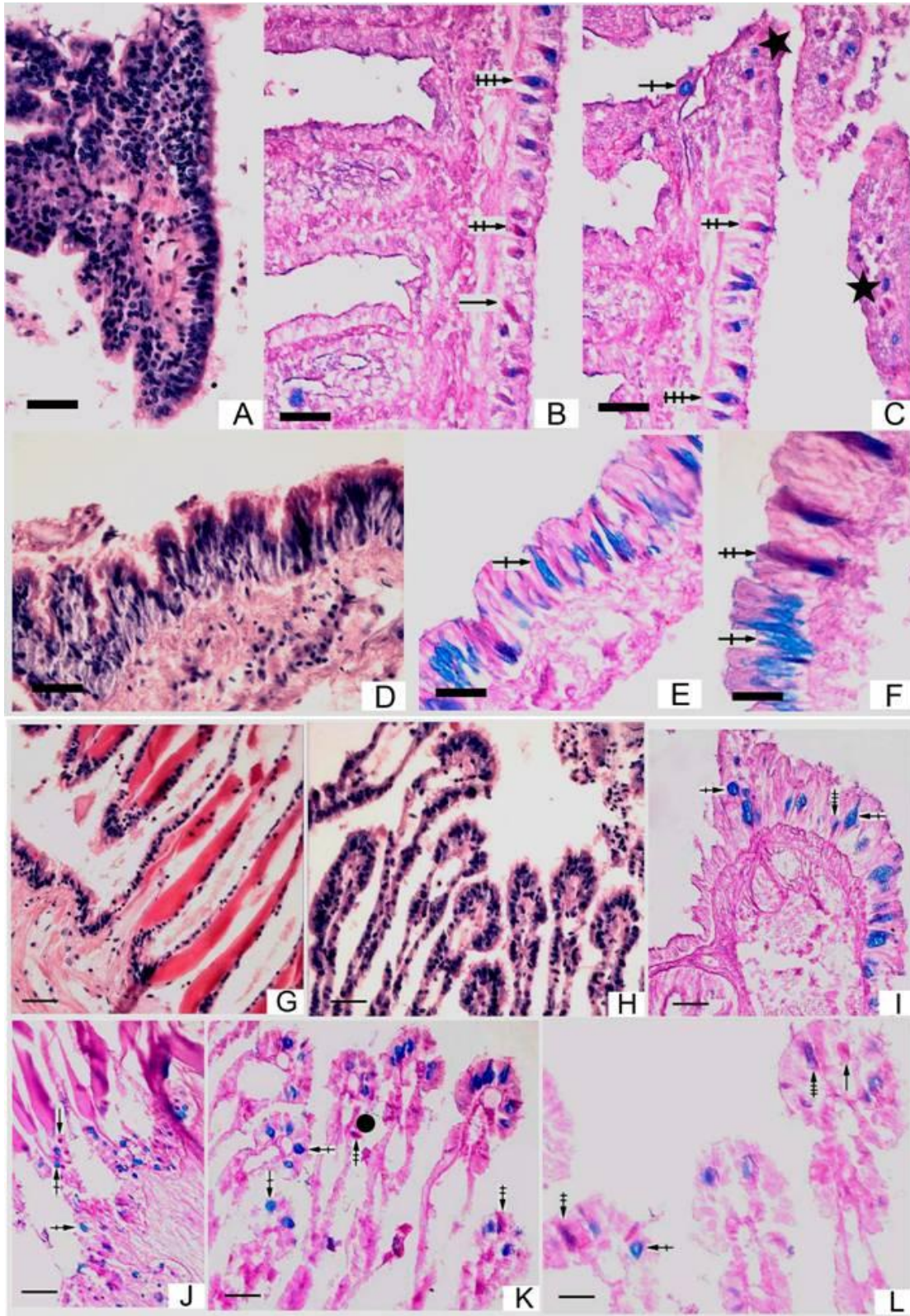


Figure 4. (A) to (F): Mucous cells in gill axis. (A), (D) HE; (B), (C) mainly medium-sized, type III mucous cells, ★ show small mucous cells; (E), (F) large mucous cells. (G) to (L): Mucous cells in gill filaments. (G), (H) HE; (J) mucous cells at base of gill filaments, small cells, type II and type III; (K) a few mucous cells in the middle of the gill filaments (●), type III; (I), (K), (L) mucous cells in filament free-ends, mainly cup-shaped type II. Scale bar, (A) to (F) = 20 μ m, (G) - (L) = 10 μ m.

nuclei had been squeezed to one side (Figure 5a). Some of the mucous gland cells were pitted deeply and formed shallow tubular glands, distributed in the connective tissue. There were four types of mucous cells in the epithelium of the slime gland; most of them were type II and IV, circle-like or cup-shaped.

Mucous cells in the alimentary tract of *H. diversicolor*

The results showed that, in different parts of the alimentary tract, the mucous cells were of different types and at different densities. There were more mucous cells in the intestines than in the mouth, but less in the esophagus, while no mucous cells were observed in the stomach caeca or the stomach.

Mouth

The proboscis of *H. diversicolor* is a short column surrounded by the papillary lips at the front-end; at the center is a longitudinal slit that is the mouth. The inner epithelium of the lips had many mucous cells, with type II being the most common form, while there was a few of the other three types, mainly cup-shaped and mostly medium-sized cells. There were also circle-like, pear-shaped and irregular-shaped mucous cells, with the circle-like cells being small, while the pear-shaped and cup-shaped cells were comparatively larger. In addition, there were a large number of brown granules in the epithelial cells (Figures 6a to d).

Esophagus

Abalones have a long esophagus, beginning at the back with a radula sac and its walls are folded into numerous deep ridges and grooves. Terminally, it becomes extremely narrow.

The number of mucous cells in the esophagus was increased dramatically and there were large numbers of all four types. There were more cup-shaped, pear-shaped and circle-like, mainly type II, mucous cells. The number of the mucous cells decreased gradually from the anterior to the posterior.

In the anterior esophagus, there was a high density of mucous epithelial cells, mainly type II, mostly cup-shaped and circle-like, with a few pear-shaped and irregular-shaped (Figure 6f). There were fewer epithelial mucous cells in the middle of the esophagus than in the anterior esophagus and they were mainly cup-shaped and circle-like type II cells but, in addition, there were small numbers of cup-shaped mucous cells (Figure 6h). When the posterior esophagus began to narrow, before connection with the crop, the epithelial mucous cells were further reduced (Wang et al., 2004). They were mainly

type II, mostly cup-shaped, but in addition, small numbers of pear-shaped and circle-like cells occurred, most of them being medium sized cells. The epithelium of the esophageal lateral pouches on both sides of the esophagus had not mucous cells, but a large number of brown particles often existed.

There were a large number of mucous cells in the intestines, rectum and anus, more in the anus than in the rectum and there were fewer mucous cells in the intestines than in the rectum. The mucous cells were mostly type II and were well dispersed. Many stick-shaped, cup-shaped and circle-like mucous cells, which were predominantly type II, were found in the inner and outer epithelia of the rectum and anus (Figure 7).

The overall types and distribution of mucous cells of *H. diversicolor* are summarized in Table 1.

DISCUSSION

AB-PAS methods of dyeing and as the standard for classification

Sibbing and Uribe (1985) divide the mucous cells of *Cyprinus carpio* L into pear-like, bag-like and cup-like shapes. Sinha (1975) suggests that, the three types of mucous cells are simply the manifestation of different stages in development involved in the synthesis of different materials, namely the bag-like cells are in the earlier period of its growth, pear-like in the middle and cup-like in the fully mature fish.

However, this kind of categorization has many inadequacies. Firstly, cell appearance classification alone cannot reflect the composition of the mucous cell; secondly, mucous cells can have various appearances because of differences in their distribution and thus, it is very difficult to unify mucous cells according to one standard, that is, the cell appearance; and thirdly, the mucous cells are stereoscopic and as a result, the appearance of a tissue slice does not necessarily represent the whole appearance of the cell.

Kitzan and Sweeny (1968), studying the structure of *Protopterus annectens* epidermis using PAS dyeing methods, describes type I cells as bright red, type II as a pale red color and type III as scarlet. The AB-PAS method was suggested by Mowry (1963). Perera (1991) used periodic acid-basic fuchsin as an alternative to the PAS technique in order to demonstrate carbohydrates and mucosubstances in paraffin sections.

Beninger and St-Jean (1997a) adopt the standard histochemical classification of mucus secretions (Vacca, 1985), the gill sections were stained using AB-PAS protocol described in Beninger et al. (1993), wherein all mucocyte secretions are termed mucopolysaccharides (MPS), in some cases, the MPS secretion type, indicative of the viscosity of mucus (Grenon and Walker, 1980), was specified (Beninger and St-Jean, 1997a). The MPS is

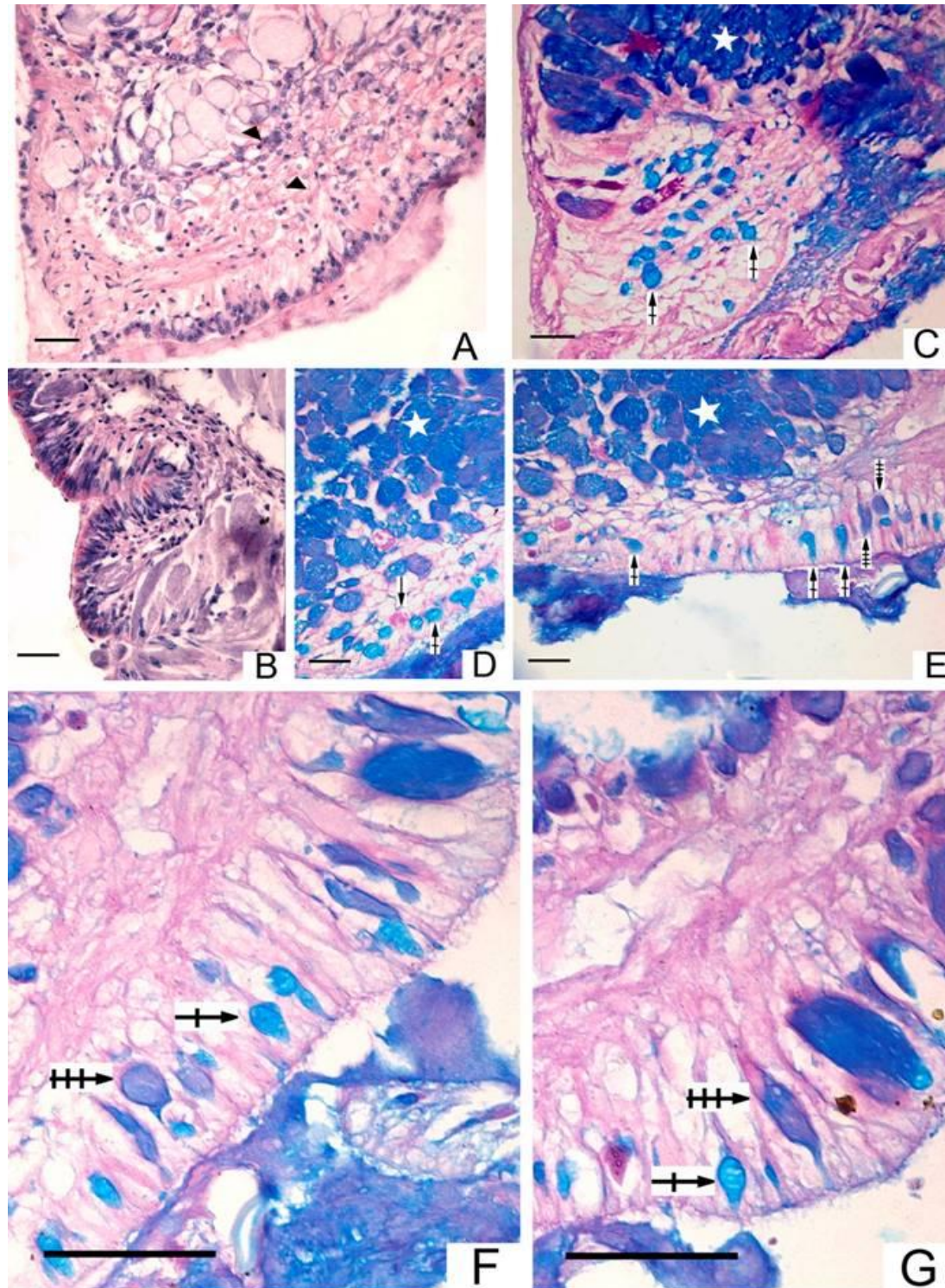


Figure 5. Mucous cells in slime gland. (A), (B) HE, nucleus round, some nuclei have been squeezed to one side (▲), or emptying vacuolar; (C) to (G) AB-PAS, mucous gland cells were thick and big, cytoplasm stained pale blue (☆), there were four types of mucous cells in the epithelium of the slime gland. Scale bar = 10 µm.

classified according to their degree of acidity. NMPS are PAS positive, Alcian-blue negative, pink and present low viscosity. AMPS are PAS negative, Alcian-blue positive,

blue and present high viscosity. Between these two endpoints MMPS were distinguished, containing roughly equal proportions of NMPS and AMPS, various shades of

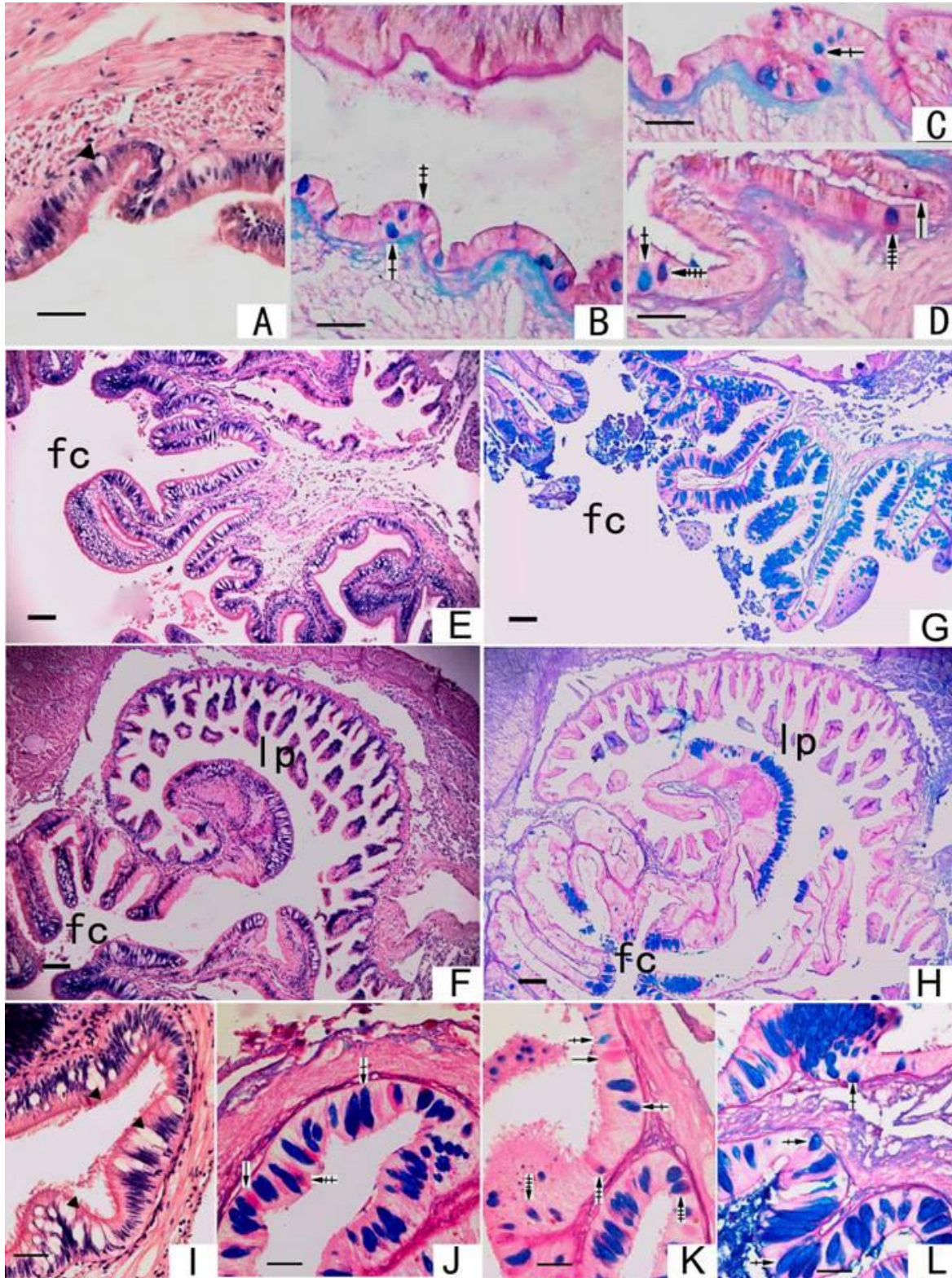


Figure 6. (A) to (D): Mucous cells in the inner epithelium of mouth. (A) HE, mucous cells (\blacktriangle); (B) to (D), type II was the most common form and there were a large number of brown granules in the epithelial cells. (E) to (L): Mucous cells in esophagus. (E), (F) HE, transverse section of the esophagus, $\times 200$; (G) AB-PAS, anterior esophagus partitions, large quantities of mucous cells, mainly type II, $\times 200$; (H) AB-PAS, mid esophagus partitions, $\times 200$; (I) HE, \blacktriangle indicates mucous cells $\times 400$; (J) to (L) AB-PAS in the inner epithelium of esophagus, mainly type II, a small number of the other three types, $\times 400$. fc (food canal), lp (lateral pouch). Scale bar, (A) to (H) = 10 μm , (I) to (L) = 5 μm .

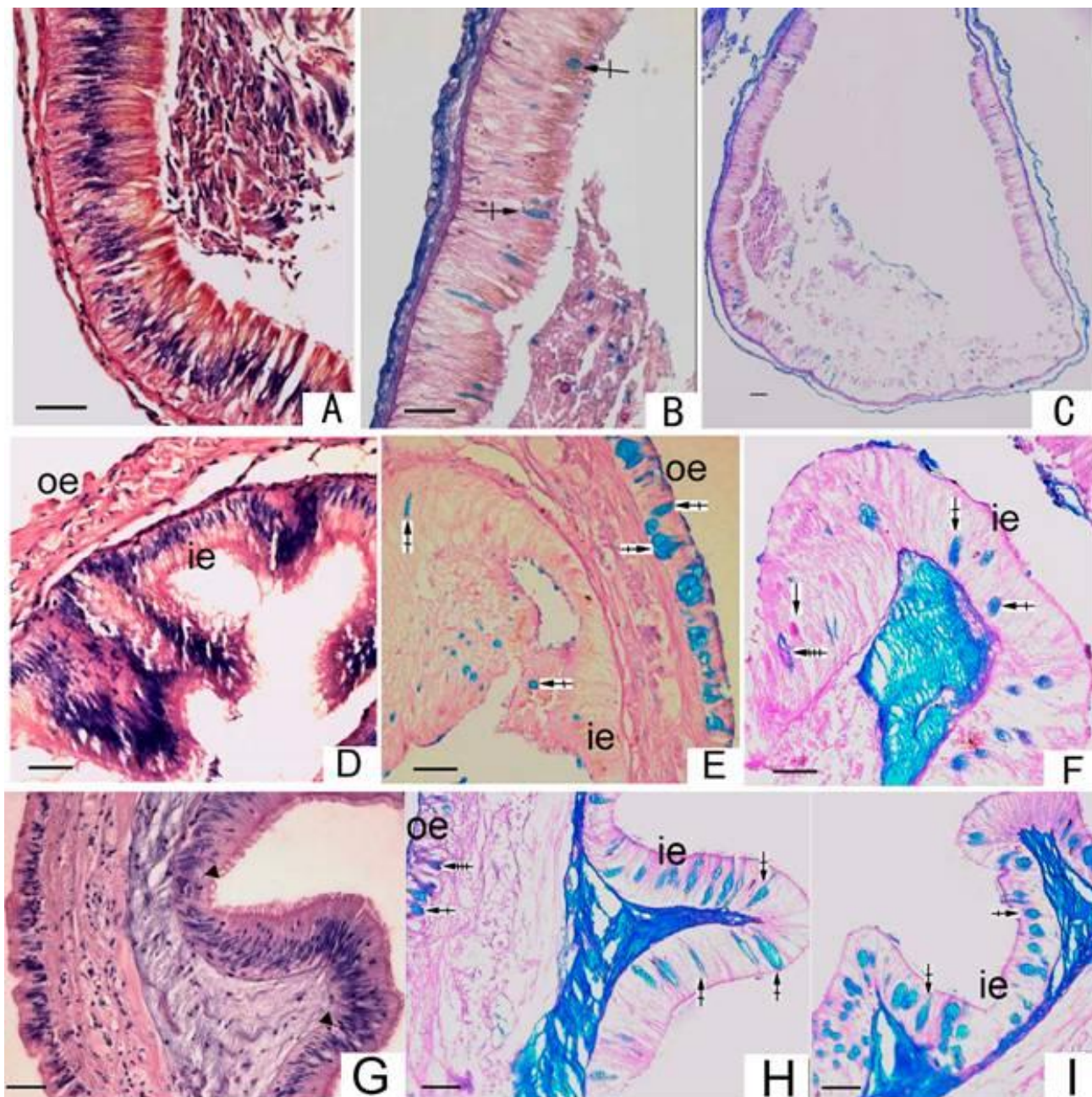


Figure 7. (A) to (C): Mucous cells in intestines. (A) HE; (B), (C) AB-PAS, mainly type II, stick-shaped or circle-like. (D) to (F): Mucous cells in rectum. (D) HE; (E), (F) AB-PAS, mucous cells in outer and inner epidermis, mainly type II, oval or circle-like, oe, outer epidermis, ie, inner epidermis. (G) to (I): Mucous cells in anus. (G) HE; (H), (I) AB-PAS, mucous cells in outer and inner epidermis, mainly type II, cup-shaped and circle-like, oe, outer epidermis, ie, inner epidermis. Scale bar= 10 µm.

purple and acid-dominant mucopolysaccharides (ADMPS), which contain a majority of AMPS. In previous studies, terms such as “acid-dominant” and “neutral-dominant”, although, useful in dealing with a particular species (Beninger et al., 1993), mixed mucopolysaccharides (MMPS) is not completely divided into different types.

We used the AB-PAS methods and the mucous cells were divided into four types. We believe that the AB-PAS

reaction was better for the classification of the mucous cells of *H. diversicolor*. Thus, it can attain the purpose of distinguishing different types of mucous cells, because the different characteristics of the mucopolysaccharides present in mucous cells can indicate directly the different functions of the mucous cells. This is much more meaningful than classification by means of cell shape. In the present study, mixed mucopolysaccharides (MMPS) was also divided into type III and type IV. We not only

Table 1. Types and distribution of mucous cells of the abalone *H. diversicolor*.

Item	Main type	Main shape	Number	Cell Size
Mantle	Type II, type II >type IV>type III>type I	Oval, stick-shaped	Moderate	Medium
Foot	Type II	Oval	Little	Medium
Pedal gland	First type III, second type II	Circle-like, cup-shaped	Higher	Large, small
Gill axis	Type II, III, IV	Stick-shaped and cup-shaped	Moderate	Large, medium and small
Gill filaments	First type II, second type III	Cup-shaped, circle-like	Moderate	Medium
Slime gland	Type II, type IV	Circle-like, cup-shaped	Higher	Large, medium
Mouth	Type II	Cup-shaped	Moderate	Medium
Esophagus	Type II	Cup-shaped, pear-shaped	Higher	Medium
Intestine	Type II	Stick-shaped, circle-like	Low	Medium
Rectum	Type II	Circle-like	Moderate	Medium
Anus	Type II	Cup-shaped, circle-like	Moderate	Medium

studied the mucous cells of gills and studied a variety of tissues, but also carried out routine HE histological procedures staining to the corresponding positions of these tissues. The types and distribution of mucous cells of *H. diversicolor* were observed and analyzed, this contribute to the understanding of the physiological function of mucous cells.

Distribution of the roles of mucous cells in the abalone

In different tissues, the mucous cells were of different types, densities and shapes, and this was closely related to cells function. The mucous cells were generally confined to the outer layers of the epithelium and frequently opened onto the surface. The present research provided histochemical evidence for the differentiation and distribution of different classes of mucopolysaccharide in abalone epithelium.

Since the epidermis cells of the mantle, gill and foot of the abalone directly contact sea water, they must have the ability to resist infection by microorganism in the sea water and so molluscan epithelial mucus is often the first line of defense. The epidermis of the foot only has a small number of mucous cells. However, a portion of the epithelium was stained with brown granules and so the composition and function of these granules need to be further investigated.

Grenon and Walker (1978) examine the structure of the foot and pedal gland system of *Patella vulgata* and find that, mucocytes are randomly distributed throughout the foot, except in the peripheral region. Epithelial goblet cells (mucocytes) are present in many gastropods (Fretter and Graham, 1994). In the present study, there were a few mucous cells in the epithelium of the foot and all of them were type II and oval.

Mucous cells were very abundant in mantle tissue of molluscs (Alejandra et al., 1994). Sun et al. (2002) used AB-PAS staining protocol, the scallop *C. farreri* mucous

cells in the mantle were divided into four types, namely type I, type II type III and type IV. The mucous cells can be observed in the epithelium and connective tissue. In *M. meretrix* Linnaeus, the distribution of mucous cells in mantle was similar to *C. farreri* (Ren et al., 2003). In *A. irradians*, there were also type I, type II, type III and type IV mucous cells in the mantle, the mucous cells can be observed in the inner and the outer epithelium (Ren and Fu, 2006). In the present study, the abalone *H. diversicolor* mantle mucous cells were also divided into type I, type II type III and type IV, the mucous cells can be observed in the inner epithelium, the outer epithelium and connective tissues. Thus, the distribution of the mucous cells was not uniform in this tissue.

The slime gland was the main source of abalone body mucus, with adhesive sand or the excretion in the mantle cavity and excreted them (Bullough, 1958). Histological studies have shown that the mucous gland cells directly secreted mucus into the mantle cavity and were not located on the surface of the mantle and connected directly with the outside, but were mainly distributed in grooves in the mantle, which may be related to protection of the thick and tender mucous cells from damage.

In *C. farreri* (Sun et al., 2002), the mucous cells in the epithelium of gill axis were mainly types I and III, The mucous cells in the epithelium of gill filaments were mainly types II and IV. In abalone *Haliotis discus hannai* (Wang et al., 2004), the mucous cells were rich in the epithelium of gill axis and filaments and most of them were in type II and type I, while a few were in type III and type IV. In the present study, the mucous cells in the epithelium of gill axis were mainly types II, while a few were in type III and type IV. The mucous cells in the epithelium of gill filaments were mainly types II and III.

Dufour and Beninger (2001) documented the types and distributions of mucocytes on the abfrontal gill surfaces of eight species of bivalves. The gills of three homorhabdic filibranchs, *M. edulis*, *Modiolus modiolus* and *A. zebra*, presented different densities of abfrontal mucocytes, from very dense in *M. edulis* to sparse in *A. zebra*. The gills of

one heterorhabdic filibranch, *P. magellanicus*, were studied. The heterorhabdic gills had intermediate mucocyte densities, with highest concentrations of abfrontal mucocytes on the principal filaments and had both AMPS- and MMPS-secreting mucocytes on their abfrontal and frontal surfaces. The gills of one heterorhabdic pseudolamelli branch, *C. virginica*, contained only AMPS-secreting mucocytes on its abfrontal surface; the frontal surface had in addition NMPS-secreting mucocytes. In one case, a different mucocyte secretion type was reported. Eble and Scro (1996), also using AB-PAS, found NMPS-secreting mucocytes on the abfrontal surface of *C. virginica*. The gills of three homorhabdic eulamelli branches, *S. solidissima*, *M. mercenaria* and *M. arenaria* were also studied. The abfrontal mucocytes of *S. solidissima* were very abundant, where the abfrontal mucocytes were glandular. *M. arenaria* and *M. mercenaria* had fewer abfrontal mucocytes. This group had only AMPS-secreting abfrontal mucocytes and exhibited the most extreme heterogeneity in abfrontal mucocyte density of the gill types studied. These species represent the four major gill types, cover a broad taxonomic range and for some, show taxonomic diversity within a gill type.

In oyster, *C. gigas* (Cannuel and Beninger, 2007), two types of mucocytes were most frequently observed; AMPS-containing mucocytes and MMPS-containing mucocytes. NMPS-containing mucocytes were rarely observed.

In bivalves, the function of gill is respiration, as well as filter feeders feature. In gastropods, the function of gill is mainly respiration. Types and distribution of mucous cells in gill may be related to the gill types. Sibbing and Uribe (1985) found that, mucous cells of fish are varied such as its morphology and histochemical characteristics in different developmental stages. Therefore, the reasons of different types and distribution of mucous cells in gill is because of different developmental stages, the gill types or other factors, mucous cells of the molluscs should be more extensive research

Mucus in molluscs serves many purposes, one of which is lubrication (Davies and Hawkins, 1998). Acidic mucus is highly viscous and is a good lubricant because it is not easily hydrated or removed from the epithelium (Faillard and Schauer, 1972). Mucus secreted by abfrontal mucocytes lubricates the abfrontal surface; species with high densities of abfrontal mucocytes could utilize abfrontal mucus to reduce drag, especially in the highly fused gills, such as those of the eulamelli branches (Dufour and Beninger, 2001). The differing distributions of abfrontal mucocytes may reflect different selective pressures acting on the gills within the various taxa (Dufour and Beninger, 2001).

Secretions from the abundant abfrontal mucocytes of *P. magellanicus* might lubricate the gills and protect their delicate structure from hydrodynamic forces during valve clapping and especially swimming (Le Pennec et al.,

1988). Abundant abfrontal mucocytes are also present on the eulamelli branch gill of *S. solidissima*; in this species it was suggested that abfrontal mucus lubricates the water channels and canals, facilitating water flow through the gill (Beninger et al., 1997a).

Using the AB-PAS staining method, Beninger et al. (1995) describe two different types of mucocyte on the palp ridged surface; subepithelial, acid-dominant secretion mucocytes and epithelial mucocytes characterized by neutral secretions. Beninger and Le-Pennec (1993) investigate the possible role of the bucco-oesophageal glands in the blue mussel *M. edulis* L, and using an AB 8GX PAS procedure, finds that the glands contained large amounts of both neutral and acid mucopolysaccharides.

According to Graham (1939), the esophagus in prosobranch animals is divided into the central food channel and two long lateral pouches, the left and right side of the esophagus had long-shaped lateral pouches. The esophagus is divided into anterior, mid and posterior partitions. In the anterior esophagus, which is shorter and connected to the mouth, no torsion has occurred. Before the wide mid esophagus wide hind narrows and becomes funnellform, there is a counter-clockwise 180° torsion. The mid esophagus was again divisible into two histologically and functionally clear regions, a central food channel and two baggy lateral pouches, which are unique structures of prosobranch animals. The posterior esophagus is a short narrow channel connected to the crop. The mucosal epithelium of the anterior esophagus and food channel and the posterior esophagus had mucous cells. Mucous cells in the esophagus of the abalone were mainly type II, the high density of mucous cells is mainly related to food lubrication.

Mucous cells in the alimentary tract of the abalone were mainly type II, which indicated that they mainly contained acid mucopolysaccharide, in accord with the digestion of food needing acidic conditions. Acidic mucus is highly viscous and is a good lubricant, thus, the high density of mucous cells is mainly related to food lubrication and agglutination. In the front and last segments of the alimentary tract of the abalone, namely the mouth, esophagus and rectum, distribution of mucous cells was more centralized and this distribution have resulted in more mucus contributing to food transport and digestion. There was a higher density of the various types of mucous cells in the mouth, which related to the complexity of structure and function in this area. When abalones ingest food, casual organisms enter the interior of the body along with the food. Antibacterial material (such as hydrolase) in the mucus here can prevent to a certain extent pathogenic organisms entering the digestive tract. Starting with the mouth and ending with the rectum, the digestive tract is in direct contact with the sea water and the opportunity of contacting pathogenic organisms is greater, and therefore the abundance of mucous cells in the epidermis of the mouth and rectum

segments is greater. The crop, stomach caecum and stomach are in the middle section of the alimentary tract, their function is relatively simple and that is why no obvious mucous cells were observed in these regions.

The distribution of acid-dominant secretion mucocytes in the troughs may also be related to the proposed function of the trough in particle rejection (Foster-Smith, 1978). Beninger and Le-Pennec (1993) uses endoscopy to provide functional correlates to more traditional histological determinations of mucocyte distribution. These techniques were used on *M. edulis* to trace the origin of the ventral mucus strand, which transports trapped food particles to the mouth, as do the mucocytes on the frontal surfaces of the gill filaments and/or the mucus glands within the filaments dorsal to the ventral grooves. Beninger and St-Jean (1997a) suggested that, the mucus produced by various pallial organs differs according to the function of each organ. They further suggest that viscous acid-dominated GAGs are produced on or from areas leading to exposed surfaces and that, these function in particle transport against the prevailing current flow, for example, nonselective transportation of pseudofaeces or in the ventral gill grooves; lower-viscosity mixed GAGs are produced where transport is on or from areas leading to an enclosed surface and with current flow, for example, transport of particles for ingestion and low-viscosity neutral GAGs occur where a reduced viscosity function is important, for example, on labial palps where food particles are extracted from the mucus prior to sorting.

Many scholars have studied the fundamental principles of particle processing mechanisms using indirect techniques such as mucocyte mapping (Beninger et al., 1993; Beninger and Dufour, 1996; Beninger and St-Jean, 1997a, b; Beninger et al., 2003; Beninger, 2005; Dufour and Beninger, 2001; Dubois et al., 2005). Mucocyte mapping was particularly informative to the fine-scale functioning of the adult oyster gill (Beninger et al., 2005). Cannuel and Beninger (2007) has reported on the ontogenetic changes in mucocyte total volumes and distributions on the *C. gigas* gill during development of the juvenile life stage and related these changes to functional capacities of particle processing. The relationship between the type of GAGs and physiological function and the relationship between distribution laws and physiological function in *H. diversicolor* needs further study.

ACKNOWLEDGEMENTS

This research was supported by the Hi-Tech Research and Development (863) Program of China (Project No. 2006AA10A407), the Modern Agro-industry Technology Research System (Project No. nycyx-47) and the Innovative Platform for Science and Technology, Fujian Province (Project No. 2008N2004). We are grateful to Professor John Hodgkiss for his great help in improving

the English in the paper.

REFERENCES

- Ahn HY, Sue LF, Ma JKH, Pinkstaff CA, Pore RS, Overman DO, Malanga CJ (1988). Synthesis and secretion of mucous glycoprotein by the gill of *Mytilus Edulis* L. Histochemical and chromatographic analysis of [¹⁴C] glucosamine bioincorporation. *Biochimica. et Biophysica. Acta.* 966: 122- 132.
- Alejandra GG, Rosa IO, Miguel B (1994). Microscopic anatomy of the mantle of the pearl oyster *Pinctada mazatlanica* (Hanley, 1856). *J. Shellfish. Res.* 13(1): 85-89.
- Beninger PG, Ward JE, MacDonald BA, Thompson RJ (1992). Gill function and particle transport in *Placopecten magellanicus* (Mollusca: Bivalvia) as revealed using video endoscopy. *Mar. Biol.* 114: 281-288.
- Beninger PG, Le-Pennec ML (1993). Histochemistry of the bucco-oesophageal glands of *Mytilus edulis*: the importance of mucus in ingestion. *J. Mar. Biol. Assoc. UK.* 73: 237-240.
- Beninger PG, St-Jean SD, Poussart Y (1995). Labial palps of the blue mussel *Mytilus edulis* (Bivalvia: Mytilidae). *Mar. Biol.* 123: 293-303.
- Beninger PG, Dufour SC (1996). Mucocyte distribution and relationship to particle transport on the pseudolamellibranch gill of *Crassostrea virginica* (Bivalvia: Ostreidae). *Mar. Ecol.-Prog. Ser.* 137: 133-138.
- Beninger PG, St-Jean SD (1997a). The role of mucus in particle processing by suspension-feeding marine bivalves: unifying principles. *Mar. Biol.* 129: 389-397.
- Beninger PG, St-Jean SD (1997b). Particle processing on the labial palps of *Mytilus edulis* and *Placopecten magellanicus* (Mollusca:Bivalvia). *Mar. Ecol. Prog. Ser.* 147:117-127.
- Beninger PG, Dufour SC, Decottignies P, Le-Pennec M (2003). Particle processing mechanisms in the archaic, peri-hydro-thermal vent bivalve *Bathypecten vulcani*, inferred from cilia and mucocyte distributions on the gill. *Mar. Ecol. Prog. Ser.* 246:183-195.
- Beninger PG, Cannuel R, Jaunet S (2005). Particle processing on the gill plicae of the oyster *Crassostrea gigas*: fine-scale mucocyte distribution and functional correlates. *Mar. Ecol. Prog. Ser.* 295:191-199.
- Bullough WS (1958) *Practical invertebrate anatomy.* Macmillan Press Ltd, London, pp. 342-346.
- Cannuel R, Beninger PG (2007). Acquisition of particle processing capability in juvenile oyster *Crassostrea gigas*: ontogeny of gill mucocytes. *Mar. Biol.* 151: 897-905.
- Davies MS, Jones HD, Hawkins SJ (1990). Seasonal variation in the composition of pedal mucus from *Patella vulgata* L. *J. Exp. Mar. Biol. Ecol.* 144: 101-112.
- Davies MS, Hawkins SJ (1998). Mucus from marine molluscs. *Adv. Mar. Biol.* 34: 1-71.
- Dubois S, Barillè L, Cognie B, Beninger PG (2005). Particle capture and processing mechanisms in *Sabellaria alveolata* (Polychaeta: Sabellariidae). *Mar. Ecol. Prog. Ser.* 301: 159-171.
- Dufour SC, Beninger PG (2001). A functional interpretation of cilia and mucocyte distributions on the abfrontal surface of bivalve gills. *Mar. Biol.* 138: 295-309.
- Eble AF, Scro R (1996). General anatomy. In: Kennedy VS, Newell RIE, Eble AF (eds) *The eastern oyster Crassostrea virginica.* Maryland Sea Grant, College Park, pp. 19-73.
- Faillard H, Schauer R (1972). Glycoproteins as lubricants, protective agents, carriers, structural proteins and as participants in other functions. In: Gottschalk A (ed) *Glycoproteins. Their composition, structure and function, part B, vol 5.* Elsevier, Amsterdam, pp. 1246-1267.
- Foster-Smith RL (1978). The function of the pallial organs of bivalves in controlling ingestion. *J. Mollus. Stud.* 44:83-89.
- Fretter V, Graham A (1994). "British Prosobranch Molluscs", 2nd ed Ray Society, London.
- Graham A (1939). On the structure and function of the alimentary canal of the style-bearing prosobranch. *Proc. Zool. Soc. Lond. B.* 109: 75-112.
- Grenon JF, Walker G (1978). The histology and histochemistry of the

- pedal glandular system of two limpets: *Patella vulgata* and *Acmaea tessulata* Gastropoda: Prosobranchia). J. Mar. Biol. Assoc. UK. 58: 803-816.
- Grenon JF, Walker G (1980). Biochemical and rheological properties of the pedal mucus of the limpet, *Patella vulgata* L. Comp. Biochem. Physiol. B. 66: 451-458.
- Grimm-Jørgensen Y, Ducor ME, Piscatelli J (1986). Surface mucus production in gastropods is dependent on environmental salinity and humidity. Comp. Biochem. Phys. A. 83: 415-419.
- Harris JE, Watson A, Hunt S (1973). Histochemical analysis of mucous cells in the epidermis of brown trout *Salmo trutta* L. J. Fish. Biol. 5: 345-351.
- Kitzan SM, Sweeny PR (1968). A light and electron microscope study of the structure of *Protopterus annectens* epidermis. I. Mucus production. Can. J. Zool. 46: 767-772.
- Le Pennec M, Beninger PG, Herry A (1988). New observations of the gills of *Placopecten magellanicus* (Mollusca: Bivalvia), and implications for nutrition. II. Internal anatomy and microanatomy. Mar. Biol. 98: 229-237.
- Mowry RW (1963). The special value of methods that colour both acidic and vicinal hydroxyl groups in the histochemical study of mucins with revised directions for the colloidal iron stain, the use of alcian blue 8GX, and their combination with the periodic acid-Schiff reaction. Ann. NY Acad. Sci. 106: 402-23.
- Perera PAC (1991). Periodic acid-basic fuchsin (PABF) technique for the demonstration of carbohydrates and mucosubstances in paraffin sections: an alternative to PAS technique. J. Histotechnol. 14: 155-158.
- Reid L, Clamp JR (1978). The biochemical and histochemical nomenclature of mucus. Br. Med. Bull. 34: 5-8.
- Ren SZ, Yan Y, Song WB (2003). Studies on the Histology and Histochemistry of the Mantle of *Meretrix meretrix* Linnaeus. J. Ocean Univ. Qingdao, 33(5): 701-706.
- Ren SL, Fu Y (2006). Microscopic Anatomy and Types of Mucous Cells of the Mantle of *Argopectens irradians*. Periodical Ocean Univ. China, 36(5): 739-744.
- Shirbhate R, Cook A (1987). Pedal and opercular secretory glands of *Pomatias*, *Bithynia* and *Littorina*. J. Mollus. Stud. 53: 79-96.
- Sibbing FA, Uribe R (1985). Regional specializations in the oropharyngeal wall and food processing in the carp (*Cyprinus Carpio* L.). Netherl. J. Zool. 35: 377-422.
- Simkiss K, Wilbur KM (1977). The molluscan epidermis and its secretions. Symposia Zool. Soc. London, 39: 35-76.
- Sinha GM (1975). A histochemical study of the mucous cells in the bucco-pharyngeal region of four Indian freshwater fishes in relation to their origin, development, occurrence and probable functions. Acta. Histochem. 53: 217-223.
- Sun HS, Wang YY, Wang P, Wu SJ, Sun XQ, Li GY (2002). Types and distribution of mucous cells in mantle and gill of *Chlamys farreri*. J. Fishery Sci. China, 9(4): 315-317.
- Vacca LL (1985). Laboratory manual of histochemistry. Raven Press, New York.
- Wang YY, Sun HS, Tao DY (2004). Types and Distribution of Mucous Cells in Mantle, Gill and Foot of Abalone *Haliotis discus hannai*. Chin. J. Zool. 39(3): 8-11.
- Ward JE, MacDonald BA, Thompson RJ, Beninger PG (1993). Mechanisms of suspension feeding in bivalves: resolution of current controversies by means of endoscopy. Limnol. Oceanogr. 38: 265-272.
- Xue J, Xu Y (2008). Effects of traditional Chinese medicine on immune responses in abalone, *Haliotis discus hannai* Ino. Fish. Shellfish. Immun. 24: 752-758.