

## **ALECTATIC AND DEGENERATIVE EFFECTS OF DATURA METEL LEAF EXTRACT ON THE MORPHOLOGY OF THE ALVEOLAR AND HEPATIC TISSUES**

Onyije FM<sup>1</sup>, Ilegbedion IG<sup>1</sup>, Digba KA<sup>2</sup>

1. Department of Medical Laboratory Science, Faculty of Basic Medical Sciences, College of Health Sciences, Niger Delta University, Wilberforce Island, Bayelsa State.
2. Department of Medical Laboratory Science, Faculty of Basic Sciences, Igbinedion University, Okada, Nigeria,

Author for Correspondence: Felix M. Onyije

Email: onyijefelix@yahoo.com, onyije.felix@mail.ndu.edu.ng

### **ABSTRACT**

**Aim:** This study was aimed at investigating the effects of Datura metel (D. metel) on the histology of the lungs and liver in rat models.

**Methods:** Twenty rats were divided into four groups of five each. D. metel extract was administered (50, 100 and 150mg/kg) to the rats through an orogastric tube once daily for 21 days.

**Results:** The histomorphological parameters showed thin atrophic and collapsed alveolar sacs (Atelectasis) in the lungs. In the liver there was severe ballooning degeneration of hepatocytes. Biochemical parameters revealed significant decreases ( $p < 0.01$  and  $p < 0.05$ ) in chloride experimental groups ( $70.60 \pm 1.5$  and  $74.00 \pm 6.9$ ) and  $\text{HCO}_3^-$  also increased significantly ( $p < 0.01$ ) in the second group ( $17.80 \pm 8.07$ ). The level of urea concentration in serum increased but was not significant in all the experimental groups ( $7.38 \pm 0.3$ ,  $7.27 \pm 1.9$  and  $7.30 \pm 1.3$ ) as well as Creatinine ( $11.00 \pm 1.22$ ,  $40.25 \pm 1.2$ ,  $58.00 \pm 30.5$ ) when compared with their controls ( $6.13 \pm 0.2$  and  $47.50 \pm 3.4$ ).

**Conclusion:** The result of administration of Datura metel in rat model is suggestive of pulmohepatic and kidney toxicity at a concentration of 50mg/kg.

**Key words:** Pulmonary, Ballooning degeneration, Histopathology, Liver, Lungs

### **INTRODUCTION**

History has it that plants are the oldest sources of medication and its use predates written human history (Fabricant and Farnsworth, 2001). They are either used alone or combined with other substances for the treatment of diseases (Avwioro, 2010). Datura metel (D. metel) belongs to the family Solanaceae, and includes about 2,400 species (Ahmad et al., 2012). It is called thorn apple (Abdullahi et al., 2003), devil's apple, stink weed, Jimson weed and angels' trumpet (Ahmad et al., 2012). In Nigeria it is called different names by different ethnic groups. In Ogoni the southern part of Nigeria it is called "jegemi" (Wannang1 et al., 2009), in the Eastern part (Igbo), it is called "myaramuo", in the Western part (Yoruba) it is called "gegemu", "ewe ikan" or "Apikan" (Ahmad et al., 2012; Abdullahi et al., 2003), while the Northern part (Hausa) calls it "zakami" (Abdullahi et al.,

2003). D. metel has been reported to have hallucinogenic properties and these classes of plants are used as mind altering agents (Abubakaret al., 2009). It has a wide range of medicinal value which includes mental illness, epilepsy, insomnia, laryngitis, trachitis, catarrh, diarrhoea, skin disease, gonorrhoea, menstrual pain and many more (Babalola, 2014). D. metel plant contains dangerous levels of tropane alkaloids which are poisonous and may be fatal if ingested (Preissel and Preissel, 2002) though may be dose dependent, which is the reason for its prohibition in some regions. It is also used for psychoactive activities where it is abused. Atelectasis is due to hypoventilation of lung units. It may involve the entire lung or a lobe, segment, or a subsegment. It can be caused by intrinsic obstruction of an airway or external compression from lymph nodes, parenchymal masses, or other entities. When lung units are

atelectatic, ventilation-perfusion mismatch leads to hypoxemia. Infection may result from sustained atelectasis (O'donnell, 2012). The etiology and pathogenesis of atelectasis have been linked to impairment of surfactant (secreted by type II pneumocytes) function, compression of lung tissue and absorption of alveolar air (Duggan and Kavanagh, 2005).

## MATERIALS AND METHODS

### Plant Material

The plant was collected in July, 2014 at Akute-Odo, Ifo Local Government Area of Ogun State, and was confirmed by a botanist in the Department Pharmacognosy and Herbal Medicine, Faculty of Pharmacy, Niger Delta University, Wilberforce Island, Bayelsa State.

### Solvent Extraction of *D. metel*

The leaves were dried at 50°C and pulverized. The powdered material was extracted in 95% ethanol for 48 hours. It was decanted, filtered and concentrated using a regulated water bath. The extract obtained was reconstituted with water to give the required dosage of 50, 100 and 150 mg/kg body weight.

### Animal Care

Twenty adult Sprague Dawley rats weighing between 190 and 250g were obtained from the animal house of College of Health Sciences, Niger Delta University, Wilberforce Island, Bayelsa State. All animals were allowed free access to commercially purchased grower's feed and water ad libitum. All animals were handled gently and calmly in accordance with the guidelines for animal research as detailed in the NIH Guidelines for the Care and Use of Laboratory Animals (NIH Publication 2009).

### Experimental Design for in vivo study

The animals were divided into four groups of five rats each and the extract was administered with the aid of orogastric tube once per day for 21 days as follows.

**Group A (Control):** Received water

**Group B:** 50mg/kg of *D. metel* extract

**Group C:** 100mg/kg of *D. metel* extract

**Group D:** 150mg/kg of *D. metel* extract

### Histopathology

The rats were sacrificed 24 hours after the last dose, the lungs and livers were excised, fixed in 10% formal saline, dehydrated in ascending grades of alcohol, impregnated and embedded in paraffin wax. Paraffin sections (5µm thick) were stained with haematoxylin and eosin (H&E)

method for general histological examination. Slides were viewed under a light microscope and digital photomicrographs were taken.

### Biochemistry

Blood samples were obtained from the rats were kept in a plain vial and centrifuged at 5000 rpm for 10 min at room temperature to obtain serum. Serum urea and creatinine as well as electrolytes (chloride and bicarbonate ions) were determined using commercially available assay kits (AGAPPE product) following standard methods.

### Statistical analysis

Data were expressed as mean  $\pm$  standard deviation and were analysed using One-way Analysis of Variance (ANOVA) + Tukey-kramer multi comparison test, values are statistically different from control at  $p < 0.05^*$  and  $**0.01$  using GraphPad Instat (Version 3.10). Charts were drawn using Paleontological Statistics (PAST) software package (Version 2.17c).

## RESULTS

The results of the final weight (240.4 $\pm$ 36.0, 214.8 $\pm$ 11.3, 205.8 $\pm$ 22.9 and 246 $\pm$ 45 respectively) of animals increased but were not statistically significant when compared with their initial weight (234.6 $\pm$ 31.53, 206.4 $\pm$ 11.9, 199.6 $\pm$ 3.57 and 206 $\pm$ 2.9 respectively) (Table 1). There was significant decrease in chloride in both group B (70.60 $\pm$ 1.5) and D (74.00 $\pm$ 6.9), were as in group C there was decrease level of chloride when compared with the control group (90.75 $\pm$ 5.3). In Table 2, bicarbonate (HCO<sup>3</sup>) increased in groups B (17.80 $\pm$ 8.07), C (7.25 $\pm$ 2.2) and D (6.80 $\pm$ 2.5) but was only significant in group B when compared with the control group (4.00 $\pm$ 1.8). The level of urea concentration in serum increased but was not significant in all the experimental groups (7.38 $\pm$ 0.3, 7.27 $\pm$ 1.9 and 7.30 $\pm$ 1.3) when compared with the control (6.13 $\pm$ 0.2) in Figure 1. Creatinine concentration decreased in group B (11.00 $\pm$ 1.22) and group C (40.25 $\pm$ 1.2) but increased in group D (58.00 $\pm$ 30.5) when compared with the control (47.50 $\pm$ 3.4) in Figure 2. In figure 3 (Micrograph of lung), Group A which is the control slide showed a well circumscribed alveolar sacs and duct. The pneumocytes are normal and distinguishable. Group B which was administered with 50mg/kg of *D. metel* extract showed collapsed alveolar sacs (Atelectasis), as well as collapsed alveolar duct. There was also presence of inflammatory cells in the stroma of the lung tissue when compared with the control. Group C (100mg/kg) showed few areas of loss of

connective tissue. Group D received 150mg/kg of D. metel extract and differed from the control due to its thin atrophic alveoli walls. Figure 4 (Micrograph of Liver), group A slide showed normal histology of the liver architecture with a well displayed central vein and radiating hepatocyte. The size of the canaliculi (sinusoid) is also normal. Group B (50mg/kg of D. metel extract) showed occluded central vein by blood.

There are some hepatocytes with ballooned cytoplasm and markedly dilated canaliculi (sinusoid) are also prominent. There was also presence of ballooned cytoplasm in group C. While group D which was administered 150mg/kg of D. metel extract shows more severe ballooning degeneration and swollen hepatocytes have expanded cytoplasm. Few darkly stained cells are suggestive of Mallory bodies.

Table 1: Comparison of weight of animals

Group	Initial Wt (g)	Final Wt (g)	P value	
A (Control)	234.6±31.5	240.4±36.0	P>0.05	Not significant
B	206.4±11.9	214.8±11.3	P>0.05	Not significant
C	199.6±3.57	205.8±22.9	P>0.05	Not significant
D	206.0±2.9	246.0±5.1	P>0.05	Not significant

Each value represents the mean ± standard deviation, values are statistically different from initial weight at p<0.05\* one-way analysis of variance (ANOVA) + Tukey-kramer multiple comparison test.

Table 2: Electrolyte analysis

Parameter (mmol/L)	Group A (Control)	Group B	Group C	Group D
Chloride	90.8±5.3	70.6±1.5**	82.8±14.1	74.0±6.7*
Bicarbonate	4.0±1.8	17.8±8.1**	7.3±2.2	6.8±2.5

Each value represents the mean ± standard deviation, values are statistically different from control at p<0.05\* and \*\* 0.01 One-way Analysis of Variance (ANOVA) + Tukey-kramer multi comparison test.

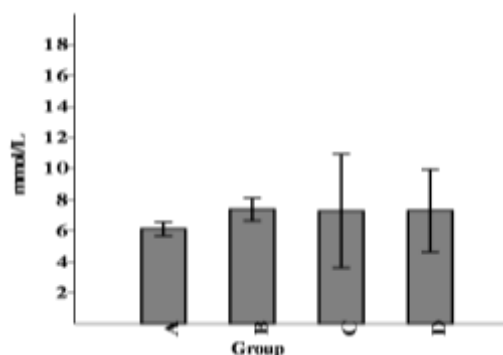


Fig. 1: Chart of urea

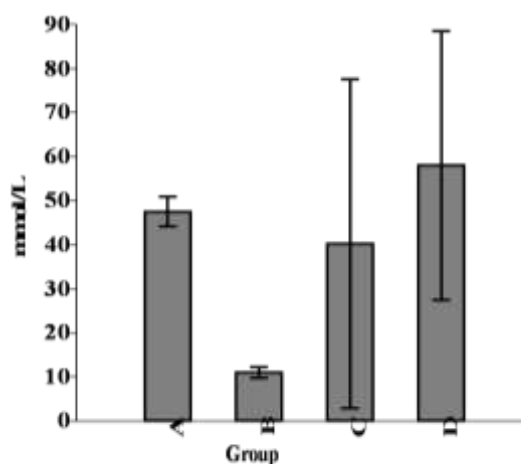


Fig. 2: Chart of creatinine

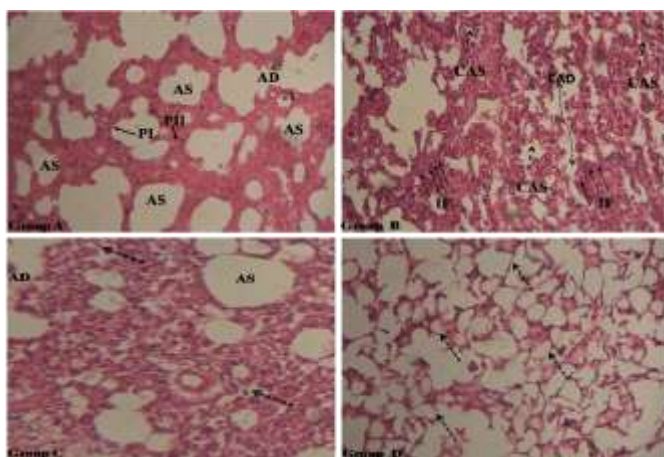


Figure 3 (Lung): Group A (CNT) with well circumscribed alveolar sacs (AS) and duct (AD). The Pneumocytes (PI and PII) are normal. Group B collapsed alveolar sacs (Atelectasis) (CAS), collapsed alveolar duct (CAD) and infiltration of inflammatory cells (IF). Group C shows loss of connective tissues in the alveolar (Dash arrows). Group C Thin atrophic alveoli (Dash arrows). H&E x100

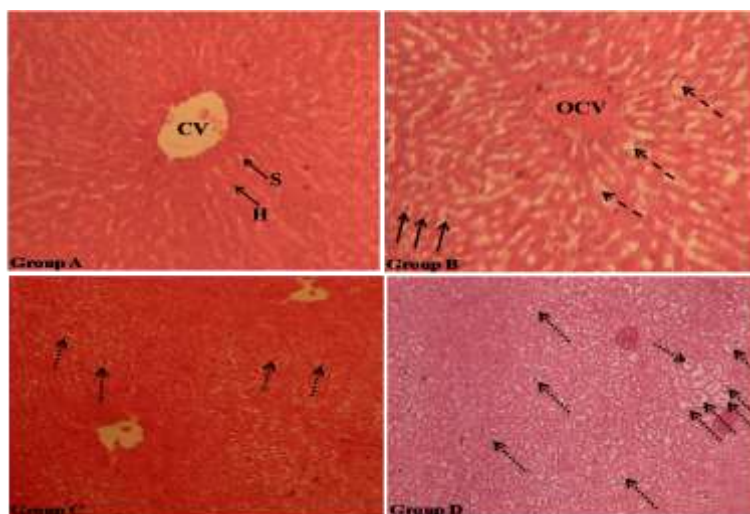


Figure 4 (Liver): Group A (CNT) slide showing normal Central Vein (CV) with well radiating Hepatocyte (H) and Sinusoid (S). Group B displays Central Vein occluded by blood (OCV). Hepatocytes cytoplasm are ballooned (Arrows) and markedly dilated Sinusoid (Dash Arrows) are also visible. Group C also shows presence of ballooned cytoplasm (Dash Arrows). Group D shows more severe ballooning degeneration, swollen hepatocytes having expanded cytoplasm (Dash Arrows). There is also presence of Mallory bodies (Dot Arrows). H&E x100

**DISCUSSION**

Several studies have been performed on the effect of plants on animal tissues (Oduola et al., 2010; Onyije and Awioro, 2012; Onyije et al., 2010; Fowotade et al., 2017). The appearance of ballooning degeneration in the histology of liver parenchyma is a predominant mode of hepatocyte injury in hepatitis (Puja, 2014). There are several mechanisms by which toxins can cause hepatic injury which involves the expression of cytokines, growth factors and the extracellular matrix but these mechanisms are poorly understood (Michalet et al., 2013; Sharma et al., 2011; Kaplowitz, 2004). The mechanism that leads to the obstruction of the hepatic veins is thrombosis (Stuart, 1957) (thrombosis has to do with the formation of a blood inside a vessel,

obstructing blood flow). The obstruction of a single hepatic vein is usually clinically silent but two or more may increase sinusoidal blood pressure and reduce sinusoidal blood flow (Parker, 1959), as a result of this may cause sinusoidal dilatation and congestion among others (Akiyoshi and Terada, 1999). The findings of this research revealed occluded central vein, markedly dilated sinusoid and different levels of ballooning degeneration of hepatocyte following the administration of 50,100 and 150mg/kg body weight of *D. metel* as seen in Figure 4. These findings are similar to some researches carried out with a similar species (*Datura stramonium*) such as Adekomi et al., (2011) where they reported occlusion of the portal vein, degenerative and progressive cell death in rats

exposed to fumes of *Datura stramonium* (0.5g and 0.74g). This present research is also similar to the work done by Zuhour and Samia (2014) who reported congestion, fatty changes and necrosis, infiltration of inflammatory cells in Sprague Dawley rats administered with 5 and 7.5mg/kg of *Datura stramonium* Seed. Contrary to the findings of this study, Dugan et al. (1989) reported normal liver in rats fed with diet containing 0.5, 1.58 and 5.0% *Datura stramonium* seed. Atelectasis which is the collapse or closure of the alveoli of the lungs (Wedding and Gyls, 2005) may be caused by pneumonia, obstruction from mucus plugging, tumour, general anaesthesia, surgery (Proto 1996; Ishikawa et al., 2002; Vargas et al., 1993), lack of surfactant that coat the lining of alveoli and prevent it from collapse, large dosage of opioids or sedatives, smoking etc. (Cedars, 2015). In the present research the lung tissue of the administered groups (50, 100,150 mg/kg of *D. metel* extract) showed atelectasis with inflammatory cells, loss of connective tissue and thin atrophic alveoli walls when compared to the control slide (group A) as seen in figure 3. This is corroborated by extreme significant increase ( $p<0.01$ ) in serum bicarbonate in group B ( $17.80\pm 8.07$ ) and other increases in groups C ( $7.25\pm 2.2$ ) and D ( $6.80\pm 2.5$ ) when compared with the control group ( $4.00\pm 1.8$ ), as seen in table 2. It is documented that increase level of serum  $\text{HCO}_3$  is seen in compensated respiratory acidosis and in metabolic alkalosis (Tietz, 1983; Friedman, 1980). This is also in agreement with the work of Adekomiet et al., (2011) where there was a major alteration and enlargement of the alveoli sacs in rats administered with *Datura stramonium* leaf. Low serum chloride can be seen in salt-losing nephropathy, various acid base disturbances, conditions characterized by expansion of extracellular fluid volume and a lot more (Tietz, 1983; Friedman, 1980). There was significant decrease ( $p<0.01$ ) in chloride in both group B ( $70.60\pm 1.5$ ) and D ( $74.00\pm 6.9$ ). The level of chloride in group C decreased but was not significant when compared with the control group ( $90.75\pm 5.3$ ). This result corroborates the serum urea increase of experimental groups ( $7.38\pm 0.3$ ,  $7.27\pm 1.9$  and  $7.30\pm 1.3$ ) which is an indication of acute and chronic intrinsic renal disease (Tietz, 1983; Friedman, 1980). Creatinine concentration decreased in groups B ( $11.00\pm 1.22$ ) and C ( $40.25\pm 1.2$ ) but increased in group D ( $58.00\pm 30.5$ ) when compared with the control ( $47.50\pm 3.4$ ) in Figure 2. Creatinine elevation is seen in renal functional impairment while decrease characterized by muscle wasting.

The findings on the kidney in this research are closely related to the research carried out by Adekomi et al. (2011) where they reported major degenerative changes in the kidney in rats administered with *Datura stramonium* leaf.

### Conclusion

The entire findings of this research are similar to the compelled work of U.S.-Australian symposium on the effects of poisonous plants on domestic livestock (Richard et al., 1978). Base on this research *D. metel* is not a nontoxic plant and its rampant abuse may even cause more harm.

### Acknowledgements

Authors wish to acknowledge Perede Anthony, and Miller, Azibaodi Myles for their contribution towards the realisation of this article.

### References

- Abdullahi M, Muhammad G, Abdulkadir NU (2003). Medicinal and Economic Plants of Nupe land. Jube Evans Book and Publications, SW718, Down Hospital Road Bida, Niger State. Nigeria, pp: 234
- Abubakar M, Suleiman U, Frank A, Ukwuani A. (2009) Hallucinogenic Effects Of Aqueous Seeds Extract Of *Datura Metel* In Rats.. The Internet Journal of Pharmacology 9 (1).
- Adekomi DA., Tijani AA., Adeniyi T. D (2011) Musa A. A.and Usman B. Exposure to smoke extract of *Datura stramonium* leaf: Some of its effects on the heart, liver, lungs, kidneys and testes of male Sprague Dawley rats. Journal of Pharmacognosy and Phytotherapy. 3(1). 6-12
- Ahmad AT, Daniel T. Adeniyi 1, Damilare AA (2012). *Datura metel* is deleterious to the visual cortex of adult Sprague Dawley rats. Advances in Applied Science Research, 3 (2):944-949
- Akiyoshi H, Terada T. (1999) Centrilobular and peri sinusoidal fibrosis in experimental congestive liver in the rat. J Hepatol; 30:433-39
- Avwioro OG (2010). Effectiveness of some medicinal plant decoction in the treatment of malaria in Nigeria. Annals of biological research.1 (2):230-237
- Babalola S. A. *Datura Metel* L: Analgesic or Hallucinogen? "Sharo" Perspective (2014) Middle-East Journal of Scientific Research 21 (6): 993-997,
- Cedars S. Collapsed Lung (Atelectasis), [www.cedars-sinai.edu/Patients/Health-Conditions/Collapsed-Lung-Ateletaisi.aspx](http://www.cedars-sinai.edu/Patients/Health-Conditions/Collapsed-Lung-Ateletaisi.aspx). Retrieved 3rd of July, 2015.

- Dugan GM, Gumbmann MR, Friedman M. Toxicological evaluation of jimson weed (*Datura stramonium*) seed. *Food Chem Toxicol.* 1989 Aug; 27(8):501-510.
- Duggan M., Kavanagh B.P, (2005) Pulmonary Atelectasis: A Pathogenic Perioperative Entity *Anesthesiology*, 102: 838-854.
- Fabricant DS, Farnsworth NR (2001)"The value of plants used in traditional medicine for drug discovery". *Environ. Health Perspect.*109 Suppl 1 (Suppl 1): 69–75. doi:10.1289/ehp.01109s169.
- Fowotade AA, Fowotade A, Enaibe BU, Avwioro OG (2017). Evaluating Toxicity Profile of Garlic (*Allium sativum*) on the Liver, Kidney and Heart Using Wistar Rat Model. *International Journal of Tropical Disease & Health* 26(2): 1-1
- Friedman, RB (1980). Effects of Diseases on Clinical Laboratory Tests. *Clin Chem.* 26(4):1D-476D.
- Ishikawa S, Takahashi T, Ohtaki A, Sato Y, Suzuki M, Hasegawa Y, et al (2002) Peripheral pulmonary atelectasis and oxygenation impairment following coronary artery bypass grafting. *J Cardiovasc Surg (Torino)*; 43:419-22
- Kaplowitz N. Drug-induced liver injury (2004). *Clin Infect Dis*;38:S44–S48
- Michael B. Duncan, Changqing Yang, Harikrishna Tanjore, Patrick M. Boyle, Doruk Keskin, Hikaru Sugimoto, Michael Zeisberg, Bjorn R. Olsen and Raghu Kalluri (2013) Type XVIII collagen is essential for survival during acute liver injury in mice. *Dis. Model. Mech.* 6(4): 942-951
- National Institutes of Health, Office of Animal Care and Use 2009. Guidelines for preparing USDA annual reports and assigning USDA pain and distress categories. [http://oacu.od.nih.gov/arak/documents/usda\\_report\\_s.pdf](http://oacu.od.nih.gov/arak/documents/usda_report_s.pdf). Accessed 5th April 2016.
- O'donnell A.E, (2012). Bronchiectasis, Atelectasis, Cysts, and Localized Lung Disorders in Goldman's Cecil Medicine (24<sup>th</sup> Ed.), 2012
- Oduola T., Bello I.S., Idowu T.O., Avwioro O.G., Adeosun OG, Isa LO (2010) Histopathological changes in Wistar albino rats exposed to aqueous extract of unripe *Carica papaya* North American *Journal Medical Science* 2:(5); 234-237
- Onyije FM, Avwioro OG (2012). Effect of ethanolic extract of *Bauhinia monandra* leaf on the liver of alloxan induced diabetic rats. *Journal of Physiology and Pharmacology Advances* 2(1) 59-63.
- Onyije FM, Avwioro OG, Waritimi EG (2012). Evaluation of nephrotoxic effect of *bauhinia monandra* on the kidney of alloxan induced diabetic rats. *Journal of Pharmacy and Clinical Sciences.* 4:7-9
- Parker RGF (1959). Occlusion of the hepatic veins in man. *Medicine (Baltimore)*;38:369-402
- Preissel U and Preissel H (2002). *Brugmansia and Datura: Angel's Trumpets and Thorn Apples.* Buffalo, New York: Firefly Books. 120–123. ISBN 1-55209-598-3.
- Proto AV (1996) Lobar collapse: basic concepts. *Eur J Radiol*;23:9-22
- Puja S (2014). Pathology of Alcoholic liver disease, can it be differentiated from non-alcoholic Steatohepatitis. *World J. Gastroenterol.* 2014, 20(44)16474-16479
- Richard F. Keeler, Kent R.V., Lynn F.J. Effects of Poisonous Plants on Livestock. Elsevier, First Edition 25 Sep 1978. Page 278
- Sharma S., Anand G., and Arora T (2011). General Concepts of Drug Induced Liver Injury. *International Journal of Research in Pharmacy and Science* 1 (2), 18-30
- Stuart K and Bras G (1957). Veno-occlusive disease of the liver. *Q J Med*;26:291-314
- Tietz, N. W., *Clinical Guide to Laboratory Tests*, Saunders, Philadelphia, PA1983.
- Vargas FS, Cukier A, Terra-Filho M, Hueb W, Teixeira LR, Light RW (1993). Influence of atelectasis on pulmonary function after coronary artery bypass grafting. *Chest*;104:434-7
- Wannangl NN, Ndukwe HC and Nnabuife C. (2009) Evaluation of the analgesic properties of the *Daturametel* seeds aqueous extract *Journal of Medicinal Plants Research* Vol. 3(4), pp. 1 92-1 95.
- Wedding ME, Gylys BA. *Medical Terminology Systems: A Body Systems Approach.* Philadelphia, 2005 5<sup>th</sup> Edition
- Zuhour Y. Shamseldin and Samia M. A. El Badwi. A Potential Antidotal Effect of *Datura stramonium* Seeds on the Toxicity of Malathion Insecticide in Rats. Annual Conference of Postgraduate Studies and Scientific Research-February. 2014