

*Full Length Research Paper*

# **Patterns of presentation of rotator cuff tendinopathy and the role of abnormal ultrasonography findings in its early detection among overhead sport athletes**

**Aiyegbusi Ayoola I.\*, Odebiyi Daniel O. and Osasona Oluwatosin O.**

Department of Physiotherapy, College of Medicine, University of Lagos, Nigeria.

Received 10 February, 2022; Accepted 28 June, 2023

Rotator cuff tendinopathy (RCT), a common shoulder disorder in overhead sports, has different presentation patterns. The presentation mode may help identify altered biomechanics, a common cause of impingement of the rotator cuff tendon. Therefore, this study investigated the patterns of presentation of RCT and their association with selected biomechanical variables in overhead sport athletes. This cross-sectional study involved 135 (95 males and 40 females) recreational overhead sport athletes between the ages of 19 to 39 years recruited by convenience. RCT was assessed using musculoskeletal ultrasonography and specific clinical tests. Posterior shoulder tightness (PST), pectoralis minor muscle length (PMML) and scapular asymmetry were evaluated. Data were analyzed using mean, frequency, standard deviation, Kruskal-Wallis, ANOVA and Chi-square. Participants designated as the control group had neither clinical symptoms nor abnormal ultrasonography. The patterns of presentation identified among the other participants included clinical symptoms only, abnormal ultrasonography findings only and a combination of both. Compared with the control group, participants with only abnormal ultrasonography showed no significant ( $p > 0.05$ ) differences in biomechanical variables. In contrast, those in the other groups had shoulder tightness and severely compromised PMML (PST:  $p = 0.01$ ) PMML:  $p = 0.01$ ). However, there was no significant ( $p = 0.13$ ) association between scapular asymmetry and RCT in all the groups. Abnormal ultrasonography of the rotator cuff tendon in the absence of clinical symptoms is an early indicator of RCT.

**Key words:** Rotator cuff tendinopathy, pectoralis minor muscle length, shoulder tightness, kinematics, overhead sports.

## **INTRODUCTION**

Recreational sport is an essential aspect of leisure activities that help relieve daily work stress and significantly impacts human physiology and psychology, though participation in these activities is not without the risk of specific musculoskeletal injuries (Wen et al., 2011; Aiyegbusi et al., 2016; Jordan et al., 2018). Rotator cuff

tendinopathy (RCT), a common shoulder problem prevalent among general and athletic populations, is associated with excessive and repeated use of the upper limbs as seen in overhead sport participation (Littlewood et al., 2013; Shamash et al., 2017).

It is characterized by pain and weakness, most

\*Corresponding author. E-mail: [aiyegbusi@unilag.edu.ng](mailto:aiyegbusi@unilag.edu.ng).

commonly experienced with shoulder external rotation and elevation movements because of excessive load on the rotator cuff tissues (Lewis et al., 2015). The definitive cause of RCT has been proposed to include intrinsic and extrinsic mechanisms or a combination of both factors (Lewis et al., 2015). The most implicated intrinsic mechanisms for RCT include anatomic variables such as pectoralis minor muscle (PMM) length, scapular kinematics and humeral kinematic that predispose to impingement, the leading extrinsic cause of RCT (Seitz et al., 2011; Umer et al., 2012; Fabis et al., 2016). Other risk factors for RCT include genetic factors, age, repetitive strain and degenerative changes. A good understanding of this dysfunction's altered biomechanics is essential for preventive measures to be put in place (Goldfarb et al., 2016). For instance, the PMM resting length has been described as a potential contributor to detrimental shoulder kinematics, and clinical assessment of the resting length has been considered valuable for early intervention (Hodgins et al., 2017). Ultrasonography is one of the diagnostic methods for RCT. However, a study by Bradley and Waqas (2015) reported that findings from imaging may not always correlate with clinical symptoms as it is very common to find anatomical changes associated with asymptomatic individuals. The patterns of presentation of RCT vary between abnormal imaging only, clinical symptoms only and a combination of both and may be an indication for early intervention and preventative measures. This study aimed to investigate the patterns of presentation of RCT and their association with abnormal findings of selected kinematic and biomechanical variables in recreational overhead sport athletes in Lagos, Nigeria.

## MATERIALS AND METHODS

This cross-sectional analytical survey involved hundred and thirty-five (135) healthy recreational overhead sport athletes (95 males and 40 females) recruited from three sporting facilities in Lagos, Nigeria. The minimum sample size was calculated to be 96 (Mohamad et al., 2013).

The participants between the ages of 19 and 39 years engaged in Basketball, Volleyball, Cricket and Tennis and were involved in full training and match responsibilities at the time of the study. Individuals with cognitive problems, recent shoulder surgery and prior history of shoulder dislocation were excluded. The participants were recruited by convenience, while the sporting facilities were purposively selected. All the participants were screened for RCT, and the diagnosis was based on clinical tests and ultrasonography findings. Ethical approval was obtained from the institutional Health Research and Ethics Committee, and informed consent was sought and obtained from participants prior to the commencement of the study. A Self-developed report form was used to collect information on the socio-demographics, musculoskeletal clinical tests and biomechanical and kinematic variables.

### Diagnosis and grouping of participants

Participants were recruited by convenience for this study and screened in line with the inclusion criteria.

### Special musculoskeletal clinical tests

The diagnosis of RCT can be based on response to clinical tests. The participants were categorized as symptomatic if any of the two musculoskeletal tests was positive (Lewis, 2010). The clinical tests carried out on each participant included the Empty Can Test and Hawkins' Test, which was carried out by one of the researchers blinded to the athletes' biomechanical measurements and ultrasound imaging results.

### Ultrasonography Imaging

A musculoskeletal ultrasound machine was used to ascertain participants with focal morphological abnormalities at the rotator cuff tendon. The tendons were imaged on a gray scale with an ultrasound machine equipped with a 10-15MHz linear transducer (Siemens Acuson; Siemens Medical Solutions, Inc, Malvern, Pennsylvania). A single musculoskeletal ultra-sonographer, blinded to the athletes' clinical history, performed all imaging in the transverse and longitudinal planes. Results were categorized as normal or abnormal/tendinopathic with hypoechoic regions in both transverse and longitudinal planes (Naredo et al., 2006).

### Grouping of participants

The participants were then separated into four groups according to the pattern of presentation of rotator cuff tendinopathy:

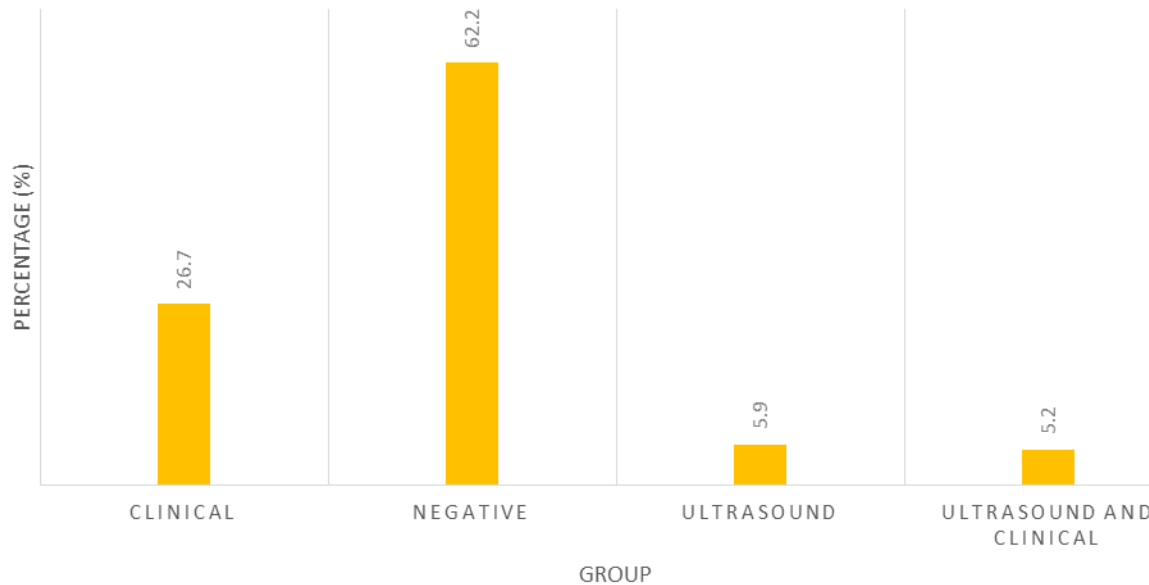
- Group A (Control): Participants without ultrasonography features of tendinopathy and negative to the clinical tests.
- Group B: Participants positive or symptomatic to the clinical tests but showed no ultrasonography features of tendinopathy.
- Group C: Participants with ultrasonography features of tendinopathy but negative or asymptomatic to the clinical tests.
- Group D: Participants with ultrasonographic features of tendinopathy and positive or symptomatic to the clinical tests

### Biomechanical and kinematic evaluation

The posterior shoulder tightness was evaluated according to the protocol of Myers et al. (2013) while the Pectoralis minor length (PML) was measured according to the method of Sahrman et al. (2017). The lateral scapular slide test was used to assess the scapular kinematics, as described by Kibler (1998). The differences between the three test positions was added together to give the sum of the difference. A sum of difference greater than 1.5 cm, indicated an asymmetry in the participant's scapular kinematics.

### Data analysis

IBM Statistical package for social sciences (SPSS Inc., Armonk, New York, USA) 25.0 version for windows package programme was used to analyze all data. Descriptive statistics of frequency, percentages, mean and standard deviation was used. Demographic data were expressed as mean  $\pm$  standard deviation (SD). Kruskal-Wallis test was used to analyze the significant difference between the patterns of occurrence of rotator cuff tendinopathy among the sampled sports. One-Way ANOVA was used to analyze the differences in biomechanical and kinematic variables among the pattern of occurrence of rotator cuff tendinopathy and Chi-square was used to test the association of scapular biomechanics and kinematics with RCT. Level of significance was set at 0.05 ( $p < 0.05$ ).



**Figure 1.** The pattern of presentation of rotator cuff tendinopathy across the groups.  
Source: Author.

## RESULTS

The population of the four overhead sporting activity sampled was Basketball (27.4 %); Volleyball (24.4 %); Cricket (25.2 %) and Tennis (23.0 %) and a non-parametric testing of the prevalence of rotator cuff tendinopathy across the sporting groups with Kruskal Wallis test showed no significant difference among the four participating sports ( $H = 3.91$ ,  $P = 0.27$ ).

Figure 1 presents the pattern of occurrence of rotator cuff and shows that majority of the study participant (62.2%) tested negative to both ultrasound imaging and clinical symptoms while the others were positive to either or both.

Table 1 shows the Socio-demographic characteristics of the participants while Table 2 depicts the differences in the mean posterior shoulder tightness and the pectoralis minor muscle length in the dominant limb of the athletes across all the groups ( $F = 22.92$ ,  $p = 0.01^*$ ;  $F = 12.23$ ,  $p = 0.01^*$ ) respectively. Table 3 shows the post-hoc analysis while Table 4 shows no significant association between scapular symmetry and occurrence of rotator cuff tendinopathy among the athletes across the groups ( $X^2 = 2.54$ ,  $p\text{-value} = 0.13$ ).

## DISCUSSION

The aim of this study was to determine the association between the patterns of presentation of RCT and abnormal biomechanical and kinematic variables of the shoulder. Three patterns of presentation of RCT were observed in this study. Group B (the presence of clinical symptoms only) and Group C (positive ultrasonography

features only) are consistent with the results of a study by Bradley and Waqas (2015) who reported that findings from imaging may not always correlate with clinical symptoms and that it is very common to find anatomical changes in the tendon of asymptomatic individuals. A third group (Group D) comprised participants with both clinical symptoms and abnormal ultrasonographic features underscores the importance of the diagnostic criteria proposed by Docking et al. (2015) that suggested the use of both diagnostic criteria.

Studies have attempted to identify specific biomechanical and kinematic variables that may predispose to RCT through impingement of the rotator cuff tendon. This is important, as a better understanding of these intrinsic disposition of an individual to RCT will facilitate the identification of modifiable risk factors and make valuable contributions to planning of preventative measures and interventions. Also, addressing any abnormality in these intrinsic factors is an important step in the successful rehabilitation of RCT.

Our findings showed a significant ( $p = 0.01$ ) difference in the mean value of the posterior shoulder tightness of the dominant limb across all the groups with the tightness being most pronounced in the symptomatic groups (B and D).

This confirms a recent study by Hall and Borstad (2018) who reported that posterior shoulder tightness is often observed in individuals with shoulder pain. Furthermore, our findings also demonstrated a significant difference ( $p = 0.01$ ) in mean values of pectoralis minor muscle length in the dominant limb across the groups which could be attributed to adaptive shortening of the pectoralis minor muscle as a result of repetitive use of the upper extremity for activities that protract and rotate the

**Table 1.** Socio-demographic data of the participants.

Variable		Frequency (n)	Percent
Gender	Male	95	70.4
	Female	40	29.6
Age (years)	15-19	1	0.7
	20-24	8	13.3
	25-29	60	44.4
	30-34	49	36.3
	35-39	7	5.2
Occupation	Student	25	18.5
	Artisan	8	5.9
	Civil servants	20	14.8
	Professional	26	19.3
	Businessman/woman	29	21.5
	Unemployed	27	20.0
Type of overhead sport	Basketball	37	27.4
	Cricket	34	25.2
	Tennis	31	23.0
	Volleyball	33	24.4
Length of participation	< 6 months	1	0.7
	6 months -3 years	69	51.3
	3-6 years	61	45.2
	>6 years	4	3.0
Duration of play per week (hours)	0-2	1	0.7
	2-5	42	31.1
	5-10	63	46.7
	10-15	20	14.8
	15-20	7	5.2
	20-25	2	1.5

Source: Author.

**Table 2.** Differences in the posterior shoulder tightness and pectoralis minor muscle length across the groups.

Variable/group	Posterior shoulder tightness		Pectoralis minor muscle length	
	Dominant limb	Non-dominant limb	Dominant limb	Non-dominant limb
	$\bar{x} \pm SD$	$\bar{x} \pm SD$	$\bar{x} \pm SD$	$\bar{x} \pm SD$
Group A	110.80±4.84	110.94±4.96	9.96±1.67	10.03±1.63
Group B	104.65±5.16	111.28±5.00	8.34±1.06	10.14±0.78
Group C	110.59±4.02	110.65±3.98	9.81±0.75	9.89±0.71
Group D	99.03±4.69	107.29±3.75	8.17±1.00	9.83±1.00
F	22.92	1.355	12.23	0.15
P-value	0.01	0.26	0.01	0.93

\*Significant at 0.05, Group A: Neither clinical symptoms nor ultrasound features, Group B: Presence of Clinical symptoms only, Group C: Ultrasonography features only, Group D: Both clinical symptoms and Ultrasonography feature, DL: Dominant limb, NDL: Non-dominant limb.

Source: Author.

**Table 3.** Post-Hoc analysis of the posterior shoulder tightness and pectoralis minor muscle length using the least significant difference (lsd) across the groups.

Variable	Group status (i)	Group status (j)	Mean difference (df) (i-j)	p-value
<b>Posterior shoulder tightness</b>				
Group A		Group B	6.15	0.01*
		Group C	0.21	0.907
		Group D	11.77	0.00*
Group B		Group A	-6.15	0.00*
		Group C	-5.93	0.00*
		Group D	5.62	0.00*
Group C		Group A	-0.21	0.90
		Group B	5.93	0.00*
		Group D	11.56	0.00*
Group D		Group A	-11.77	0.00*
		Group B	-5.62	0.00*
		Group C	-11.56	0.00*
<b>Pectoralis minor muscle length</b>				
Group A		Group B	1.62	0.00*
		Group C	0.14	0.79
		Group D	1.79	0.00*
Group B		Group A	-1.62	0.00*
		Group C	-1.48	0.01*
		Group D	0.16	0.79
Group C		Group A	0.14	0.79
		Group B	1.48	0.01*
		Group D	1.64	0.03*
Group D		Group A	-1.79	0.00*
		Group B	-0.16	0.79
		Group C	-1.64	0.03*

\*Significant at 0.05, Group A: Neither clinical symptoms nor ultrasound features, Group B: Presence of Clinical symptoms only, Group C: Ultrasonography features only, Group D: Both clinical symptoms and Ultrasonography feature.

Source: Author.

**Table 4.** Association between rotator cuff tendinopathy and scapular symmetry in recreational overhead sport athletes.

Variable	Frequency (n)	Percentage	$\chi^2$	p
<b>Symmetrical</b>				
No	111	92.5		
Yes	12	80.0		
<b>Asymmetrical</b>				
No	9	7.5		
Yes	3	20.0	2.57	0.11

Source: Author.

scapula downwards as seen in overhead athletes (Borstad, 2006; Hodgins et al., 2017).

It is pertinent to note that compared with the control group, the group with abnormal Ultrasound imaging only,

had normal posterior shoulder motion and PMM length even with the obvious degenerative changes as depicted by the ultrasonography findings. This underscores the need to ensure that athletes with abnormal Ultrasound imaging go through preventive interventions as prophylaxis against the biomechanical changes in the structures around the shoulder joint even when they do not present with symptoms. Abnormal ultrasonography findings may give an early indication of RCT, therefore, a person with abnormal imaging findings even without clinical symptoms must be taken through preventative protocol to prevent the biomechanical changes seen in symptomatic individuals. It was also observed that the participants with clinical symptoms had significantly compromised biomechanical variables as seen in the shoulder tightness and reduced PMM length. This suggests that a person with clinical symptoms of RCT already has biomechanical alterations, underscoring the need for routine ultrasonography imaging for early intervention.

Conversely, there was no significant association between scapular symmetry and rotator cuff tendinopathy in these study participants. This result is inconsistent with previous studies as it has been documented that the PMM adaptively shortens in individuals with repetitive upper limb motion, resulting in scapular kinematic alterations associated with shoulder impingement syndrome, the main cause of RCT (Hodgins et al., 2017). It has however been reported that some degree of scapular asymmetry may be normal in some athletes and should not be considered a pathological sign but rather an adaptation to sports practice and extensive use of the upper limb. This assertion has been linked with racial/genetic factors (Andrea and Pascoa, 2013) and may explain why scapular asymmetry had no significant impact on RCT in our study population as most prior studies had been carried out among Caucasians and not Africans.

## Conclusion

The results of this study suggest that abnormal Ultrasonography of the rotator cuff tendon in the absence of clinical symptoms is an early indicator of rotator cuff tendinopathy among recreational overhead sport athletes.

Thus, routine Ultrasonography of the rotator cuff tendon should be incorporated into the screening of overhead sport athletes and interventions targeted at preventing biomechanical abnormalities be adopted.

This study was carried out on recreational athletes, we thus recommend that further studies involving professional/elite overhead sport athletes be considered.

## CONFLICT OF INTERESTS

The author has not declared any conflict of interests.

## REFERENCES

- Aiyegbusi AI, Okafor UA, Leke OP (2016). Prevalence of Achilles tendinopathy and its association with physical characteristics in recreational sport participants in Lagos, Nigeria. *Journal of Clinical Sciences* 13(4):163-166.
- Andrea R, Pascoal AG (2013). Resting scapular posture in healthy overhead throwing athletes. *Manual Therapy* 18(6):547-550
- Borstad JD (2006). Resting position variables at the shoulder: evidence to support a posture-impairment association. *Journal of Orthopaedic and Sports Physical Therapy* 86(4):549-557.
- Bradley B, Waqas A (2015). Imaging of Tendinopathy: A Physician's Perspective. *Journal of Orthopaedics and Sports Physical Therapy* 45(11):826-828.
- Docking S, Chin C, Connell D (2015). Tendinopathy: Is Imaging Telling Us the Entire Story? *Journal of Orthopaedics and Sports Physical Therapy* 45(11):842-852.
- Fabis J, Rzepka R, Fabis A (2016). Shoulder proprioception – lessons we learned from idiopathic frozen shoulder. *Biomed Central Musculoskeletal Disorders* 17:123.
- Goldfarb CA, Puri SK, Carlson MG (2016). Diagnosis, Treatment, and Return to Play for Four Common Sports Injuries of the Hand and Wrist. *Journal of American Academy of Orthopedic Surgery* 24(12):853-862.
- Hall K, Borstad JD (2018). Posterior Shoulder Tightness: To Treat or Not to Treat? *Journal of Orthopaedics and Sports Physical Therapy* 48(3):133-136.
- Hodgins J, Rubenstein W, Kovacevic D (2017). Pectoralis Minor Contracture in Throwing Shoulders of Asymptomatic Adolescent Baseball Players. *Orthopedic Journal of Sports Medicine* 5(9):2325967117728041. <https://doi.org/10.1177/2325967117728041>
- Jordan S, Brian D, Peter P (2018). Identifying high risk loading conditions for in-season injury in elite Australian football players. *Journal of Science and Medicine in Sport* 21(1):46-51.
- Kibler WB (1998). The role of the scapula in athletic shoulder function. *American Journal of Sports Medicine* 26(2):325-337.
- Lewis J, McCreesh K, Roy JS et al (2015). Rotator Cuff Tendinopathy: Navigating the Diagnosis-Management Conundrum. *Journal of Orthopaedic and Sports Physical Therapy* 45(11):923-937.
- Lewis JS (2010). Rotator cuff tendinopathy: a model for the continuum of pathology and related management. *British Journal of Sports Medicine* 44(13):918-923. doi:10.1136/bjism.2008.054817
- Littlewood C, Malliaras P, Mawson S (2013). Development of a self-managed loaded exercise programme for rotator cuff tendinopathy. *Physiotherapy* 99(4):358-362.
- Mohamad A, Mohsen V, Mitra R (2013). Sample size calculation in medical studies. *Gastroenterology and Hepatology from Bed to Bench* 6(1):14-17.
- Myers JB, Oyama S, Hibberd EE (2013). Scapular dysfunction in high school baseball players sustaining throwing-related upper extremity injury: a prospective study. *Journal of Shoulder and Elbow Surgery* 22(9):1154-1159.
- Naredo E, Moller I, Moragues CI (2006). Interobserver reliability in musculoskeletal ultrasonography: Results from a teach the teachers Rheumatologist course. *Annals of Rheumatology Disease* 65:14-19.
- Seitz AL, McClure PW, Finucane S (2011). Third Michener LA Mechanisms of rotator cuff tendinopathy: intrinsic, extrinsic, or both. *Journal of Clinical Biomechanics (Bristol, Avon)* 26(1):1-12.
- Shamash K, Kelby B, William J (2017). Rotator Cuff Tendinopathy: An Evidence-Based Overview for the Sports Medicine Professional. *Strength and Conditioning Journal* 40(4):61-71.
- Shirley Sahrman, Daniel C. Azevedo, and Linda Van Dillen (2017). Diagnosis and treatment of movement impairment syndromes. *Brazilian Journal of Physical Therapy* 21(6):391-399.
- Umer M, Qadir I, Azam M (2012). Subacromial impingement syndrome. *Orthopedic Reviews* 4(2):18.
- Wen C, Wai J, Tsai M (2011). Minimum amount of physical activity for reduce mortality and extended life expectancy: A prospective cohort study. *The Lancet* 6736:1-10.