

Full Length Research Paper

Toxicological effects of silver nanoparticles in rats

**Roshan Rezaee Ranjbar Sardari¹, Saeid Rezaei Zarchi², Alireza Talebi³, Sima Nasri⁴,
Saber Imani^{5*}, Arezoo Khoradmehr⁶ and Seyed Alireza Razavi Sheshde⁷**

¹Department of Biology, Payame Noor University, Yazd, Iran.

²Department of Biology, Payame Noor University, Taft, Iran.

³Research and Clinical Center for Infertility, Shahid Sadughi University of Medical Sciences, Yazd, Iran.

⁴Department of Biology, Payame Noor University, Tehran, Iran.

⁵Chemical Injuries Research Center, Baqiyatallah University of Medical Sciences, Tehran, Iran.

⁶Research and Clinical Center for Infertility, Yazd University, Iran.

⁷Department of Animal Science, College of Animal Science and Fisheries, Sari Agriculture and Natural Resources University, Sari, Iran.

Accepted 9 November, 2011

Toxicity of nanoparticles depends on chemical composition, atomic arrangement and particle size. Silver is being widely used in consumer medical products, due to its uniqueness such as antimicrobial activity. In this study, we assessed the toxic effects of size-silver nanoparticles 70 nanometer in rat's living tissues, with different doses such as 0.25, 0.5, 1 and 2 mg/kg body weight on kidney, liver and spleen tissues via oral gavage for 30 days. Adverse impacts on liver, spleen and kidney were observed in a high dose-treated group (1 and 2 mg/kg), when determined by histopathological analysis. Pathological examination showed tissue damages, bloodshed, cell necrosis and apoptosis from all rat in high dose group compared to control group. Based on these results, it is suggested that the effect of nanosilver particles on the tissues may cause organ toxicity in rats.

Key words: Silver, nanoparticle, kidney, liver, spleen, toxicity, rat.

INTRODUCTION

Nanotechnology deals with structures sized of 1 to 100 nanometer. Nanoparticle has been shown to be comparatively over toxic than other sizes. In addition, different size and shape silver nanoparticles have different toxicities (Hillyer and Albrecht, 2001). Health effects of nanoparticles are attracting considerable and increasing worldwide recognition. Nanoparticles can be ingested directly via water, food, cosmetics, drugs, drug delivery devices, etc (Oberdo, 1990). Uptake of particles of different size via the gastrointestinal tract can also lead to different toxicological effects (Bockmann et al., 2000). But reports about the toxicological research of nanoparticles by the gastrointestinal tract are few. Nano-sized silver particles are one of the manufactured

nanomaterials and are now industrially produced and available commercially. Recently, silver and its nanoparticles are widely being applied to consumer products and medical uses (Edwards-Jones, 2009). Some medical and biological reports have proved that, many medical devices release silver ions into the blood and its accumulate in the liver and kidney which cause liver and kidney toxicity that lead to death ultimately (Park and Bae, 2010). So, it is presumed that the silver nanoparticles must have the same toxicity, but the mechanism of their cytotoxicity is not clear (Tang, 2008). According to the experiments done with a variety of metal nanoparticles, silver nanoparticles have shown more toxicity than other metals such as iron, nickel, manganese and aluminum (Braydich-Stolle et al., 2005). The production and usage of these materials in different industries lead to the necessity and importance of this research, thus investigation of harmful effects of these substances is an essential and urgent matter (Chen and

*Corresponding author. E-mail: imani.saber@yahoo.com. Tel: +989126407588. Fax: +982177104955.

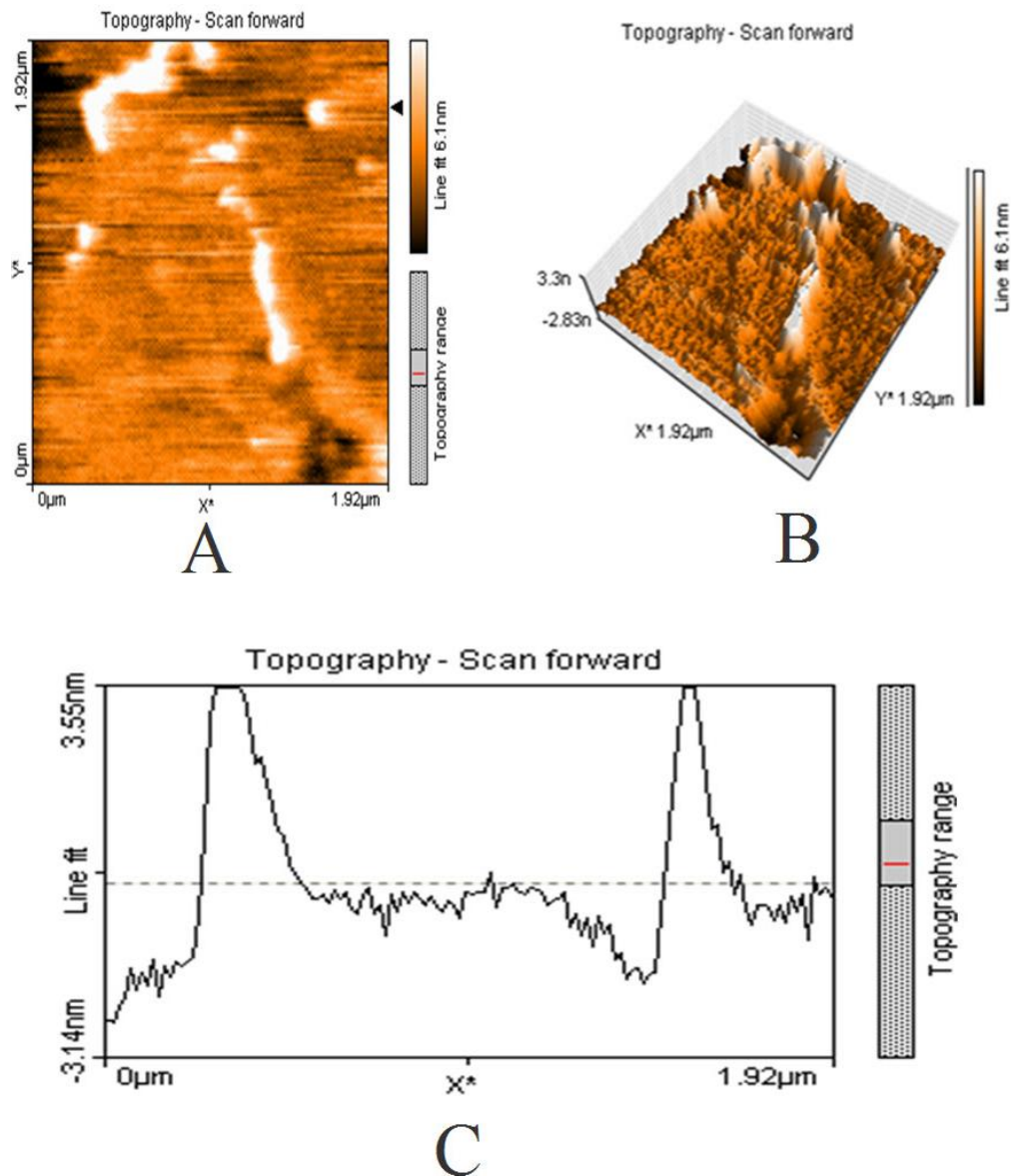


Figure 1. 70 nm Silver nano-particles used in this experiment by AFM microscope; **A** two-dimensional image; **B** three-dimensional image; **C** chart height and surface nano-silver.

Schluesener, 2008). In this study, four different silver nanoparticles doses were prepared, and repeated-dose toxicity was evaluated after oral administration in rat.

MATERIALS AND METHODS

Preparation for analysis

The synthesized silver nanoparticles 70 nm, were prepared by the Institute of Nano Science and Technology Payam Noor University, Yazd, Iran agnps (Cat. No. D-12486 plasmachem gmbh, Berlin) was suspended with sonication in de-ionized water. The size distribution was analyzed by microscope AFM (Figure 1). The average size of agnps prepared by AFM was 70 nanometer.

Animals

50 male adult Wistar rats (age 8 weeks, weight 250 to 200 g) were used in this research there were purchased from Shahid Sadoughi University of Medical Sciences, Yazd, Iran. The rats were divided to five groups (10 rats per group) with each group named as N1, 2, 3, 4 and 5. Group N1, was called control group and was given sodium chloride solution and the other four groups, N2 to 5 were called experimental groups. All groups were kept on controlled conditions of $22 \pm 1^\circ\text{C}$ temperature, $60\% \pm 10$ humidity, 12 h light and darkness, and 12 h free access to water and food [all the animals used in this study were cared for in accordance with the principles outlined in the "Guide for the Care and Use of Laboratory Animals" issued by the Animal Care Committee of National Veterinary Research and Quarantine Service (NVRQS)]. Suspension of silver nanoparticles was fed to rat (1ml every day) by gavage for 30 days,

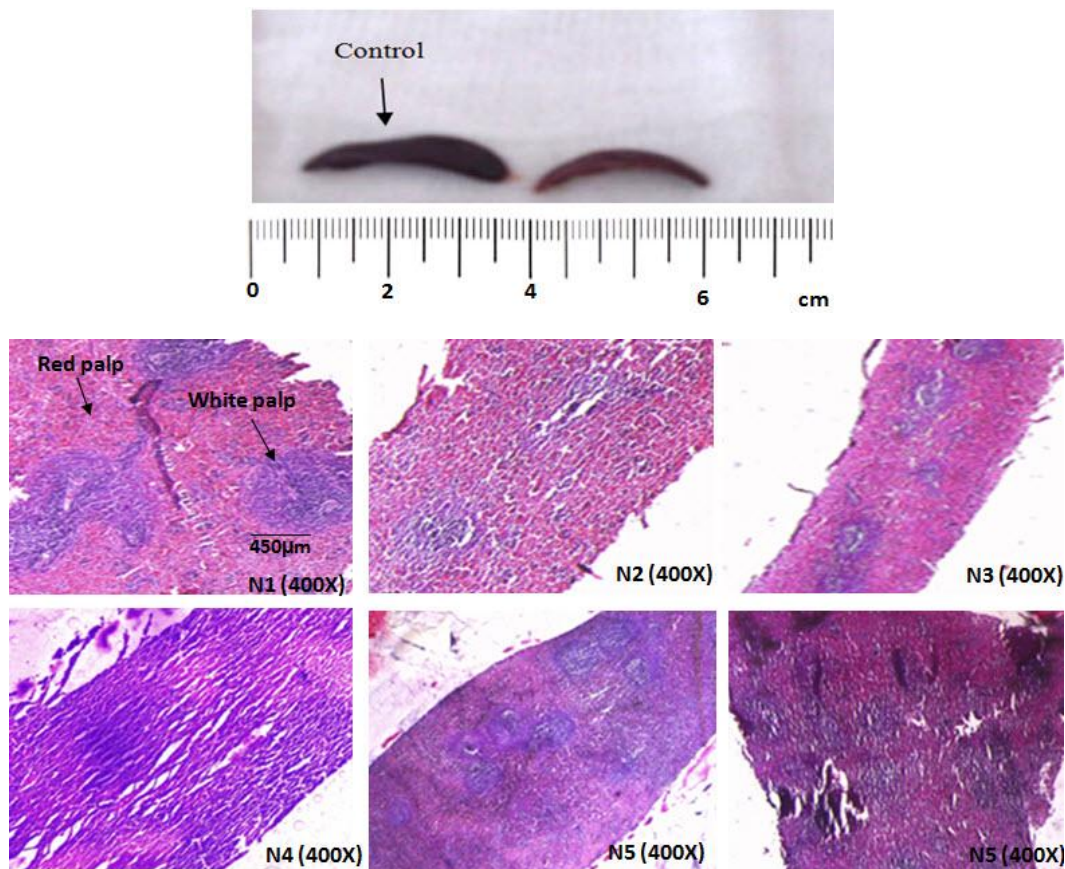


Figure 2. Morphological and pathological changes in rat's spleen.

with different doses such as 0.25, 0.5, 1 and 2 mg/kg.

After 30 days the rats were anesthetized by ether and were dissected. Kidney, liver and spleen were separated carefully and washed with sodium chloride solution and then their morphology was investigated. After that they were put in 10% buffered formalin to be fixed and kept for histopathological experiments. Tissue samples were processed by tissue processing device from Research and Clinical Center of infertility in Yazd, Iran, and they were prepared with paraffin blocks. After paraffin embedding, 5 micrometer sections were cut and stained with hematoxylin and eosin (H and E) for histopathologic evaluation. Injuries were examined microscopically by invert microscope for evidence of cellular damages.

RESULTS

Morphological changes in rat

There were morphological changes in the rats which were exposed to nanoparticles (2 mg/kg dose); it showed significant changes in hair color (tan color). Figures 2, 3 and 4 respectively, show morphological changes in spleen, kidney and liver of the experimental rat groups that were treated with silver nanoparticles when compared to the control group. Silver nanoparticles (70 nm) caused spleen color changes and atrophy in rat in

groups N5 (Figure 2). The result showed that spleen damages increased in higher doses in experimental animals. To examine explicitly the grade of changes caused by the silver nanoparticles, spleen index (S_x) was defined as:

$$S_x = \frac{\text{weight of experimental spleen/weight of the experimental animal}}{\text{weight of control spleen/weight of the control animal}}$$

The average value of S_x , in experimental rat groups, is 0.78 ± 0.19 , closed to 1.00 ± 0.20 , the normal parameter obtained from the control group. The appearance of the kidney and liver in the control group was the same (Figure 4), but that of the experimental group exhibited dramatic changes in color and became bronze colored. This shows that the spleen is one of the target organs for silver nanoparticles. The other organs did not show macroscopic changes.

Pathological changes in rats

It was observed that spleen cell was decreasing (red pulp), while lymphocytes was increasing (white pulp) and

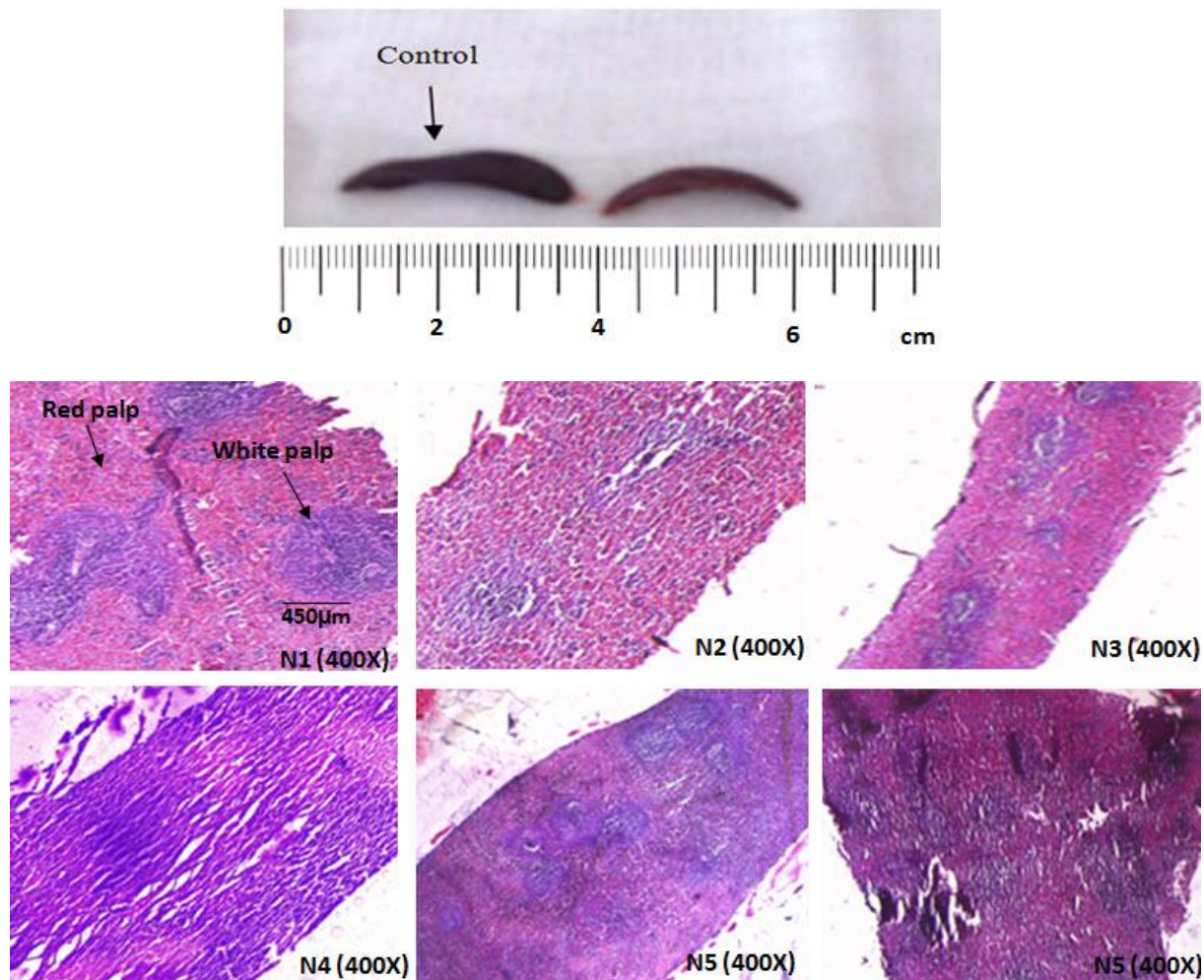


Figure 2. Morphological and pathological changes in rat's spleen.

bleeding (Figure 2). The pathological results showed damages in kidney's tissue, including necrosis of glomerular cells, bowman capsule and proximal tubular in group N4 and N5 (Figure 3). Proteinic sediment was seen in renal tubules, whereas inflammation of the parenchymal cells was observed in the liver, and nuclear duplication of some cells and intercellular space enlargement were observed in the hepatic lobule. More so, apoptosis around the central vein and blood between some cells were also observed (Figure 4).

DISCUSSION

In this study, we tried to identify the adverse effects of silver nanoparticles using rats treated with oral administration. In addition, we tried to investigate the effects of toxicity, in the different doses of silver nanoparticles. Nanoparticles induced damage tissues, shows an explicit dose-dependent trend, that is, the higher dose of

nanoparticles showed severer damages to the spleen, liver and kidney tissues of the experimental rats. There are different ways nanoparticles gain entrance into the body; such as respiratory, oral and intravenous, their toxic effects due to their small size have been discussed (Edwards-Jones, 2009; Nel et al. 2006). In the experiments carried out with three different sizes of nanoparticles orally on rats, it was observed that after dissection and tissue investigation of the control and receiving groups with 323 nm size, there was no difference in the liver, kidney and spleen tissues. While in two other sizes, smaller than 22 and 71nm nanosilver, absorption was mostly observed in their gastrointestinal system (Park and Bae, 2010). In previous study, it was reported that when mice were repeatedly exposed for 28 days to oral administration of 30, 300 and 1,000 mg/kg dose of silver nanoparticles (60 nm) in carboxymethyl cellulose, the silver nanoparticles did not induce any significant changes in body weight. The accumulation in tissues was dose-dependent, but genetic toxicity related

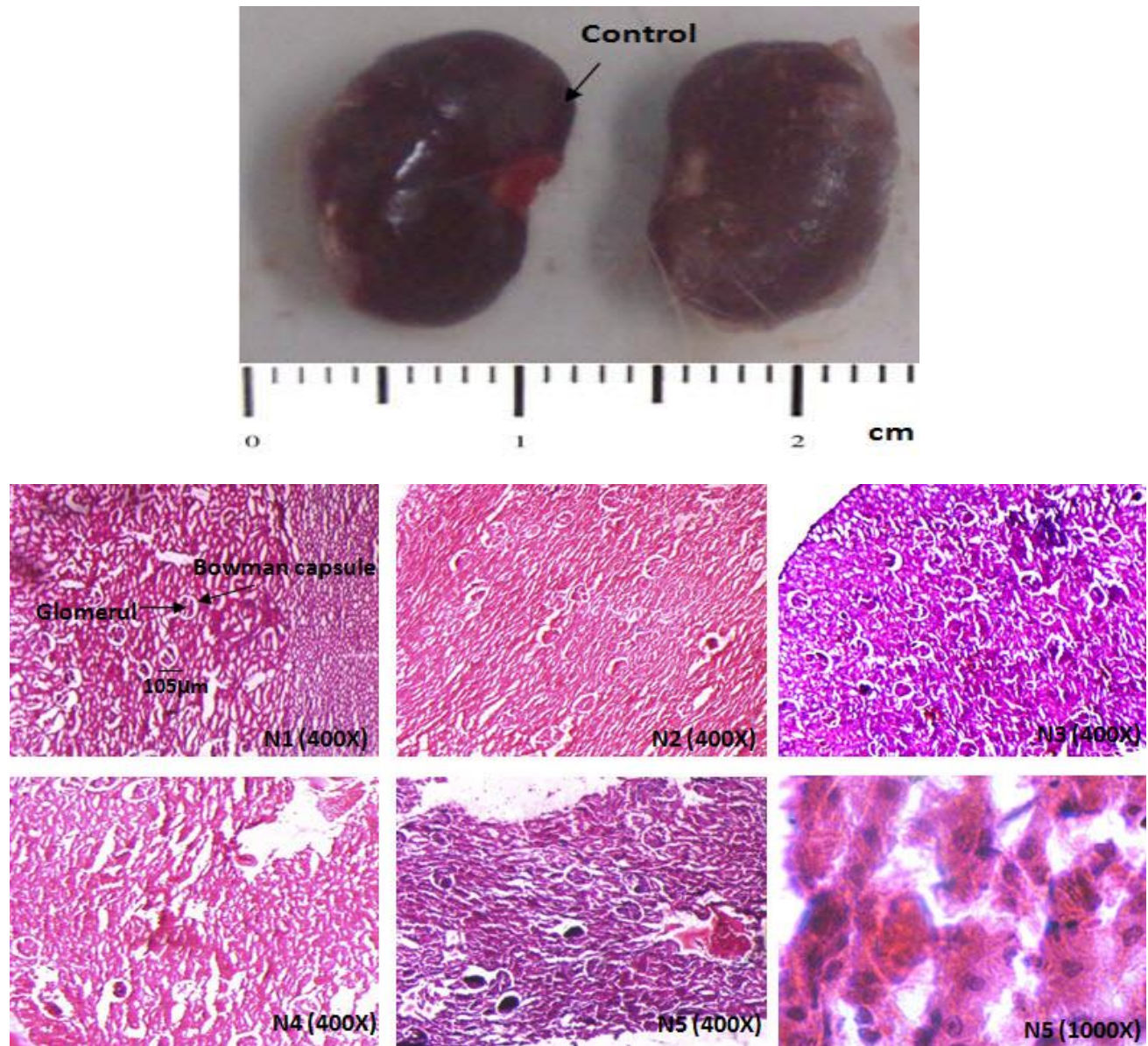


Figure 3. Morphological and pathological changes in rat's kidney.

reactions were not shown in all groups (Kim et al., 2009). Other researchers administered bare silver nanoparticles (42 nm) in distilled water with doses of 0.25 mg/kg, 0.5 mg/kg, and 1 mg/kg. These results mean that bare silver nanoparticles may induce hepatotoxicity by repeated oral administration. Nanoparticles are removed from the liver by macrophages due to phagocytosis process, repetition of this process produced a higher oxygen radicals. The increasing of oxidants was caused by lyses cell membrane and organ dysfunction. In this study, we reported that glomerular necrosis and proximal tubular of kidney were in high dose. Glomerular diseases are due to immunological damages, but tubules damages are mostly due to infectious agents and toxins. On the other hand,

associated anatomical of these structures, causes the damage of a part leading to disruption of the other parts (Hendi, 2010). In this experiment, the tubular damage caused by the toxic effects of silver nanoparticles increased glomerular pressure and causes glomerular atrophy. Hussain, (2005) reported that silver nanoparticles were highly toxic in rat's liver cells. Silver nanoparticles reduced the activity of mitochondria which results in reduction of available energy for cells (Chen and Schluesener, 2008; Hussain, 2005). Moreover, some researchers reported that silver and silver salts are distributed to the whole body and finally accumulate in the liver, kidney and spleen. The researchers showed that, silver cause the permeability of cell membrane to

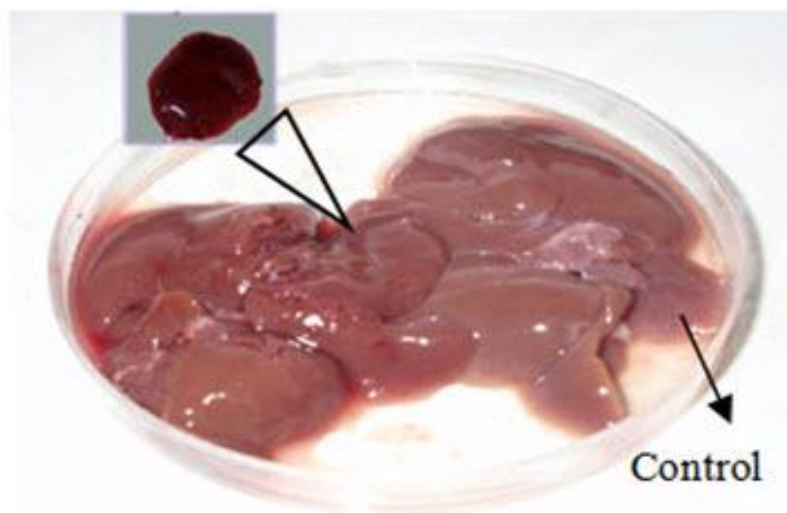


Figure 4. Morphological and pathological changes in rat's liver.

potassium and sodium, and disrupt the activity of Na-K-ATPase and mitochondria (Oberdo, 1990; Lam, 2006). Sheng et al. (2008) reported that silver nanoparticles cause liver and kidney toxicity, and a high dose leads to death (Sheng et al., 2008). In the present study, silver nanoparticles also cause histopathological changes in the liver, spleen and kidneys; which indicated the tendency of silver ions to binding thiol groups in livers, causing reduction reactions, transferring of glutathione to bile bladder and reducing the concentration of glutathione available for biochemical reduction reactions. It should be mentioned that reducing glutathione is necessary to

remove peroxides (Hendi, 2010; Campen, 2003). So, different kinds of nanoparticles can be toxic in human and animal tissues (Miura and Shinohara, 2009; Choi et al., 2009). We hope with more researches (in relation with toxicity in silver nanoparticles and various doses) shapes and size effects of silver consumption on body tissues will be cleared.

Conclusion

The aim of this study was to evaluate the potential toxicity

and the general mechanism in nanosilver toxicity. The effects of nanosilver on tissues which were investigated in significant and analytical experiments showed the damages in the tissues. These damages were caused by the increase of free radicals and stimulation of oxidative stress; however, more immunological and genetical investigations will clear the biological effects of nanoparticles.

ACKNOWLEDGEMENTS

This work was supported by the Institute of Nano Science and Technology, Payam Noor University and The Research and Clinical Center of Infertility of Yazd, Iran.

REFERENCES

- Bockmann J, Lahl H, Eckert TH, Unterhalt B (2000). Titan-Blutspiegel vor und nach Belastungsversuchen mit Titandioxid. *Pharmazie* 55: 140–143.
- Braydich-Stolle L, Hussain S, Schläger JJ, Hofmann MC (2005). In vitro cytotoxicity of nanoparticles in mammalian germline stem cells. *Toxicol. Sci.*, 88: 412-9.
- Campen MJ, McDonald JD, Gigliotti AP, Seilkop SK, Reed MD, Benson JM (2003). Cardiovascular effects of inhaled diesel exhaust in spontaneously hypertensive-rate. *Cardiovas. Toxicol.*, 3: 353-361.
- Chen X, Schluesener HJ (2008). Nanosilver: a nanoparticle in medical application. *Toxicol. Lett.* 176(1): 1–12.
- Choi JE, Kim S, Ahn JH, Youn P, Kang JS, Park K, Yi J, Ryu DY (2009). Induction of oxidative stress and apoptosis by silver nanoparticles in the liver of adult zebrafish. *Aquat. Toxicol.*, Epub. ahead of print (PMID): 20060176.
- Edwards-Jones V (2009). The benefits of silver in hygiene, personal care and healthcare. *Lett. Appl. Microbiol.* 49(2): 147–152
- Hendi A (2010). Silver nanoparticles mediate differential responses in some of liver and kidney functions during skin wound healing. *J. King Saud Univ - Sci.*, S1018-3647(10)00071-6.
- Hillyer JF, Albrecht RM (2001). Gastrointestinal persorption and tissue distribution of differently sized colloidal gold nanoparticles. *J. Pharm. Sci.* 90: 1927–36
- Hussain SM (2005). *In vitro* toxicity of nanoparticles in BRL 3A rat liver cells.19: 975-83.
- Kim WY, Kim J, Park JD, Ryu HY, Yu IJ (2009). Histological study of gender differences in accumulation of silver nanoparticles in kidneys of Fischer 344 rats. *J. Toxicol. Environ. Health A*, 72(21–22): 1279–84.
- Lam CW (2006). A review of carbon nanotube toxicity and assessment of potential occupational and environmental health risk. *Crit. Rev. Toxicol.*, 36: 189-217.
- Miura N, Shinohara Y (2009). Cytotoxic effect and apoptosis induction by silver nanoparticles in hela cells. *Biochem. Biophys. Res. Commun.* 390(3): 733–737.
- Nel A, Xia T, Mädler L, Li N (2006). Toxic potential of materials at the nanolevel. *Science*, 311: 622-627.
- Oberdo Rster G (1990). Increased pulmonary toxicity of ultrafine particles Lung lavage studies. *J. Aerosol Sci.*, 21: 384-387
- Park E, Bae E (2010). Repeated-dose toxicity and inflammatory responses in mice by oral administration of silver nanoparticles. *Environ. Toxicol. Pharm.* 30: 162–168.
- Sheng Wu Yi XG, Cheng X, Za Z (2008). Status of biological evaluation on silver nanoparticles. *Beijing University of Sci. Technol.*, 25: 958-961.
- Tang J (2008). Status of biological evaluation on silver nanoparticles.25: 958-61.