

Full Length Research Paper

# The effects of albendazole and povidone iodine for hydatid cysts protoscoleces, *in-vitro* and *-vivo*

Erdal Polat<sup>1</sup>, Mustafa Aslan<sup>1</sup>, Huseyin Cakan<sup>2</sup>, Suat Saribas<sup>1</sup>, Turgut Ipek<sup>3</sup> and Bekir Kocazeybek<sup>1\*</sup>

<sup>1</sup>Microbiology and Clinical Microbiology Department, Cerrahpasa Faculty of Medicine, Istanbul University, Turkey.

<sup>2</sup>Institute of Forensic Sciences, Istanbul University, Turkey.

<sup>3</sup>General Surgery Department, Cerrahpasa Faculty of Medicine, Istanbul University, Turkey.

Accepted 28 September, 2009

The aim of using chemotherapy for inactivating protoscoleces is to prevent dissemination. The most suitable way to apply chemotherapy is to inject killing substances directly to the hydatid cysts protoscoleces. We performed our experiments with 95% live hydatid cyst protoscoleces. In *in-vivo* experiments, in survey group mice, no hydatid cyst was observed in the first and second group which 1 g/L and 100 µg/ml albendazole was added to their waters, respectively and in the third group, 1/10 povidone-iodine was added for 30 min during the 6 months. All of the above groups were given 4 - 6 live hydatid cyst protoscoleces. However, hydatid cysts were developed in the control group mice in the 87th day. In *in-vitro* studies; all of the hydatid cysts pre-treated with 1/10 povidone-iodine and 100 µg/ml albendazole lost their viability after 15 min and the viability of the hydatid cysts, which were kept at room temperature were not lost.

**Key words:** Cystic echinococcosis, protoscoleces, povidone-iodine, albendazole.

## INTRODUCTION

Parasitic diseases are still a serious public health problem for developing countries. It affects animals and humans and is very important from the aspect of health and economy. According to the Turkey Health Minister, 40,242 patients with cystic echinococcosis (CE) were operated on between 1975 - 1994 and 909 (2.3%) of them died. Another retrospective study showed that 14,789 patients with CE were operated on in different hospitals of Turkey between 2001 - 2005 and 171 (1.2%) of them died. Case/population ratio of CE is 1/15.850 (6.3/100 000) (Yazar et al., 2008). Case/population ratios of CE are 197/100 000, 143/100 000, 220/100 000 and 13/100 000 for China, Argentina, Kenya and Greece, respectively (Amman and Eckert, 1996; Gottstein, 1992).

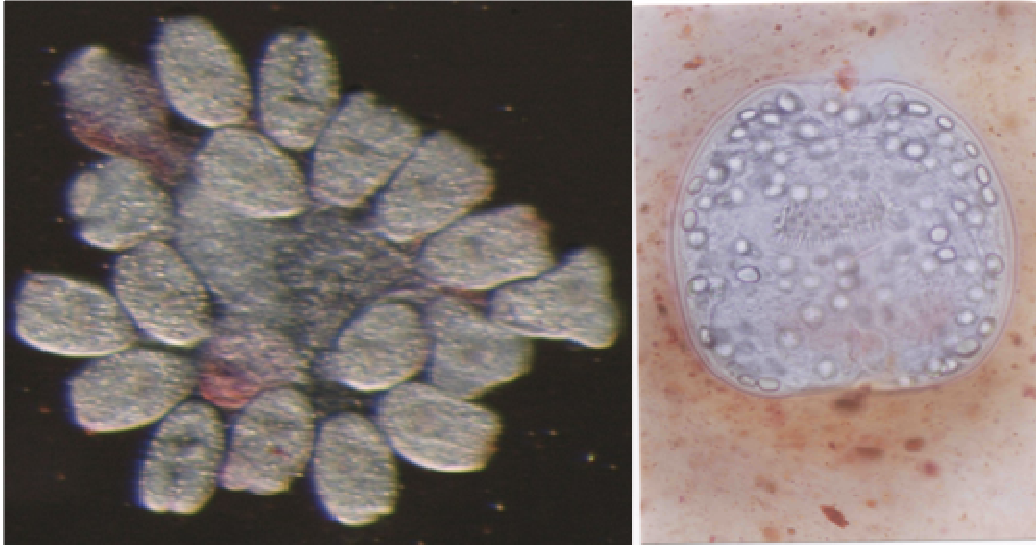
Conventional surgery is used for the treatment. Open surgery has high mortality and morbidity. However,

surgery has risk factors like long-stay hospitalization, high dissemination, recurrence, infection, biliary fistula development and to exclude all above risk factors, new alternative therapy methods are under investigation. Albendazole is used successfully for the treatment of CE and other helminthiasis. As a vermifuge, albendazole causes degenerative alterations in the tegument and intestinal cells of the worm by binding to the colchicine-sensitive site of tubulin, thus inhibiting its polymerization or assembly into microtubules and inhibits the cell proliferation in metaphase stage (Yuksel, 2001).

Injecting scolicedal solutions into the hydatid cyst and packing the operative field with sponges soaked in scolicedal agents have been used to avoid dissemination of the parasite during surgery. However, there is no consensus for the concentrations and exposure times of the various agents. Ideal scolicedal solution has to be fast and has effective anti-parasitic effect with no side effects and also be cost effective (Altindis, 2004.).

In this study, we aimed to investigate the effects of albendazole and povidone iodine for the hydatid cysts protoscoleces, *in-vitro* and *-vivo*.

\*Corresponding author. E-mail: [bzeybek@istanbul.edu.tr](mailto:bzeybek@istanbul.edu.tr), [suatsaribas@yahoo.com](mailto:suatsaribas@yahoo.com). Tel: 00-90-532-6168150. Fax: 00-90-212-6322122.



**Figure 1.** Protoscoleces are not stained with eosin.

## MATERIALS AND METHODS

Cyst fluid of an operated patient with CE was used for experiments. It was obtained from liver of the patient and was transferred to a 50 ml falcon tube and hydatid sand was recovered after 25 - 30 min by standing in a vertical position at room temperature. One drop of this hydatid sand was placed on a slide and added one or two drop of 0.1% eosine and visualized by a stereo microscope ( $6.3 \times 10$ ). The viability of protoscoleces was calculated per microscopic area.

The four groups, each of them includes 10 mice (Balb/c) were organized for *in-vivo* studies.

### Group 1

4 - 6 protoscoleces were injected to the peritoneum of each mice and albendazole was added to tap water of the mice.

### Group 2

Hydatid cyst protoscoleces were pre-treated with 100  $\mu\text{g/ml}$  albendazole in a tube for 30 min and 4 - 6 pre-treated protoscoleces were injected to the peritoneum of each mouse.

### Group 3

Protoscoleces were pre-treated with 1/10 povidone-iodine in a tube for 30 min and 4 - 6 pre-treated protoscoleces were injected to the peritoneum of each mouse.

All of the 3 groups described herein were screened for 6 months and peritoneum of the died mice were investigated.

### Group 4

4 - 6 protoscoleces were injected to the mice control group and screened for 3 months and peritoneum of the died mice were investigated.

Two groups were organized for *in-vitro* studies.

### Group 1

Protoscoleces were pre-treated with 1/10 povidone-iodine in a tube. One drop was taken from the tube in 5, 10, 15, 20, 25 and 30 min and stained with 0.1% eosin. The viability of the protoscoleces was investigated by a stereo microscope ( $6.3 \times 10$ ).

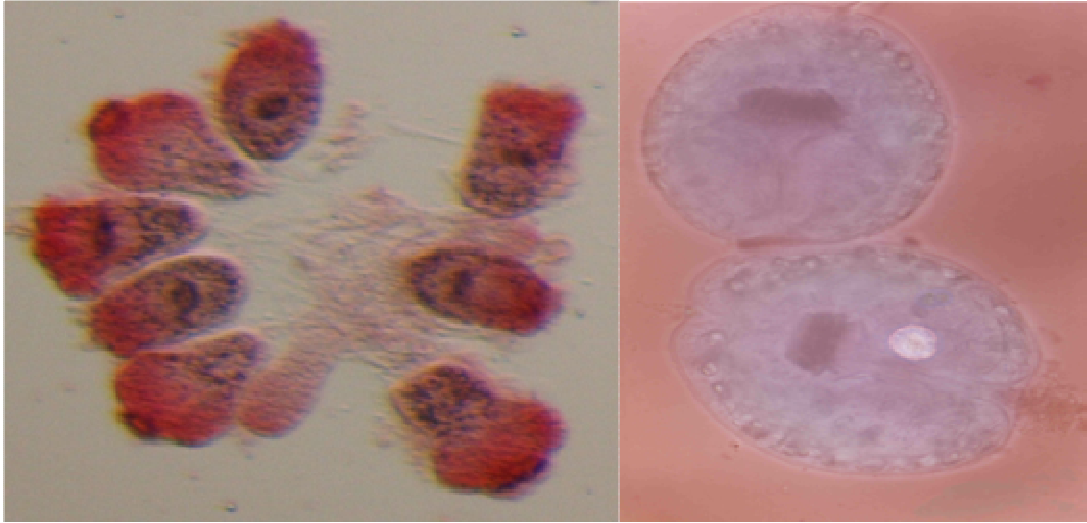
### Group 2

Protoscoleces were pre-treated with 100  $\mu\text{g/ml}$  albendazole in a tube. One drop was taken from the tube in 5th, 10th, 15th, 20th, 25th and 30th minutes and stained with 0.1% eosin. The viability of the protoscoleces was investigated by a stereo microscope ( $6.3 \times 10$ ). Cyst fluid containing protoscoleces was stayed at room temperature and the viability of protoscoleces was controlled in short periods.

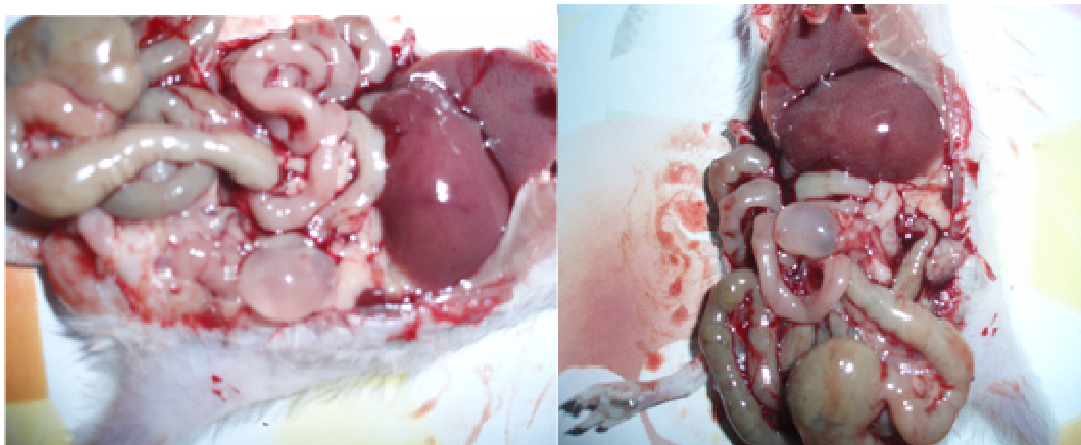
Completely stained protoscoleces with 0.1% eosin were accepted as dead and unstained protoscoleces were accepted as alive.

## RESULTS

The viability of protoscoleces was detected as 95% (Figure 1). Two of the mice in control group died in the first week of the *in-vivo* experiment. The other 4 control group mice were developed cyst hydatid in the 87th day of the experiment (Figure 3). Two of the second group and 4 of the third group died in the 3 - 4 months of the experiment (*in-vivo* groups) but no hydatid cyst were detected in any of the dead mice. No hydatid cysts were detected also in none of the other three groups of mice after six months (*in-vivo* group). In *in-vitro* studies with 1/10 povidone-iodine, 40, 75 and 100% of the protoscoleces lost their viability after 5th, 12th and 15th min, respectively. On the other hand in *in-vitro* studies with 100  $\mu\text{g/ml}$  albendazole, 30, 67 and 100% of the protoscoleces lost their viability after 5, 12 and 15 min respectively; and all of the



**Figure 2.** Protoscoleces are stained with eosin.



**Figure 3.** Developed hydatid cysts in mice peritoneum.

min, respectively; and all of the protoscoleces were stained with 0.1% eosin (Figure 2).

## DISCUSSION

Cystic echinococcosis is still an important health problem in Turkey regarding to the unauthorized eradication programs, excess of ownerless dogs, slaughter of animals in inconvenient conditions, insufficient education for the population of CE. Open surgery operations used for the patients diagnosed with liver CE in the past. Nowadays, percutaneous drainage methods are used as an alternative to open surgery. Rupture of a hydatid cyst may happen spontaneously or traumatic. Rupture may also happen during percutaneous drainage or surgery. Multiple cysts can be formed in the peritoneal cavity during the intraperitoneal rupture. Abdomen distention and intestinal

obstruction may also be developed during rupture of a hydatid cyst. Episodic leakage from a hydatid cyst may produce fever, pruritis, urticaria, eosinophilia, or fatal anaphylaxis (Cosme and Oriv, 1987).

Primer treatment of cystic hydatid disease is surgery but benzimidazoles and derivatives (albendazole, mebendazole) are in use for the inoperable and cases with multiple cyst since 1980. Their effects are due to their metabolites. Their metabolites reach a definite serum concentration and passes to the hydatid fluid. Mebendazole disrupts microtubules of hydatid cysts and albendazole inhibits the glucose uptake. Finally, cysts die. Albendazole, mebendazole and benzimidazole disrupt microtubules of hydatid cysts and stop the cell proliferation in the metaphase phase.

In circumstances that the patients need to take drugs; if the patient's clinical condition is not suitable for an operation, the localization of the cyst is not convenient for

an operation, if the cyst was ruptured during surgery, if multiple cysts were present, re-formation of a cyst after a surgery operation and to kill the cysts after a surgery operation and also to ameliorate the surgery (Kalayci, 2002).

The killing effect of povidone-iodine is dependent on its concentration for hydatid cystprotoscoleces. The staining property of povidone-iodine makes difficult to distinguish the cyst-biliary relation but it has effective impact to inhibit the development of secondary cysts (Gokce et al., 1991).

In our study, we detected that the interaction with 100 µg/ml albendazole and 1/10 povidone-iodine killed the hydatid protoscoleces after 15 min in *in-vitro*. We observed hydatid cysts only in peritoneum of 4 control group mice after 87 days. No hydatid cyst was observed in the first group which 1 g/l albendazole was added to their waters and second group which was pre-treated with 100 µg/ml albendazole and the third group which was pre-treated with 1/10 povidone-iodine for 30 min. All of the groups were screened during the 6 months.

As a result, we concluded that albendazole and povidone-iodine are effective for the killing of hydatid protoscoleces and inhibit hydatid cyst development. Primary method of the hydatid cyst treatment is currently surgery, but in circumstances like the localization of the cyst, complications due to cyst rupture during the surgery, the patients has to take chemotherapy. Cysts have to be operated after being ineffective by chemotherapy. We also

advise to apply chemotherapy in order to prevent dissemination after surgery.

## REFERENCES

- Altındis M, Arikan Y, Cetinkaya Z, Polat C, Yilmaz S, Akbulut G, Dilek ON, Gokce O (2004). Octenidine hydrochloride in hydatid disease. *J. Invest. Surg.*, 17: 41-44.
- Amman RW, Eckert J (1996). *Echinococcus*. *Gastroenterol. Clin. North Am.*, 25: 655-689.
- Cosme A, Orive V, Ojeda E, Aramburu V, Irazusta M, Arenas JI (1987). Hydatid cyst of the head of the pancreas with spontaneous fistula to the deudenum. *Am. J. Gastroenterol.*, 82: 1311-1313.
- Gokce O, Gokce C, Yilmaz M, Huseyinoglu K, Gunel S (1991). Povidone-iodine in experimental peritoneal hydatidosis. *Br. Surg.*, 78: 495-496.
- Gottstein B (1992). Molecular and immunological diagnosis of *Echinococcus*. *Clin. Microbiol. Rev.*, 5: 248-261.
- Kalayci G (2002). *General Surgery*. Nobel Medical Publisher, 2: 1103-1109.
- Yazar S, Ozkan AT, Hokelek M, Polat E, Yilmaz H, Ozbilge H, Ustun S, Koltas IS, Ertek M, Sakru N, Alver O, Cetinkaya Z, Koc Z, Demirci M, Aktas H, Parsak CK, Ozerdem D, Sakman G, Engiz ZT, Ozer A, Keklik K, Yemenici N, Turan M, Dastan A, Kaya E, Tamer GS, Girginkardesler N, Turk M, Sinirtas M, Evci C, Kilicturgay S, Mutlu F, T Parazitol, Aris T (2008). Cystic Echinococcosis. *Derg.*, 32: 208-220.
- Yüksel M, Kalayci G (2001). Surgical treatment of Alveolar hydatid cyst. (Eds. Yüksel M and Kalaycı G) *Göğüs Cerrahisi*. İstanbul: Bilmedya grup. pp. 647-658.