

Full Length Research Paper

Comparative effect on liver fibrosis of bicyclol and silymarin

Liping Wang^{1,2}, Li Zhang^{2,3}, Kelan Gan¹, Xiaoping Hua², Ying Xiao², Yikun Shi² and Zhenghuai Tan^{2*}

¹Department of Pharmacy, Chengdu Jinjiang Hospital for Women and Children Health, Chengdu, Sichuan, 610021, China.

²Institute of Traditional Chinese Medicine Pharmacology and Toxicology, Sichuan Academy of Chinese Medicine Sciences, Chengdu, Sichuan, 610041, China.

³Department of Pharmacy, College of Veterinary Medicine, Sichuan Agriculture University, Chengdu, Sichuan, 611130, China.

Received 16 October, 2019; Accepted 17 December, 2019

Bicyclol and silymarin are widely used in the treatment of various liver diseases; however, there is no report on comparative effect of them on liver fibrosis. To compare their liver protective effect, liver fibrosis rats induced by bile duct ligation (BDL) were orally treated with 100 mg/kg bicyclol and 100 mg/kg silymarin respectively for 4 weeks. Liver index, liver function activities, inflammatory biomarkers, fibrotic biomarkers and liver histopathology were assessed. BDL induced marked histopathological changes in liver tissues coupled with changes in serum biochemistry. Furthermore, hepatic content of hydroxyproline, transforming growth factor-beta1 (TGF- β 1), and interleukin-6 (IL-6) were elevated, together with a reduction of interleukin-1 alpha (IL-1 α) and interleukin-4 (IL-4) in the liver. In addition, BDL increased the expression of alpha-smooth muscle actin (α -SMA). Treatment with bicyclol or silymarin protected against BDL induced liver fibrosis, as proved by the alleviation of inflammatory and fibrotic biomarkers. Overall, our results indicated that the effect of bicyclol was better than that of silymarin.

Key words: Liver fibrosis, bile duct ligation, bicyclol, silymarin, comparative effect.

INTRODUCTION

Several chronic inflammatory diseases, such as viral hepatitis, alcoholic and primary biliary cirrhosis, might result in liver fibrosis. This pathology is characterized by excessive deposition of extracellular matrix (ECM) components in response to acute chronic liver injury.

Accumulation of ECM proteins distort the hepatic architecture by the formation of a fibrous scar, nodules of regenerating hepatocytes and pathologic angiogenesis, ultimately leads to cirrhosis (Gulamhusein and Hirschfield, 2019; Schutte et al., 2013). Nowadays, liver

*Corresponding author. E-mail: tanzhh616@163.com.

Author(s) agree that this article remain permanently open access under the terms of the [Creative Commons Attribution License 4.0 International License](https://creativecommons.org/licenses/by/4.0/)

fibrosis is an urgent problem with high morbidity and mortality (Almpanis et al., 2016; Altamirano-Barrera et al., 2017). And due to the complicated molecular pathogenesis, the effective systemic therapy is relatively limited (Saber et al., 2018). Recent studies revealed that development of liver fibrosis is a dynamic process that can be modulated by arresting progression and/or promoting resolution (Trautwein et al., 2015).

Silymarin, a milk thistle extract, contains three bioactive chemicals: silychristine, silybin, and silydianin, which are among the famous herbal agents used to treat liver diseases with low toxicity (Polyak et al., 2013; Shaker et al., 2010). It has been previously shown to be capable of protecting the liver against hepatotoxicity induced by carbon tetrachloride (Salam et al., 2009), ethanol (Zhang et al., 2013), thioacetamide (Ghosh et al., 2016), arsenic (Jain et al., 2011; Muthumani and Prabu, 2012), cisplatin (Abdelmeguid et al., 2010), acetaminophen (Avizeh et al., 2010) and *Schistosoma mansoni* (Clichici et al., 2016; El-Lakkany et al., 2012).

Bicyclol (4,4'-dimethoxy-2,3,2',3'-dimethylene-dioxy-6-hydroxymethyl-6'-carbonyl-biphenyl) is a novel anti-hepatitis drug widely used in the clinic to treat patients with chronic hepatitis B and C (Chi et al., 2019; Liu, 2009; Xie et al., 2012) which was synthesized by Chinese scientists (Figure 1) (Li et al., 2001). Furthermore, bicyclol exhibits a protective effect against liver injury induced by hepatotoxins in mice and rats. Recent studies demonstrated that bicyclol markedly improved experimental liver fibrosis induced by carbon tetrachloride (Gu et al., 2010), dimethyl nitrosamine (Hu and Liu, 2006), chemotherapeutic agent (Li et al., 2014) and bile duct ligation (Zhen et al., 2015).

Even though an incredible number of publications related to silymarin and bicyclol reversing liver fibrosis was produced, the comparative study of silymarin and bicyclol on liver fibrosis has not been reported. This study aimed to compare the efficacy of bicyclol and silymarin as anti-fibrotic drug in an animal model of BDL-induced liver fibrosis by assessing organ index, liver function activities, inflammatory biomarkers, fibrotic biomarkers and liver histopathology.

METHODOLOGY

Reagents

Bicyclol was purchased from Beijing Union Pharmaceutical Company (China). Silymarin was obtained from Madaus GmbH (Germany). α -SMA antibody was purchased from Wuhan Boster Biological Engineering Co., Ltd. (China). ALT, AST, ALB, TP, ALP, GGT, TBIL, and DBIL assay kits were purchased from Sichuan Maker Biotechnology Co. Ltd. (China). The hydroxyproline assay kit was obtained from Nanjing Jiancheng Bioengineering Institute (China). BCA protein assay kit was purchased from TianGen Biotech Co., Ltd. (China). TGF- β 1 assay kits were purchased from R&D Systems (USA). Lastly, IL-1 α , IL-6, and IL-4 MILLIPLEX[®]MAP

Rat Cytokine/Chemokine Magnetic Bead Panel was purchased from Millipore (USA).

Animals

8-week-old female Sprague Dawley (SD) rats were provided by Experimental Animals Center of Sichuan Academy of Chinese Medicine Sciences (Chengdu, China). All animal experiments were performed in accordance with the national standard of the Laboratory Animal-Requirements of Environment and Housing Facilities (GB 14925-2001) and the Sichuan Academy of Chinese Medicine Sciences Institutional Animal Care and Use Committee.

BDL procedure and drug administration

All of the surgical procedures were performed under aseptic conditions. Rats were randomly divided into control group and ligated group, anesthetized with 50 mg/kg pentobarbital intraperitoneally. Controls underwent a sham operation. Ligated groups were shaved and prepped by scrubbing the surgical area skin with alternating exposure to povidone-iodine and 70% ethanol. These surgeries involved a midline laparotomy (approximately 15 mm), followed by ligation of the bile duct with a silk thread at two positions to close the wounds. After 5 days, the BDL rats were divided randomly into three groups (BDL, BDL-Bicyclol and BDL-Silymarin group). To test the effect of bicyclol (100 mg/kg) and silymarin (100 mg/kg) on BDL-induced liver fibrosis respectively, oral administration was performed for 4 weeks. The BDL and sham operated group were orally administrated saline for 4 weeks too. At the end of the experiment, liver and spleen tissues were collected under general. The serum was collected for biochemistry assays.

Body weight and liver index

At indicated time points, 0 week (pre-administration) and 1 week, 2 week, 3 week, 4 week (post-administration), body weight of rats were measured. Thereafter, liver was collected and weighed. Organ index was calculated by the following formula:

$$\text{Organ index} = \frac{\text{Organ weight}}{\text{Body weight}} \times 100\%$$

Determination of liver function activities

Serum direct bilirubin (DBIL), total bilirubin (TBIL), albumin (ALB), globulin (GLB), total protein (TP) and the activities of the liver-associated enzymes alanine aminotransferase (ALT), aspartate aminotransferase (AST), alkaline phosphatase (ALP), gamma glutamyl transpeptidase (GGT) were estimated with an automatic biochemical analyzer (HITACHI 7020, Japan).

Determination of inflammatory biomarkers

Homogenate of liver was used for estimation IL-10, IL-6, and IL-4, which were determined using MILLIPLEX[®]MAP Rat Cytokine/Chemokine Magnetic Bead Panel according to Luminex 200 (Millipore, USA).

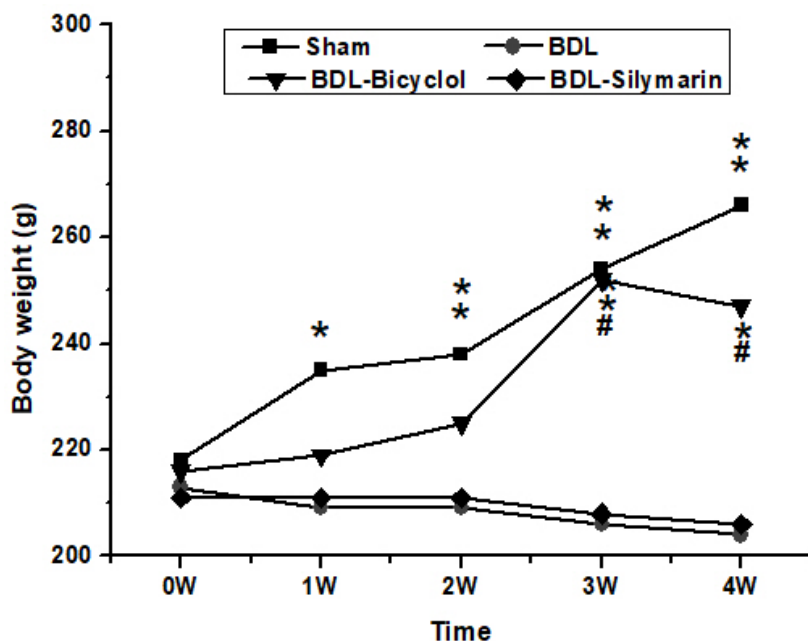


Figure 1. Effect of bicyclol and silymarin on body weight in the BDL rats. Values are expressed as the mean \pm SD (n=9); *P<0.05 and **P<0.01 versus BDL rats. The significance between silymarin and bicyclol treatment was represented by #P<0.05.

Determination of fibrotic biomarkers

Homogenate of liver was used for estimation of TGF- β 1 and hydroxyproline using ELISA reagent kits, according to the manufacture's guidelines.

Immunohistochemistry (IHC) process of α -SMA is as follows: paraffin sections of 4% paraformaldehyde fixed liver samples were rehydrated and subjected to antigen retrieval in 10 mM sodium citrate buffer (pH 6.0). The sections were then incubated with 10% goat serum at room temperature for 30 min, followed by anti- α -SMA (1:40 dilution) antibody at 4°C overnight. Next day, sections were incubated with the secondary antibodies for 10 min and color developed with DAB. Sections were then dehydrated and closure.

Histological examination

The liver paraffin sections (4 μ m thick) from the right lobe of the liver were routinely processed for hematoxylin-eosin (H&E) and Masson's trichrome staining following standard protocols. The liver fibrosis stage was assessed by METAVIR scoring system (F0, no fibrosis; F1, portal fibrosis without septa; F2, portal fibrosis with rare septa; F3, numerous septa without cirrhosis; F4, liver cirrhosis) (French METAVIR Cooperative Study Group, and P. Bedossa, 1994).

Statistical analysis

The statistical analysis of data was performed using analysis of variance (ANOVA) by using the SPSS 15.0 software (SPSS Inc., Chicago, USA). The results were expressed as mean \pm standard deviation. A difference with p of < 0.05 was considered statistically

significant.

RESULTS

Changes of body weight and liver index in BDL rats

Following drug administration, BDL-Silymarin rats exhibited a little higher body weight than BDL rats from 1 to 4 week. Compared with both BDL and BDL-Silymarin rats, the body weight in the BDL-Bicyclol rats were always higher and from 3 to 4 week they were significantly increased (Figure 1). After 4 weeks, the liver index of the BDL rats significantly increased, reaching 185.7% of that in the sham control and it was antagonized by treatment with silymarin or bicyclol to 71.2 and 61.3%, respectively (Figure 2).

Effect of silymarin and bicyclol on liver function in BDL rats

Liver function was impaired severely in BDL rats after 4 weeks. Specifically, the serum levels of ALT, AST, ALP, GGT, TBIL, and DBIL were increased significantly, whereas the level of ALB and the albumin to globulin ratio (A/G) was decreased significantly in BDL rats compared with sham control. Treatment with bicyclol could

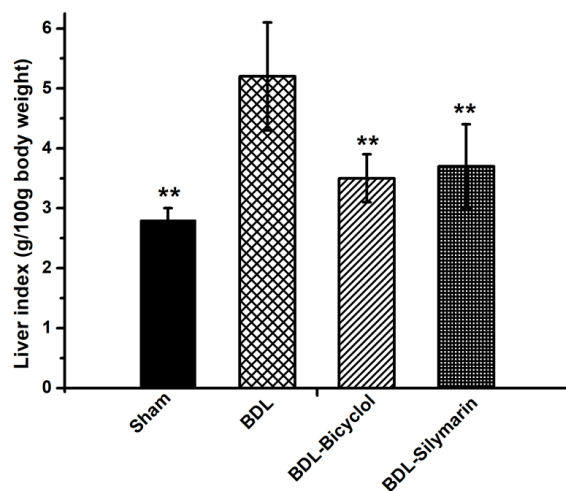


Figure 2. Effect of bicyclol and silymarin on liver index in the BDL rats. Values are expressed as the mean \pm SD (n=9); *P<0.05 and **P<0.01 versus BDL rats.

significantly reduce the levels of ALP, ALT, AST, GGT, TBIL and DBIL to 25.7%, 16.6%, 20.8%, 0.73%, 1.04% and 0.94%, respectively, and increase the levels of ALB, reaching to 113% as compared with BDL rats. Although silymarin also significantly reduced the levels of GGT, ALP, TBIL, and DBIL and increased the levels of ALB, the effect is not as good as bicyclol, moreover, it had no effect on ALT and AST activity (Figure 3).

Effect of silymarin and bicyclol on inflammatory biomarkers in BDL rats

Four weeks after BDL, the liver content of IL-6 was increased markedly to 142.9%, accompanied with a reduction in liver IL-1 α and IL-4 content to 66.1 and 66.7% of that in the sham control. The oral administration of bicyclol reduced IL-6 content to 65.7%, and increased IL- α and IL-4 to 133.3 and 150.0% respectively, as compared with BDL rats. The administration of silymarin also could reduce the content of IL-6 and increase IL- α and IL-4 in liver to a certain degree, but there is no significant difference as compared with BDL rats (Figure 4).

Effect of silymarin and bicyclol on fibrotic biomarkers in BDL rats

BDL rats showed a significant elevation in liver content of TGF- β 1 and hydroxyproline to 179.3 and 179.8% as compared with sham control. The oral administration of 100 mg/kg bicyclol or 100 mg/kg silymarin markedly decreased the content of TGF- β 1 and hydroxyproline to

53.8 and 63.5%, and 62.1 and 63.0%, respectively, in comparison with BDL model control (Figure 5).

The activation of HSC plays an important role in liver fibrosis. α -SMA can be used to identify and quantify activated HSCs in liver fibrosis. The expression of α -SMA in liver samples was analyzed using immunohistochemistry, and the number of α -SMA-positive cells was counted. α -SMA-immunopositive cells were absent in the sham control. For BDL rats, intensely stained α -SMA-positive HSCs associated with bridging fibrotic septa were present (Figure 6). The treatment of 100 mg/kg silymarin decreased the number of α -SMA-positive cells significantly, while rats treated with 100 mg/kg bicyclol had staining pattern almost similar to sham control animals.

Bicyclol and silymarin alleviate BDL-induced structural changes in liver

Liver fibrosis was evaluated in rats by two histological methods, H&E and Masson's trichrome stain. The H&E histological analysis of the livers harvested from sham control indicated a normal liver lobular architecture with central vein and radiating hepatic cords, without any proliferation of connective tissue. Liver specimens from BDL rats showed severe changes in morphology, including necrosis, obvious collagen deposition, formation of pseudoblobules, and infiltration of inflammatory cells in liver interstitial areas, which appeared in the form of portal-portal fibrous strands and replaced the normal hepatic lobulation. The one treated with silymarin showed more or less normal hepatic architecture. This is consistent with the result reported by Mansour et al.

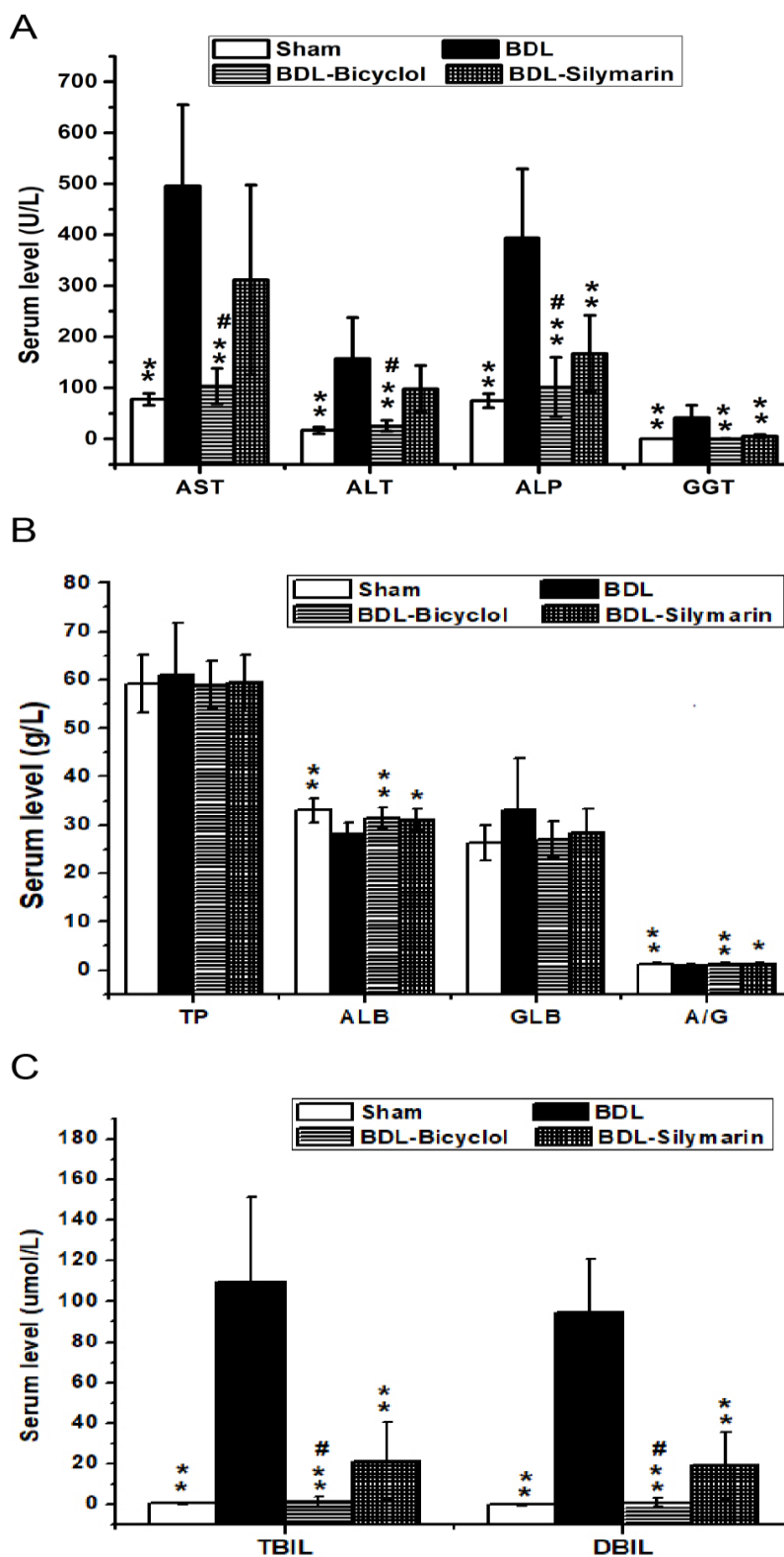


Figure 3. Effect of bicyclol and silymarin on (A) AST, ALT, ALP and GGT, (B) ALB, GLB, TP and A/G (C) TBIL and DBIL. Values are expressed as the mean \pm SD (n=9); *P<0.05 and **P<0.01 versus BDL rats; the significance between Silymarin and Bicyclol treatment was represented by #P<0.05.

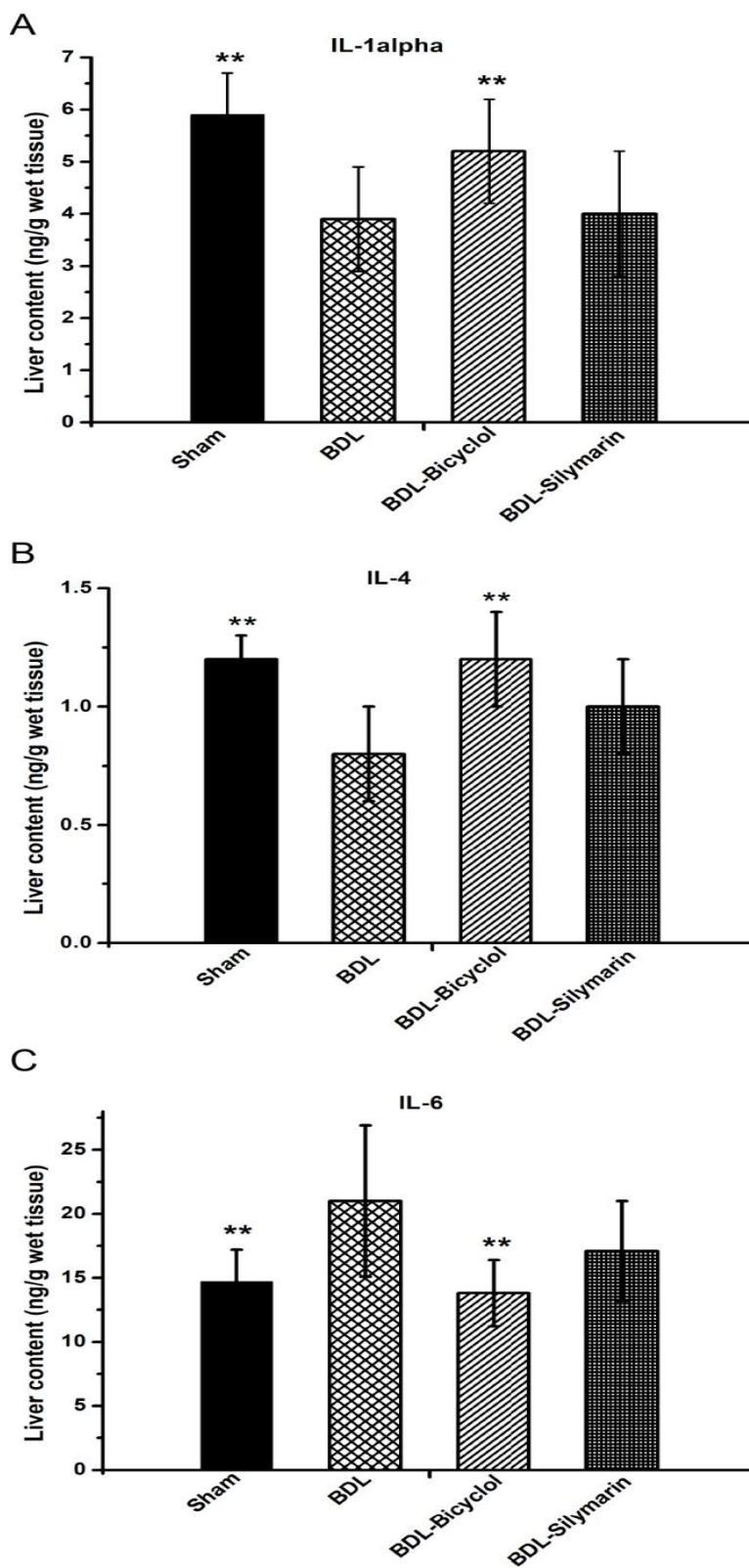


Figure 4. Effect of bicyclol and silymarin on IL-1 alpha (A), IL-4 (B) and IL-6 (C). Values are expressed as the mean \pm SD (n=9); *P<0.05 and **P<0.01 versus BDL rats.

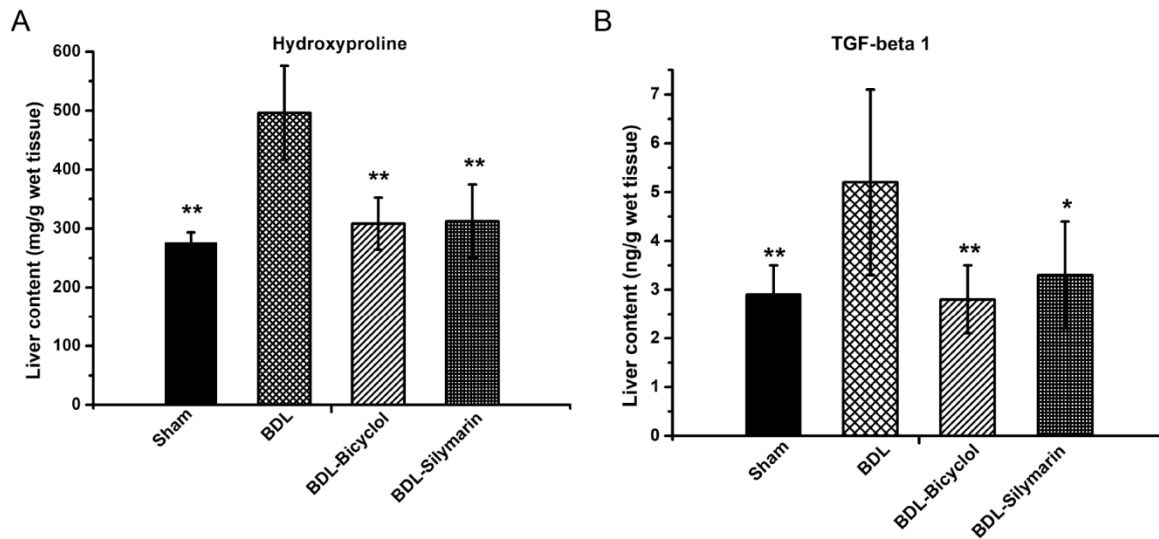


Figure 5. Effect of bicyclol and silymarin on Hydroxyproline (A), TGF-β1 (B). Values are expressed as the mean ± SD (n=9); **P<0.01 versus BDL rats.

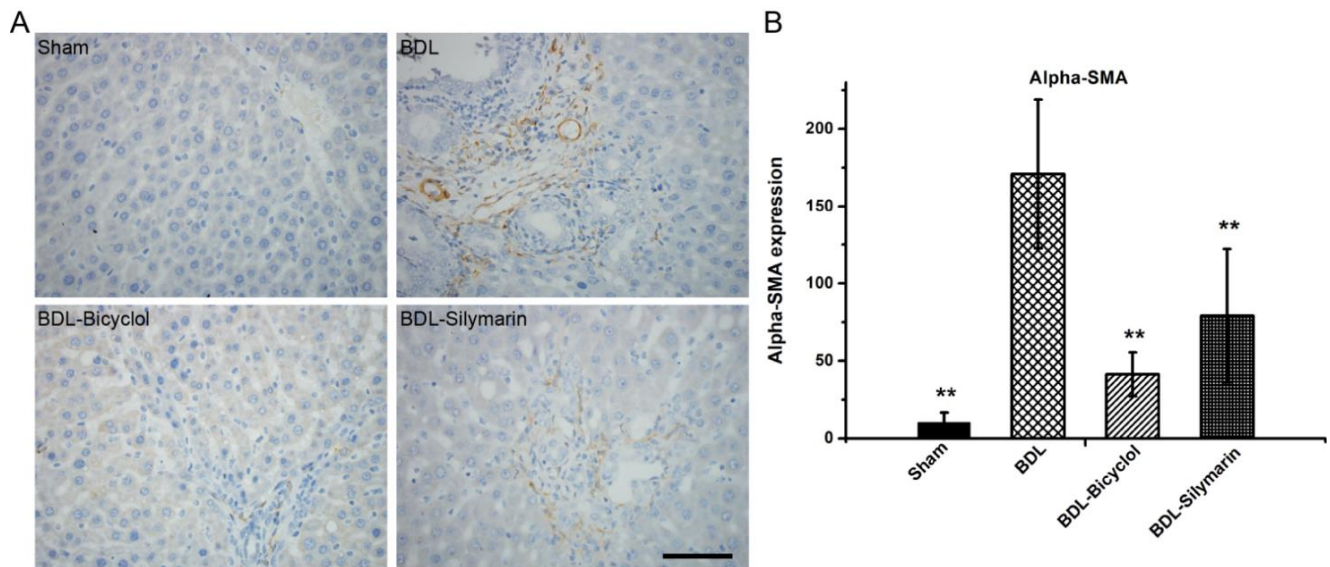


Figure 6. Immunohistochemical expression of α-SMA in BDL rats. A photomicrography of liver tissue for the expression of α-SMA (A). Histogram showing the number of cells positively expressing α-SMA within a certain field of view (B). Values are expressed as the mean ± SD (n=9); **P<0.01 versus BDL rats. Scale bar: 100 μm.

(2018). On the other hand, much better improvement occurred in bicyclol treatment, as there is almost restoration of normal hepatic architecture (Figure 7A-C).

Sections of liver tissue stained with Masson’s trichrome stain for detection of fibrosis. BDL rats showed massive fibrosis around blood vessels that extends in between the hepatocytes. The rats treated with bicyclol or silymarin revealed decrease in fibrosis that became restricted to

areas around blood vessels, especially treated bicyclol, with minimal fibrous tissues between hepatocytes (Figure 7A-C).

DISCUSSION

The fundamental cellular event of liver fibrosis is hepatic

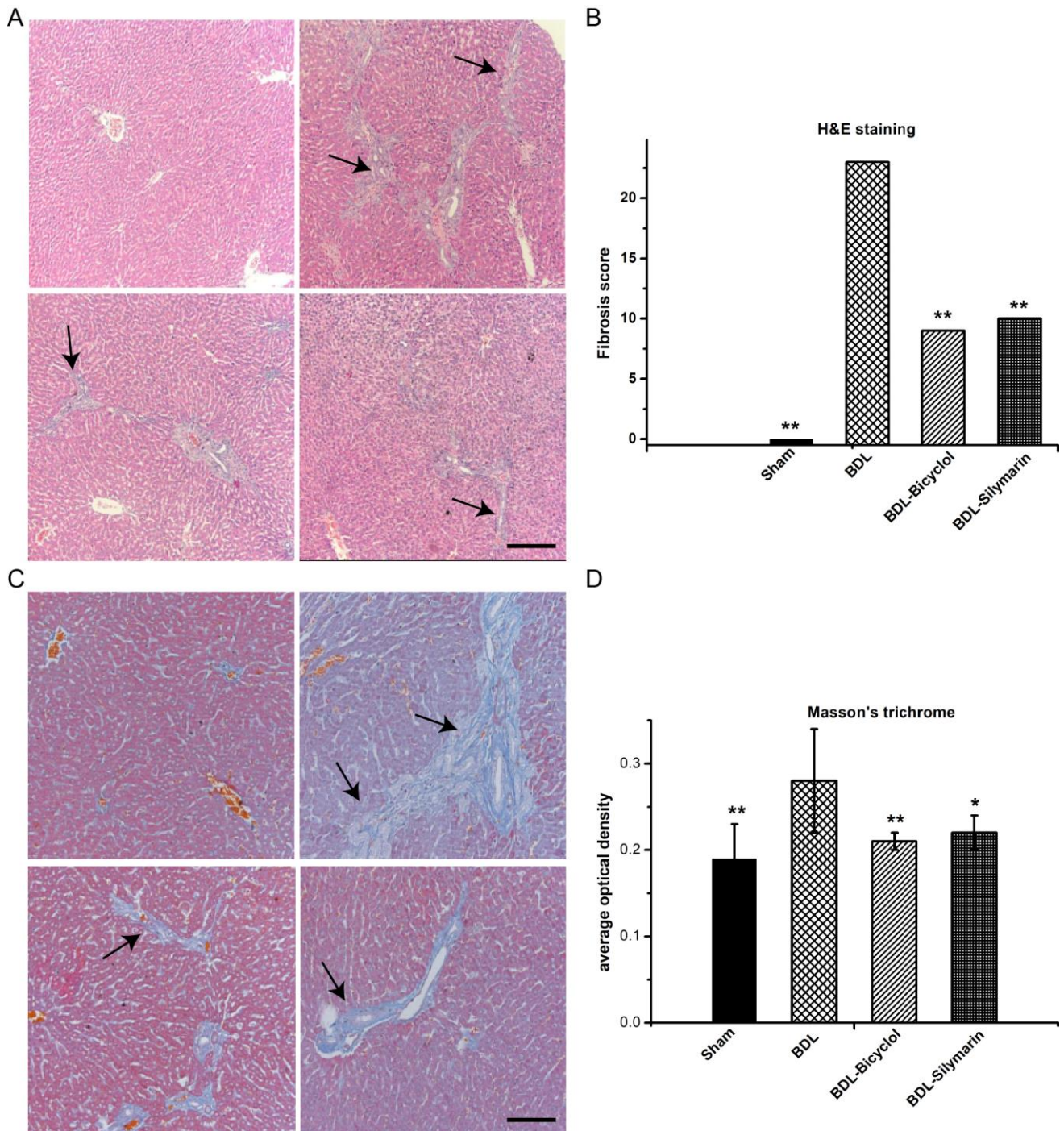


Figure 7. Effect of bicyclol and silymarin on the histopathology of liver in BDL rats. H&E, black arrows indicate changes in liver morphology (magnification $\times 100$) (A). Histogram showing the fibrosis score of H&E staining (B). Masson's trichrome, black arrows indicate fibrous strands (magnification $\times 200$) (C). Histogram showing the percentage area of Masson's trichrome staining of collagen (D). Values are expressed as the mean \pm SD (n=9); **P<0.01 versus BDL rats. Scale bar: 100 μ m.

stellate cells (HSCs) activation. Upon stimulation, myofibroblast-like cells will proliferate with accumulation of ECM, and expression of α -SMA (Friedman, 2000);

moreover, involving amount of inflammatory and fibrotic markers, even the liver function and structure changed. Liver fibrosis represents the final common pathway of all

chronic liver disease and eventually leads to cirrhosis, which is end-stage liver disease (Mu et al., 2018). Development of effective new drugs for treatment of this disease is of great importance.

Bicyclol has a preventive effect on a variety of liver injury with proprietary intellectual property rights in China. It was registered and sold in many countries. It is reported that bicyclol is effective in improving liver function, relieving hepatic inflammation, alleviating hepatic fibrosis, and has good hepatoprotective and anti-inflammatory effects. It was demonstrated in experimental and clinical studies that bicyclol decreased serum transaminase levels and resulted in improvements as observed by pathology (Han et al., 2014; Liu et al., 2017; Naqiong et al., 2017; Xie et al., 2012). Silymarin has been traditionally used because of its excellent hepatoprotective activity against to acute and chronic viral hepatitis, toxin/drug-induced liver disorders, alcoholic liver diseases and cirrhosis (Mastron et al., 2015). The basic and preclinical studies reported that anti-fibrotic properties are based on HSC cell cycle arrest, apoptosis of the activated HSCs, or free radicals scavenging properties (Ezhilarasan et al., 2017). However, at present, there is almost no information available on comparing the liver fibrosis protective effect of bicyclol and silymarin. So, we explored and compared the efficacy of bicyclol or silymarin in the treatment of BDL induced liver fibrosis rats.

In this study, the BDL model rats can be induced liver fibrosis with increase in serum ALT, AST, ALP, GGT, DBIL, TBIL and liver index, decrease in body weight and ALB. Together with the inflammatory and fibrotic markers, there were significant changes in TGF- β 1, IL-1 α , IL-4, IL-6, hydroxyproline and α -SMA. Finally, the histological examination showed severe destruction of hepatic architecture in BDL rats compared with sham control. This is in line with the previous studies (Gharbia et al., 2018; Mansour et al., 2018). Bicyclol decreased liver index, ALT, AST, ALP, GGT, DBIL and TBIL, increased ALB and body weight of BDL rats and improved liver histopathology significantly after four weeks. Similarly, it was shown that bicyclol reduced ALT, AST and TBIL, and also ameliorated the liver pathological structure in BDL rats (Zhen et al., 2015). And its effectiveness was comparable with the effect of silymarin. Silymarin has the effect on decreasing liver index, ALP, GGT, DBIL and TBIL, increasing ALB and improve liver tissue damage to a certain extent but with no significant effect on the ALT and AST activity. Therefore, we can conclude that bicyclol has a better effect on the serum biochemical index and the recovery of liver pathological structure of BDL rats than silymarin.

Inflammatory biomarkers such as IL-4, IL-1 α and IL-6 also play an important role in the process of fibrogenesis. The oral administration of bicyclol reduced IL-6 content, and increased IL- α and IL-4 respectively, as compared

with BDL rats. Silymarin treatment also could decrease the content of IL-6 and increase IL- α and IL-4 in liver to a certain degree, but with no significant difference as compared with BDL rats. It would be of benefit to point out that bicyclol is more potent as anti-inflammatory compared with silymarin in the BDL rats.

TGF- β 1 plays a key role in liver fibrogenesis (Xu et al., 2016). Action of TGF- β 1 signals mediated via its cognate receptors to Smad proteins, leading to activation of HSCs and production of ECM (Mallat and Lotersztajn, 2013). The hepatic α -SMA expression is a reliable marker of activated HSC *in situ*, which is recognized as being crucial in liver fibrogenesis. Additionally, HSCs activation is the main source of excessive ECM protein synthesis and deposition. During liver damage, HSCs become activated and is being accompanied by higher proliferation, expression of α -SMA and production of ECM (Friedman, 2003). Collagen is the main component of ECM, moreover, hydroxyproline is found almost exclusively in collagens. Thereafter, determination of the content of hydroxyproline in the tissue is regarded as a good method to quantify fibrosis and to evaluate the effectiveness of new potentially anti-fibrotic agents (Yoshiji et al., 2002). Indeed, both of bicyclol and silymarin could decrease the content of TGF- β 1 and hydroxyproline and lower the expression of α -SMA in the liver issue of BDL rats. But from the histograms, we can clearly know that the protective effect of bicyclol was always better than silymarin and rats treated with bicyclol had α -SMA staining pattern similar to the sham control.

Conclusion

This study assessed bicyclol or silymarin ameliorated the liver index, liver function activities, inflammatory biomarkers, fibrotic biomarkers and liver histopathology mentioned above in the BDL induced liver fibrosis rats. Finally, bicyclol is considered superior to silymarin in the treatment of liver fibrosis.

CONFLICT OF INTERESTS

The authors have not declared any conflicts of interests.

ACKNOWLEDGEMENTS

This work was supported by the Chinese National Natural Science Foundation (20872099), and the Science and Technology Department of Sichuan Province (11010119 and 2012SZ0184).

Authors contributed equally to this work.

REFERENCES

Abdelmeguid NE, Chmaisse HN, Abou Zeinab NS (2010). Silymarin

- ameliorates cisplatin-induced hepatotoxicity in rats: histopathological and ultrastructural studies. *Pakistan Journal of Biological Sciences* 13 (10):463-479.
- Almpanis Z, Demonakou M, Tiniakos D (2016). Evaluation of liver fibrosis: Something old, something new.... *Annals of Gastroenterology: Quarterly Publication of the Hellenic Society of Gastroenterology* 29(4): 445.
- Altamirano-Barrera A, Barranco-Fragoso B, Mendez-Sanchez N (2017). Management strategies for liver fibrosis. *Annals of Hepatology* 16(1):48-56.
- Avizeh R, Najafzadeh H, Razizalali M, Shirali S (2010). Evaluation of prophylactic and therapeutic effects of silymarin and N-acetylcysteine in acetaminophen-induced hepatotoxicity in cats. *Journal of Veterinary Pharmacology and Therapeutics* 33(1):95-99.
- Chi X, Xiao H, Shi M, Cai G, Xie Y, Jiang J, Tian G, Wu S, Zhang C, Zhao P, and Chen J (2019). Histological improvement in chronic hepatitis B patients treated with bicyclol: real world experience. *BMC Gastroenterol* 19(1):88.
- Clichici S, Olteanu D, Filip A, Nagy A L, Oros A, and Mircea P A (2016). Beneficial Effects of Silymarin After the Discontinuation of CCl4-Induced Liver Fibrosis. *Journal of Medicinal Food* 19(8):789-797.
- El-Lakkany NM, Hammam OA, El-Maadawy WH, Badawy AA, Ain-Shoka AA, Ebeid FA (2012). Anti-inflammatory/anti-fibrotic effects of the hepatoprotective silymarin and the schistosomicide praziquantel against *Schistosoma mansoni*-induced liver fibrosis. *Parasites and Vectors* 5(1):9.
- Ezhilarasan D, Evraerts J, Sid B, Calderon P B, Karthikeyan S, Sokal E, Najimi M (2017). Silibinin induces hepatic stellate cell cycle arrest via enhancing p53/p27 and inhibiting Akt downstream signaling protein expression. *Hepatobiliary and Pancreatic Diseases International* 16(1):80-87.
- French METAVIR Cooperative Study Group, and P. Bedossa (1994). Intraobserver and interobserver variations in liver biopsy interpretation in patients with chronic hepatitis C. The French METAVIR Cooperative Study Group. *Hepatology* 20 (1 Pt 1):15-20.
- Friedman SL (2000). Molecular regulation of hepatic fibrosis, an integrated cellular response to tissue injury. *Journal of Biological Chemistry* 275 (4):2247-2250.
- Friedman S L (2003). Liver fibrosis -- from bench to bedside. *Journal of Hepatology* 38:38-53.
- Gharbia S, Balta C, Herman H, Rosu M, Varadi J, Bacskay I, Cristian RE(2018). Enhancement of silymarin anti-fibrotic effects by complexation with hydroxypropyl (HPBCD) and randomly methylated (RAMEB) β -cyclodextrins in a mouse model of liver fibrosis. *Frontiers in Pharmacology* 9:883.
- Ghosh S, Sarkar A, Bhattacharyya S, Sil PC (2016). Silymarin Protects Mouse Liver and Kidney from Thioacetamide Induced Toxicity by Scavenging Reactive Oxygen Species and Activating PI3K-Akt Pathway. *Frontiers in Pharmacology* 7:481.
- Gu Y, Zhao J, Yao XM, Li Y (2010). Effects of bicyclol on immunological liver fibrosis in rats. *Journal of Asian Natural Products Research* 12(5):388-398.
- Gulamhusein AF, Hirschfield GM (2019). Primary biliary cholangitis: pathogenesis and therapeutic opportunities. *Nature Reviews Gastroenterology and Hepatology*, pp. 1-18.
- Han Y, Shi JP, Ma AL, Xu Y, Ding XD, Fan JG (2014). Randomized, vitamin E-controlled trial of bicyclol plus metformin in non-alcoholic fatty liver disease patients with impaired fasting glucose. *Clinical Drug Investigation* 34(1):1-7.
- Hu QW, Liu GT (2006). Effects of bicyclol on dimethylnitrosamine-induced liver fibrosis in mice and its mechanism of action. *Life Sciences* 79(6):606-612.
- Jain A, Yadav A, Bozhkov AI, Padalko VI, Flora S JS (2011). Therapeutic efficacy of silymarin and naringenin in reducing arsenic-induced hepatic damage in young rats. *Ecotoxicology and Environmental Safety* 74(4):607-614.
- Li X, Zhou J, Chen S, Guan M, Wang Y, Zhao L, Zhou Y (2014). Role of bicyclol in preventing chemotherapeutic agent-induced liver injury in patients over 60 years of age with cancer. *Journal of International Medical Research* 42(4):906-914.
- Li Y, Dai GW, Liu GT (2001). Effect of bicyclol on acetaminophen-induced hepatotoxicity: energetic metabolism and mitochondrial injury in acetaminophen-intoxicated mice. *Yao xue xue bao= Acta Pharmaceutica Sinica* 36(10):723-726.
- Liu GT (2009). Bicyclol: a novel drug for treating chronic viral hepatitis B and C. *Medicinal Chemistry* 5(1):29-43.
- Liu X, Zhao M, Mi J, Chen H, Sheng L, Li Y (2017). Protective effect of bicyclol on anti-tuberculosis drug induced liver injury in rats. *Molecules* 22(4):524.
- Mallat A, Lotersztajn S (2013). Cellular mechanisms of tissue fibrosis. 5. Novel insights into liver fibrosis. *American Journal of Physiology-Cell Physiology* 305(8):789-799
- Mansour HM, Salama AAA, Abdel-Salam RM, Ahmed NA, Yassen NN, Zaki HF (2018). The anti-inflammatory and anti-fibrotic effects of tadalafil in thioacetamide-induced liver fibrosis in rats. *Canadian Journal of Physiology and Pharmacology* 96(12):1308-1317.
- Mastron JK, Siveen KS, Sethi G, Bishayee A (2015). Silymarin and hepatocellular carcinoma: a systematic, comprehensive, and critical review. *Anticancer Drugs* 26(5):475-486.
- Mu M, Zuo S, Wu RM, Deng KS, Lu S, Zhu JJ, Zou GL, Yang J, Cheng ML, Zhao XK (2018). Ferulic acid attenuates liver fibrosis and hepatic stellate cell activation via inhibition of TGF-beta/Smad signaling pathway. *Drug Design Development and Therapy* 12(4):107-4115.
- Muthumani M, Prabu SM (2012). Silibinin potentially protects arsenic-induced oxidative hepatic dysfunction in rats. *Toxicology Mechanisms and Methods* 22(4):277-288.
- Naqiong W, Liansheng W, Zhanying H, Yuanlin G, Chenggang Z, Ying G, Jianjun L (2017). A multicenter and randomized controlled trial of bicyclol in the treatment of statin-induced liver injury. *Medical science monitor: international Medical Journal of Experimental and Clinical Research* 23:5760.
- Polyak SJ, Ferenci P, Pawlowsky JM (2013). Hepatoprotective and antiviral functions of silymarin components in hepatitis C virus infection. *Hepatology* 57 (3):1262-1271.
- Saber S, Goda R, El-Tanbouly GS, Ezzat D (2018). Lisinopril inhibits nuclear transcription factor kappa B and augments sensitivity to silymarin in experimental liver fibrosis. *International Immunopharmacology* 64:340-349.
- Salam OMA, Sleem AA, Omara EA, Hassan NS (2009). Hepatoprotective effects of misoprostol and silymarin on carbon tetrachloride - induced hepatic damage in rats. *Fundamental and Clinical Pharmacology* 23(2):179-188.
- Schutte K, Kipper M, Kahl S, Bornschein J, Gotze T, Adolf D, Arend J, Seidensticker R, Lippert H, Ricke J, Malfertheiner P (2013). Clinical characteristics and time trends in etiology of hepatocellular cancer in Germany. *Digestion* 87(3):147-159.
- Shaker E, Mahmoud H, Mnaa S (2010). Silymarin, the antioxidant component and Silybum marianum extracts prevent liver damage. *Food and Chemical Toxicology* 48(3):803-806.
- Trautwein C, Friedman SL, Schuppan D, Pinzani M (2015). Hepatic fibrosis: concept to treatment. *Journal of hepatology* 62(1):15-24.
- Xie W, Shi G, Zhang H, Zhao G, Yu Z, Lang Z, Cheng J (2012). A randomized, multi-central, controlled study of patients with hepatitis B e antigen-positive chronic hepatitis B treated by adefovir dipivoxil or adefovir dipivoxil plus bicyclol. *Hepatology International* 6(2):441-448.
- Xu F, Liu C, Zhou D, Zhang L (2016). TGF- β /SMAD pathway and its regulation in hepatic fibrosis. *Journal of Histochemistry and Cytochemistry* 64(3):157-167.
- Yoshiji H, Kuriyama S, Yoshiji J, Ikenaka Y, Noguchi R, Nakatani T, Fukui H (2002). Tissue inhibitor of metalloproteinases-1 attenuates spontaneous liver fibrosis resolution in the transgenic mouse. *Hepatology* 36(4):850-860.
- Zhang W, Hong R, Tian T (2013). Silymarin's protective effects and possible mechanisms on alcoholic fatty liver for rats. *Biomolecules and Therapeutics* 21(4):264-269.
- Zhen YZ, Li NR, He HW, Zhao SS, Zhang GL, Hao X F, Shao RG (2015). Protective effect of bicyclol against bile duct ligation-induced hepatic fibrosis in rats. *World Journal of Gastroenterology* 21(23):7155.