

Full Length Research Paper

## Antiprotozoal effect of *Allium cepa* on acute renal failure caused by *Toxoplasma gondii*

Yaghub Gharadaghi<sup>1</sup>, Saeedeh Shojaee<sup>2</sup>, Arash Khaki<sup>3\*</sup>, Fatemeh fathiazad<sup>4</sup>, Amir afshin Khaki<sup>5</sup>, Elham Ghdamkheir<sup>6</sup> and Mahdi rouhaninia<sup>7</sup>

<sup>1</sup>Department of Parasitology, Tabriz Branch, Islamic Azad University, Tabriz, Iran.

<sup>2</sup>Department of Medical Parasitology, School of Public Health, Tehran University of Medical Sciences, Tehran, Iran.

<sup>3</sup>Department of Veterinary Pathology, Tabriz Branch, Islamic Azad University, Tabriz, Iran.

<sup>4</sup>Department of Pharmacognosy, Faculty of Pharmacy, Tabriz University of Medical Sciences, Tabriz, Iran.

<sup>5</sup>Department of Anatomical Sciences, Bonab Branch, Islamic Azad University, Bonab, Iran.

<sup>6</sup>Department of Veterinary Pathology, Tabriz Branch, Islamic Azad University, Tabriz, Iran.

<sup>7</sup>Department of horticulture, Faculty of Agriculture, Tabriz University, Tabriz, Iran.

Accepted 29 February, 2012

Renal failure is described as a decrease in glomerular filtration rate. Biochemically, renal failure is typically detected by an elevated serum creatinine level. The present study was investigated to evaluate the effects of *Allium cepa* on renal failure in male rats which experimentally infected by *Toxoplasma gondii*, RH strain. Wistar male rats (n=40) were allocated into four groups, group one received tachyzoites of *T. gondii* (ip) (n=10), group two received tachyzoites of *T. gondii* (ip) plus fresh onion juice by gavage method (n=10), group three received just fresh onion juice by gavage method (n=10) and control group (n=10) received nothing. Animals were kept in standard condition. In 30 day after inducing toxoplasma infection, 5<sup>CC</sup> blood were collected for serum creatinine, BUN, protein, albumin, malondialdehyde (MDA) and total antioxidant capacity (TAC) levels. Kidney tissues of rat in whole groups were removed and prepared for analysis. Serum albumin and TAC were significantly decreased in group that was infected with *T. gondii*, in comparison to control and onion groups. Kidneys weights in toxoplasma group significantly decreased in comparison to control group (P<0.05). This study showed that *T. gondii* have significantly effect on serum creatinine, albumin, blood urea nitrogen (BUN), MDA and TAC and fresh onion juice returned and treated this harmful effect, so it is suggested that eating of onion is useful in toxoplasma infection.

**Key words:** Albumin, *Allium cepa*, creatinine, kidney, *Toxoplasma gondii*.

### INTRODUCTION

Despite the advances in medical care, acute renal failure (ARF) remains as an important problem that leads to morbidity and mortality and requires special care (such as dialysis) and causes high financial cost (Aykut et al., 2012). Acute kidney injuries can be present on top of chronic kidney disease, a condition called acute-on-

chronic renal failure (AoCRF). The acute part of AoCRF may be reversible, and the goal of treatment, as with AKI, is to return the patient to baseline renal function, typically measured by serum creatinine and it describes condition in which the kidneys fail to adequately filter toxins and waste products from the blood. There are two forms of this disease: acute and chronic. Renal failure is described as a decrease in glomerular filtration rate. Biochemically, renal failure is typically detected by an elevated serum creatinine level and proteinuria (protein loss in the urine) may occur. Toxoplasmosis is a parasitic disease caused

\*Corresponding author. Email: [arashkhaki@yahoo.com](mailto:arashkhaki@yahoo.com). Tel: +98-9143138399.

by the protozoan *Toxoplasma gondii* (Ryan and Ray, 2004). The parasite infects most genera of warm-blooded animals, including humans, but the definitive host is the felid (cat) family. Animals are infected by eating of infected meat, by ingestion of feces of a cat that has itself recently been infected, or by transmission from mother to fetus.

Although cats are often blamed for spreading toxoplasmosis, contact with raw meat is a more significant source of human infections in many countries, and fecal contamination of hands is a greater risk factor (Torda, 2001). Up to one third of the world's human population is estimated to carry a toxoplasma infection (Montoya and Liesenfeld, 2004). The Centers for Disease Control and Prevention notes that overall seroprevalence of toxoplasma infection in the United States as determined with specimens collected by the National Health and Nutritional Examination Survey (NHANES) between 1999 and 2004 was found to be 10.8%, with seroprevalence among women of childbearing age (15 to 44 years) 11% (Jones et al., 2007). Many parasites such as *Cryptosporidium*, *Toxoplasma*, *Leishmania*, *Trypanosoma*, *Strongyloides*, *Malaria* and *Schistosoma* cause to severe infection in immunocompromised patients. These infections may be either acquired de novo (for example, toxoplasmosis and malaria) or a dormant infection may be activated as a result of immunosuppression (for example, cryptosporidiosis and strongyloidiasis).

Several studies have reported that antioxidants and vitamin A, B, C, and E in diet can protect mammalian cells deoxyribonucleic acid (DNA) from free radicals (Jedlinska-krakowska et al., 2006). Also ascorbic acid or N-acetylcysteine that have been investigated in some ischemia-reperfusion injury studies could provide protection against renal I/R injury in rats (Aykut et al., 2012). Evidences suggest that *Allium cepa* has antioxidative effects in rats (Khaki et al., 2009). Antioxidants protect DNA and other important molecules from oxidation and damage (Yang et al., 2006). Therefore, the role of nutritional and biochemical factors on immune systems is very important. The present study was planned to assess the ability of *A. cepa* for the treatment of kidney functional in biochemical, when induced renal failure in rats infected by *T. gondii*. The results obtained here will provide further insights into appropriate treatment of *T. gondii* by using herbals.

## MATERIALS AND METHODS

### Plant material

#### Preparation of onion juice

The underground yellowish-white bulbs of *A. cepa* (onion) was collected in August 2007 from Ilkhchi in the province of East

Azerbaijan-Iran. The skin was removed and fresh juice of onions was prepared using a Tefal fruit juice extracting machine before the experiments.

### Analysis of onion juice

The onion juice was tested for the determination of flavonoids using the Shinoda test (Yousef, 2005). Qualitative thin-layer chromatography (TLC) was employed for determination of quercetin as a main flavonoid in onion. For TLC, 10 mL of fresh onion juice was dried in a vacuum and the resulting residue dissolved in 1 mL of methanol. 20 mL of methanolic solution was spotted on a silica gel plate (10 × 20 cm, silica gel 60 GF254, Merck, Darmstadt, Germany) with a solvent system of EtOAc/MeOH (80:20). Quercetin, Sigma chemical Co. (St. Louis, MO, USA) was used as a control. After developing and drying, the TLC plate was sprayed with a 2% AlCl<sub>3</sub> solution in methanol. Quercetin in the onion samples appeared as a yellow spot at R<sub>F</sub> = 0.6. Separation of quercetin was performed with further purification by preparative TLC on silica gel and quantitative determination of quercetin carried out on a Model 2100 Spectrophotometer (Shimadzu, Japan) in 370 nm comparing to a pure quercetin standard curve. The amount of quercetin in fresh onion was 12 mg/100 g.

### *T. gondii* infection

Tachyzoites of *T. gondii* RH strain was maintained by passage in mice every 3 days. Tachyzoites were collected from the peritoneal cavity of infected mice and used to inoculate to rats. The rats were intraperitoneally injected with 10<sup>7</sup> tachyzoites of *T. gondii* (Berday et al., 2000) in animal house at the department of vet pathology in Islamic Azad University, Tabriz Branch-Iran (Khaki et al., 2011).

### Experimental animals

Forty adult Wistar albino male rats with 8 weeks old and weigh 250±10 g were obtained from animal facility of pasture institute of Iran. Male rats were housed in temperature controlled rooms (25°C) with constant humidity (40 to 70%) and 12 h light/ dark cycle prior to experimental protocols. All animals were treated in accordance to the Principles of Laboratory Animal Care [NIH]. All rats were fed a standard diet and water. The daily intake of animal water was monitored at least one week prior to start of treatments in order to determine the amount of water needed per experimental animal. Thereafter, the rats were randomly divided into control (n=10) and experimental (n=30) groups. The control group just received 4<sup>CC</sup> distilled water daily. However, the experimental infected rats (n =20) split to two toxoplasma infected groups, one of these groups was toxoplasma test group (n=10) and the other was toxoplasma group (n=10) which received 1<sup>CC</sup> of fresh onion juice daily for 20 consecutive days; the fourth group (n=10) received just 1<sup>CC</sup> of fresh onion juice daily for 20 consecutive days (Khaki et al., 2009), this group was onion test group. At the end of the study the rats were killed with carbon dioxide. All procedures in this research were approved by the Ethical committee of Tabriz University of Medical Sciences.

### Surgical procedure

In thirtieth day, the Pentobarbital sodium (40 mg/kg) was administered intra-peritoneal for anesthesia and the peritoneal cavity was opened through a lower transverse abdominal I incision.

**Table 1.** The effect of the 1<sup>CC</sup> fresh onion juice/rat on kidney weights, serum creatinine, albumin, BUN, TAC and MDA of control and toxoplasma groups in the rats.

Group	Control	1 <sup>CC</sup> fresh onion juice /rat	Toxoplasma	Toxoplasma plus 1 <sup>CC</sup> fresh onion juice /rat
Kidney (gr)	0.49±0.55	0.48±0.54	0.45±0.55	0.45±0.55
Serum creatinine (mg/dl)	0.1±0.05	0.99±0.11	0.2±0.33	0.15±0.33
Serum albumin (g/dl)	3.1±0.05	3.6±0.05	2.6±0.05	2.6±0.05
Serum BUN (mg/dl)	44±0.02	40±0.01	90±0.02	65±0.02
Total antioxidant capacity (mmol/ml)	0.80±0.55	1±0.01*	0.50±0.55*	0.60±0.55*
Malondialdehyde (mmol/ml)	3.70±0.55	2.22±0.11*	4.90±0.55*	2.82±0.11*

Data are presented as mean±SE. \*Significant different at P<0.05 level, (compared with the control group).

Thereafter kidneys in control and experimental groups were immediately removed. The weights of kidneys in each group were registered. The animals were decapitated between 9:00 AM and 11:00 AM, and blood samples were obtained. Blood samples were centrifuged at 4°C for 10 min at 250×g and the obtained serum was stored at -20°C until used.

#### Histopathological kidney studies

For histological studies, kidneys were fixed in formaldehyde 10%, buffer. 5 µm paraffin sections were stained with *H&E* and *Masson's trichrome* staining methods.

#### Serum analysis for biochemical studies

Level of BUN, creatinine, total protein and albumin were measured using kits (Merck Diagnostic Ltd., India) followed by spectrometric methods. The values were expressed in mg dL<sup>-1</sup> in all the cases.

#### TAC, MDA measurement in serum

A TAC detecting kit was obtained from Nanjing Jiancheng Bioengineering Institute-China. According to this method, the antioxidant defense system, which consists of enzymatic and non-enzymatic antioxidants, is able to reduce Fe<sup>3+</sup> to Fe<sup>2+</sup>. TAC was measured by the reaction of phenanthroline and Fe<sup>2+</sup> using a spectrophotometer at 520 nm. At 37°C, a TAC unit is defined as the amount of antioxidants required to make absorbance increase 0.01 in 1 mL of serum (Huang et al., 1995). Free radical damage was determined by specifically measuring MDA. MDA was formed as an end product of lipid peroxidation which was treated with thiobarbituric acid to generate a colored product that was measured at 532 nm (MDA detecting kit from Nanjing Jiancheng Bioengineering Institute-China) (Quintanilha et al., 1982).

#### Statistical analysis

Statistical comparisons were made using the ANOVA test for comparison of data in the control group and the experimental groups. The results were expressed as mean±S.E.M (standard error of means) and significance levels were set at P<0.05.

## RESULTS

### Weight of individual male kidney

The obtained results in this study are illustrated in Table 1. There was significant difference in kidney weights between toxoplasma groups as compared to the other groups (p<0.05) (Table 1).

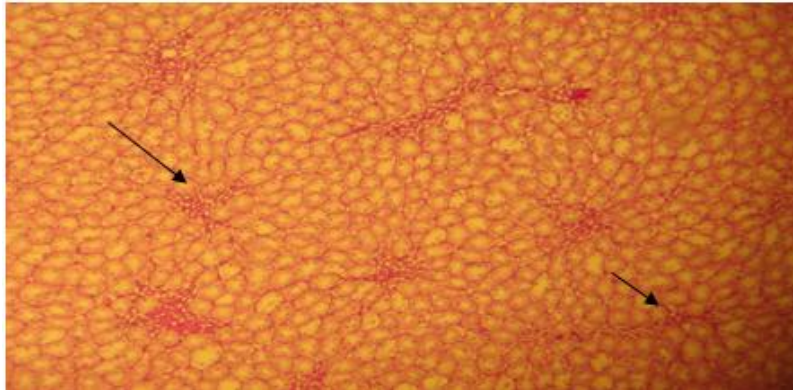
### Histopathological studies of kidneys

Histopathological studies of kidneys showed the normal architecture including glomerulus, bowman capsules, proximal and distal tubules. Toxoplasmosis markedly disrupted the histology as evidenced by the tubular degeneration, tubular congestion, tubular dilatation, necrosis and glomerular injuries (Figures 1 and 2).

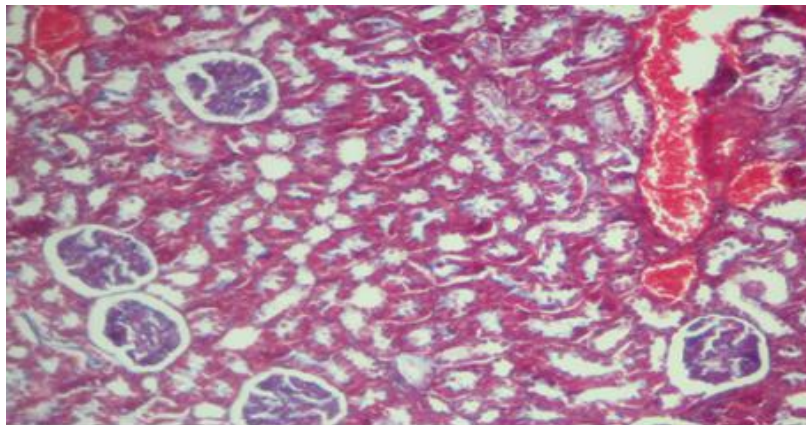
Prevention of nephropathological injuries was determined with onion in toxoplasma treated rats (Figure 3). Fresh onion juice can treat inter-tubular congestion, rearrangement of tubular and tubules healing (Figure 4).

### Results of serum BUN, creatinine total protein and albumin measurement

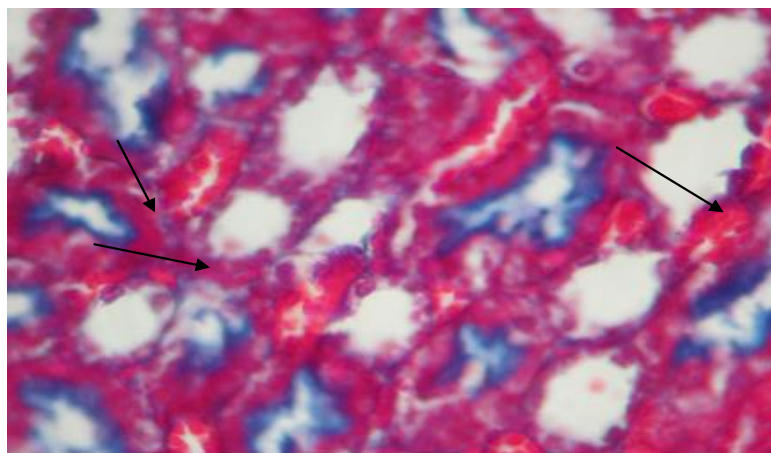
Effects of 1<sup>CC</sup> fresh onion juice and toxoplasma plus onion juice on serum BUN, total protein, albumin and creatinine are shown in Table 1. In the toxoplasma group, there was an increase in serum BUN, creatinine and a decrease in total protein and albumin level significantly viewed in the toxoplasma group than the control and onion groups. Administration of 1<sup>CC</sup> fresh onion juice in combination with toxoplasma ameliorated the pathogenicity of *Toxoplasma* and rebounded the level of total protein, albumin and caused a significant reduction in creatinine levels as compared to that of the toxoplasma treated group. However, these differences were non-significant alterations in the levels of the treated group as compared to the control group (P<0.05) (Table 1).



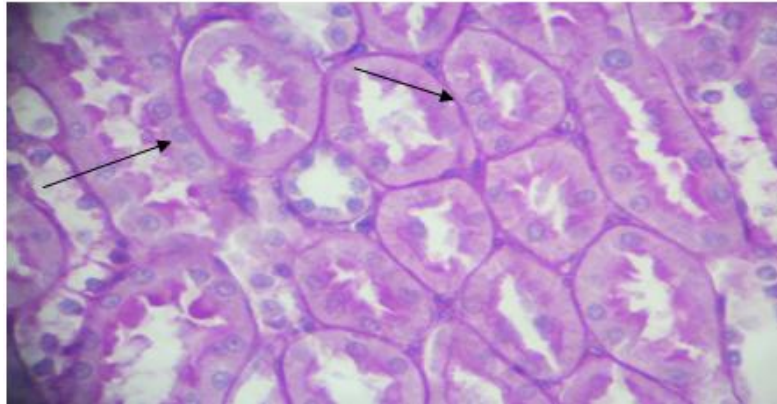
**Figure 1.** showed the normal architecture including glomerulus, bowman capsule, proximal and distal tubules, H&E, X640.



**Figure 2.** Toxoplasmosis markedly disrupted the histology as evidenced by the tubular degeneration, tubular congestion, tubular dilatation, necrosis and glomerular injuries, H&E and Masson's trichrome, X640.



**Figure 3.** Toxoplasmosis markedly disrupted the histology as evidenced by the tubular degeneration, inter-tubular congestion, tubular dilatation, necrosis and glomerular injuries, H&E and Masson's trichrome, X640.



**Figure 4.** Healing of nephropathological injuries was determined in toxoplasmosis group that receive onion juice, Masson's trichrome, X640.

### Results of TAC and MDA concentration measurement in serum

The mean concentration of MDA level was not significantly difference in all groups in comparison to control group ( $P < 0.05$ ). TAC was significantly higher in fresh onion juice groups as compared with toxoplasma group ( $P < 0.05$ ) (Table 1).

### DISCUSSION

Acute kidney failure usually occurs when the blood supply to the kidneys is suddenly interrupted or when the kidneys become overloaded with toxins. Causes of acute failure include accidents, injuries, or complications from surgeries in which the kidneys are deprived of normal blood flow for extended periods of time. Heart-bypass surgery is an example of one such procedure. Drug overdoses, accidental or from chemical overloads of drugs such as antibiotics or chemotherapeutics, may also cause the onset of acute kidney failure. Unlike in chronic kidney disease, however, the kidneys can often recover from acute failure, allowing the patient to resume a normal life. People suffering from acute failure require supportive treatment until their kidneys recover function, and they often remain at increased risk of developing future kidney failure (Klahr and Miller, 1998). Parasites are an important union in the rich tropical and subtropical bioecology and depended to the climatic conditions, economic standards and lack of adequate preventive health care programmes. *T. gondii* infection is associated with a wide spectrum of clinical pictures in man, it has been well documented that toxoplasmosis is of crucial importance especially for pregnant women and immunocompromised patients.

In addition to the risks of gestation complications and congenital infections, it has been suggested that toxoplasmosis has some unfavorable effects on reproductive capacity in both men and women (Aral et al., 2011). Many parasites such as *cryptosporidium*, *toxoplasma*, *leishmania*, *trypanosomia*, *strongyloides*, *malaria* and *schistosomia* cause to severe infection in the immunocompromised patients. The first reports came up from South East Asia, where up to 18.5% of acute renal failures (38.5% of those due to medical causes) are attributed to *Plasmodium falciparum* infections. Many parasitic infections lead to acute or subclinical self-limited glomerulopathy during the early phase of immune stimulation. Toxoplasmosis and schistosomiasis, malaria, filariasis, leishmaniasis, trichinosis, ecchinococcosis and trypanosomiasis cause to glomerular lesions and urinary abnormalities such as proteinuria, lymphocyturia and pyuria were accoured (Wang et al., 2005). Acute interstitial lesions resulted by parasite-associated interstitial nephritis in many parasistis infection like kala-azar disease and heavily infiltrated with monocytes and lymphocytes, which clearly display an acute cell-mediated inflammation.

Occasionally, renal function is impaired even with acute oliguric renal failure (Wang et al., 2004). Researchers was revealed that IFN- $\gamma$  plays an important role in preventing the reactivation of *T. gondii* (Kang and Suzuki, 2001; Wang et al., 2007). Non- T cells and CD8- positive T cells were reported as sources of IFN- $\gamma$  during chronic toxoplasma infection, which prevent reactivation (Khan et al., 1999; Wang et al., 2005, 2007). It was also reported that IL-12 is required for the maintenance of IFN- $\gamma$  production of T cells during chronic toxoplasma infection (Yap et al., 2000). Onion and garlic contain a wide variety of phytochemicals and micro constituents such as trace elements, vitamins, fructans, flavonoids, and sulphur

compounds, which may have a protective effect against free radicals. Recently, much attention has been focused on the protective effects of onion against colon cancers in rats (Fukushima et al., 1997; Ross et al., 2006). Haidari showed that oral administration of onion at 3.5 and 7.0 mg kg<sup>-1</sup> day<sup>-1</sup> for 7 days was able to reduce serum uric acid levels in hyperuricemic rats with no significant effects on the level of this compound in the normal animals.

In addition, when onion tested *in vivo* on rat liver homogeneities elicited significant inhibitory actions on the Xanthine Dehydrogenase (XDH) and Xanthine Oxidase (XO) activities (Haidari et al., 2008). Our results showed that administration of onion juice (1<sup>CC</sup>/rat/day) for 20 consecutive days caused a marked increase in TAC and significantly decrease in MDA, creatinine and BUN levels, as compared to respective controls and this agree with our previous research (Khaki et al., 2009; Khaki et al., 2011). These effects could be related to vitamins, vitamin C, and flavonoids of onion such as quercetin. Oxidative damage was ascertained by measuring malondialdehyde levels, reactive oxygen species (ROS) generation, alterations in antioxidant defences and the extent of protein oxidation. Quercetin, an important flavonoid, has a beneficial effect on health due to its antioxidant function (Khaki et al., 2010). Previous study showed, the effect of quercetin on serum MDA was determined, but the results indicated no obvious effect of quercetin on MDA production (Mi and Zhang 2005, Mi et al., 2007).

In present study *T. gondii* was significantly reduced level of TAC showe glomerular and tubular injury and cause to hypoproteinemia, albuminemia and reduces of reabsorption in kidneys and in other hand our researches showed that onion fresh juice can reuptake and balance the level of TAC and have balancing rule in creatinine, BUN, protein and albumin in witch group of animals that infected with *T. gondii*, and this results in agreement with other researchers finding that showed onion can treatment hyperuricemic rats and balances the level of hepatic XDH and XO activities (Haidari et al., 2008). Antioxidants and vitamins from foods consumed by animals, such as quercetin, vitamin C, B, and E, could improve sperm health parameters and testicular androgenesis. in our research results were showed that onion fresh juice could significantly increase and recovery of serum parameters such as TAC, BUN and protein levels in infected rats, in other study that done by McCarthy and friends study in 2003, they were showed vitamin E and selenium could resulted in trends toward increased tissue cyst number, tissue pathology and weight loss during infection (McCarthy et al., 2003).

In our study, *T.gondii* have significantly effect on protein losing and cause to hypoproteinemia, increased creatinin and decreasing albumin in serum. These findings revealed fresh onion juice has strong antioxidant potential and decreasing cell injury, such as apoptosis in

tubules and nephrons and doing antiprotozoal role with decreasing cell injury in nephrons, so it is suggested that eating of onion is useful in infected patients.

## REFERENCES

- Aral AG, Elhan HA, Akarsu C (2011). Retrospective evaluation of Toxoplasma gondii seropositivity in fertile and infertile women. Mikrobiyol. Bull., 45(1): 174-180.
- Aykut K, Kavala A, Hazan E, Sarioglu S, Paksoy S, Sisma A (2012). The effect of iloprost on renal ischemia/reperfusion injury in an experimental rat model. Afr. J. Pharm. Pharmacol., 6(6): 397-401.
- Berdoy M, Webster JP, Macdonald DW (2000). Fatal attraction in rats infected with Toxoplasma gondii. Proc. Biol. Sci., 267(1452): 1591-1594.
- Fukushima S, Takada N, Hori T, Wanibuchi H (1997). Cancer prevention by organosulfur compounds from garlic and onion. J. Cell Biochem., 27: 100-105.
- Haidari F, Rashidi MR, Keshavarz SA, Mahboob SA, Eshraghian MR, Shahi MM (2008). Effects of onion on serum uric acid levels and hepatic xanthine dehydrogenase/xanthine oxidase activities in hyperuricemic rats. Pak. J. Biol. Sci., 11(14): 1779-1784.
- Huang HFS, Linsenmeyer TA, Li MT, Giglio W, Anesetti R, von Hagen J, Ottenweller JE, Pogach L (1995). Acute effects of spinal cord injury on the pituitary-testicular hormone axis and Sertoli cell functions: a time course study. J. Androl., 16: 148-157.
- Jedlińska-Krakowska M, Bomba G, Jakubowski K, Rotkiewicz T, Jana B, Penkowski A (2006). Impact of oxidative stress and supplementation with vitamins E and C on testes morphology in rats. J. Reprod. Dev., 52: 203-209.
- Jones JL, Kruszon-Moran D, Sanders-Lewis K, Wilson M (2007). Toxoplasma gondii infection in the United States, 1999-2004, decline from the prior decade. Am. J. Trop. Med. Hyg., 77(3): 405-10.
- Kang H, Suzuki Y (2001). Requirement of non-T cells that produce gamma interferon for prevention of reactivation of Toxoplasma gondii infection in the brain. Infect. Immun., 69(5): 2920-2927.
- Khaki A, Fathiazad F, Nouri M, Khaki AA, Khamenehi HJ, Hamadeh M (2009). Evaluation of androgenic activity of allium cepa on spermatogenesis in the rat. Folia Morphol.(Warsz), 68(1): 45-51.
- Khaki A, Fathiazad F, Nouri M, Khaki A, Maleki NA, Khamnei HJ, Ahmadi P (2010). Beneficial effects of quercetin on sperm parameters in streptozotocin-induced diabetic male rats. Phytother. Res., 24(9): 1285-1291.
- Khaki A, Farzadi L, Ahmadi Sh, Ghadamkheir E, Khaki AA, Shojaaee S, Sahizadeh R (2011). Recovery of spermatogenesis by Allium cepa in Toxoplasma gondii infected rats. Afr. J. Pharm. Pharmacol., 5(7): 903 - 907.
- Khan IA, Green WR, Kasper LH, Green KA, Schwartzman JD (1999). Immune CD8(+) T cells prevent reactivation of Toxoplasma gondii infection in the immunocompromised host. Infect Immun., 67(11): 5869-5876.
- Klahr S, Miller S (1998). Acute oliguria. N Engl. J. Med., 338(10): 671-675.
- McCarthy SM, Davis CD (2003). Prooxidant diet provides protection during murine infection with Toxoplasma gondii. J. Parasitol., 89(5): 886-894.
- Mi Y, Zhang C (2005). Protective effect of quercetin on Aroclor 1254-induced oxidative damage in cultured chicken spermatogonial cells. Toxicol. Sci., 88: 545-550.
- Mi Y, Zhang C, Taya K (2007). Quercetin protects spermatogonial cells from 2,4-d-induced oxidative damage in embryonic chickens. J. Reprod. Dev., 53: 749-754.
- Montoya J, Liesenfeld O (2004). Toxoplasmosis. Lancet. 363(9425): 1965-1976.
- Quintanilha AT, Packer L, Davies JM, Racanelli TL, Davies KJ (1982). Membrane effects of vitamin E deficiency: bioenergetic and surface charge density studies of skeletal muscle and liver mitochondria. Ann. NY. Acad. Sci., 393: 32-47.

- Ross SA, Finley JW, Milner JA (2006). Allyl sulfur compounds from garlic modulate aberrant crypt formation. *J. Nutr.*, 136: 852S-854S.
- Ryan KJ, Ray CG (2004). *Sherris Medical Microbiology*(4th ed.). McGraw Hill. pp. 723-7277.
- Torda A(2001). Toxoplasmosis. Are cats really the source? . *Aust. Fam. Physician*, 30(8): 743-747.
- Wang X, Kang H, Kikuchi T, Suzuki Y(2004). Gamma interferon production, but not perforin-mediated cytolytic activity, of T cells is required for prevention of toxoplasmic encephalitis in BALB/c mice genetically resistant to the disease. *Infect Immun.*, 72(8): 4432-4438.
- Wang X, Claflin J, Kang H, Suzuki Y(2005). Importance of CD8(+)/Vbeta8(+) T cells in IFN-gamma-mediated prevention of toxoplasmic encephalitis in genetically resistant BALB/c mice. *J. Interferon Cytokine Res.*, 25(6): 338-344.
- Wang X, Michie SA, Xu B, Suzuki Y(2007). Importance of IFN-gamma-mediated expression of endothelial VCAM-1 on recruitment of CD8+ T cells into the brain during chronic infection with *Toxoplasma gondii*. *J. Interferon Cytokine Res.*, 27(4): 329-338.
- Yang HS, Han DK, Kim JR, Sim JC (2006). Effects of alpha- tocopherol on cadmium-induced toxicity in rat testis and spermatogenesis. *J. Korean Med. Sci.*, 21: 445-451.
- Yap G, Pesin M, Sher A (2000). Cutting edge: IL-12 is required for the maintenance of IFN-gamma production in T cells mediating chronic resistance to the intracellular pathogen, *Toxoplasma gondii*. *J. Immunol.*, 15: 165(2): 628-631.
- Yousef MI (2005). Protective effect of ascorbic acid to enhance reproductive performance of male rabbits treated with stannous chloride. *Toxicology*, 207: 81-89.