

Full Length Research Paper

Histopathological and genetic study on the protective role of β -Carotene on testicular tissue of adult male albino rats treated with titanium dioxide nanoparticles

Amira Hamed Mohamed Soliman*, Ibrahim Amin Ibrahim, Mohammed Ahmed Shehata and Heba Osama Mohammed

Department of Anatomy and Embryology, Faculty of Medicine, Zagazig University, Egypt.

Received 27 November, 2019; Accepted 23 December, 2019

Titanium dioxide nanoparticles are one of the famous widely produced nanoparticles in the world that are widely used in paints, cosmetics, plastics, pharmaceutical preparations, water treatment and purification and filtration of air. Beta carotene is provitamin A carotenoid with antioxidant and anti-apoptotic activities. The aim of this study is to evaluate the histopathological changes that occur in the testicular tissue of adult albino rats after intraperitoneal injection of titanium dioxide nanoparticles and to clarify possible protective role of beta carotene against this toxicity. 48 adult male albino rats weighing 180 to 200 g was divided into 4 groups: (I) *Control group* which consisted of 24 rats divided into 3 equal subgroups (Subgroup Ia (negative control): Received balanced diet for 14 days; Subgroup Ib (positive control): received intraperitoneal injection of distilled water for 14 days; Subgroup Ic: received corn oil by gastric gavage for 21 days (positive control)). *Beta carotene group* (positive control) which consisted of 8 rats received oral beta carotene 10 mg/kg once daily by gastric gavage for 21 days. *The treated group* which consisted of 8 rats received intraperitoneal (IP) injection of TiO₂ nanoparticles (300 mg/kg) daily for 14 days. *The protective group* which consisted of 8 rats received 10 mg/kg beta carotene for 7 days by gavage then intraperitoneal (IP) injection of TiO₂ nanoparticles (300 mg/kg) for 14 days together with 10 mg/kg beta carotene by gavage. Testicular sections were stained with H&E, Masson's trichrome, vimentin immunohistochemical staining. Serum testosterone level along with quantitative real-time PCR for TNF α gene was measured and statistical analysis was done. Results revealed that marked histopathological changes in testicular tissue was observed in TDN treated group which was improved by co-administration of beta carotene. In addition, statistically significant difference in TNF α expression in testicular tissue, testosterone level, body weights, testes weights and sperm count, motility, tubular dimensions, thickness of capsule in TDN treated group compared to the control group and protective group which showed significant improvement. Thus, titanium dioxide nanoparticles have hazardous effect on testis and that can be improved by beta carotene co-administration.

Key words: Adult albino rats, testes, titanium dioxide nanoparticles, β -carotene and gene expression.

INTRODUCTION

Three decades ago, nanotechnology had been significantly flourished and has transitioned from bench

top science to applied technology. Whereas, nanomaterials (NMs) have been widely developed and applied in industry, medicine, cosmetics and personal care products (Shah et al., 2017; Wu and Tang, 2018), nanomaterials are predicted to soon become the cornerstone of the microelectronics, materials, textiles, energy, healthcare, and cosmetics industries (McIntyre, 2012).

The extensive use of nanotechnology raised concern about their adverse effects. There is increasing need to evaluate risk associated with their use, as humans potentially exposed to nanoparticles (NPs) due to their wide use in diagnosis or therapy (Shi et al., 2013; Faddah et al., 2013).

Owing to their minute size, NPs can get an entrée to many biological structures, interacting with molecules such as nucleic acids, proteins and lipids, which may, in turn, meddle with their normal function, damage the subcellular organelles and cause cellular death (Tay et al., 2014).

Nano-sized Titanium dioxide particles are one of the most commonly synthetic nanoparticles (Liang et al., 2009). Titanium dioxide particle is an odorless, low-solubility crystal which has thermal stability and combustibility, excellent physical properties, corrosion resistance, biocompatibility and excellent electrical and optical performance (Morgan et al., 2006).

Titanium dioxide NPs are found in toothpaste, food colorants, candies, sweets and chewing gums (Weir et al., 2012) as well as in sunblock creams for protecting the skin from ultraviolet light (Wiesenthal et al., 2011). They are also used for implanted medical devices as cardiovascular stents, dental implants, joint replacements and spinal fixation devices. However, under mechanical stress or altered physiological conditions such as low pH, titanium-based implants can release large amounts of NPs debris (Cunningham et al., 2002).

Contact to nanoparticle can be either by accident due to occupational exposure, or purposely through different routes such as nose by inhalation, mouth by intake, skin contact or intravenous injection (Zhu et al., 2012).

Carotenoids are yellow or orange, containing organic pigments found in the chloroplasts of plants, some bacteria, and fungi (Altincicek et al., 2011). Beta carotene is the most efficient pro-vitamin A carotenoid which acts as an antioxidant that protect the cells against free radicals, due to its unique structure and cleavage efficacy (Orazizadeh et al., 2014). The present study is aimed at evaluating the possible toxic effect of Titanium dioxide NPs on the structure of the testis of adult albino rats and to determine the protective role of beta carotene to

minimize its toxicity.

MATERIALS AND METHODS

Chemicals

Titanium dioxide NPs (TiO₂NPs) nano powder comes with the following characters: <100 nm particle size, surface area of 35-65 m²/g and purity ≥99.5% trace metals basis and CAS No 634662. It is a white odorless fine powder mixture of rutile and anatase manufactured by Sigma-Aldrich Chemical Company, Germany and purchased from Sigma-Egypt. B-carotene is presented in red orange powder form, obtained from Sigma-Aldrich Chemical Company, Germany and was purchased from Sigma-Egypt with code c 9750. Corn oil was obtained from SEKEM Company, Cairo, Egypt and primers were obtained from Delta Company Egypt.

Animals

The present study was conducted on forty-eight adult male albino rats weighing about 180 g. They were housed in a temperature-controlled and light-controlled room (12-h light/dark cycle), with free access to food and water. All experimental procedures were performed in accordance with the guidelines of the Institutional Animal Care and Use Committee of Faculty of Medicine; Zagazig University, Egypt. The animals were divided equally into 4 groups:

Control group (I): this contains 24 rats and is divided into 3 equal subgroups:

Subgroup Ia (negative control): 8 rats received balanced diet for 14 days.

Subgroup Ib (positive control): 8 rats received intraperitoneal injection of distilled water for 14 days.

Subgroup Ic (positive control): 8 rats received corn oil by gastric lavage for 21 days.

Beta carotene group (II): 8 rats received oral beta carotene 10 mg/kg once daily by gastric lavage for 21 days.

The treated group (III) (TDN group): this contains 8 rats that received intraperitoneal (IP) injection of TiO₂ NPs (300 mg/kg) daily for 14 days (Xu et al., 2013).

The protective group (IV) (TDN+BC group): This contains 8 rats that received 10 mg/kg beta carotene for 7 days by gavage then intraperitoneal (IP) injection of TiO₂ NPs (300 mg/kg) for 14 days together with 10 mg/kg β-carotene by gavage (Lyama et al., 1996). By the end of the experiment, all animals were anesthetized by thiopental inhalation, venous blood samples were collected by means of micro-capillary glass tubes from vein of rat tail for assessment of testosterone level and then animals were sacrificed. Laparotomy was performed and the testis was carefully dissected out and weighed then subjected to histopathological, immunohistochemistry and morphometrical examination.

*Corresponding author. E-mail: amirahamid85@gmail.com Tel: 00201222928151.

Table 1. primers used for Semi-quantitative PCR analysis

Target gene	Primer sequence: 5' - 3'
TNF- α	Forward: 5'- CCACCACGCTCTTCTGTCTAC-3'
	Reverse: 5'-ACCACCAGTTGGTTGTCTTTG-3'
GAPDH	Forward: 5'-AGATCCACAACGGATACATT-3
	Reverse: 5-TCCCTCAAGATTGTCAGCAA-3'

Approach

Testosterone level

Venous blood samples for each animal, about 2 mL were collected into a glass tube for measuring testosterone hormone levels. Blood samples were left for serum separation, and then centrifuged at 3000 r.p.m. for 15 min. Serum samples were collected and kept frozen at -20°C for performing hormonal analysis by using Testosterone Rat/Mouse ELISA (Enzyme-linked immunosorbent assay) (Zirkin and Chen, 2000).

Epididymal spermatozoa examination

Spermatozoa collection was done from the content of the Epididymis of each rat. It was obtained immediately by cutting the tail of the epididymis and squeezing it gently to obtain the fresh undiluted semen in a clean Petri dish to proceed with the following examinations:

Sperm motility: A small droplet of undiluted semen was added to one drop of sodium citrate solution in 2.9-3% on warm slide, several fields were examined under light microscope and incidence of motile sperms were estimated and recorded (Bearden and Flyquary, 1980).

Sperm count: The hemocytometer pipette was used to withdraw the undiluted semen up to the 0.1 mark and was then filled up to the mark 101 by normal saline stained with eosin; thereafter, the pipette content was vigorously shaken by holding the ends of the pipette between the thumb and index finger. A cover slide was placed over the hemocytometer counting chamber and a drop of diluted semen was spread between the hemocytometer chambers and its cover. Thereafter, the sperm were counted in 5 large squares at 400X magnification. Sperm concentration was estimated by multiplying the counted number of sperm by 100 (depth) and 1000 (dilution) (Blazak et al., 1993).

Real time PCR detection of TNF α gene

RNA extraction and cDNA synthesis: For preparation of total RNA, testes (approximately 100 mg per sample) were collected from rats, frozen in liquid nitrogen and subsequently stored at -70°C

in 1 mL Qiazol (QIAGEN Inc., Valencia, CA). Frozen samples were homogenized using a Polytron 300 D homogenizer (Brinkman Instruments, Westbury, NY). Thereafter, 0.3 mL chloroform was added to the homogenate. The mixtures were shaken for 30 s followed by centrifugation at 4°C and 12,500 rpm for 20 min. The supernatant layer was transferred to a new set of tubes and an equal volume of isopropanol was added to the samples, shaken for 15 s and centrifuged at 4°C and 12,500 rpm for 15 min. The RNA pellets were washed with 70% ethanol, briefly dried up, then dissolved in Diethylpyrocarbonate (DEPC) water. The prepared RNA integrity was checked by means of electrophoresis. RNA concentration and purity were determined spectrophotometrically at 260 nm. The ratio of the 260/280 optical density of all RNA samples was 1.7-1.9. For synthesis of cDNA, mixture of 2 μ g total RNA and 0.5 ng oligo dT primer in a total volume of 11 μ L sterilized DEPC water was incubated in the PeX 0.5 thermal Cycler (Thermo Electronic Corporation, Milford, Ma) at 65°C for 10 min for denaturation. Thereafter, 4 μ L of 5X RT-buffer, 2 μ L of 10 mM dNTPs and 100 U Moloney Murine Leukemia Virus (M-MuLV) Reverse Transcriptase (SibEnzyme Ltd. Ak, Novosibirsk, Russia) were added and the total volume was completed up to 20 μ L by DEPC water. The mixture was then re-incubated in the thermal Cycler at 37°C for 1 h, then at 90°C for 10 min to inactivate the enzyme.

Semi-quantitative PCR analysis

Specific primers for tested genes (Table 1) were designed using Oligo-4 computer program and synthesized by Macrogen (Delta Company, Egypt). PCR was conducted in a final volume of 25 μ L consisting of 1 μ L cDNA, 1 μ L of 10 picomolar (pM) of each primer (forward and reverse) and 12.5 μ L PCR master mix (Promega Corporation, Madison, WI); the volume was brought up to 25 μ L using sterilized, deionized water. PCR was carried out using a PeX 0.5 thermal Cycler with the cycle sequence at 94°C for 5 min one cycle, followed by different cycles each of which consisted of denaturation at 94°C for one minute, minute with additional final extension at 72°C for 7 min. As a reference, expression of Glyceraldehyde-3-Phosphate Dehydrogenase (G3PDH) mRNA was detected by using specific primers (Table 1). PCR products were electrophorized on 1% agarose gel (Bio Basic INC. Konrad Cres, Markham Ontario), and stained with ethidium bromide in TBE (Tris-Borate-EDTA) buffer. PCR products were visualized under UV light and photographed using gel documentation system. The intensities of the bands were quantified densitometrical using ImageJ software (El-Kirdasy et al., 2014).

Table 2. Comparison between mean values of testes weights and rat weights in different studied groups.

Parameter	Control	β -Carotene	Titanium	Titanium + β -Carotene	ANOVA
	Mean \pm SD				
Rat weight (g)	215.63 \pm 11.78 ^a	216.25 \pm 10.26 ^a	165.63 \pm 17.20 ^{b***}	200.63 \pm 17.82 ^A	< 0.0001***
Testis weight (g)	1.30 \pm 0.06 ^a	1.30 \pm 0.13 ^a	1.03 \pm 0.03 ^{b**}	1.21 \pm 0.20 ^A	0.0009***

Groups with different letters are statistically significant P value <0.05. Different stages of significance were considered. High significance (***) when P value < 0.001, Moderate significant (**) at 0.01 >P value >0.001 and low significance (*) when 0.05 >P value >0.01.

Histopathological examination

The testes of male albino rats were collected at the end of experiment from tested groups. The samples were fixed in Bouin's solution, then dehydrated in ascending grades of alcohols, cleared in xylene and embedded in paraffin. The samples were casted, then sliced into 5 μ m in thickness and placed onto glass slides. The slides were stained by hematoxylin and Eosin (H&E) stains and Masson's Trichrome (Bancroft and Gamble, 2008).

Immunohistochemical study

Immunohistochemistry was performed following the method of Ramos-Vara et al. (2008). The paraffin sections were processed by Streptavidin-biotin complex (Strep ABC) paraffin deparaffinized in xylene, hydrated and then placed in phosphate buffered saline (PBS; pH 7.6). Antigen retrieval was performed by boiling for 15 min in citrate buffer (0.01 M). Sections were treated with 3% hydrogen peroxide for 5 min to quench endogenous peroxidase activity, rinsed with deionized water and then washed with PBS. Sections were incubated first with 1% pre-immune rabbit serum to decrease non-specific staining and then with a monoclonal antibody against Vimentin (Dako, Carpinteria CA, USA) at 23°C in a moist chamber for 1 h. Detection of the antibody was performed using a biotin-streptavidin detection system (Bio Genex, San Ramon CA, USA) with 3-amino 9-ethyl carbazole (AEC) as chromogen (Dako, Carpinteria CA, USA). Sections were counterstained with Mayer's hematoxylin and sections were evaluated using a light microscope.

Morphometric study

The morphometric study was done using Image analyzer software (Leica Imaging System Ltd., Cambridge, England). Ten readings were obtained in each specimen and the mean values were obtained. According to this method, we used an optical magnification of 100 for calculating the mean tubular diameter, epithelial height and interstitial space thickness, and tunica albuginea thickness were performed on routine H&E sections while thickness of capsule was performed on sections stained with Masson's trichrome.

Statistical analysis

Results are expressed as means \pm S.D of 8 different rats per each group. Statistical analysis was done using ANOVA with p<0.05 being considered as statistically significant.

RESULTS

Body weight

Regarding weight of rats, titanium treated group showed significant decrease than all other groups. Moreover, there is no significant difference between control and both β -carotene and β -carotene in combination with titanium (Table 2).

Testis weight

Considering testicular weight, titanium group showed significant decrease than all other groups. Although, β -Carotene and β -Carotene in combination with titanium showed non-significant difference with control group (Table 2).

Laboratory results

There was non-significant difference in sperm count between both control and β -Carotene groups; sperm count of Titanium treated group was significant less than control and β -Carotene groups. Moreover, on administration of beta carotene in combination with titanium, sperm count is significantly less than control but significantly more than treated (Table 3).

As regards both sperm motility and testosterone level, there is significant decrease in Titanium treated group in comparison to all other groups. Moreover, in the group protected by β -Carotene, sperm count was significantly less than control but significantly more than treated (Table 3).

Considering TNF α , there was non-significant difference between control, β -Carotene and Titanium + β -Carotene groups, but titanium treated group was significantly increased in comparison with all other groups (Table 3).

Histopathological examination

Hematoxylin and eosin (H&E)

Examination of H&E sections obtained from testis in

Table 3. Comparison between mean values of sperm count, motility, testosterone and TNF α in different studied groups.

Parameter	Control	β -Carotene	Titanium	Titanium + β -Carotene	ANOVA
	Mean \pm SD				
Sperm count (million/mm ³)	24.75 \pm 4.53 ^a	24.50 \pm 3.74 ^a	10.58 \pm 2.02 ^{b***}	16.19 \pm 3.25 ^{c***}	< 0.0001***
Sperm motility (%)	85.63 \pm 5.73 ^a	84.63 \pm 7.03 ^a	37.50 \pm 9.64 ^{b***}	63.75 \pm 8.35 ^{c***}	< 0.0001***
Testosterone (μ g/ml)	4.25 \pm 0.59 ^a	4.28 \pm 0.42 ^a	1.72 \pm 0.48 ^{b***}	3.22 \pm 0.66 ^{c**}	< 0.0001***
TNF α	1.025 \pm 0.35 ^a	1.03 \pm 0.18 ^a	1.60 \pm 0.21 ^{b**}	1.21 \pm 0.36 ^A	0.0006

Groups with different letters are statistically significant P value <0.05. Different stages of significance were considered. High significance (***) when P value < 0.001, Moderate significant (**) at 0.01 >P value >0.001 and low significance (*) when 0.05 >P value >0.01.

Table 4. Comparison between mean values of seminiferous tubule diameter, germinal epithelium thickness, interstitial space thickness, basement membrane thickness, *Tunica albuginea* thickness.

Parameter	Control	β -Carotene	Titanium	Titanium + β -Carotene	ANOVA
	Mean \pm SD				
Seminiferous tubule diameter (μ m)	233.03 \pm 12.43 ^A	229.37 \pm 18.01 ^a	123.59 \pm 9.97 ^{b***}	165.83 \pm 14.68 ^{c***}	<0.0001***
Germinal epithelium thickness (μ m)	58.62 \pm 6.89 ^A	59.77 \pm 5.11 ^a	36.30 \pm 6.30 ^{b***}	47.41 \pm 6.35 ^{c**}	<0.0001***
Interstitial space thickness (μ m)	9.81 \pm 1.62 ^A	9.60 \pm 1.19 ^a	18.91 \pm 3.40 ^{b***}	10.15 \pm 1.42 ^A	<0.0001***
Tunica albuginea thickness (μ m)	12.79 \pm 1.87 ^a	12.15 \pm 1.32 ^a	62.34 \pm 12.79 ^{b***}	15.21 \pm 4.05 ^a	<0.0001***
Vimentin OD	0.671 \pm 0.177 ^a	0.670 \pm 0.145 ^a	0.273 \pm 0.058 ^{b***}	0.554 \pm 0.094 ^a	<0.0001***

Groups with different letters are statistically significant P value <0.05. Different stages of significance were considered. High significance (***) when P value < 0.001, Moderate significant (**) at 0.01 >P value >0.001 and low significance (*) when 0.05 >P value >0.01.

control group revealed normal seminiferous tubules lined by stratified germinal epithelium. Spermatozoa were observed in the lumina of the tubules (Figure 1a).

The germinal epithelium revealed two types of cells; spermatogenic and Sertoli. Sertoli cells were detected in-between spermatogenic cells as pyramidal cells. The spermatogenic cells were seen in regularly arranged rows at different stages of spermatogenesis. They were arranged from the basal compartment to the lumina of the tubules starting from spermatogonia, primary spermatocytes, and spermatids till mature spermatozoa in the lumen (Figure 1b).

On the other hand, examination of H&E sections obtained from testes in treated group demonstrated highly congested sub-capsular blood vessel (Figure 2a). Other sections showed loss of normal hexagonal uniform of seminiferous tubules. They appeared with irregular contour with detached and separated basement membrane (Figure 2c).

Others tubules showed detached germinal epithelium from basement membrane (Figure 2a) and loss of layers of germinal epithelium (Figure 2b). And others exhibited disorganized germinal epithelium with darkly stained pyknotic nuclei and vacuolation within seminiferous tubule (Figure 2d).

Lumina of some tubules appeared either empty or with many sloughed germinal cells and deposition of hyaline

acidophilic material in interstitium and some acidophilic material also appeared in the lumina of some seminiferous tubules (Figure 2b).

Examination of H&E sections obtained from testes in the protective group demonstrated wide areas of testicular tissue similar to the examined control sections. Most seminiferous tubules had nearly normal architecture lined by stratified germinal epithelium formed of several layers. Their lumina of some of them showed aggregated spermatozoa and few seminiferous tubules lined by disorganized detached germinal epithelium from basement membrane (Figure 3a, b and d). Other section revealed congested blood vessels between seminiferous tubules (Figure 3c).

Masson's trichrome stain

Masson's trichrome stained sections of control group revealed normal distribution of collagen fibers in the testicular capsule and around the blood vessels (Figure 4a), while stained sections obtained from treated group revealed marked increase of collagen fibers in the capsule and around blood vessels (Figure 4b).

On the other hand, Masson's trichrome stained sections obtained from protective group revealed mild increase of collagen fibers in testicular capsule and

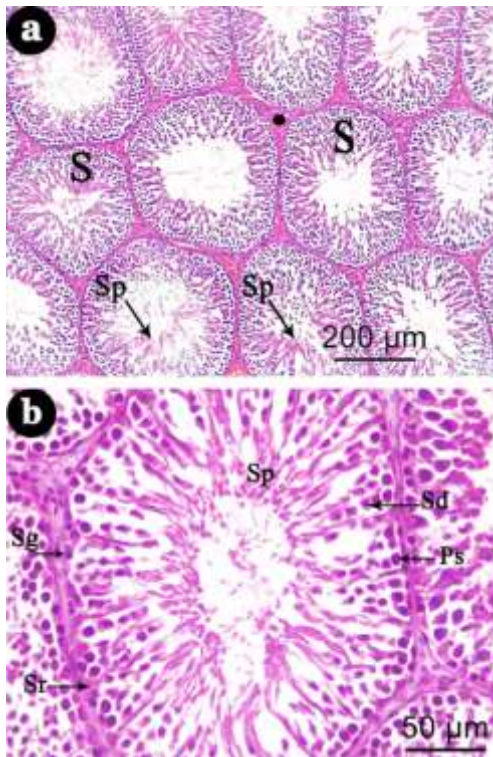


Figure 1. (a) A photomicrograph of a section of control adult albino rat testis showing oval to round closely packed seminiferous tubules (S) with little interstitial tissues in between (black dot) and cavity full of sperms (Sp). (H&E $\times 100$). (b): A photomicrograph showing seminiferous tubules lined by Sertoli cells appeared pyramidal cells with pale nucleus (Sr) and different germ cells namely, spermatogonia were seen close to the basement membrane with their dark nuclei (Sg), primary spermatocyte were the largest cells (Ps) spermatids appeared smaller than primary spermatocytes and lying near the lumen (Sd) and spermatozoa (Sp) from outward inward. (H&E $\times 400$).

around blood vessels (Figure 4c).

Vimentin immunostaining

Vimentin immunostaining testicular section of the control group showed Vimentin prominently expressed in the Sertoli cells with clear continuity between both Sertoli cells' apical and basal segments (Figure 5a). Vimentin immunostaining of testicular section of the treated group showed Sertoli cells destruction exhibited clearly. There was nearly complete destruction of the apical segment of Sertoli cells with scarce appearance of basal segment in most of tubules (Figure 5b).

However, Vimentin immunostaining of testicular section of protective group showed moderate improvement with

conservation of the vimentin expression pattern of the control in some Sertoli cells with apical and basal segments. However, few Sertoli cells showed some destruction (Figure 5c).

Morphometrical results

There is non-significant difference in tubular diameter and germinal epithelium thickness between control and β -Carotene groups. Tubules of titanium treated group were significant less than control and β -Carotene groups. Moreover, on administration of beta carotene in combination with titanium, tubular diameter is significantly less than control but significantly more than treated. (Table 4).

Considering interstitial space thickness and tunica albuginea, there is non-significant difference in between control and β -Carotene and Titanium + β -Carotene groups. Interstitial space thickness of Titanium treated group was significant more than all other groups. (Table 4).

There is non-significant difference in Vimentin OD (Optical Density) between control, beta carotene and Titanium + β -Carotene groups. Vimentin OD in titanium treated group was significant less than all other groups. (Table 4).

DISCUSSION

The testes are the most vital organs of the male reproductive system and are highly sensitive to genetic, hormonal and environmental insults (e.g., X-ray exposure, infectious diseases, and toxicants) (Lewis and Aitken, 2005), as it possess highly sensitive cellular composition of the spermatogenic epithelium and the high rate of mitotic activity (EL Shafai et al., 2011).

Rats have well-defined reproductive systems and the compounds which can cause infertility in human males were also noticed to be active in rats (Cho et al., 2014).

In this study, Titanium dioxide was injected by i.p route. The drug absorption by i.p injection is good and rapid because of the intensive blood and lymph vessels in the peritoneum beside its large surface area, thus the drug easily reached the circulation. Moreover, injection can avoid the common gastrointestinal side effects related to oral route of administration (Nebendahl, 2000). Moreover, Shi et al. (2013) used intraperitoneal method to evaluate the possible toxic effects of TiO_2 NPS used in nanomedicine.

β -carotene is a precursor of vitamin A which acts as potent antioxidant agent that blocks the free radicle formation or scavenges them (Yüncü et al., 2015). The present study was designed to investigate protective effect of β -carotene on TNP-induced testicular damage.

Regarding the effect of TiO_2 on body weights, our

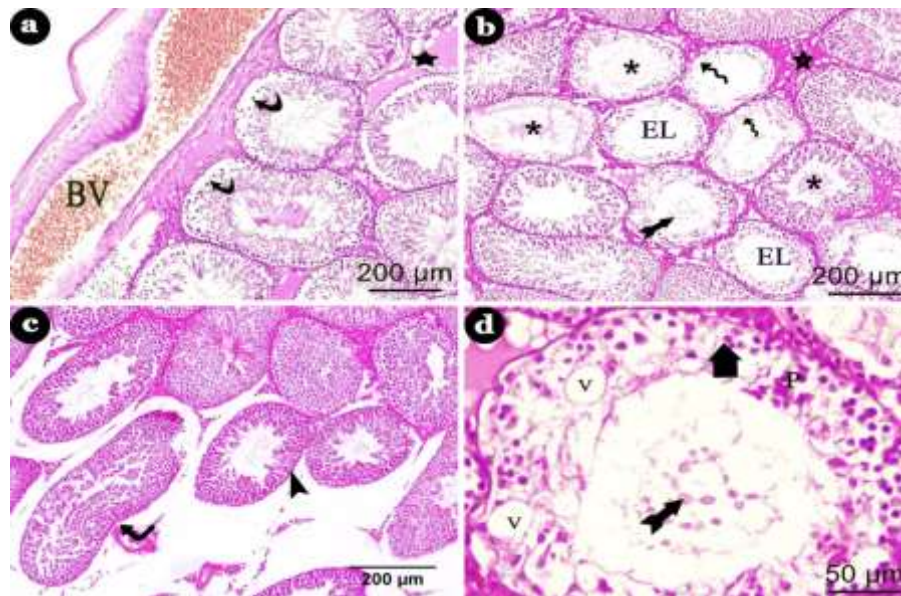


Figure 2. (a) A photomicrograph of a section of adult male albino rat testis of the TiO_2 treated group showing highly congested sub-capsular blood vessel (BV) some seminiferous tubules showing detached germinal epithelium from basement membrane (curved arrow) and vacuolated acidophilic material in interstitium (star). (H&E $\times 100$) (b) A photomicrograph showing some shrunken tubules with different shape and irregular outlines (head of arrow) also with irregular corrugated outline (bent arrow) (H&E $\times 100$). (c) A photomicrograph showing distorted lining of some seminiferous tubules and loss of some layer of germinal epithelium (wavy arrow), sloughing of some cells in the lumen (thick tailed arrow) other tubule show empty lumen (EL) acidophilic hyaline material appears in the lumen of some seminiferous tubules (astrike) and interstitium (star) (H&E $\times 100$). (d) A photomicrograph showing disorganized germinal epithelium (thick short arrow) with marked vacuolation (V), dark pyknotic nuclei (P), and sloughing of some cells in the lumen (thick tailed arrow) (H&E $\times 400$).

results revealed that rats fed on TiO_2 had lowered mean value of body weights compared with that of the control group; this result is in agreement with Khayal et al. (2019) who observed that Titanium dioxide NPS treated rats revealed a significant reduction in body weight in comparison with other groups. El-Sharkawy et al. (2010) explained that the weight loss is paralleled with anorexia, depression, and white feces among the different dose levels of TiO_2 treated male rats along the experimental period.

Protective group showed a significant increase in body weight in comparison to TDN treated group; this result is in disagreement with Orazizadeh et al. (2014) who reported that the body weight in all groups (control group, TDN treated group and TDN + BC group) was the same and no difference was detected between them.

This study revealed that rats fed on TiO_2 had lowered mean value of testicular weights; this result is in agreement with Morgan et al. (2015) who observed significant decrease in relative testis weights after 8 weeks of TiO_2 exposure. Contrary to our results, Jia et al. (2013) found no significant difference in absolute or

relative weights of testes and epididymides between TDN-exposed mice and control group after oral exposure to 10, 50 and 250 mg/kg/day TDN (25 nm) for 42 days, but in protective group there was significant increase in testis weight in comparison to TND intoxicated group; this result is in agreement with Orazizadeh et al. (2014) who also observed significant increase in testis weight in BC + TDN group in comparison with TND treated group.

This discrepancy between our results and the previous literatures concerning the suppressive effect of TDN on body and sex organs weights could be related to particle size, species, strain, route, dose and duration of exposure variation.

This study revealed that intraperitoneal administration of TDN resulted in a significant decrease in serum testosterone level and reduction in sperm count and sperm motility compared to control. This is consistent with Karimi et al. (2019) who reported that there was significant reduction in testosterone concentration in the TiNO_2 treated animals. However, in the protective group there was significant increase in testosterone level and sperm count; this result is in agreement with Orazizadeh

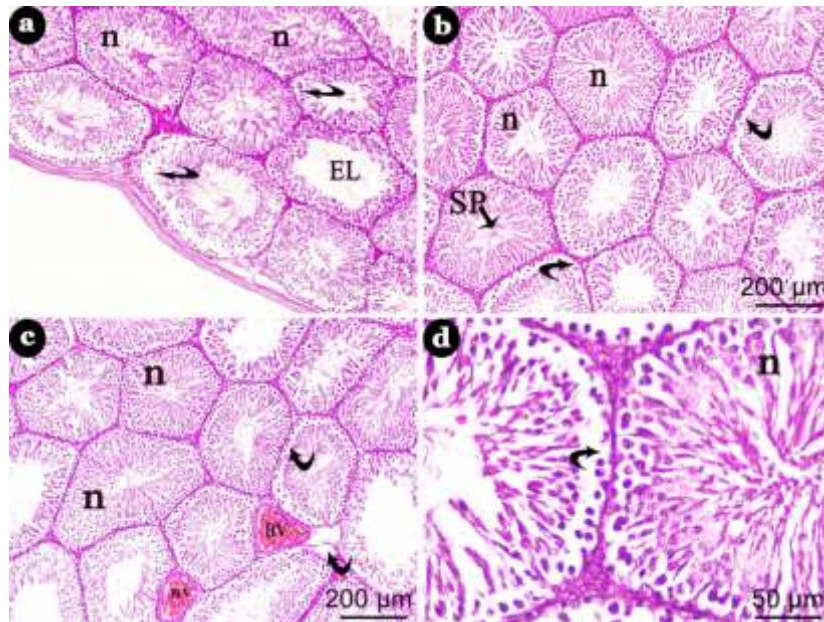


Figure 3. (a) A photomicrograph of a section of adult male albino rat testis of the TiO₂&beta carotene treated group showing some tubules appear normal (n) while others appear affected with detached germinal epithelium (curved arrow) and some tubule appear with empty lumen (EL) (H&E ×100). (b) A photomicrograph showing tubules with disorganized detached germinal epithelium from basement membrane (curved arrow) between others appear normal (n) with aggregation of sperms in the lumen (SP) (H&E ×100). (c) A photomicrograph showing few disorganized seminiferous tubules with detachment of spermatogenic cell (curved arrow) between many normal seminiferous tubules (n) and congested blood vessels between seminiferous tubules (BV) (H&E ×100). (d) A photomicrograph showing seminiferous tubules lined by detached germinal epithelium from basement membrane (curved arrow) and another tubule showing nearly normal organization of seminiferous tubule (n) (H&E ×400).

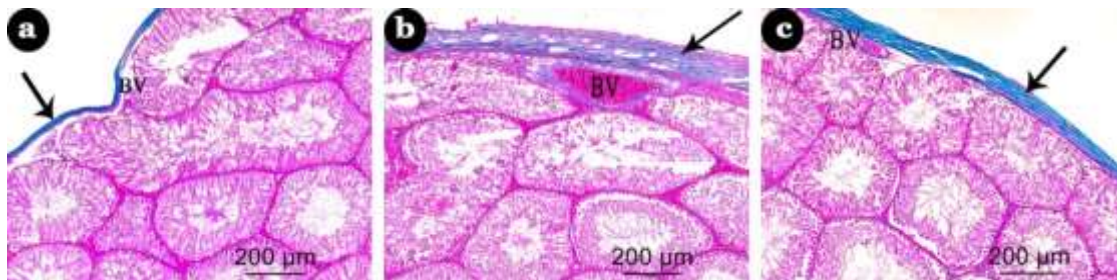


Figure 4. (a) A photomicrograph of a section of the testis of an adult male albino rat of control group showing normal distribution of collagen fibers in the capsule (arrow) and around blood vessels (BV) (Masson's trichrome ×100). (b) Photomicrograph of a section of the testis of an adult male albino treated group showing marked increase of collagen fibers in the capsule (arrow) and around the blood vessels (BV). (Masson's trichrome ×100) (c) Photomicrograph of a section of the testis of an adult male albino rat protective group showing mild increase of collagen fibers in the capsule (arrow) and around blood vessels (BV) (Masson's trichrome ×100).

et al. (2014) who reported that BC elevated the testosterone concentration in TDN-intoxicated mice, Sofikitis et al. (2008) assumed that the protection in

gametogenic activity in BC pre-treated mice may be the result of restoration of testicular androgenesis, as androgen is a prime regulator of gametogenesis.

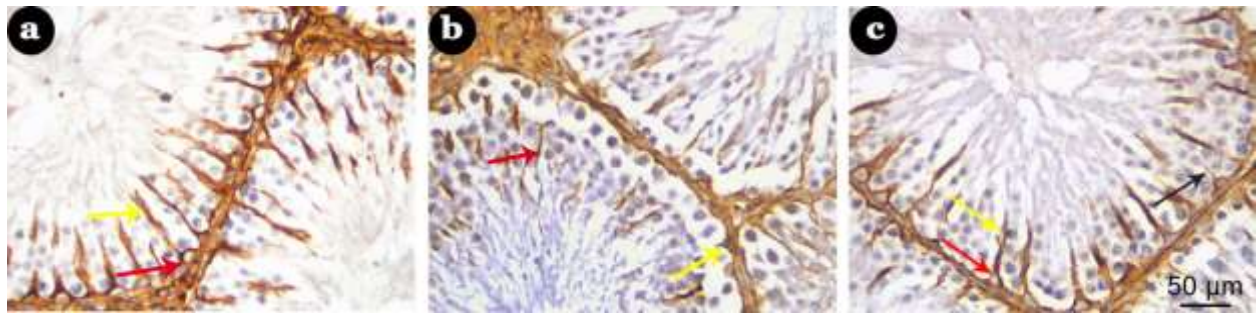


Figure 5. (a) A photomicrograph of testicular section of the control group showing Vimentin prominently expressed in the Sertoli cells with clear continuity between both Sertoli cells apical (yellow arrow) and basal segments (red arrow) (Vimentin X400). (b) A photomicrograph of testicular section of the treated group showing Sertoli cells destruction exhibited clearly, there was nearly complete destruction of the apical segment of Sertoli cells (red arrow) with scarce appearance of basal segment in most of tubules (yellow arrow) (Vimentin x400). (c) A photomicrograph of testicular section of protective group showing conservation of the vimentin expression pattern of the control in some Sertoli cells with apical (yellow arrow) and basal segments (red arrow). However, few Sertoli cells still showing some destruction (arrow) (Vimentin x400).

In our study, administration of TiO_2 to rats increased $TNF-\alpha$ expression in testes and their expression was normalized in rats administered β carotene together with TiO_2 . This result is in agreement with El-Kirdasy et al.

(2014) who mentioned that TiO_2 induced oxidative stress and increased IL-6 and $TNF-\alpha$ expression in testes and their expression was normalized in protective group. It is also in agreement with Khayal et al. (2019) who reported that the rats treated with TiO_2 NPs showed significant elevations of IL6 and $TNF-\alpha$ levels with significant reduction in IL10 in the ileal tissue compared to other groups.

In this study, normal architecture of the seminiferous tubules and intact germinal epithelium were observed in BC (β - carotene) group. This result in agreement with Orazizadeh et al. (2014); also, there was no difference in the histopathology criteria between BC and control groups.

In the present study, H&E stained sections of the testis of treated group revealed highly congested sub capsular blood vessel, distortion and loss of normal organization of the seminiferous tubules. Moreover, some tubules appeared shrunken and had variable shapes with irregular outlines and wide spacing from each other. Detachment of germinal epithelium from the underlying basement membrane and disorganized epithelial lining with marked depletion in germ cell number were noticed. Some tubules showed wide empty lumens while others showed exfoliation of germ cells within their lumens. This result in agreement with Karimi et al. (2019) who observed that in the TiO_2 NPs treated group there were disorganization, detachment, sloughing and atrophy of germ cell layer.

In this study, the testis in β -Carotene and TiO_2 administered rats showed partial improvement in the testicular tissue, some of seminiferous tubules nearly

retained their normal architecture, they revealed regular rounded contour and were lined by healthy germinal epithelium showing several types of spermatogenic cells and lumens contained aggregations of sperms and other seminiferous tubules lined by disorganized germinal epithelium, acidophilic hyaline material appears in interstitium and seminiferous tubules and mild congestion of the testicular blood vessels still persist; these results are in agreement with Orazizadeh et al. (2014).

In this study, Vimentin immunostaining in control group showed distinct expression of Vimentin in Sertoli cell cytoplasm. Vimentin positive reaction was found around the nucleus with apical extensions projecting towards the developing spermatids, a result that is in agreement with Alam and Kurohmaru (2014); however, in treated group, Sertoli cells showed loss of vimentin apical extensions towards the lumen, with the perinuclear condensation preserved and is in agreement with those of Dalgaard et al. (2000, 2001) who suggested that this alteration may be related to fragmentation of vimentin filaments into small subunits which become collected in the perinuclear region. As vimentin filaments of sertoli cells play an important role in the maintenance of spermatogenesis, therefore any alteration in the distribution of vimentin filaments correlate with sloughing of spermatogenic cells from the seminiferous epithelium (Zhu et al., 2010). The protective group showed conservation of the expression pattern of the control in most of sertoli cells. However, some sertoli cells showed loss of vimentin apical extensions towards the lumen, results that were consistent with Erkekoglu et al. (2011).

As regards Masson's trichrome, staining sections from control group revealed normally distributed collagen fibers in the capsule and around blood vessels, results that were in agreement with those described by Abd Ellatief et al. (2015); but in treated group revealed marked

increase of collagen fibers especially in the capsule and around blood vessels; this result is in accordance with Salem et al. (2017) and Altindag et al. (2007) who proposed that the increased collagen fibers are due to the decrease in collagen metabolism that may be related with oxidative stress. In protective group, there was normal distribution of collagen fibers especially in testicular capsule and around blood vessels, a result that is in agreement with Gopal et al. (2015).

Regarding this study, BC has an ameliorating effect against TDN induced testicular germ cell damage. BC may be a valuable protective agent to ameliorate spermatogenesis dysfunction and cell loss; also, BC treatment increased the weight of testis, serum testosterone and sperm count.

Conclusion

Taken together, the results of this study revealed that TiO₂NPs induced histological, genetic and immuno-histochemical abnormalities in testis of adult albino rats. Beta carotene improved the changes associated with TiO₂NPs administration. This study supports the usage of beta carotene as a protective agent against the toxic effects of TiO₂NPs.

Recommendation

Much more attention should be paid for limiting the occupational and environmental exposure to TiO₂NPs by continuous monitoring of TiO₂NPs level in work environment and keeping it within the recommended exposure limits and increased awareness about the health hazards caused by TiO₂NPs. Moreover, highly exposed individuals are advised to take β-Carotene supplementation to limit the toxic effects of TiO₂NPs on the testes. In addition, toxicity studies should be done to clarify the mechanisms of TiO₂NPs's toxicity.

CONFLICT OF INTERESTS

The authors have not declared any conflict of interests.

REFERENCES

- Abd Ellatief RB, Elgamal DA, Mohamed EEM (2015): Effects of chronic tramadol administration on testicular tissue in rats: an experimental study. *Andrologia* 47(6):674-679.
- Alam MS, Kurohmaru M (2014). Disruption of Sertoli cell vimentin filaments in prepubertal rats: an acute effect of butylparaben in vivo and in vitro. *Acta histochemica* 116(5):682-687.
- Altincicek B, Kovacs JL, Gerardo NM (2011). Horizontally transferred fungal carotenoid genes in the two-spotted spider mite *Tetranychus urticae*. *Biology Letters* 8(2):253-257.
- Altindag O, Erel O, Aksoy N, Selek S, Celik H, Karaoglanoglu M (2007): Increased oxidative stress and its relation with collagen metabolism in knee osteoarthritis. *Rheumatology International* 27(4):339-344.
- Bancroft J, Gamble M (2008). *Theory and practice of Histological technique* (6 th Ed), Churchill Livingstone, New York, Edinburgh London pp. 165-175.
- Bearden HJ, Fuquay J (1980). *Applied Animal Reproduction*. Reston publishing Co. Inc. Reston, Virginia pp. 158-160.
- Blazak WF, Treinen KA, Juniewicz PE (1993). Application of testicular sperm head counts in the assessment of male reproductive toxicity. In: Chapin RE and Heindel J (editors). *Male Reproductive Toxicology*. New York: Academic Press 3:86-105.
- Cho PN, Hashim NH, Hasan ADS (2014). Effects of nigella sativa (Habbatus sauda) oil and nicotine chronic treatments on sperm parameters and testis histological features of rats. *Evidence-Based Complementary and Alternative Medicine*.
- Cunningham BW, Orbegoso CM, Dmitriev AE, Hallab NJ, Seftor JC, McAfee PC (2002). The effect of titanium particulate on development and maintenance of a posterolateral spinal arthrodesis: an *in vivo* rabbit model. *Spine* 27(18):1971-1981.
- Dalgaard M, Lam RL, Ladefoged O, Nellesman C, Sorensen KI (2001). The acute effects of mono (2- ethylhexyl) phthalate (MEHP) on testes of prepubertal rats. *Toxicology Letters* 122(1):69-79.
- Dalgaard M, Ostergaard G, Lam RL, Hansen EV, Ladefoged O (2000) Toxicity study of di (2- ethylhexyl) phthalate (DEHP) in combination with acetone in rats. *Pharmacology and toxicology* 86(2):92-100.
- EL Shafai A, Zohdy N, EL Mulla K, Hassan M, Morad, N (2011). Light and electron microscopic study of the toxic effect of prolonged lead exposure on the seminiferous tubules of albino rats and the possible protective effect of ascorbic acid. *Food and chemical toxicology* 49:734-743
- El-Kirdasy FA, Nassan AM, Baiomy AA, Ismail AT, Soliman MM, Attia FH (2014). Potential ameliorative role of n-acetylcysteine against testicular dysfunction induced by Titanium dioxide in male albino rats. *American Journal of Pharmacology and Toxicology* 9(1):29-38.
- El-Sharkawy NI, Hamza SM, Abou-Zeid EH (2010). Toxic impact of Titanium dioxide (TiO₂) in male albino rats with special reference to its effect on reproductive system. *Journal of American Science* 6(11):865-872.
- Erkekoglu P, Rachidi W, Yuzugullu OG, Giray B, Ozturk M, Favier A (2011): Induction of ROS in DEHP- and MEHP-exposed LNCaP cells-protection by selenium compounds. *Food and Chemical Toxicology* 49(7):1565-1571.
- Faddah LM, Abdel BNA, Al-Rasheed NM (2013) Biochemical responses of nanosize Titanium dioxide in the heart of rats following administration of idepenone and quercetin. *African Journal of Pharmacy and Pharmacology* 7(38):2639-2651.
- Gopal K, Gowtham M, Sachin S, Ram MR, Shankar EM, Kamarul T (2015). Attrition of hepatic damage inflicted by angiotensin II with α-tocopherol and β-carotene in experimental apolipoprotein E knock-out mice. *Scientific Reports* 5:18300.
- Jia F, Sun Z, Yan X, Zhou B, Wang J (2013). Effect of pubertal nano-TiO₂ exposure on testosterone synthesis and spermatogenesis in mice. *Archives of Toxicology* 88(3):781-788.
- Karimi S, Khorsandi L, Nejaddeshbashi F (2019): Protective effects of Curcumin on testicular toxicity induced by Titanium dioxide NPS in mice. *JBRA Assisted Reproduction* 23(4):344.
- Khayal E, Amin D, Shabana M (2019): The Possible Protective Role of N-Acetyl Cysteine against Titanium dioxide Nanoparticles Intestinal Toxicity in Adult Male Albino Rats. *Ain Shams Journal of Forensic Medicine and Clinical Toxicology* 33(2):59-69.
- Lewis SE, Aitken RJ (2005): DNA damage to spermatozoa has impacts on fertilization and pregnancy. *Cell and Tissue Research* 322(1):33-41.
- Liang G, Pu Y, Yin L, Liu R, Ye B, Su Y, Li Y (2009). Influence of different sizes of Titanium dioxide Nanoparticles on hepatic and renal functions in rats with correlation to oxidative stress. *Journal of Toxicology and Environmental Health* 72(11-12):740-745.
- Lyama T, Takasuga A, Azuma M (1996). Beta-carotene accumulation in

- mouse tissues and a protective role against lipid peroxidation. *Journal International De Vitaminologie et de Nutrition* 66(4):301-305.
- McIntyre RA (2012). Common nano-materials and their use in real world applications. *Science Progress* 95(1):1-22.
- Morgan AM, MI AEH, Noshay PA (2015). Reproductive toxicity investigation of Titanium dioxide nanoparticles in male albino rats. *World Journal of Pharmaceutical Sciences* 4(10):34-49.
- Morgan G, Mihail M, Murray M (2006): Hepatic physiology and anesthetics. In: *Clinical Anesthesiology*. Fourth edition, Lange Medical Books, McGraw-Hill pp. 708-716.
- Nebendahl K (2000). Routes of administration. In: Krinke GJ, editor. *The handbook of experimental animals: the laboratory rat*, 1st ed. Ch 24. Academic Press, New York pp. 463- 483.
- Orazizadeh M, Khorsandi L, Absalan F, Hashemitabar, M, Daneshi E (2014). Effect of beta-carotene on titanium oxide nanoparticles-induced testicular toxicity in mice. *Journal of Assisted Reproduction and Genetics* 31(5):561-568.
- Ramos-Vara JA, Kiupel M, Baszler T, Bliven,L, Brodersen B,Chelack B, Czub S, Del Piero F, Dial S, Ehrhart EJ, Graham T, Manning L, Paulsen D, Valli VE, West K(2008). Suggested guidelines for immunohistochemical techniques in veterinary diagnostic laboratories. *Journal of Veterinary Diagnostic Investigation* 20:393-413.
- Salem MM, Altayeb ZM, El-Mahalaway AM (2017). Histological and Immunohistochemical Study of Titanium dioxide Nanoparticle Effect on the Rat Renal Cortex and the Possible Protective Role of Lycopene. *Egyptian Journal of Histology* 40(1):80-93.
- Shah SNA, Shah Z, Hussain M, Khan M (2017). Hazardous effects of Titanium dioxide nanoparticles in ecosystem. *Bioinorganic Chemistry and Applications*.
- Shi H, Magaye R, Castranova V, Zhao J (2013).Titanium dioxide nanoparticles: a review of current toxicological data. *Particle and Fibre Toxicology* 10(1):15.
- Sofikitis N, Giotitsas N, Tsounapi P, Baltogiannis D, Giannakis D, Pardalidis N (2008).Hormonal regulation of spermatogenesis and spermiogenesis. *The Journal of Steroid Biochemistry and Molecular Biology* 109(3-5):323-330.
- Tay CY, Fang W, Setyawati MI, Chia SL, Tan KS, Hong CHL, Leong D T (2014). Nano-hydroxyapatite and nano-Titanium dioxide exhibit different subcellular distribution and apoptotic profile in human oral epithelium. *ACS Applied Materials and Interfaces* 6(9):6248-6256.
- Weir A, Westerhoff P, Fabricius L, Hristovski K, Von Goetz N (2012). Titanium dioxide nanoparticles in food and personal care products. *Environmental science and technology* 46(4):2242-2250.
- Wiesenthal A, Hunter L, Wang S, Wickliffe J, Wilkerson M (2011). Nanoparticles: small and mighty. *International Journal of Dermatology* 50(3):247-254.
- Wu T, Tang M (2018). The inflammatory response to silver and Titanium dioxide nanoparticles in the central nervous system. *Nanomedicine* 13(2):233-249.
- Xu J, Shi H, Ruth M, Yu H, Lazar L, Zou B, Yang C, Wu A, Zhao J (2013): Acute toxicity of intravenously administered Titanium dioxide nanoparticles in mice. *PLoS ONE* 8(8).
- Yüncü M, Bükücü N, Bayat N, Sencar L, Tarakçıoğlu M (2015) .The effect of vitamin E and L-carnitine against methotrexate-induced injury in rat testis. *Turkish Journal of Medical Sciences* 45(3):517-525.
- Zhu M, Li Y, Shi J, Feng W, Nie G, Zhao Y (2012).Exosomes as extrapulmonary signaling conveyors for nanoparticle-induced systemic immune activation. *Small* 8(3):404-412.
- Zhu XB, Tay TW, Andriana BB, ALAM MS, Choi EK, Tsunekawa N, Kurohmaru M (2010). Effects of di-iso-butyl phthalate on testes of prepubertal rats and mice. *Okajimas Folia Anatomica Japonica* 86(4):129-136.
- Zirkin BR, Chen H (2000). Regulation of Leydig cell steroidogenic function during aging. *Biology of Reproduction* 63(4):977-981.