

Full Length Research Paper

A novel green approach for the treatment of immature *Schistosoma mansoni* infection in mice with; Arabic gum (*Acacia senegal*); an antischistosomal agent

**Rabab Selem¹, Samia Rashed¹, Mohammad Younis¹, Boshra Hussien², Fatma Mohamed³,
Awatif Edrees², Asmaa EL-kholy¹, Gehan Rashed¹, Shereen Kishik^{1*}, Ahlam Moharm¹, Marwa
Nageeb¹ and Manal Kardoush¹**

¹Department of Parasitology, Faculty of Medicine, Benha University, Farid Nada Street, Banha, Egypt.

²Tropical Medicine Department, Faculty of Medicine, Tanta University, Tanta, Egypt.

³Tropical Medicine Department, Faculty of Medicine, Al-Azhar University, Cairo, Egypt.

Received 19 October, 2018: Accepted 8 November, 2018

Praziquantel (PZQ), the only common schistosocidal drug in use, is not efficacious for treatment of immature schistosomiasis infection. Arabic gum (AG) is a complex polysaccharide that acts as an antioxidant which modulates the inflammatory and/or immunological processes. This study explores for the first time, the antischistosomal properties of AG in mice infected with the immature stage of *Schistosoma mansoni* (*S. mansoni*). Mice were divided into four groups: control group (infected non-treated), AG treated group, PZQ treated group, and AG+PZQ treated group. Oral administration of AG in a dose of 1 g/kg body weight, daily for 3 consecutive weeks post-infection (PI) resulted in a statistically significant (P-value 0.002 and 0.008 respectively) lower worm burden in both AG group and AG+PZQ group compared to PZQ and control groups. AG+PZQ group always showed the best results when compared with other groups regarding tissue egg load and oogram pattern. AG, both alone and in combination with PZQ, decreased the granuloma number and diameter; with increasing the cellularity and the number of degenerated *Schistosoma* eggs inside granulomas. Results obtained by this work elucidated a promising AG bioactivity against *S. mansoni* immature stages and provided a platform for subsequent experimental studies to illuminate the academia more about this novel and "green" antischistosomal agent.

Key words: *Schistosoma mansoni*, immature stages, Arabic gum, antischistosomal agents, mice.

INTRODUCTION

Schistosomiasis is the most common disease caused by parasitic worms, known as blood flukes, it affects over 240 million people around the world with almost 800

million at risk of infection (Steinmann et al., 2006). Serious consequences and disabilities might result from untreated schistosomiasis such as chronic malnutrition, anemia,

*Corresponding author. E-mail: dr.shereen_kishik@yahoo.com, shereen.kishik@fmed.bu.edu.eg.

organ scarring and fibrosis (King and Dangerfield, 2008).

Control of such long-term morbidity is a priority of the World Health Organization (WHO); it adapts a preventive strategy via mass drug administration campaigns (Taylor, 2008). Praziquantel is the drug of choice for treating all species of *Schistosoma*. Unfortunately, some strains have developed a resistance against it making their treatment a challenge (Ribeiro-dos-Santos et al., 2006; Wang et al., 2012). Although praziquantel is highly effective against adult *Schistosoma* and very early stage of schistosomula just few hours after penetration into the host's skin, it is much less effective against young developing stages of schistosomula (Doenhoff et al., 2008). Thus, it is essential to develop a new irresistible alternative which lacks the aforementioned drawbacks (Botros et al., 2003). AG is a dried exudate obtained from stems and branches of *Acacia senegal* (Leguminosae), consisting of calcium, magnesium, and potassium salts of the polysaccharide AG acid (Rehan et al., 1985). It has been used in Arabic folk medicine to treat patients suffering from chronic renal failure as it decreases the requirements as well as the frequency of hemodialysis (Al-Majed et al., 2002). US Food and Drug Administration have listed AG as one of the safest dietary fibers (Anderson, 1986).

Different studies showed that AG can modulate the transforming growth factor beta 1 (TGF- β 1) generation and function (Matsumoto, 2006), stimulated mouse dendritic cells (Xuan et al., 2010), control chemical plaque in subjects with gingivitis (Pradeep et al., 2010) and exert a cytoprotection against Hg-induced nephrotoxicity (Gado and Aldahmash, 2013).

Other studies reported several favorable renal effects including reduced plasma phosphate concentration, blood pressure, proteinuria, as well as extra renal effects such as slowing of intestinal glucose transport, which might be of value in the prevention and treatment of obesity and diabetes (Nasir et al., 2012; Nasir, 2013). It has been also reported to induce fetal hemoglobin in sickle cell anemia (Kaddam et al., 2015), prevents and enhances healing of gastric ulcers (Al-Yahya and Asad, 2016), influences the expression of murine ovarian oxidative stress gene (Ahmed et al., 2016) and improves semen quality and oxidative stress capacity in alloxan-induced diabetes in rats (Fedail et al., 2016).

AG was reported to be an efficient antimicrobial agent, of a natural origin, against many buccal microorganisms such as *Porphyromonas gingivalis* and *Prevotella intermedia* (Clark et al., 1993) fungi as *Candida albicans*, *Aspergillus niger* and *Microsporiumcanis* (Saini et al., 2008) bacteria as *Staphylococcus aureus*, *Staphylococcus epidermidis*, *Streptococcus pneumoniae*, *Salmonella typhi*, *Pseudomonas aeruginosa* (Singh et al., 2015). As far as we know, only one published parasitological study has investigated the antimalarial effect of AG, it stated that AG is significantly decreased

the parasitaemia and significantly expanded the lifespan of the infected mice (Ballal et al., 2011). The aim of this study was to explore and evaluate the antischistosomal properties of AG in mice infected with *S. mansoni* at the immature stage.

MATERIALS AND METHODS

Parasites and animals

Fifty laboratory-bred male Swiss albino mice, CD1 bred, were used in this study. Cercariae of *S. mansoni* were obtained from infected *Biomphalaria alexandrina* snails by the following method. *S. mansoni* ova were obtained from SBSC-TBRI which was originally an Egyptian strain and has been routinely maintained in *B. alexandrina* and albino mice CD1 strain. They were left for hatching in dechlorinated water (24 \pm 1°C) under a desk lamp light. The hatched miracidia were pipetted for snail infection. The snails were examined individually and repeatedly from the day 21 post miracidial exposure, for cercarial shedding in multi dishes under artificial light for two hours (stimulant period) and 2 ml of dechlorinated tap water/snail (Mohamed et al., 2011) which were reared and maintained at Schistosome Biological Supply Program (SBSP), Theodor Bilharz Research Institute (TBRI), Giza, Egypt. Each mouse was infected with 80 *S. mansoni* cercariae suspended in 0.2 ml water via abdominal subcutaneous injection (Holanda et al., 1974).

Ethics statement

All animal experiments were approved by the Facility Animal Care Committee of The Theodor Bilharz Research Institute (Giza, Egypt) and followed the guidelines of the Medical Research Ethics Committee (MREC) of the National Research Center (NRC) of Egypt. Approval no. 4013/2016.

Experimental design

Mice were divided into 4 groups, 10-13 mice each, representing: AG treated group, PZQ treated group, AG+PZQ treated group and untreated infected control group. AG group mice were treated daily starting 24 h (PI) till the 21st day using a dose of 1 g/kg body weight. AG is a powdered material obtained from local conventional herbal medicine market, suspended in water as a solvent reagent at a concentration of 100 mg/ml. This dose was similar to that of Nasir et al. (2012) but given individually to each mouse orally using a syringe with a curved end. On the 21st and 22nd day PZQ (Alexandria Company for Pharmaceuticals and Chemical Industries, Alex., Egypt) was freshly suspended in 13 ml of 2% cremophore-EL (Sigma Chemical Co., USA) and orally administered to mice at a dose of 500 mg/kg body weight for two consecutive days (Nessim and Demerdash, 2000). Three weeks later (6 weeks PI) all animals were scarified by cervical dislocation to assess AG antischistosomal efficacy. As for AG+PZQ group, the drug given as previous method.

Evaluation of AG antischistosomal effect

Worm burden

Schistosomes recovery was done by porto-mesenteric perfusion technique (PMPT), 3 weeks post-treatment, according to the

Table 1. Performance of AG, PZQ and combined AG+PZQ therapeutic regimens on *S. mansoni* total worm burden after treatment of infected mice during the immature infection stage.

Group	Control	AG	PZQ+AG	PZQ	P value*	
	Mean \pm SD(range)	16 \pm 5.2(11–24)	3.9 \pm 2.5(0–8)	4.4 \pm 2.6(2–8)	11.4 \pm 1.8(9–13)	
	Reduction rate (R.R)		75.6%	72.5%	28.7%	
Total worm count	P versus control		<0.001*	<0.001*	0.151	<0.001
	P vs AG			1	0.002*	
	P vs PZQ+AG				0.008*	

AG: Arabic gum, PZQ: Praziquantel.

method of Duvall and DeWitt (1967). Drug efficacy was measured by percent reduction of worms according to the formula of Abdel - Salam et al. (2008): R% (percent reduction) = $C-T/C \times 100$, where C is the mean worm burdens in control infected animals and T, mean number of worms in infected treated animals.

Tissue egg load (hepatic and intestinal)

Segments of liver and intestine were blotted between two filter papers, weighed, transferred each to a test tube containing 5 ml 5% potassium hydroxide solution (Cheever, 1969), and left overnight at room temperature to facilitate tissue digestion without egg destruction. Next morning, tubes were incubated at 37°C for 1 h to finish the tissue clearance (Selem and Eraky, 2015). Ova in homogenous emulsions were counted after being spread on slides, and the number of ova/mg tissues was calculated. To detect the egg load in the hepatic and intestinal tissue, the average number of eggs in 1 ml sample was multiplied by the total volume of potassium hydroxide, then divided by the weight of tissue to yield the number of eggs/gram tissue (Cheever, 1968). Percentage reduction was accordingly calculated. R% (percent reduction) = $C-T/C \times 100$, percentage reduction was calculated using the aforementioned equation (Abdel-Salam et al., 2008).

Oogram pattern

After mice perfusion, three segments, one cm in length of the small intestine were sectioned longitudinally, rinsed in saline 0.9%, slightly dried on filter paper, compressed between two glass slides and examined under microscope for oogram pattern that may reflect the direct drug action on ova development (Pellegrino et al., 1962). Eggs of *S. mansoni* were classified in the current study in three types immature, mature and dead (Cancado et al., 1965).

Histopathological examination

Mice livers were fixed for 48 h in 10% buffered formalin and then embedded in paraffin. Haematoxylin and eosin were used to stain sections (Harris, 1900) for granuloma counting while Masson trichrome stains (Masson, 1929) were used to demonstrate collagen fibers. Lesions containing single ova in their centers were selected for measurement (Botros et al., 1986). The granuloma diameter of each case was measured using the ocular micrometer (Lichtenberg, 1962). For each section, granulomas were counted in five successive fields (10 \times 10).

Statistical analysis

Gathered data were tabulated and analyzed using SPSS statistical software (IBM Corp., Armonk, NY, USA). Data were expressed as mean \pm SD or SE. Analysis of variance between groups was done using ANOVA test and when significant, post hoc Bonferroni test was applied for pair wise comparison between groups. P value <0.05 was considered statistically significant. All statistical tests were two-sided. Chi square test was used to assess if there was a significant difference between granuloma types in various study groups.

RESULTS

Regarding the worm load (Table 1), the AG group demonstrated the highest reduction rate (75.6%) followed by the AG+PZQ group (72.5%) while the PZQ group had the lowest rate (28.7%). The difference between all groups was statistically significant (P-value <0.001). Comparing each group with the control group, the difference was significant except for the PZQ group (P-value 0.151). While comparing the PZQ group with the AG group and the AG+PZQ group, the difference is statistically significant (P-value 0.002 and 0.008 respectively).

As for egg counting in the liver (Table 2), the AG+PZQ had the lowest number (950 \pm 498.8), followed by the PZQ group (1964.8 \pm 909), then the AG group (2315.8 \pm 252.7) and the highest number belonged to the control group (8507.4 \pm 915.2), with the difference is statistically significant (P-value <0.001). Comparing each group with the control group, the difference was significant (P-value <0.001). The AG+PZQ group demonstrated the highest hepatic egg load reduction rate (88.8%) followed by the PZQ group (76.9%) while the AG group had the lowest rate (72.7%). Comparing the result of the AG-group with that of the AG+PZQ group revealed a statistically significant difference (P-value =0.010) while comparing it to that of the PZQ group revealed a non-significant difference (P-value=1). Similarly, comparing the result of the AG+PZQ group to that of the PZQ group revealed a non-significant difference (P-value =0.226).

A similar pattern was noted for the intestinal egg load

Table 2. Comparison between the reductive effect of AG, PZQ and combined AG+ PZQ therapeutic regimens reductive effect on *S. mansoni* liver and intestinal egg count after treatment of infected mice during the immature infection stage.

Group		Control	AG	PZQ+AG	PZQ	P value between all groups
Liver egg count	Mean \pm SD	8507.4 \pm 915.2	2315.8 \pm 252.7	950 \pm 498.8	1964.8 \pm 909.7	
	(range)	(7830–10434)	(1418–3724)	(392–1818)	(963–2750)	
	R. R	--	72.70%	88.80%	76.90%	<0.001
	P versus control		<0.001*	<0.001*	<0.001*	
	P vs AG			0.010*	1	
	P vs PZQ \pm AG			0.226		
Intestinal egg count	Mean \pm SD	7205.1 \pm 1049.6	3168.8 \pm 1016.7	961.1 \pm 387.2	1121.8 \pm 629	
	(range)	(5809–8600)	(19787–4851)	(484–1720)	(528–1818)	
	R. R	--	56%	86.60%	84.40%	<0.001
	P versus control		<0.001*	<0.001*	<0.001*	
	P vs AG			<0.001*	0.001*	
	P vs PZQ \pm AG			1		

AG: Arabic gum, PZQ: Praziquantel.

(Table 2) as the AG+PZQ had the lowest number (961.1 \pm 387.2), followed by the PZQ group (1121.8 \pm 629), then the AG group (3168.8 \pm 1016.7) and the highest number belonged to the control group (7205.1 \pm 1049.6), with statistically significant difference (P-value <0.001). Comparing each group with the control group, the difference was significant (P-value <0.001). The AG+PZQ group demonstrated the highest intestinal egg load reduction rate (86.6 %) followed by the PZQ group (84.4%) while the AG group had the lowest rate (56%). Comparing the AG group to either AG+PZQ or PZQ group yielded a statistically significant difference (P-value <0.001), while comparing the PZQ and AG+PZQ groups yielded a non-significant difference (P-value =1).

According to the oogram pattern, the results of combined AG+PZQ demonstrating the lowest immature egg count (45 \pm 1.7), followed by the PZQ group (51.8 \pm 1.8), then the AG group (54.9 \pm 6.4) and the highest number belonged to the control group (51.1 \pm 4.6), yet the difference was insignificant (P-value= 0.015). Comparing each group with the control group, the difference was also insignificant. Comparing the result of the AG group with that of the AG+PZQ group revealed a statistically significant difference (P-value= 0.009) while comparing it to that of the PZQ group revealed a non-significant difference (P-value=1). Similarly, comparing the result of the AG+PZQ group to that of the PZQ group revealed a non-significant difference (P-value =0.306).

The mature egg count was (40.4 \pm 4.9) in the AG+PZQ group, (42 \pm 2.1) in the PZQ group, and (40 \pm 6.7) in the AG group. The difference between each group and the control group was statistically insignificant. Comparing the AG group to either AG+PZQ or PZQ group, as well as

comparing the AG+PZQ groups yielded non-significant differences (P-value 1, 1 and 1 respectively). While regarding the dead egg count in (Table 3), the highest number was detected in the AG+PZQ (5–25, Mean \pm SD_14.6 \pm 6.8), followed by the control group (4–10, Mean \pm SD_6.3 \pm 2.1), then, the PZQ group (5–8, Mean \pm SD_6.2 \pm 1.3). When each group was compared to the control group the difference was statistically insignificant (P-value=1) except for the AG+PZQ group (P-value= 0.001). While comparing the AG group with the AG+PZQ group the difference is statistically significant (P-value <0.001) and statistically insignificant when compared with the PZQ group (P-value=1). On the other side, the difference between the PZQ and the AG+PZQ groups was statistically significant (P-value 0.003).

The histopathological assessment of the granuloma diameter revealed that, the AG+PZQ had the smallest granuloma diameter (214.23 \pm 12.18), followed by the PZQ group (272.22 \pm 11.2), then the AG group (297.28 \pm 7.5) and the largest granuloma diameter belonged to the control group (353.15 \pm 12.4). Comparing each group with the control group, the difference was significant (P-value=0.0010, 0.0010 and 0.00010 for the AG, PZQ and AG+PZQ groups respectively).

On the other side, the AG+PZQ group demonstrated the lowest granuloma number (3.32 \pm 1.21), followed by the AG group (3.9 \pm 1.13), then the PZQ group (5.4 \pm 1.82), and the control group presented the highest granuloma number (10.62 \pm 1.97). Comparing each group with the control group, the AG and AG+PZQ showed a significant difference (P-value 0.0064 and 0.0064 respectively) while the difference between the PZQ group and the control group was insignificant (P-value= 0.09). While results of

Table 3. Oogram pattern of AG, PZQ and combined AG+PZQ therapeutic regimens after treatment of infected mice during the immature infection stage.

Result/egg type	Group	Control	AG	PZQ+AG	PZQ	P value between all groups
Immature eggs	Mean \pm SD	51.1 \pm 4.6	54.9 \pm 6.4	45 \pm 7.1	51.8 \pm 1.8	0.015
	(range)	(42-55)	(45-65)	(35-55)	(50-54)	
	P versus control		1	0.320	1	
	P vs AG			0.009*	1	
	P vs PZQ \pm AG				0.306	
Mature eggs	Mean \pm SD	42.6 \pm 3.2	40 \pm 6.7	40.4 \pm 4.9	42 \pm 2.1	0.715
	(range)	(40-48)	(30-50)	(33-45)	(40-45)	
	P versus control		1	1	1	
	P vs AG			1	1	
	P vs PZQ \pm AG				1	
Dead eggs	Mean \pm SD	6.3 \pm 2.1	5.1 \pm 0.9	14.6 \pm 6.8	6.2 \pm 1.3	<0.001
	(range)	4-10	4-7	5-25	5-8	
	P versus control		1	0.001*	1	
	P vs AG			<0.001*	1	
	P vs PZQ \pm AG				0.003*	

AG: Arabic gum, PZQ: Praziquantel.

the granuloma type revealed that the AG group had the highest cellular and the least fibro-cellular and fibrous types among all groups (80, 20 and 0%), followed by AG+PZQ group (65, 30 and 5%) and the last in order was the PZQ group (55, 43 and 2%). Only AG and AG+PZQ had significantly different granuloma types as compared to the control group (P-value <0.001 and 0.022 respectively), while the types distribution in the PZQ group was not significantly different from that of the control group (P-value= 0.247).

The state of *S. mansoni* eggs (Table 4 and Figure 1) demonstrated a different pattern as the lowest number of intact eggs and the highest number of degenerated eggs was detected in the AG group (17 and 83 respectively), while the AG+PZQ group had (23) intact eggs and (77) degenerated eggs, and the PZQ group had (45) intact eggs and (55) degenerated eggs. Comparing each group with the control group, the difference was significant (P-value <0.001).

DISCUSSION

Schistosomiasis control programs are based mainly on a single drug which is praziquantel tablet (Savioli and Daumerie, 2013). Despite the fact that patients could tolerate PZQ well, it has some drawbacks including the

emergence of drug resistance, the poor efficacy on the immature stages (Botelho et al., 2010), the large, bitter tablets, and the unavailability of a pediatric formula (Colley, 2014). Recently, natural products and natural product-derived compounds have been popular and attracted most of the attention as it could offer new effective therapy against schistosomiasis. AG is an edible, dried sticky exudate from *Acacias senegal*, which is rich in soluble dietary fiber (Ali et al., 2009).

In this study, assessment of AG antischistosomal properties revealed an excellent statistically significant effect against immature murine schistosomiasis, both alone and in combination with PZQ demonstrated in parasitological parameters; worm load, egg count, oogram pattern and histopathological results; granuloma metrics (diameter, number, and state of *Schistosoma* eggs within them).

In all parasitological parameters, apart from the worm load, AG+PZQ treated animals showed the best results as compared to monotherapy groups, denoting a considerable synergistic effect of AG+PZQ on both female fecundity, egg maturation and ability to elicit its immunopathological effect. The highest reduction rate of *Schistosoma* worms was demonstrated in the AG monotherapy group, nevertheless, the difference between AG and AG+PZQ treated mice worm load was negligible. On the contrary, the PZQ treated mice

Table 4. Effect of AG, PZQ and combined AG+PZQ treatment regimens on *S. mansoni* induced hepatic granulomas parameters as compared with the control group.

Parameter	Granuloma diameter	No. of granuloma in successive power fields (10x10) mean_±SE	Types of granuloma			State of <i>S. mansoni</i> eggs	
			Group cellular (%)	Fibro-cellular (%)	Fibrous (%)	Intact	Degenerated
Group							
Control	353.15±12.4	10.62±1.97	47	50	3	98	2
AG	297.28±7.5	3.9±1.13	80	20	0	17	83
PZQ	272.22±11.2	5.4±1.82	55	43	2	45	55
AG + PZQ	214.23±12.18	3.32±1.21	65	30	5	23	77
			AG vs Control				
	=0.0010*	=0.0064*		<0.001*			<0.001*
			PZQ vs Control				
<i>P</i>	0.0010*	0.0922		=0.247			<0.001*
			AG±PZQ vs Control				
	=0.0001*	0.0083*		0.022*			<0.001*

AG; Arabic gum, PZQ; Praziquantel.

demonstrated the worst results among all studied groups regarding total worm load. However, such results were expected as PZQ is less effective against immature *S. mansoni*, the stage targeted in this experiment.

Regarding the histopathological parameters, the AG+PZQ group showed the least mean granuloma diameter, while the largest diameter was demonstrated in the AG group. This could be explained by the fact that the granuloma of that group is the highest cellular, the least fibrocellular and fibrous granuloma types, lacking adequate fibers amount diminishes its contraction and permits large sizes. Another explanation is based on the highly significant difference in *S. mansoni* intact - degenerated eggs distribution within the examined granulomas, as the cellularity that dominated granulomas of AG treated animals might eliminate the physical barriers which would be created by fibrous tissue and hampers the action of the host immune system. Concerning the mean granuloma number, AG was significantly effective; both alone and in combination with PZQ, followed by the combination of AG+PZQ and the least effect belonged to the PZQ monotherapy. These results could be attributed to the destructive effect of AG on fecundity which in turn decreases the number of evolving granulomas.

The AG therapeutic effect on immature murine schistosomiasis in this experiment could be attributed to its immunomodulatory effect, as it stimulates the dendritic cells (Xuan et al., 2010) which are antigen-presenting cells responsible for triggering both innate and adaptive immunity (Van Duivenvoorde et al., 2007).

Also, it might be attributed to the antioxidant properties

of AG in many tissues like renal tissue (Gado et al., 2013), RBCs in sickle cell anemia (SCA) disease (Kaddam et al., 2015) and hepatic tissue as mentioned by Ahmed et al. (2015) who stated that AG significantly decreased the level of hepatic enzymes, lipid peroxidation, antioxidant enzymes as well as the expression of oxidative stress genes. Activities of superoxide dismutase (SOD), catalase (CAT) and glutathione peroxidase (GPx), which may contribute to the alleviation of *S. mansoni* infection consequences similar to what has been reported in many other antioxidants like gold nanoparticles *Ceratonia siliqua* pod extract (Al-Olayan et al., 2016), limonin (Soliman et al., 2017). Another theoretically potential mechanism of AG action relies on the fact that its administration enhances butyric acid production in the bowel and hence raising its serum concentration (Matsumoto et al., 2006).

Butyric acid is a short chain fatty acid (SCFA) that is synthesized via the fermentation of otherwise non-digestible fiber by bacteria in the colon (Pryde et al., 2002). It has four actions; first, it raises IL 10 serum level (West et al., 2013), second, it increases serum levels of IL-1 receptor antagonist (IL-1RA), third, it suppresses synthesis of transforming growth factor (TGF-β1) (Matsumoto et al., 2006), and fourth, it fosters the expression of fetal hemoglobin in erythrocytes (Ballal et al., 2011). Each of the aforementioned actions has a direct effect on schistosomiasis infection outcome; IL10 regulates not just the intensity of egg-induced inflammatory responses, but also the coherence of granuloma structure, particularly deposition of collagen by fibroblasts around the periphery (Sadler et al., 2003).

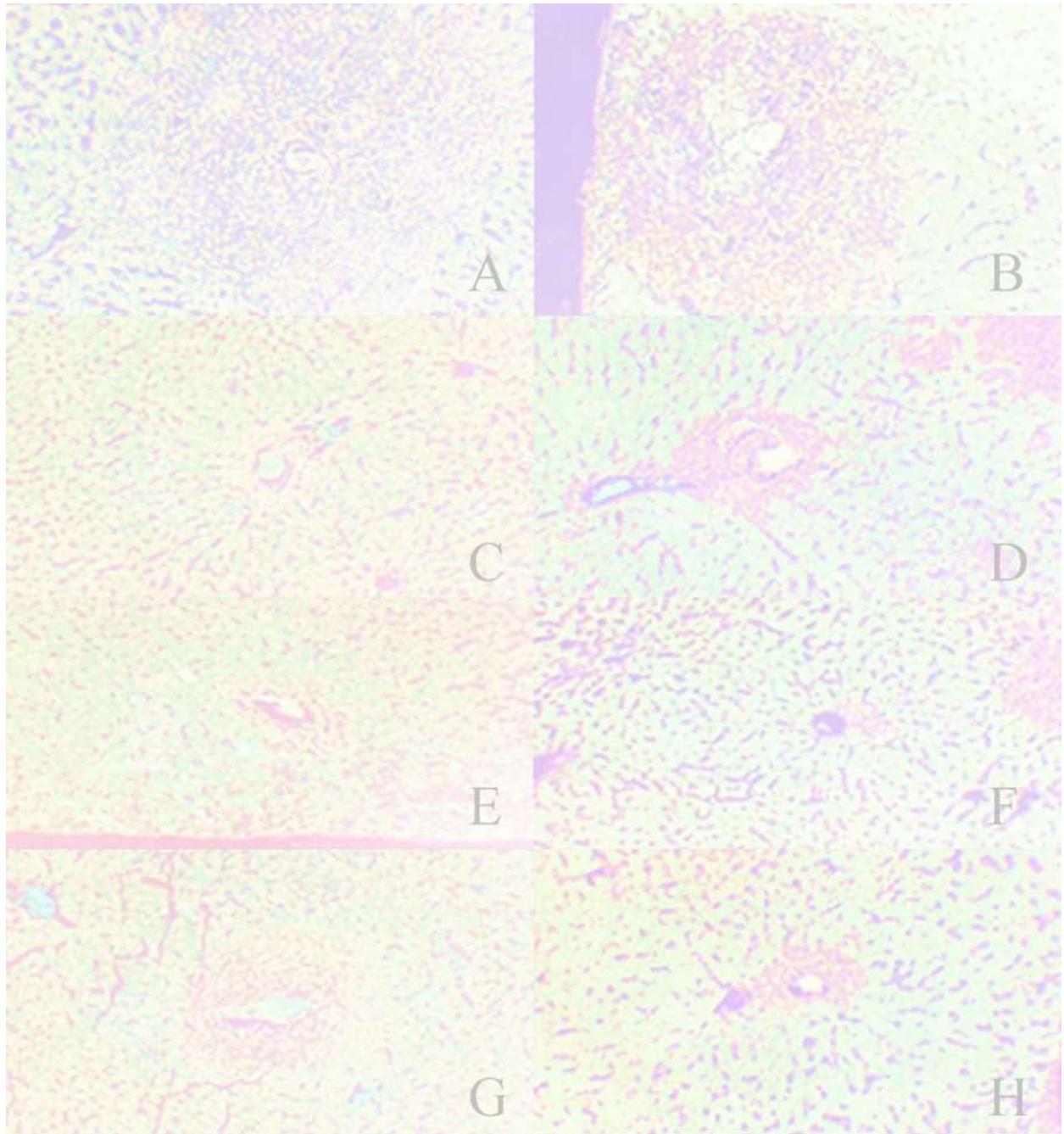


Figure 1. Liver histology at six weeks after *S. mansoni* infection of CD1 bred mice with 80 cercariae by subcutaneous injection (hematoxylin and eosin stain: 100x magnification) and (masson trichrome stain: 100x magnification).

1A: liver infected sections non treated control mice groups 6 weeks p.i. showing large number of fibrocellular granulomas stained with H&E (x100).

1B: liver infected sections non treated control mice groups 6 weeks p.i. showing large number of fibrocellular granulomas stained with masson trichrome stain (x100).

1C: Liver of infected mice group treated PZQ showing less number of fibrocellular granuloma (x100).

1D: Liver of infected mice group treated PZQ showing decrease in granuloma size showing small fibrous granuloma (x100).

1E: Liver of infected mice group treated with AG and PZQ showing less number of cellular granuloma (x100).

1F: Liver of infected mice group treated with AG and PZQ showing decrease in the granuloma size showing small granuloma with degenerated eggs (x100).

1G: Liver of infected mice group treated with AG showing decrease in size of granulomas (x100).

1H: Liver of infected mice group treated with AG showing decrease in size of granulomas degenerated eggs (x100).

It also down regulates B7 MHC II costimulatory molecule on APC (Ding et al., 1993), leading to hyporesponsive state through induction of T cells energy (King et al., 1996). IL-1RA was reported before to cause *in vivo* depletion of exacerbated granuloma size and augmented regional cytokine production (Ruth et al., 1996).

The effect of both IL 10 and IL-1RA might be manifested in this experiment in decreased granuloma diameters, fibrosis, increased cellularity and deteriorated *Schistosoma* eggs status inside the lesions. The transforming growth factor (TGF- β 1) is one of the strongest factors that lead to liver fibrosis. TGF- β 1 promotes hepatic stellate cell (HSC) proliferation and collagen synthesis in the activated HSC (Bowen et al., 2013) or modulates deposition of extracellular matrix (ECM) components and immune functions (Verrecchia and Mauviel, 2002). Furthermore, a number of researchers have recognized TGF- β 1 inhibition as one of the factors that can be used to evaluate the antifibrotic effects of drugs on hosts infected with *Schistosoma japonicum* (Chen et al., 2012). Consequently, possible suppression of TGF- β 1 by AG could reverse the immunopathologic effect induced by *Schistosoma* eggs in the affected tissues as seen in the current study.

Blood-feeding parasites, including schistosomes, hookworms, and malaria parasites, make use of aspartic proteases to produce initial or early cleavages in ingested host hemoglobin. Although phylogenetically distinct, these parasites all have the same food source; they are obligate blood feeders, or hematophagous. Hb from ingested or parasitized erythrocytes is their major source of exogenous amino acids for growth, development, and reproduction; the Hb, a 64-kDa tetrameric polypeptide, is broadly catabolized by parasite enzymes to free amino acids or small peptides (Brinkworth et al., 2001).

The fact that fetal-hemoglobin has been shown to slowdown hemoglobin degradation depriving *Schistosoma* worms of its food source (Shear et al., 1998), has inspired many researchers to evaluate the effect of increasing its production on murine malaria parasitaemia (Ballal et al., 2011), they reported that the administration of Arabic gum significantly decreased the parasitaemia and extended the lifespan of infected mice. The present study demonstrated that AG was highly effective against the immature form of *S. mansoni* which resists PZQ, and using both agents together yielded the best results owing to their synergetic effect.

To summarize, the study in hands focused the light on a novel and "green" management approach of *S. mansoni*, via AG, being one of the safest dietary fibers, and perceptibly effective in treating immature forms which entails the abortion of reinfection in endemic areas. Further studies on a larger scale are required to evaluate the feasibility of using AG as an effective treatment of immature *S. mansoni* and for prophylaxis against

reinfection, particularly in endemic areas where the control programs are continually hampered by many socioeconomic, topographic and cultural obstacles that are not currently anticipated to be defeated in the near future.

CONFLICT OF INTERESTS

The authors have not declared any conflict of interests.

REFERENCES

- Abdel-Salam A, Ammar N, Abdel-Hamid A (2008). Effectiveness of probiotic Labneh supplemented with garlic or onion oil against *Schistosoma mansoni* in infected mice. *International Journal of Dairy Science* 3(2):97-104.
- Ahmed AA, Fedail JS, Musa HH, Kamboh AA, Sifaldin AZ, Musa TH (2015). Gum Arabic extracts protect against hepatic oxidative stress in alloxan induced diabetes in rats. *Pathophysiology* 22(4):189-194.
- Ahmed AA, Fedail JS, Musa HH, Musa TH, Sifaldin AZ (2016). Gum Arabic supplementation improved antioxidant status and alters expression of oxidative stress gene in ovary of mice fed high fat diet. *Middle East Fertility Society Journal* 21(2):101-108.
- Ali BH, Ziada A, Blunden G (2009). Biological effects of gum arabic: a review of some recent research. *Food and Chemical Toxicology* 47(1):1-8.
- Al-Majed AA, Mostafa AM, Al-Rikabi AC, Al-Shabanah OA (2002). Protective effects of oral arabic gum administration on gentamicin-induced nephrotoxicity in rats. *Pharmacological Research* 46(5):445-51.
- Al-Olayan EM, El-Khadragy MF, Alajmi RA, Othman MS, Bauomy AA, Ibrahim SR, Moneim AE (2016). Ceratonia siliqua pod extract ameliorates *Schistosoma mansoni*-induced liver fibrosis and oxidative stress. *BMC Complementary and Alternative Medicine* 16(1):434.
- Al-Yahya AA, Asad M (2016). Antiulcer activity of gum arabic and its interaction with antiulcer effect of ranitidine in rats. *Biomedical Research* 27(4).
- Anderson D (1986). Evidence for the safety of gum arabic (*Acacia senegal* (L.) Willd.) as a food additive—a brief review. *Food Additives and Contaminants* 3(3):225-230.
- Ballal A, Bobbala D, Qadri SM, Föller M, Kempe D, Nasir O, Lang F (2011). Anti-malarial effect of gum arabic. *Malaria Journal* 10(1):139.
- Botelho MC, Oliveira PA, Vieira P, Delgado MdL, Lourenço L, Lopes C, Correia da Costa JM (2010). Granulomatous-like immune reaction and hepatic fibrosis induced by *Schistosoma haematobium* immature worms. *Virulence* 1(3):123-129.
- Botros S, El-Badrawy N, Metwally A, Khayyal M (1986). Study of some immunopharmacological properties of praziquantel in experimental schistosomiasis *mansoni*. *Annals of Tropical Medicine and Parasitology* 80(2):189-196.
- Botros S, William S, Hammam O, Holý A (2003). Activity of 9-(S)-[3-hydroxy-2-(phosphonomethoxy) propyl] adenine against *Schistosomiasis mansoni* in mice. *Antimicrobial Agents and Chemotherapy* 47(12):3853-3858.
- Bowen T, Jenkins RH, Fraser DJ (2013). MicroRNAs, transforming growth factor beta-1, and tissue fibrosis. *The Journal of Pathology* 229(2):274-285.
- Brinkworth RI, Prociw P, Loukas A, Brindley PJ (2001). Hemoglobin-degrading, Aspartic Proteases of Blood-feeding Parasites substrate specificity revealed by homology models. *Journal of Biological Chemistry*.
- Cançado JR, da Cunha AS, de Carvalho DG, Cambraia JS (1965). Evaluation of the treatment of human *Schistosoma mansoni* infection by the quantitative oogram technique. *Bulletin of the WHO* 33(4):557.

- Cheever AW (1968). Conditions affecting the accuracy of potassium hydroxide digestion techniques for counting *Schistosoma mansoni* eggs in tissues. *Bulletin of the WHO* 39(2):328.
- Cheever AW (1969). Quantitative comparison of the intensity of *Schistosoma mansoni* infections in man and experimental animals. *Transactions of the Royal Society of Tropical Medicine and Hygiene*. 63(6):781-795.
- Chen B-L, Zhang G-Y, Wang S-P, Li Q, Xu M-H, Shen Y-M, Mu YB (2012). The combined treatment of praziquantel with osteopontin immunoneutralization reduces liver damage in *Schistosoma japonicum*-infected mice. *Parasitology* 139(4):522-529.
- Clark D, Gazi M, Cox S, Eley B, Tinsley G (1993). The effects of *Acacia arabica* gum on the in vitro growth and protease activities of periodontopathic bacteria. *Journal of Clinical Periodontology* 20(4):238-243.
- Colley DG (2014). Morbidity control of schistosomiasis by mass drug administration: how can we do it best and what will it take to move on to elimination? *TROP. MED. health*. 42(2Supplement):S25-S32.
- Ding L, Linsley P, Huang L, Germain R, Shevach E (1993). IL-10 inhibits macrophage costimulatory activity by selectively inhibiting the up-regulation of B7 expression. *Journal of Immunology* 151(3):1224-1234.
- Doenhoff MJ, Cioli D, Utzinger J (2008). Praziquantel: mechanisms of action, resistance and new derivatives for schistosomiasis. *Current Opinion in Infectious Diseases* 21(6):659-667.
- Duvall RH, DeWitt WB (1967). An improved perfusion technique for recovering adult schistosomes from laboratory animals. *American Journal of Tropical Medicine and Hygiene* 16(4):483-486.
- Fedail JS, Ahmed AA, Musa HH, Ismail E, Sifaldin AZ, Musa TH (2016). Gum arabic improves semen quality and oxidative stress capacity in alloxan induced diabetes rats. *Asian Pacific Journal of Reproduction* 5(5):434-441.
- Gado AM, Aldahmash BA (2013). Antioxidant effect of Arabic gum against mercuric chloride-induced nephrotoxicity. *Drug Design, Development and Therapy* 7(3):1245.
- Harris H (1990). On the rapid conversion of haematoxylin into haematein in staining reactions. *Journal of Applied Microscopic Laboratory Methods* 3(3):777.
- Holanda J, Pellegrino J, Gazzinelli G (1974). Infection of mice with cercariae and schistosomula of *Schistosoma mansoni* by intravenous and subcutaneous routes. *Revista do Instituto de Medicina Tropical de Sao Paulo* 16(3):132-134.
- Kaddam L, FdleAlmula I, Eisawi OA, Abdelrazig HA, Elnimeiri M, Lang F, Saeed A M (2015). Gum Arabic as fetal hemoglobin inducing agent in sickle cell anemia; in vivo study. *BMC Hematology* 15(1):19.
- King CH, Dangerfield-Cha M (2008). The unacknowledged impact of chronic schistosomiasis. *Chronic illness* 4(1):65-79.
- King CL, Medhat A, Malhotra I, Nafeh M, Helmy A, Khaudary J, Brustoski K (1996). Cytokine control of parasite-specific anergy in human urinary schistosomiasis. IL-10 modulates lymphocyte reactivity. *Journal of Immunology* 156(12):4715-4721.
- Lichtenberg FV (1962). Host response to eggs of *S. mansoni*: I. Granuloma formation in the unsensitized laboratory mouse. *American Journal of Tropical Medicine and Hygiene* 41(6):711.
- Masson P (1929). Some histological methods: trichrome stainings and their preliminary technique. *Journal Technology methods* 12:75-90.
- Matsumoto N, Riley S, Fraser D, Al-Assaf S, Ishimura E, Wolever T, Phillips AO (2006). Butyrate modulates TGF- β 1 generation and function: Potential renal benefit for *Acacia* (sen) SUPERGUM™ (gum arabic)? *Kidney International* 69(2):257-265.
- Mohamed AH, Sharaf El-Din AT, Mohamed AM, Habib MR (2011). Tissue Responses Exhibited by Biomphalaria Alexandrina Snails from Different Egyptian Localities Following Exposure to *Schistosoma Mansoni* Miracidia. *Experimental parasitology* 127(4):789-794
- Nasir O (2013). Renal and Extrarenal Effects of Gum Arabic (*Acacia Senegal*)-What Can be Learned from Animal Experiments?. *Kidney and Blood Pressure Research* 37(45):269-279.
- Nasir O, Umbach AT, Rexhepaj R, Ackermann TF, Bhandaru M, Ebrahim A, Föller M (2012). Effects of gum arabic (*Acacia senegal*) on renal function in diabetic mice. *Kidney and Blood Pressure Research* 35(5):365-372.
- Nessim NG, Demerdash Z (2000). Correlation between infection intensity, serum immunoglobulin profile, cellular immunity and the efficacy of treatment with praziquantel in murine schistosomiasis. *Arzneimittelforschung*. 50(02):173-177.
- Pellegrino J, Oliveira CA, Faria J, Cunha AS (1962). New approach to the screening of drugs in experimental schistosomiasis mansoni in mice. *American Journal of Tropical Medicine and Hygiene* 11(2):201-215.
- Pradeep A, Happy D, Garg G (2010). Short-term clinical effects of commercially available gel containing *Acacia arabica*: a randomized controlled clinical trial. *Australian Dental Journal* 55(1):65-69.
- Pryde SE, Duncan SH, Hold GL, Stewart CS, Flint HJ (2002). The microbiology of butyrate formation in the human colon. *FEMS Microbiology Letters* 217(2):133-139.
- Rehan A, Johnson KJ, Kunkel RG, Wiggins RC (1985). Role of oxygen radicals in phorbol myristate acetate-induced glomerular injury. *Kidney International* 27(3):503-511.
- Ribeiro-dos-Santos G, Verjovski-Almeida S, Leite LC (2006). Schistosomiasis—a century searching for chemotherapeutic drugs. *Parasitology Research* 99(5):505.
- Ruth JH, Bienkowski M, Warmington KS, Lincoln PM, Kunkel SL, Chensue SW (1996). IL-1 receptor antagonist (IL-1ra) expression, function, and cytokine-mediated regulation during mycobacterial and schistosomal antigen-elicited granuloma formation. *Journal of Immunology* 156(7):2503-2509.
- Sadler CH, Rutitzky LI, Stadecker MJ, Wilson RA (2003). IL-10 is crucial for the transition from acute to chronic disease state during infection of mice with *Schistosoma mansoni*. *European Journal of Immunology* 33(4):880-888.
- Saini ML, Saini R, Roy S, Kumar A (2008). Comparative pharmacognostical and antimicrobial studies of *Acacia* species (Mimosaceae). *Journal of Medicinal Plants Research* 2(12):378-386.
- Savioli L, Daumerie D (2013). Sustaining the drive to overcome the global impact of neglected tropical diseases: second WHO report on neglected tropical diseases: WHO. 2.
- Salem RF, Eraky MA (2015). Assessment of mefloquine in-vivo efficacy on juvenile and adult stages of *Schistosoma haematobium* (Egyptian strain). *Parasitologists United Journal* 8(1):60-67.
- Shear HL, Grinberg L, Gilman J, Fabry ME, Stamatoyannopoulos G, Goldberg DE, Nagel RL (1998). Transgenic mice expressing human fetal globin are protected from malaria by a novel mechanism. *Blood*. 92(7):2520-2526.
- Singh B, Dubey S, Siddiqui M (2015). Antimicrobial activity of natural edible gums. *Journal of Pharmaceutical Sciences* 3(11):2217-2221.
- Soliman R, Ismail O, Badr M, Nasr S (2017). Resveratrol ameliorates oxidative stress and organ dysfunction in *Schistosoma mansoni* infected mice. *Experimental parasitology* 174:52-58.
- Steinmann P, Keiser J, Bos R, Tanner M, Utzinger J (2006). Schistosomiasis and water resources development: systematic review, meta-analysis, and estimates of people at risk. *The Lancet Infectious Diseases* 6(7):411-425.
- Taylor M (2008). Global trends in schistosomiasis control. *Bulletin of the WHO* 86(10):738-738.
- Van Duivenvoorde LM, Han WG, Bakker AM, Louis-Plence P, Charbonnier L-M, Apparailly F, Toes RE (2007). Immunomodulatory dendritic cells inhibit Th1 responses and arthritis via different mechanisms. *Journal of Immunology* 179(3):1506-1515.
- Verrecchia F, Mauviel A (2002). Transforming growth factor- β signaling through the Smad pathway: role in extracellular matrix gene expression and regulation. *Journal of Investigative Dermatology* 118(2):211-215.
- Wang W, Wang L, Liang YS (2012). Susceptibility or resistance of praziquantel in human schistosomiasis: a review. *Parasitology Research* 111(5):1871-1877.
- West NP, Christophersen CT, Pyne DB, Cripps AW, Conlon MA, Topping DL, Clarke JM (2013). Butyrylated starch increases colonic butyrate concentration but has limited effects on immunity in healthy physically active individuals. *Exercise Immunology Review* P 19.

Xuan NT, Shumilina E, Nasir O, Bobbala D, Götz F, Lang F (2010).
Stimulation of mouse dendritic cells by Gum ArabicCellular Physiology
and Biochemistry 25(6):641-648.