

Full Length Research Paper

Hepatoprotective effect of Barrisal (herbal drug) on carbon tetrachloride induced hepatic damage in rats

Muhammad Ahmed^{1*}, Aisha Azmat², M. A. Azeem³, Naviad-ul- Zafar⁴ and S. I. Ahmad⁵

¹Department of Pharmacology, Faculty of Pharmacy, Umm Al-Qura University, P.O. Box 7607 Makkah, Saudi Arabia.

²Department of Physiology, Faculty of Medicine, Umm Al-Qura University, P.O. Box 7607 Makkah, Saudi Arabia.

³United Medical College, Ibrahim Haydri Korangi Creek, Karachi, Pakistan.

⁴Hmadard Laboratories (Waqf), Pakistan.

⁵Dr HMI Institute of Pharmacology and Herbal Sciences, Hamdard University, Karachi-74600, Pakistan.

Accepted 15 April, 2013

Barrisal is an herbal preparation of Hamdard Laboratories (Waqf) Pakistan that has been used as hepatoprotective agent. In this study, the protective effects of Barrisal against liver damage were evaluated in carbon tetrachloride (CCl₄)-induced chronic hepatotoxicity in rats. Four groups (I, II, III, IV) of Sprague-Dawley (SD) rats were used and Groups I and II were orally fed with saline and Barrisal (10 ml/kg), respectively for 14 consecutive days while Groups III and IV were orally fed with saline, Barrisal (10 ml/kg) and then a single dose of CCl₄ (0.3 ml/kg body weight in a 20% olive oil) was injected intraperitoneally 30 min after the last dose of Barrisal and the animals were starved for 24 h. The degree of protection was measured using biochemical parameters like serum glutamate oxaloacetate transaminase (SGOT) and serum glutamate pyruvate transaminase (SGPT), alkaline phosphatase (ALP), total protein and albumin. Data obtained from results were compared using student's t-test (paired and unpaired) and one-way analysis of variance (ANOVA), significant differences were determined (Tukey honestly significant difference (HSD) test) using the Minitab 13 computing program. Values of P<0.05, were considered to be significant. The results showed that the treatment with Barrisal significantly lowered the CCl₄-induced serum levels of hepatic enzyme markers (GOT, GPT, ALP, and total bilirubin, total cholesterol, total protein) indicated hepatoprotective effect of the Barrisal. Histopathological examination of liver sections confirmed that, pre-treatment with Barrisal reduced the hepatic damage induced by CCl₄. Barrisal reduced the incidence of liver lesions including hepatic cells cloudy swelling, lymphocytes infiltration, hepatic necrosis, and fibrous connective tissue proliferation induced by CCl₄ in rats. Therefore, the results of this study suggest that Barrisal could protect liver against CCl₄-induced oxidative damage in rats, and this hepatoprotective effect might be because of its antioxidant and free radical scavenger effects.

Key words: Barrisal, hepatoprotective, carbon tetrachloride (CCl₄), hepatic enzymes marker, liver, kidney.

INTRODUCTION

Barrisal syrup prepared by Hamdard Laboratories (Waqf) Pakistan is composed of only *Aloe vera* syn. *Aloe barbadensis* Mill. (*A. barbadensis* Linn. Family; Liliaceae).

Barrisal is widely prescribed in hepatic and spleen

disorders; it is claimed that Barrisal is an immune modulating drug having adaptogenic activity. The medicinal plant *Aloe vera* is used traditionally. It is a xerophytic plant which includes trees (*Aloe ferox*), shrubs and herbs

and herbs (*A. barbadensis*). It has large fleshy leaves, carrying spines at the margin and resemble to some extent the agave or century plant (*Agave Americana* Linne) (Capasso et al., 1998). Pharmacological activities reported so far for its gel, polysaccharides, polypeptides, anthrones and chromones include antibacterial (Tian et al., 2003), anti-inflammatory (Hutter et al., 1996), and immunoprotective (Strickland et al., 2004) activities.

A. vera has been recognized as a good medicine for the treatment of asthma, gastrointestinal ulcer, constipation, otalgia, cancer, burns, wounds, herpes simplex virus, diabetes and inflammation (Khan, 1997).

Different compounds like cinnamoyl, p-coumaroyl, feruloyl, and caffeoyl aloesin isolated from *Aloe* species possess antiinflammatory and antioxidative properties (Yagi and Takeo, 2003). However, the biological effects of Barrisal on liver injury have not been studied yet. This study investigated the protective ability of Barrisal on liver injury induced by carbon tetrachloride (CCl_4) in rats.

MATERIALS AND METHODS

Barrisal

Barrisal (herbal syrup) used in the hepatoprotective and toxicological studies was obtained from Hamdard Laboratories (Waqf) Pakistan.

Animals

Adult Sprague Dawley rats ($n=40$) of both sex (200 to 225 g) were used for hepatoprotective, toxicological and histopathological studies, while NMR-1 mice ($n=36$: weight 20-30gm) were used only for toxicological studies. They were obtained from Animal House of Dr. Hafiz Muhammad Ilyas Institute of Pharmacology and Herbal Sciences (Dr. HMIIPHS) and were housed in groups of 6 per cage for seven days prior to experimentation with free access to standard feed and tap water *ad libitum* and kept on a 12 h light/dark cycle. All animals were housed in an air-conditioned room at $23\pm 1^\circ\text{C}$ during the quarantine period.

Toxicological studies of Barrisal in mice

Different groups of mice with either sex (twelve animals per group) were used to measure the acute toxicity of Barrisal by oral route of administration.

- (1) Group-I treated as control, was given saline (0.5 ml/mouse)
- (2) Group-II was treated with 5 ml Barrisal/kg/day.
- (3) Group-III was treated with 10 ml Barrisal/kg/day.

All the animals were treated daily for fourteen consecutive days (Zaoui et al., 2002) and were kept under constant observation for 2 h after dosing to observe any change in general behavior or other physiological activities and weighed daily to monitor any change in body weight.

Toxicological and hepatoprotective activity of Barrisal in rats

In the present study, the adult Sprague-Dawley rats of both sexes (200 to 225 g) were divided into four groups. Each group consisted of ten animals. The animals were treated as follows.

- (1) Group I was treated with saline.
- (2) Group II was treated with 10 ml/kg/day of Barrisal syrup administered orally for 14 consecutive days.
- (3) Group III animals served as reference control, which received a single dose of CCl_4 (0.3 ml/kg body weight in a 20% olive oil) intraperitoneally and the animals were starved for 24 h (Fatima, 1993).
- (4) Group IV was treated with 10 ml/kg/day of Barrisal syrup for 14 consecutive days as of Group II and then a single dose of CCl_4 (0.3 ml/kg body weight in a 20% olive oil) was injected intraperitoneally 30 min after the last dose of Barrisal and the animals were starved for 24 h.

Autopsy

At the end of 14th day, all surviving mice and rats were anaesthetized with pentothal sodium (40 mg/kg) intraperitoneally.

Estimation of different biochemical parameters

The blood samples approximately (4 to 8 ml) were drawn directly from cardiac puncture before dissecting the animals with sterile disposable syringe from all treated and control rats. Blood samples were left at room temperature for 20 min. Then incubated at 37°C for 30 min and centrifuged separately in BHG Hermle Z230 (Germany) at the speed of 3000 rpm for 20 min. Supernatants (serum) were separated out and the residue was discarded.

Serum obtained (1 to 4 ml) was subjected for the study of the following parameters: total protein, bilirubin, cholesterol, serum glutamate pyruvate transaminase (SGPT), serum glutamate oxaloacetate transaminase (SGOT), alkaline phosphatase (ALP).

All tests were performed using commercial assay kits. All these kits were purchased from Diagnostica Merck (Germany). Spectrophotometer U-2000 (Hitachi) was used to measure the absorbance of light.

Histology

At the end of toxicological studies, all vital organs of rats (heart, liver, spleen and kidneys) were subjected to microscopic examination and compared with control animals. They were fixed in 10% formalin. After usual processes of dehydration, clearing and infiltration, tissues were embedded in paraffin wax and sectioned into 7- μm slices through Leica RM 2145-Rotation Microtom. The tissues were stained with hematoxylin and eosin. The slides were studied and photographed through Nikon Advance Trinocular Research Microscope OPTIPHOT Model X2T-21E equipped with Nikon Microphotography system; Model UFX-DX-35 and phase contrast N plan.

Statistical analysis

Data obtained from results regarding serum biochemical estimations and body weight were compared using student's t-test (paired and unpaired) and one-way analysis of variance (ANOVA), significant differences were determined (Tukey HSD test) using the

MINITAB 13 Computing Program. Values of $P < 0.05$ were considered to be significant.

RESULTS

Toxicological and hepatoprotective activity of Barrisal

Toxicological and hepatoprotective effects of Barrisal have been studied on four groups of rats and mice as already described in materials and methods.

In these studies, the administration of Barrisal (10 ml/kg) for fourteen consecutive days did not show any mortality in rats and mice. Further, this treatment with Barrisal (10 ml/kg) also did not produce any significant change in the physical activity (Table 1), food and water consumption, and body weight of these animals, as shown in Figure 1a and b for mice and rats, respectively. In addition, no apparent changes in lungs, heart, liver and kidneys were observed on autopsy at 14 days of this treatment.

Biochemical parameters

The results obtained from rat blood serum analysis are presented in Table 2. This demonstrates that in the four groups of rats that were administered saline (being control, Group I), Barrisal (Group II), Saline+ CCl_4 (Group III) and Barrisal+ CCl_4 (Group IV), respectively, the serum level for all the parameters, that is, total protein, cholesterol, bilirubin, SGPT, SGOT and alkaline phosphatase, changed with respect to the control group (saline).

Barrisal treatment

The Barrisal treatment for 14 consecutive days to the 2nd group of rats was found to reduce the serum total protein, bilirubin, SGPT, and SGOT in comparison with the control group. However, ANOVA showed that this reduction in the aforementioned parameters was statistically non-significant ($P > 0.05$) for total protein, ($P > 0.05$) for bilirubin, ($P > 0.05$) for SGPT and ($P > 0.05$) for SGOT. However, a non-significant rise was observed in serum alkaline phosphatase ($P > 0.05$), as shown in Table 2. Serum cholesterol level after Barrisal administration has been found to reduce significantly ($P < 0.05$), with respect to its control (saline treated group).

CCl_4 treatment

In the 3rd group of rats, treatment with saline for 14 consecutive days was followed by the treatment with CCl_4

for a period of 24 h. This treatment has been found to produce acute hepatotoxicity for which bilirubin, SGPT, SGOT and alkaline phosphatase used as marker. These results presented in Table 2, demonstrates that after CCl_4 treatment, the serum level for all the parameters, that is, total protein, bilirubin, SGOT, SGPT and alkaline phosphatase have been found to increase except cholesterol with respect to control. A statistical comparison of these results through one-way ANOVA followed by Tukey showed that the level of total protein was found to increase non-significantly ($P > 0.05$), while the administration of CCl_4 has been found to increase the serum alkaline phosphatase ($P < 0.05$), bilirubin ($P < 0.05$), SGPT ($P < 0.05$) and SGOT ($P < 0.05$) being statistically significant. However, cholesterol level has shown non-significant fall ($P > 0.05$).

Treatment with Barrisal followed by CCl_4

In the fourth group, Barrisal (10 ml/kg) treated (14 days) rats were used for additional treatment with CCl_4 for a period of 24 h. Such treatment was found to reduce the serum transaminase activity as shown in Table 2. This activity was assessed due to significant reduction in serum alkaline phosphatase ($P < 0.05$), bilirubin ($P < 0.05$), SGPT ($P < 0.05$), SGOT ($P < 0.05$), compared to CCl_4 treated 3rd group, while similar comparison showed no statistically significant change in serum cholesterol level ($P > 0.05$). In addition, this treatment has also reduced total protein, non-significantly ($P > 0.05$).

Hepatoprotective effect of Barrisal on liver histology

The normal histological pictures of tissues obtained from control rats have been presented in Figure 2a as well as the histological pictures obtained after treatment with Barrisal were not significantly different from those in the control group (Figure 2b). The liver sections showed normal hepatic cells with well-preserved cytoplasm, prominent nucleus and central vein.

Intraperitoneal administration of CCl_4 showed complete disorganization in the structure of liver, the lesion in liver sections, liver cirrhosis with destruction of normal structure, severely damaged hepatocytes and massive ascites retention. Further, various stages of necrosis, numerous vacuoles in the cytoplasm, multifocal necrosis, moderate portal edema and infiltration of numerous inflammatory cells into portal triads were observed in CCl_4 treated rats. Bile ductule epithelial cells were swollen, vacuolated and had foci of cell necrosis with hypertrophy in the hepatocytes as shown in Figure 2c. Hypertrophy was more pronounced around central vein and peripheral region.

Table 1. Toxicological study of different extracts and drugs in mice and rats.

S/No.	Drug	Animal	Dose (ml/kg)	Route of administration	No. of animals	Days	Mortality	Symptom
1	<i>Barrisal</i>	Mice	Saline	Oral	6 Male, 6 Female	14	Nil	Decreased motor activity and corner sitting
			5	Oral	6 Male, 6 Female	14	Nil	
			10	Oral	6 Male, 6 Female	14	Nil	
2	<i>Barrisal</i>	Rats	Saline	Oral	5 Male, 5 Female	14	Nil	Nil
			10	Oral	5 Male, 5 Female	14	Nil	Nil

Table 2. Toxicological and hepatoprotective effect of *Barrisal* (10 ml/kg) in rats.

Compound	Total protein	Cholesterol	Bilirubin	SGPT	SGOT	AP
Saline	11.93±5.7 (12)	113.3±23.6 (12)	1.03±0.39 (12)	39.66±27.4 (12)	46.14±17.8 (12)	69.02±14.46 (12)
<i>Barrisal</i>	10.67±4.7 (12)	76.79±38 ^{a*} (12)	0.89±0.76 (12)	34.75±13.15 (12)	34.75±13.15 (12)	79.04±14.33 (12)
Saline+CCl ₄	11.10±3.7 (12)	95.05±9.12 (12)	2.16±1.5 ^{a*} (12)	200.63±31.65 ^{a**} (12)	169.78±36.7 ^{a***} (12)	110.8±32.08 ^{a***} (12)
<i>Barrisal</i> +CCl ₄	10.45±1.2 (12)	95.78±16.7 (12)	1.51±0.49 ^{b*} (12)	154.67±14.23 ^{b*} (12)	93.85±6.75 ^{b**} (12)	65.98±16.07 ^{b**} (12)

All values are expressed as mean±SD (n). a = p < 0.05 compared to control groups b = p < 0.05 compared to Saline + CCl₄ groups *p < 0.05, **p < 0.001, ***p < 0.00001

A hepatoprotective effect of *Barrisal* has prevented CCl₄ to induce liver damage. The hepatic pictures of rats treated with *Barrisal* + CCl₄ demonstrated a prevalence of morphologically normal hepatocytes and resulted in a significant reduction of all morphological alterations caused by CCl₄ intoxication. Only some hepatocytes with early necrotic lesions were encountered (Figure 2d).

Hepatoprotective effect of *Barrisal* on heart histology

No effects were observed in the heart. They are

comparable with each other and they did not show any significant histological abnormality. The myofibrils within each cell are well displayed. In control and treated animals, branching of fiber is evident. Histological pictures of cardiac muscle, demonstrated that the fiber is dividing, then recombining and then spreading again. Each muscle cell possesses centrally located oval nuclei. Occasional muscle cells possess two nuclei. Intercalated disc indicated intracellular junction between two cardiac muscle cells. The intercellular areas are richly supplied by capillaries as shown in Figure 3b. They are comparable with their control (Figure 3a, b, c and d).

Hepatoprotective effect of *Barrisal* on kidney histology

The histological features of the control and *Barrisal* treated rats showed normal features (Figure 4a and b). Histopathological examination of the kidney of the rats intoxicated with CCl₄ revealed some renal disturbances and shrinkage in the cortical region and Bowman's capsule. Some cortical tubules showed disorganization while glomeruli shrunken and due to glomeruli atrophy it showed mild dilatation of Bowman's space while capillary loops exhibited congestion with an adhesion between visceral and parietal layers of

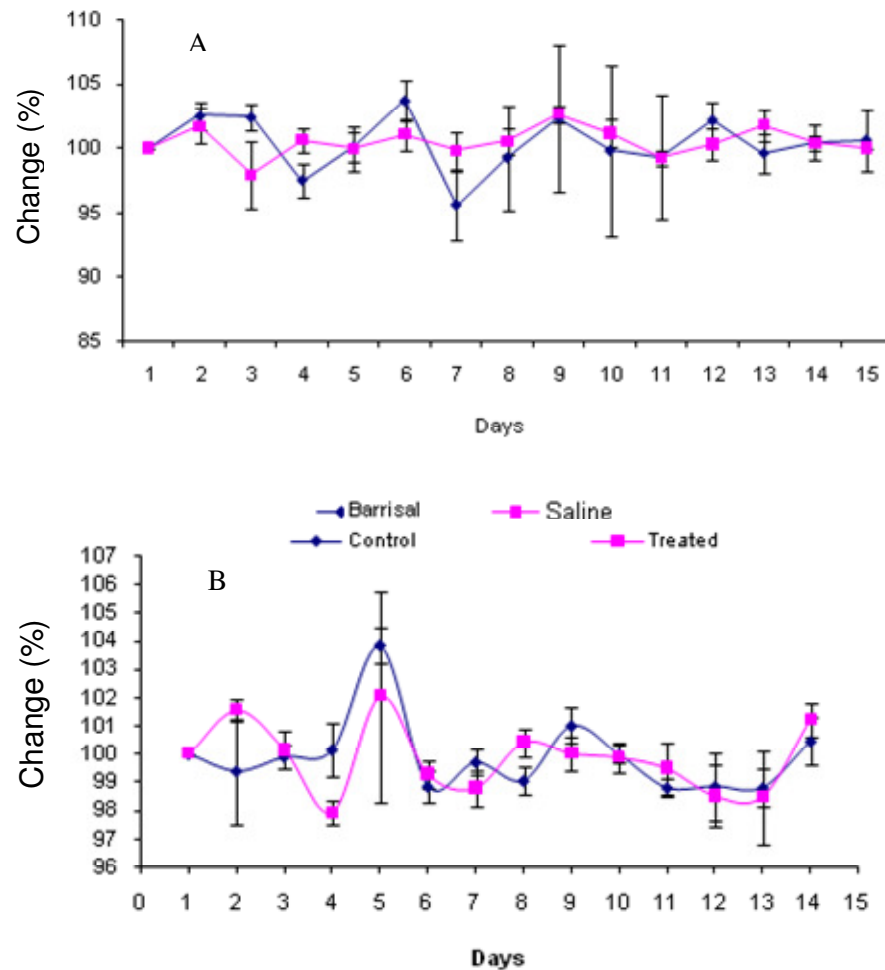


Figure 1. Effect of barrisal on body weight of (a) mice and (b) rats.

Bowman's capsule. Deterioration in some Bowman's capsule and tubular cell were observed. Renal tubules were dilated and their epithelial cells tend to be vacuolated. Interstitial inflammatory cell infiltration and fibrosis were clearly apparent after CCl_4 treatment (Figure 4c).

The kidneys of the rats treated with Barrisal + CCl_4 demonstrated a prevalence of morphologically normal glomeruli, Bowman's capsule and tubular cell. Histological appearance of the glomeruli and tubules were normal and rare vascular congestion was present in both the cortical and medullar region (Figure 4d).

DISCUSSION

The presented results for Barrisal treatment demonstrated no mortality in mice and rats. Similarly, no biochemical or histological changes have been detected as an evidence for the damage in the liver and other body

organs for the rats (Table 1). A non-significant change in body weight (Figure 1a and b) was observed during the treatment period which indicates that administration of Barrisal did not result in growth arrest (Figure 1a and b). Liver profile showed decrease bilirubin, SGPT and SGOT level, with an increase in alkaline phosphatase level, which was statistically non-significant. These results indicate that liver, heart and kidney are working normally. However, statistically non-significant changes in biochemical and histological parameters exhibit normal biological variability in rats.

In this study, the administration of Barrisal decrease the serum cholesterol level significantly ($P < 0.05$). It is also reported earlier that '*A. vera*' caused a marked reduction in total serum cholesterol (Agarwal, 1985). This decrease in serum cholesterol after Barrisal administration has added advantage, because of the putative link between serum cholesterol and the incidence of atherosclerosis (Dixit et al., 1992).

Hepatoprotective activity of Barrisal was carried out by

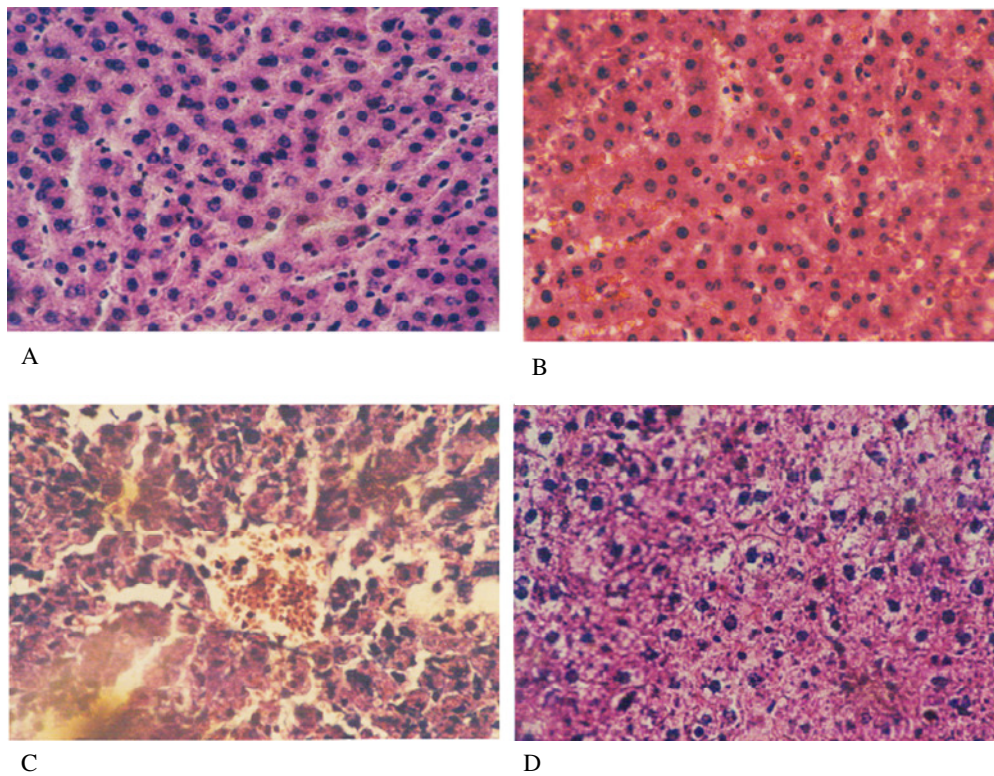


Figure 2. (A) Histological appearance of liver histology of control rats. (B) Liver histology of rats treated with Barrisal (10 ml/kg). (C) Liver histology of rats received CCl₄ olive oil. (D) Liver histology of rats received Barrisal+CCl₄ olive oil.

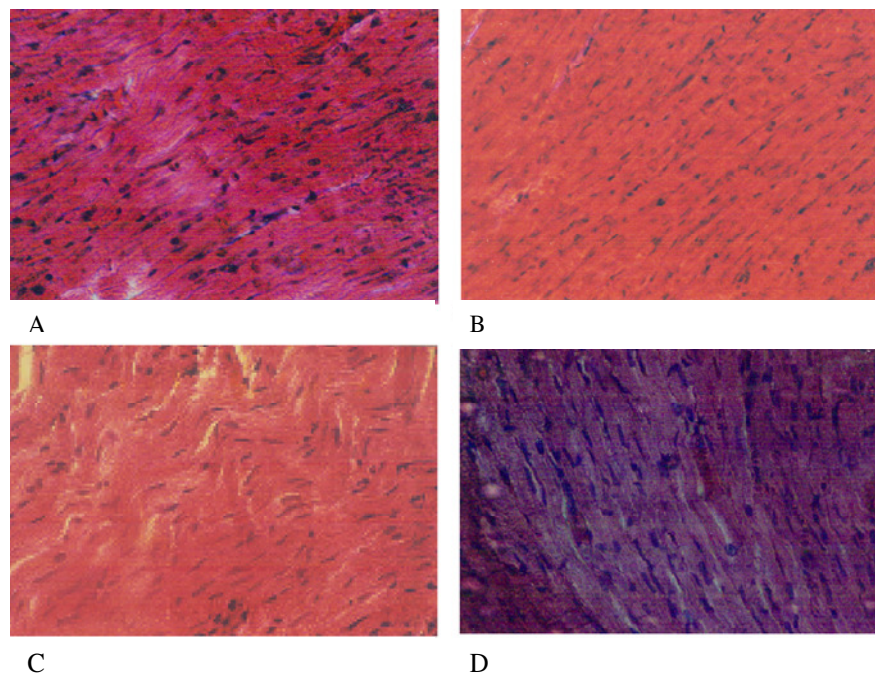


Figure 3. (A) Normal histological appearance of heart tissue of histology of control rats. (B) Histological appearance of heart tissue of Barrisal (10 ml/kg) treated rats. (C) Histological appearance of heart tissue of CCl₄ treated rats. (D) Histological appearance of heart tissue of Barrisal (10 ml/kg)+CCl₄ treated rats.

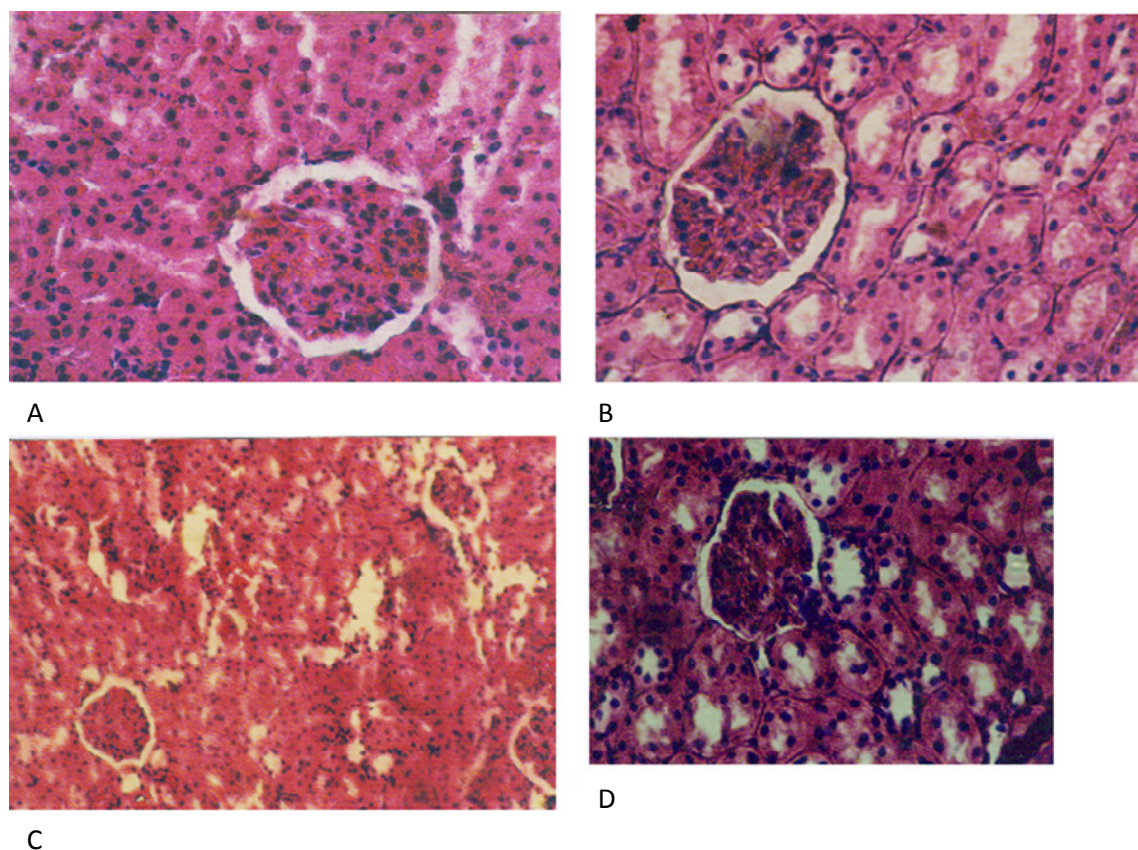


Figure 4. (A) Normal histological appearance of kidney tissue control rats. (B) Histological appearance of kidney tissue of Barrisal (10 ml/kg) treated rats. (C) Histological appearance of kidney tissue of CCl₄ treated rats. (D) Histological appearance of kidney tissue of Barrisal (10 ml/kg)+CCl₄ treated rats.

assessing the effect of Barrisal on the activities of plasma transaminases after CCl₄ treatment in rats. For this purpose, liver function tests for transaminases (SGOT, SGPT), bilirubin, protein, alkaline phosphatase were performed by considering them as useful markers to detect the extent of liver damage (Amin et al., 1996). The hepatotoxic effects of CCl₄ have been reported extensively. However, they depend upon the route of administration, amount employed, and duration of treatment (Lin et al., 1994). In the present study, the rats treated with a single dose of CCl₄ (Group III) developed hepatic damage, causing a substantial increase in the serum levels of transaminases: SGOT ($P < 0.00001$), SGPT ($P < 0.001$), bilirubin ($P < 0.05$) and alkaline phosphatase ($P < 0.001$) as shown in Table 2. Such rise in transaminases indicates the cellular leakage and loss of functional integrity of cell membrane in liver (Sango et al., 1998).

Further, liver injury is also attributed to the production of free radicals (Toshikazu et al., 1982). The mechanism of free radical production was reported by Durk and Frank (1984). They have suggested that bioactivation of

CCl₄ results in the production of trichloromethyl radical (initial metabolite) and trichloromethyl peroxy radical induced lipid peroxidation. Trichloromethyl free radical, initiates the biochemical events and attack membrane lipid/protein, thus ultimately culminate in liver cell necrosis (Pohl et al., 1984) leading to increased level of transaminases (SGOT, SGPT) and functional and structural disruption of liver cells as well as that observed in the present study (Table 2). Further, a non-significant decrease in serum cholesterol level in the present study after CCl₄ administration suggests that trichloromethyl radical can form covalent adducts with lipids, interact with O₂ to form a trichloromethyl peroxy radical (Pohl et al., 1983) causing a substantial decrease in cholesterol. CCl₄ treatment also causes significant increase in bilirubin level (Hyperbilirubinemia), because CCl₄ is also one of the most useful model to the severity of necrosis (Zimmerman, 1973). While there was no change in total protein level, these findings were in accordance with the observation that protein in general and albumin level in particular remains unchanged in acute liver damage (Anand et al., 1994). This brief period might not be sufficient

to demonstrate any rise in serum protein levels. Szymonik-Lesiuk et al. (2003) have shown that CCl₄ intoxication can lead to alteration in kidney; these findings are in accordance with the present observation. In the present study, an increased frequency of glomerulosclerosis and tubulointerstitial alterations was found in rats with reduced renal mass on CCl₄ administration (Figure 4c), thereby indicating nephrotoxicity on CCl₄ administration in rats. However, the pathogenesis of CCl₄ induced renal injury has not been clarified. While Rincon et al. (1999) showed that the effects of CCl₄ on kidney structure and function are dependent on the functional state of the liver. It is also suggested that kidney has high affinity for CCl₄ (Abraham et al., 1990), because cortex contain cytochrome P450 predominantly (Ronis et al., 1998) and cytochrome P450 lead towards CCl₄ activation, that is why the mechanism of CCl₄ nephrotoxicity is probably the same as that of liver.

Administration of Barrisal before CCl₄ exposure significantly reduced all the biochemical and histological alterations. In this study, Barrisal was found to significantly reduce the elevations in serum transaminases like SGOT (P<0.001), SGPT (P<0.05), bilirubin (P<0.05) and alkaline phosphatase (P<0.001) level against CCl₄ induced toxicity in rats. Histopathological evaluation of Barrisal in CCl₄ induced liver injury suggests a significant reduction of ballooned cells in liver of Barrisal treated rats when compared with only CCl₄ treated group. It was also found that multifocal necrotic changes induced by CCl₄ minimized or erased completely in Barrisal pretreated rats. These results indicate that Barrisal may improve general injury and suppress enzyme leakage from cellular membranes; it was also found that Barrisal showed an improvement in centrilobular necrosis around central vein. This study also revealed that Barrisal substantially protects against CCl₄ induce tubular and glomerular changes in the kidneys having nephroprotective effect.

In this study, we hypothesized that administration of Barrisal would effectively protect liver and kidney against CCl₄ induced injury and this effect was verified by both biochemical and histopathological observation (Figure 2 to 4). Numerous experimental studies have demonstrated that antioxidant treatment has beneficial effects on CCl₄ induced tissue injury (Banskota et al., 2001). Barrisal is widely prescribed in hepatic and spleen disorders, it is also claimed that Barrisal is an immune modulating drug having adaptogenic activity. Barrisal is a herbal formulation having *A. vera* syn. *A. barbadensis* Mill as an active ingredient contain cinnamoyl, p-coumaroyl, feruloyl, and caffeoyl aloesin, which have been reported to have antiinflammatory and antioxidative (Yagi and Takeo, 2003) properties and it also possess inhibitory effect (antilipoxygenase activity) in the acute inflammation process (Bezakova et al., 2005). That is why protective effects of Barrisal on the increase in plasma transaminase activities induced by CCl₄ treatment is due

to the presence of antioxidative compound cinnamoyl, p-coumaroyl, feruloyl, and caffeoyl aloesin.

Since a cellular membrane defect is a terminal feature of liver cell damage/necrosis in CCl₄ intoxication, and which is reduced under the influence of Barrisal. Therefore, it is possible that this preparation having the active ingredient of *A. vera* possesses the following character, on the basis of its possible cellular effect.

- (1) Hepatoprotective effect due to stabilization or strengthening of cell membrane.
- (2) Hepatoprotective effect may also be due to its antioxidative and anti-inflammatory property, which may prevent inflammatory hepatic damage, immunomodulating property and anti-oxidant property, thereby reducing the oxidative stress imposed by the CCl₄.
- (3) Further, Barrisal did not allow CCl₄ to exert its harmful actions and therefore, it can protect liver and kidney functions. Thus, this study provides a rationale for the use of Barrisal as a suitable herbal treatment for the management of liver disorders.

REFERENCES

- Abraham P, Wilfred G, Cathrine SP (1990). Oxidative damage to the lipids and proteins of the lungs, testis and kidney of rats during Carbon tetrachloride intoxication. *Clin. Chim. Acta* 289:177-179
- Agarwal OP (1985). Prevention of atheromatous heart disease. *Angiology* 36(8):485-92.
- Amin A, Nanji A, David Z (1996). In: David Z, Thomas B (eds.), *Hepatology. A textbook of liver disease*. WB Saunders Co., London. P 891.
- Anand KK, Singh B, Saxena AK, Chandan BK, Gupta VN (1994). Hepatoprotective studies of a Fraction from the fruit of *Terminalia bellerica* Roxb. On Experimental liver injury in rodents. *Phytother. Res.* 8:287-292.
- Banskota AH, Tezuka Y, Kadota S (2001). Recent progress in pharmacological research of propolis. *Phytother. Res.* 15:561-571.
- Bezakova L, Oblozinsky M, Sykorova M, Paulikova I, Kostalova D (2005). Antilipoxygenase activity and the trace elements content of Aloe vera in relation to the therapeutic effect. *Ceska Slov. Fam.* 54(1):43-6.
- Capasso F, Borrelli R, Capasso G, DiCarlo AA, Izzo I, Pinto N, Mascolo S, Castaldo R, Longo (1998). Aloe and its Therapeutic Use. *Phytother. Res.* 12:124-127.
- Dixit VP, Varma M, Mathur NT, Mathur R, Sharma S (1992). Hypocholesterolemic and antiatherosclerotic effects of solasodine (C27H42O2N) in cholesterol-fed rabbits. *Phytother. Res.* 6:270-273.
- Durk H, Frank H (1984). Carbon tetrachloride metabolism in vivo and exhalation of volatile alkanes: dependence upon oxygen partial pressure. *Toxicology* 30:249-257.
- Fatima N (1993). Hepatoprotective activity of Icterene. *Hamdard Med.* 36(3):56-62.
- Hutter JA, Salman M, Stavinoha WB, Satsangi N, Williams RF, Streeper RT, Weintraub ST (1996). Antiinflammatory C-glucosyl chromone from Aloe barbadensis. *J. Nat. Prod.* 59:541-543.
- Khan U (1997). *Indusynic Medicine Traditional Medicine of Herbal, Animal and Mineral Origin in Pakistan*, Department of Pharmacognosy, Faculty of Pharmacy, University of Karachi. pp. 269-270, 325-326, 397-398.
- Lin SC, Lin CC, Lin Y, Chen CH (1994). Protective effect s of Banzhilian on hepatotoxin-induced liver injuries. *Am. J. Chin. Med.* 22(1):29-42.

- Pohl L, Schulick R, George J (1984). Reductive oxygenation mechanism of metabolism of carbon tetrachloride to phosgene by cytochrome p. 450. *Mol. Pharmacol.* 25:318-324.
- Pohl L, Schulick R, Highet R, George J (1983). Identification of dichloromethyl carbene as a metabolite of carbon tetrachloride. *Biochem. Biophys. Res. Commun.* 117:367-372.
- Rincon AR, Covarrubias A, Pedraza-Chaverri J, Poo JI, Armendariz-Borunda J, Panduro A (1999). Differential effect of CCL4 on renal function in cirrhotic and non cirrhotic rats. *Exp. Toxicol. Pathol.* 51:199-205.
- Ronis MJ, Huang J, Longo V, Tinderberg N, Ingelman-Sundberg M, Badger TM (1998). Expression and distribution of cytochrome P450 enzymes in male rat kidney: effect of ethanol, acetone and dietary conditions. *Biochem. Pharmacol.* 55:123-129.
- Sango R, Germano MP, Angelo V D, Guglielmo M, De Pasquale R (1998). Antihepatotoxic properties of *Entada africana* (Mimosaceae). *Phytother. Res.* 12:S157-S159.
- Strickland FM, Kuchel JM, Halliday GM (2004). Natural products as aids for protecting the skin's immune system against UV damage. *Cutis* 74(5):24-8.
- Szymonik-Lesiuk S, Czechowska G, Stryjecka-Zimmer M, Slomka M, Madro A, Celinski K, Wielosz M (2003). Catalase, superoxide dismutase, and glutathione peroxidase activities in various rat tissues after carbon tetrachloride intoxication. *J. Hepatobiliary Pancreat. Surg.* 10:309-315.
- Tian B, Hua YJ, Ma XQ, Wang GL (2003). Relationship between antibacterial activity of *Aloe* and its anthraquinone compounds *Zhongguo Zhong Yao Za Zhi* 28(11):1034-7.
- Toshikazu N, Fong KL, Edward KL, Steve SA, King MM, Larry O, Poyer JL, Paul BM (1982). Specificity of a Phenobarbital induced cytochrome P-450 for metabolism of Carbon tetrachloride to the trichloromethyl radical. *Biochem. Pharmacol.* 31(5):615-624.
- Yagi A, Takeo S (2003). Anti-inflammatory constituents, *Aloesin* and *Albemennan* in *Aloe* species and effects of tanshinon VI in *Salvia miltiorrhiza* on heart. *Yakugaku Zasshi* 123(7):517-32.
- Zaoui A, Cherrah Y, Mahassini N, Alaoui K, Amarouch H, Hassar M (2002). Acute and chronic toxicity of *Nigella sativa* fixed oil. *Phytomedicine* 9:69-74.
- Zimmerman HJ (1973). Hepatic Failure. In: Gall EA, Mostofi FK (eds.), *The Liver*. William and Wilkins, Baltimore. pp. 384-405.