

## Case Report

# Multiple soft tissue recurrences in a case of central giant cell granuloma – true ‘tumor’ behaviour?

Devi Charan Shetty\*, Aadithya B, Harish Chandra Rai, Anurag Singh, Ajay Kumar and Adesh Manchanda

Department of Oral and Maxillofacial Pathology and Microbiology, I. T. S. Center for Dental Studies and Research, Muradnagar, Ghaziabad (U.P) - 201206, India.

Accepted 26 October, 2010

**Giant cell granulomas (GCGs) of the jaws are lesions that arise either peripherally in periodontal ligament, mucoperiosteum, or centrally in the bone. Histologically, both peripheral and central giant cell granuloma (CGCG) are characterized by the presence of numerous multinucleated giant cells (MGCs) in a prominent fibrous stroma. CGCG are further categorized into aggressive and non aggressive variant. The present case highlights the perplexity in diagnosing CGCGs which are aggressive in nature due to its close proximity with respect to pathology, behaviour and prognosis from giant cell tumors (GCT). The recurrent nature of the present case and the extensive destruction caused in the hard and soft tissues convinces us the need of exploring the possibilities of the so called true ‘tumors’ (giant cell tumors) having a definitive presence in the jaws.**

**Key words:** Giant cell granulomas, fibrous stroma.

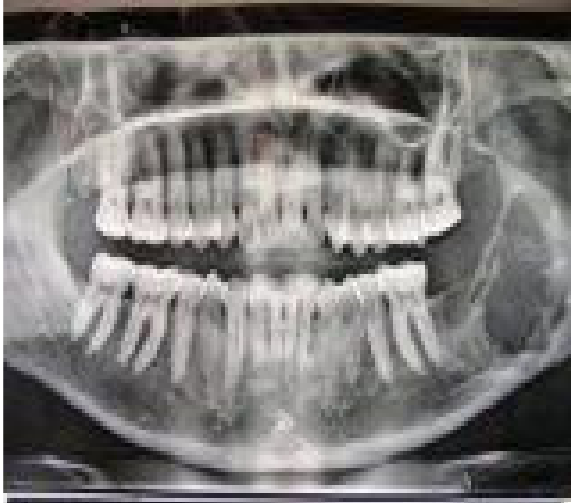## INTRODUCTION

Giant cell granulomas (GCGs) of the jaws are lesions that arise either peripherally in periodontal ligament, mucoperiosteum, or centrally in the bone. Histologically, both peripheral and central variants of giant cell granuloma are characterized by the presence of numerous multinucleated giant cells (MGCs) in a prominent fibrous stroma. Foci of hemorrhage with liberation of hemosiderin pigment and newly formed osteoid or bone are often seen. The MGCs are concentrated in the areas of hemorrhage and are adjacent to blood vessels. Jaffe separated central giant cell granuloma (CGCG) from giant cell tumors (GCT) of the bone on clinical and histologic grounds and suggested that MGCs in CGCG represent a phagocytic response to hemorrhage (Jaffe, 1953)

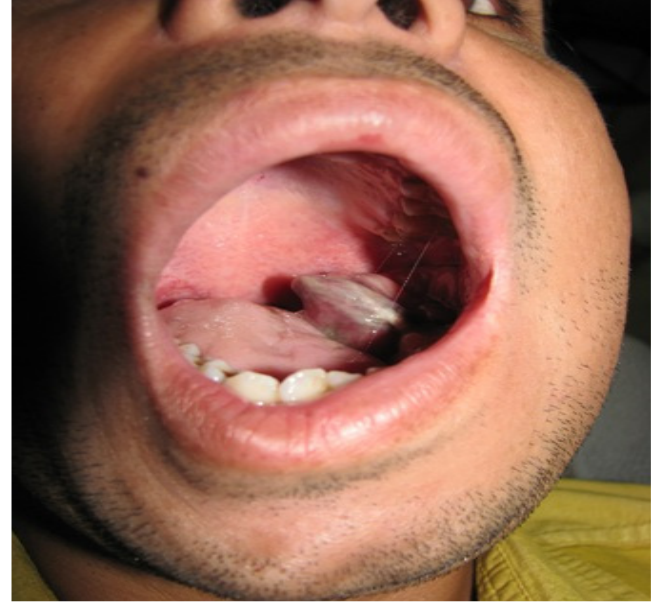CGCG affects females more often than males, in a 2:1 ratio and is seen most frequently under the age of 30 years (Motamedi, 2007). One study of 38 patients shows 74% to be less than 30 years of age and 61% to be less than 20 years of age (Waldron and Shafer, 1966). The

lesion commonly present as a solitary radiolucency with a multilocular appearance or less commonly, a unilocular appearance (Waldron and Shafer, 1966; Whitaker and Waldron, 1993; Kaffe et al., 1996). It is more prevalent in the anterior than the posterior jaws, often crossing the midline, and the mandible is more commonly affected than the maxilla (Waldron and Shafer, 1966; Kaffe et al., 1996). This lesion had also been reported in the small bones of the hands and feet (Lorenzo and Dorfman, 1980; Glass et al., 1983). The behaviour of CGCG is variable, most commonly producing an asymptomatic expansion of the jaws (De Lange and Van den Akker, 2005). However, it can be clinically aggressive, associated with pain, osseous destruction, cortical perforation, root resorption, and recurrence (Kruse, 2006). Cases of CGCG occurring with neurofibromatosis (type 1) (De Lange and Van den Akker, 2005; Ardekian et al., 1999; Ruggieri et al., 1999; Edwards et al., 2006). Noonan-like syndrome (Cohen and Gorlin, 1991; Cancino et al., 2007) or both (De Lange and Van den Akker, 2004; Van Damme and Mooren, 1994) have been reported. The treatment of CGCG includes simple curettage or curettage with peripheral ostectomy; resection for lesions of the maxilla or paranasal sinuses has been advocated as the thin bony cortices and sinuses do not provide a

\*Corresponding author. E-mail: [shettydivya76@rediffmail.com](mailto:shettydivya76@rediffmail.com), [shettydivya76@gmail.com](mailto:shettydivya76@gmail.com). Tel: +91 9873525076.



**Figure 1.** Orthopantomograph showing a unilocular radiolucent lesion in the ramus of left jaw. The inferior border of the lesion is scalloped.



**Figure 2.** Intra oral photograph depicting exophytic growth in the junction of the left pterygomandibular fossa region and buccal mucosa.

good anatomic barrier (Stolovitzky et al., 1994). Corticosteroids and calcitonin are used for non-surgical management (Terry and Jacoway, 1994; de Lange et al., 2006). The current report highlights a case of recurrent and aggressive form of CGCG in the mandible.

## CASE REPORT

A 22 year old man presented with a swelling in the left ramus of the jaw two years ago. Examination revealed a unilocular radiolucent lesion, with a scalloped inferior border (Figure 1). The CT scan revealed a well defined hyperdense soft tissue seen in the region of and below the left coronoid process of mandible, with suspicion of sclerosis. A partial mandibulectomy was performed and a reconstruction plate with a mini plate at the anterior region along with a fibular graft in the jaw was inserted to repair the defect. Microscopy of the biopsied specimen revealed a diagnosis of central giant cell granuloma.

After one year, the patient, now 23 years old, complained of a recurrent swelling in the same region. Intraorally, the patient presented with a growth in the left buccal mucosa at the level of the occlusal plane which was excised and microscopically reviewed. Histopathological examination revealed it as a granuloma. The first molar along with the premolars were removed, the region was curetted and a new reconstruction plate was given.

A year later, the patient now 24 years old, was referred to the Department of Oral Surgery with the complaint of pain and recurrent swelling of the left jaw. (The patient had difficulty in opening the mouth. There was no paraesthesia and both medical and familial histories were non contributory.

Clinically, the lesion extended from the corner of the

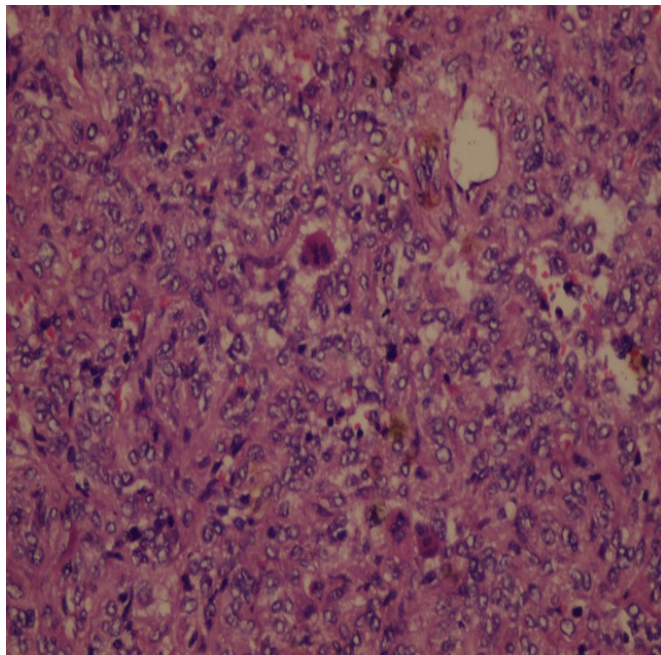
mouth to the anterior part of tragus on the left side, which was 4 × 4 cm in size, irregular in shape with a rough texture. The swelling was hard in consistency, showed no secondary changes and was non tender on palpation.

Intraoral examination revealed an exophytic growth present posteriorly near the junction of the buccal mucosa and pterygomandibular fossa region, at the level of the occlusal plane, sized 1 × 1.5 cm and soft in consistency. It had a smooth surface with no fluctuation on palpation (Figure 2).

Presently, the CT scan revealed an evidence of an expansile destructive mass (4.3 × 3.8 × 4.3 cm in the maximum anteroposterior, transverse and supero-inferior dimensions) in the expected location of the left coronoid process, with thin residual septae like areas of osseous density seen in a large soft tissue mass. This soft tissue mass showed near isodensity compared to the adjacent muscles of the left masseteric space. The lesion expanded the insertion of the left temporalis muscle and bulged anteriorly into the left buccal space and posteriorly into the left condylar head and neck and left parotid gland. Medially, the lesion led to mild pressure erosion with thinning of the buccal cortex of the left maxillary tuberosity and bulged against the left medial pterygoid muscle.

Routine haemogram and urine examination were normal. On the basis of clinical and radiological examination, a provisional diagnosis of CGCG was made. The serum chemistry of calcium, phosphorous, parathyroid hormone was normal, there by excluding the possibility of hyperparathyroidism.

Surgery was performed by a submandibular incision at the site of the previous scar, with the removal of the



**Figure 3.** Photomicrograph showing giant cells in a vesiculated fibroblast connective tissue stroma (H & E, X40).

reconstruction plate, mini plate and graft, along with the condyloid process. The tumor mass and the margins of the normal tissue were removed. A careful and thorough curettage of the residual bone cavity was performed. The defect was repaired by a reconstruction plate attached to a condylar graft.

Histopathological examination of excised specimen revealed evenly dispersed (2 - 3 / HPF) giant cells each having 2 to 8 nuclei in them, in close approximation with proliferating blood vessels admixed with areas of haemorrhage. The connective tissue was minimal with vesiculated fibroblast proliferation (Figure 3). The tumor mass had infiltrating margins and residual bony spicules towards the periphery. Even the bone graft attached to the condyle showed the presence of tumor giant cells. The patient is under follow up for any further changes.

## DISCUSSION

CGCG is a nonneoplastic proliferative lesion of unknown etiology. The etiopathogenesis of the CGCG of jawbones has not been clearly established but it has been suggested that it is the result of an exacerbated reparative process related to previous trauma and intraosseous haemorrhage that triggers the reactive granulomatous process (Ustundag et al., 2002; Kauzman et al., 2004). Donoff and Rosenberg (1993) claimed the local changes in the blood flow throughout the bone and local bone dysplasia could be probable etiologic factors. Association of t (X; 4) (q22; q31.3) in the etiology of GCG

had been reported (Buresh et al., 1999)

Although CGCGs are benign osseous lesions, some authors separate CGCG into two types, referring to its clinical and radiographic features: (a) Non aggressive lesion, usually slow growing and asymptomatic, does not show cortical resorption by the lesion or root perforation in teeth affected, and it is significantly less likely to recur than the aggressive type (Eisenbud et al., 1988), and (b) Aggressive lesions, usually found in younger patients and is painful, grows rapidly, is larger, often causes cortical perforation and root resorption and has a tendency to recur (Chuong et al., 1986). Predicting the behaviour of CGCGs that will exhibit a higher risk of recurrence after treatment had been problematic. The rate of recurrence varies between 13 to 49% (de Lange et al., 2004). Whitaker and Waldron (1993) reported a mean interval between diagnosis and initial treatment and treatment of a recurrence was 21 months, and stated that very few recurrences were manifested after 2 years of initial treatment. The present case shows two recurrences in the past two years. There has been studies suggesting that the greater functional surface area occupied by giant cells and larger relative size of giant cells may identify tumours with aggressive behaviour (Chuong et al., 1986; Yamaguchi and Dorfman, 2001) Recently, Kruse-Loser et al. (2006) also proved that the aggressive variant of CGCG presented a high number of giant cells, an increased mitotic activity, and a high fractional surface area. However, other studies have not been able to predict the clinical course of CGCGs from known histological or immunohistochemical features (Kauzman et al., 2004)

We reviewed the archival cases of 10 CGCGs from our department which were nonaggressive and non recurrent, the demographical information, location, radiographic features and histopathological features and compared with the present case.

The present case showed 2 to 3 giant cells per high power field, which was less compared to that seen in our archival cases. The connective tissue was minimal, but with a high cellularity and a vesiculated fibroblast population. The non aggressive cases of CGCG showed a minimal - moderate cellularity and a non vesiculated fibroblast population. The vascularity in the present case was minimal, which was not a differentiating factor, as cases in which the archives showed varied vascularity from minimal to mark. Comparing the aggressive variant and the non aggressive variants, it is quite evident that the number of giant cells and number of nuclei within alone does not determine aggressive nature and recurrence of CGCG.

The radiological appearance of the lesion is not pathognomonic and may be confused with that of many other lesions of jaws. The final diagnosis eventually rests on histopathology because the clinical and radiological features are not specific (Ebrahimi et al., 2008).

CGCG is composed of two distinct populations of cells which include multinucleated giant cells and spindle shaped stromal cells. The latter are thought to be proliferating

tumour cells based on available evidence. (Liu et al., 2003; Itonaga et al., 2003) These are osteoblast like cells with similar functions. They induce osteoclast formation from mononuclear blood cells via RANK- RANKL interaction. RANKL (receptor activator of nuclear factor kb ligand) present on stromal cells influences the differentiation of giant cells from RANK expressing mononuclear cells (Miyamoto et al., 2000)

Amongst all, GCT is most difficult to differentiate from CGCG without clinical and histological aids. CGCG generally occurs at younger age than GCT. Histologically, CGCG has a hemorrhagic background with presence of plump bland fibroblast, haemosiderin and fewer giant cells with smaller number of nuclei which are less uniformly distributed. While in case of GCT, giant cells are uniformly scattered with larger number of nuclei and absence of fibroblasts and hemorrhage. Diffuse sheets of large giant cells and polygonal mononuclear cells seen in GCT are lacking in CGCG. Deposition of osteoid is observed in CGCG sometimes which is lacking in GCT (Mark et al., 2001).

Immunohistochemical studies on CGCG have helped to establish the lineage of the cells, but not to predict the aggressiveness of the lesion. Supporting the theory that the multinucleated giant cells are derived from macrophages is the immunoreactive response to muramidase,  $\alpha$ -1antichymotrypsin, and  $\alpha$ -1antitrypsin (Regezi et al., 1987). Calcitonin receptor expression, however, had been found to exhibit a statistically significant difference with more expression in the aggressive type (Tobon-Arroyave et al., 2005)

## CONCLUSION

Although extensive literature had been made available to the readers who envisage a keen interest in CGCG of the jaw, clarity to this entity with respect to terminology, behaviour and its adjunctive nature to the GCT occurring in long bones has rarely been lucid in its understanding. The present case highlights the perplexity in diagnosing CGCGs which are aggressive in nature due to its close proximity with respect to pathology, behaviour and prognosis from GCT. The recurrent nature of the present case and the extensive destruction caused in the hard and soft tissues convinces us the need of exploring the possibilities of the so called true 'tumors' (giant cell tumors) having a definitive presence in the jaws.

## REFERENCES

- Ardekian L, Manor R, Peled M (1999). Bilateral central giant cell granulomas in a patient with neurofibromatosis: report of a case and review of the literature. *J. Oral Maxillofac. Surg.*, 57: 869–872.
- Buresh CJ, Seemayer TA, Nelson M, Neff JR, Dorfman HD, Bridge J (1999). t(X;4)(q22;q31.3) in giant cell reparative granuloma. *Cancer Genet. Cytogenet.* 115: 81–91.
- Cancino CM, Gaiao L, Sant'Ana Filho M (2007). Giant cell lesions with a Noonan-like phenotype: a case report. *J. Contemp. Dent. Pract.*, 8: 67–73.
- Chuong R, Kaban LB, Kozakewich H, Perez-Atayde A (1986). Central giant cell lesions of the jaws: a clinicopathologic study. *J. Oral Maxillofac. Surg.*, 44: 708–713.
- Cohen MM Jr, Gorlin RJ (1991). Noonan-like/multiple giant cell lesion syndrome. *Am. J. Med. Genet.*, 40: 159–166.
- De Lange J, Van den Akker HP (2005). Clinical and radiological features of central giant-cell lesions of the jaw. *Oral Surg. Oral Med. Oral Pathol. Oral Radiol. Endod.*, 99: 464–470.
- De Lange J, Van den Akker HP, Veldhuijzen van Zanten GO (2006). Calcitonin therapy in central giant cell granuloma of the jaw: a randomized double-blind placebo-controlled study. *Int. J. Oral Maxillofac. Surg.*, 35:791–795.
- De Lange J, Van den Akker HP, Klip H (2004). Incidence and disease-free survival after surgical therapy of central giant cell granulomas of the jaw in the Netherlands. *Head Neck.* 26: 792-795.
- Donoff RB, Rosenberg AE (1993). Case records of the Massachusetts General Hospital. Weekly clinicopathological exercises. Case 20-1993. A 23-year-old woman with a rapidly enlarging intraoral mass after a tooth extraction. *N. Engl. J. Med.* 328: 1478-1483.
- Ebrahimi H, Yazdani J, Pourshahidi S, Esmaeli F, Zenouz AT, Mehdipour M (2008). Central giant cell granuloma of the posterior maxilla: A case report. *JODDD.* 2(2):71-75.
- Edwards PC, Fantasia JE, Saini T (2006). Clinically aggressive central giant cell granulomas in two patients with neurofibromatosis 1. *Oral Surg. Oral Med. Oral Pathol. Oral Radiol. Endod.*, 102: 765–772.
- Eisenbud L, Stern M, Rothberg M, Sachs SA (1988). Central giant cell granuloma of the jaws: experiences in the management of 37 cases. *J. Oral Maxillofac. Surg.*, 46: 376-384.
- Glass TA, Mills SE, Fechner RE (1983). Giant-cell reparative granuloma of the hands and feet. *Radiology*, 149: 65–68.
- Itonaga I, Hussein I, Kudo O, Sabokbar A, Watt-Smith S, Ferguson D (2003). Cellular mechanisms of osteoclast formation and lacunar resorption in giant cell granuloma of the jaw. *J. Oral Pathol. Med.*, 32: 224-231.
- Jaffe HJ (1953). Giant cell reparative granuloma, traumatic bone cyst and fibrous (fibro-osseous) dysplasia of jaw bones. *Oral Surg. Oral Med. Oral Pathol.*, 6: 159–175.
- Kaffe I, Ardekian L, Taicher S (1996). Radiologic features of central giant cell granuloma of the jaws. *Oral Surg. Oral Med. Oral Pathol. Oral Radiol. Endod.*, 81:720–726.
- Kauzman A, Li SQ, Bradley G, Bells RS, Wunder JS, Kandel R (2004). Central giant cell granuloma of the jaws: assessment of cell cycle proteins. *J. Oral Pathol. Med.*, 33: 170-176.
- Kruse-Losler B, Diallo R, Gaertner C (2006). Central giant cell granuloma of the jaws: a clinical, radiologic, and histopathologic study of 26 cases. *Oral Surg. Oral Med. Oral Pathol. Oral Radiol. Endod.*, 101: 346–354.
- Liu B, Yu SF, Li T (2003). Multinucleated giant cells in various forms of giant cell containing lesions of the jaws express features of osteoclasts. *J. Oral Pathol. Med.* 32: 367–375.
- Lorenzo JC, Dorfman HD (1980). Giant-cell reparative granuloma of short tubular bones of the hands and feet. *Am. J. Surg. Pathol.*, 4: 551–563.
- Mark DM, George CN, Donald JF (2001). Imaging of Giant Cell Tumor and Giant Cell Reparative Granuloma of Bone: Radiologic-Pathologic Correlation. *Radiographics*, 21: 1283-1309.
- Miyamoto N, Higuchi Y, Tajima M, Ito M, Tsurudome M, Nishio M (2000). Spindle-shaped cells derived from giant-cell tumor of bone support differentiation of blood monocytes to osteoclast-like cells, 18: 647-654.
- Motamedi MH, Eshghyar N, Jafari SM (2007). Peripheral and central giant cell granulomas of the jaws: a demographic study. *Oral Surg. Oral Med. Oral Pathol. Oral Radiol. Endod.*, 103: 39–43.
- Regezi JA, Zarbo RJ, Lloyd RV (1987). Muramidase, alpha-1 antitrypsin, alpha-1 antichymotrypsin, and S-100 protein immunoreactivity in giant cell lesions. *Cancer*, 59: 64–68.
- Ruggieri M, Pavone V, Polizzi A (1999). Unusual form of recurrent giant cell granuloma of the mandible and lower extremities in a patient with neurofibromatosis type 1. *Oral Surg. Oral Med. Oral Pathol. Oral Radiol. Endod.*, 87: 67–72.
- Stolovitzky JP, Waldron CA, McConnel FMS (1994). Giant cell lesions

- of the maxilla and paranasal sinuses. *Head Neck*, 16: 143–148.
- Terry BC, Jacoway JR (1994). Management of central giant cell lesions: an alternative to surgical therapy. *Oral Maxillofac. Surg. Clin. North Am.*, 6: 579–600.
- Tobon-Arroyave SI, Franco-Gonzalez LM, Isaza-Guzman DM (2005). Immunohistochemical expression of RANK, GRalpha and CTR in central giant cell granuloma of the jaws. *Oral Oncol.*, 41: 480–488.
- Ustundag E, Iseri M, Keskin G, Muezzinoglu B (2002). Central giant cell granuloma. *Int. J. Pediatr. Otorhinolaryngol.*, 65: 143-146.
- Van Damme PA, Mooren RE (1994). Differentiation of multiple giant cell lesions, Noonan-like syndrome, and (occult) hyperparathyroidism: case report and review of the literature. *Int. J. Oral Maxillofac. Surg.*, 23: 32–36.
- Waldron CA, Shafer WG (1966). The central giant cell reparative granuloma of the jaws: an analysis of 38 cases. *Am. J. Clin. Pathol.*, 45: 437–447.
- Whitaker SB, Waldron CA (1993). Central giant cell lesions of the jaws: a clinical, radiologic, and histopathologic study. *Oral Surg. Oral Med. Oral Pathol.*, 75: 199–208.
- Yamaguchi T, Dorfman HD (2001). Giant cell reparative granuloma: a comparative clinicopathologic study of lesions in gnathic and extragnathic sites. *Int. J. Surg. Pathol.*, 9: 189-200.