

Review

Desmoid tumours: The aggressive fibromatosis

Arcot Rekha

Sri Ramachandra Medical College and Research Institute, Sri Ramachandra Medical University,
Porur, Chennai 600116, India.

Accepted 2 May, 2013

Desmoid tumours are benign tumours that have a tendency to be locally invasive. We present a desmoid tumour of the lower abdominal wall in a 30 year old female patient, discussed the treatment options and reviewed literature of this uncommon lesion.

Key words: Desmoid, abdominal wall, benign tumour.

INTRODUCTION

Desmoid tumours are histologically benign fibrous neoplasms that arise from musculo-aponeurotic structures throughout the body. The term aggressive fibromatosis is often applied to these lesions to belie their potential for invasion and progressive growth. Although they do not metastasize, clinically their management is similar to low grade fibrosarcomas (Posner et al., 1989). The term desmoid was coined by Muller in 1838, and is derived from the Greek word *desmos*, which means tendon-like.

The desmoid tumours which were originally described in the literature were found in women who had early pregnancy. They are classified into abdominal, extra-abdominal, intra-abdominal and mesenteric, based on their site of occurrence (Poshner et al., 1989).

CASE

A 30 year old woman sought medical opinion for a slowly-growing painless mass in the lower abdomen. The history revealed that it

had grown following her pregnancy 5 years ago, and had been progressively increasing since then. The patient had no history of trauma and was not on oral contraceptives. Examination showed an 8 × 6 cm maximum diameter swelling in the lower abdomen that appeared to be ill-defined on inspection (Figure 1). Palpation showed a well-defined firm swelling that was in the abdominal wall. Ultrasound examination confirmed that the mass was located in the abdominal wall and a computed tomography (CT) scan of the abdomen showed a well-defined parietal wall mass (Figure 2). A needle biopsy showed spindle cells that appeared benign. The patient then underwent laparotomy, during which the mass was found to arise from the lower abdominal musculature and to involve the external and internal aponeurosis lateral to the rectus abdominis muscle. A wide local excision was done and the edges were found to be free of tumour by frozen section. Cut section of the tumour showed a fleshy mass (Figure 3). The abdominal wall was reinforced with an onlay prolene mesh. The final histopathology report stated that the mass is an abdominal wall desmoid tumor

Pathophysiology

Desmoid tumors commonly arise from the rectus abdominis, but

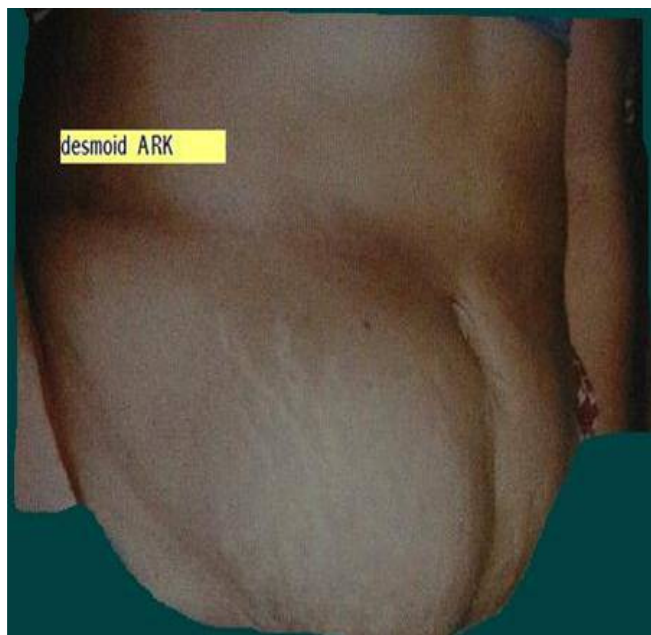


Figure 1. The mass in the lower abdomen.

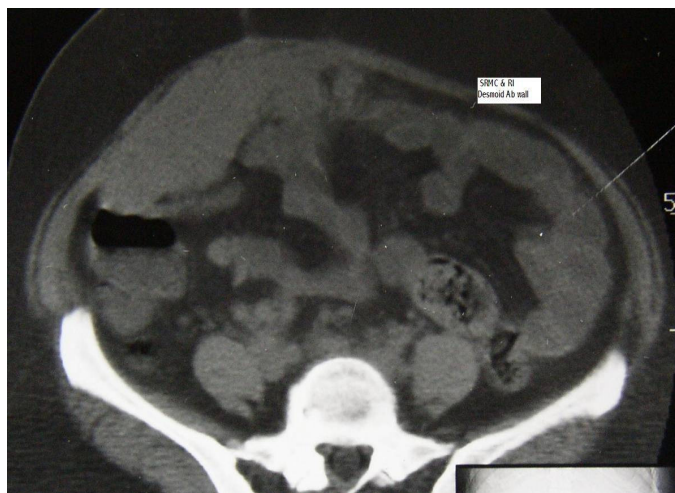

Figure 2. CT shows the mass arising from the right parietal wall of the abdomen.

they can arise from any skeletal muscle (Pack and Ehrlich, 1944). The myofibroblast is thought to be the cell of origin of these benign, but locally invasive lesions (Wu et al., 2010).

Incidence

Desmoid tumors account for approximately 0.03% of all soft tissue tumours and it develops about 1:1000 times more in patients with familial adenomatous polyposis (Shapira et al., 1989) (FAP), where the prevalence reaches 13%. They are more common in women

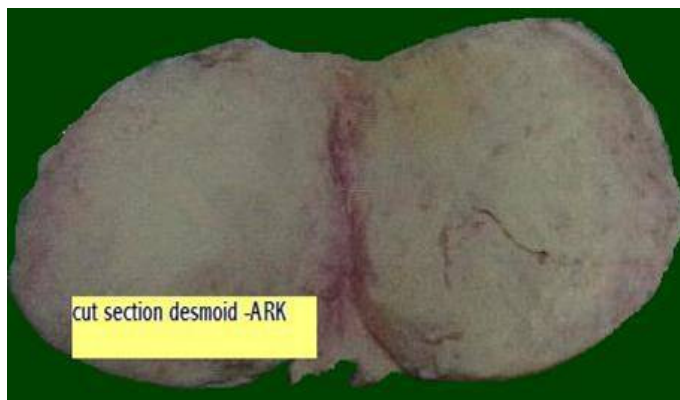


Figure 3. Cut section of the mass shows a fleshy tumour.

(Dequanter and Gebhart, 2002) and in persons aged 10 to 40 years.

Aetiology

Desmoid tumors are commonly noticed post partum, after trauma, abdominal wall surgery and after therapy with oestrogen. A genetic or hereditary aetiology is also observed (Dequanter and Gebhart, 2002). Frequent locations include the abdominal wall (Figure 1) and the root of the mesentery (Sacks et al., 1978). Limb desmoid tumors (Lev-chelouche et al., 1999) have been reported (Figure 2) as well as those of female pelvis (Mariani et al., 2000), the radial nerve (Ferraresi et al., 2001), and the head and neck (Hoos et al., 2000). Desmoid tumors are seen in Gardner's syndrome, where osteomas, benign craniofacial tumours, FAP, congenital hypertrophy of the retinal pigment epithelium, and epidermoid skin cysts are seen (Kawashima et al., 1994).

Role of molecular carcinogenesis

Telomerase activity is required for unlimited growth of cells and is repressed in most somatic tissues but is detectable in immortal cell lines germ cells and malignancies. However, no telomerase activity was detected in desmoid tumours indicating that alternative mechanisms operate in these proliferative neoplasms (Scates et al., 1998).

Clinical features

Women, during their reproductive age often present with a slowly growing painless swelling in sub-umbilical para-rapheal sites. Large lesions or those that compress adjacent nerves can cause pain. Four populations have been defined. These are:

1. Juvenile (age 4.5 ± 3.5 years), where the tumors are usually extra-abdominal.
2. Fertile (age 27.2 ± 4.4 years), in which these tumors commonly develop on the abdominal wall.
3. Middle age (43.9 ± 6.9 years), where the tumor develops on the abdominal wall.
4. Old (68.1 ± 4.4 years), where the lesions are seen in abdominal wall and extra-abdominal sites (Reitamo et al., 1986).

Multifocal desmoid tumors of the extremities have been recognized in young females (Antal et al., 1994; Fong et al., 1993). Kawashima et al. (1994) characterized the difference between patients with desmoids and those with desmoids in the setting of Gardner's syndrome. Desmoids with Gardner's (D/GS) are more likely to be multiple and involve the mesentery and abdominal wall, whereas isolated desmoids are single, and were located in the retroperitoneum. The D/GS group also tend to be smaller than idiopathic desmoids. Follow up revealed new lesions in patients with D/GS compared to the desmoids alone (Kawashima et al., 1994). There is a report of concurrent pheochromocytoma, paraganglioma, papillary thyroid carcinoma, and desmoid tumour (Scopsi et al., 1998). An analysis of RET, adenomatous polyposis coli (APC), TP53 gene mutations and of RET and NTRK1 gene arrangements yielded negative results.

DIAGNOSIS

Clinical acumen is essential to make an initial diagnosis. Imaging using computed tomography (CT) and magnetic resonance imaging (MRI) scans can delineate the extent of the tumour and the anatomic relationship to adjacent structures.

Histology

There is abundant collagen surrounding poorly circumscribed bundles of spindle cells. The dense bundles of eosinophilic spindle cells contain regular nuclei and pale cytoplasm with neither mitoses nor giant cells. Macrophages, giant cells and lymphocytes are present peripherally (Wu et al., 2010). Electron microscopy shows the spindle cells to be myofibroblasts and this probably represents abnormal wound healing where the fibroblasts should disappear. Desmoids have been examined for hormone receptors and have binding sites for oestrogens and anti-oestrogens (Reitamo et al., 1986; Lim et al., 1986; Waddell et al., 1983).

TREATMENT

Surgery

Desmoids are benign lesions which tend to be locally invasive. Therefore, these tumors require wide excision. Surgery remains the treatment of choice for these lesions that cannot be called a sarcoma, as they lack metastatic potential. Recurrence is common, especially in lesions involving the neck, the girdle, and the lower limb (Chatelard et al., 1991). Wide resections may result in considerable defects and functional impairments. Flaps (latissimus dorsi and radial forearm) as well as composite mesh have been used in reconstruction (Brenner and Rammelt, 2002). In a univariate analysis, local failure was more common among patients aged 18 to 30 years, those with marginal or inadequate excision, those who presented with residual disease and those who did not receive radiation for gross residual disease. In a multivariate analysis, only presentation with recurrent disease and inadequate margins of resection were independent prognostic factors. Gender had no influence on survival (Nutting, 2002).

Role of radiotherapy (RT)

In tumours where the resected margins are negative, there is no

role for RT. In lesions with positive resected margins, the role of RT is debatable. However, Ballo advocates adjuvant RT in the dose of 50 Gy (Ballo et al., 1998). Definitive RT is emerging as an alternative to radical surgery. Ballo et al. (1998) reported a 5-year local control rate of 69% for patients treated with RT for a gross disease (the dose for definitive RT is 56 Gy in 2 Gy per fraction to 60 Gy given in 1.8 Gy per fraction) (Goy et al., 1997; Kamath et al., 1996).

Medical treatment

There are well-documented reports of desmoid tumours responding to sulindac (Waddell et al., 1994), nonsteroidal anti-inflammatory drugs (NSAIDS) (Waddell et al., 1983), warfarin and Vitamin K (Waddell and Kirsch, 1991). The response can take months and continue for years.

Hormonal therapy

There are anecdotal reports of response to hormonal manipulation, like tamoxifene (Kinzbrunner et al., 1983), testolactone (Waddell et al., 1994), toremifene (Brooks et al., 1992), goserilin, and progesterin (Wikcken and Tattersal, 1991).

Chemotherapy

A response has also been reported with single agent doxorubicin (Seiter and Kemeny, 1993), as well as combination chemotherapy (nitrogen mustard, thio thepa, and methotrexate) (Patel et al., 1993). There is a report of a possible role of isolated limb perfusion with tumour necrosis factor and melphalan in limb desmoids (LevChelouche et al., 1999).

Conclusion

The desmoids tumour is a benign but locally invasive fibromatosis that occur in females in the reproductive age group.

REFERENCES

- Antal I, Szendrői M, Kovacs Gy, Nagyálnai T, Entz L (1994). Multicentric extra abdominal desmoids- a case report: *J. Cancer Res. Clin. Oncol.* 120(8):490-493.
- Ballo M, Zagar G, Pollack A (1998). Radiotherapy in management of desmoid tumours. *Int. J. Radiat. Oncol. Biol. Phys.* 42(5):1007-1014.
- Brenner P, Rammelt S (2002). Abdominal wall and foot reconstruction after extensive desmoid tumour resection with free tissue transfer *Langenbecks Arch. Surg.* 386(8):592-7.
- Brooks MD, Ebbs SR, Colletta AA, Baum M (1992). Desmoid tumours-treatment with triphenylethylene. *Eur. J. Cancer* 28A(6-7):1014-8.
- Nutting CM (2002). *Cancer. Principles and practice of oncology* (6th ed). In: VT DeVita Jr, S Hellman and SA Rosenberg eds. Lippincott Williams & Wilkins, Philadelphia, PA. p 1850.
- Chatelard PA, Gilly FN, Carret JP, Vauzelle JL, Brunat M, Brailion G, Dejour H (1991). Extra abdominal desmoid tumours-therapeutic indications apropos 28 cases. *Acta Orthop. Belg.* 57(3):227-33.
- Dequanter D, Gebhart M (2002). Desmoid tumours. *J. Chir. (Paris)* 139(4):236-9.

- Ferraresi S, Garozzo D, Bianchini E (2001). Aggressive fibromatosis of the radial nerve: Favorable resolution Case report. *J. Neurosurg.* 95(2):332-3.
- Fong Y, Rosen P, Brennan MF (1993). Multifocal desmoids. *Surgery* 114(5):902-6.
- Goy BW, Lee SP, Eilber F, Dorey F, Eckardt J, Fu YS, Juillard GJ, Selch MT (1997). Role of adjuvant radiotherapy in treatment of resectable desmoid tumours. *Int. J. Radiat. Oncol. Biol. Phys.* 39(3):659-65.
- Hoos A, Lewis JJ, Urist MJ, Shaha AR, Hawkins WG, Shah JP, Brennan MF (2000). Desmoid tumours of the head and neck-a clinical study of a rare entity *Head Neck* 22(8):814-21.
- Kamath SS, Parsons JT, Marcus RB, Zlotecki RA, Scarborough MT (1996). Radiotherapy for local control of aggressive fibromatosis. *Int. J. Radiat. Oncol. Biol. Phys.* 36(2):325-8.
- Kawashima A, Goldman SM, Fishman EK, Kuhlman JE, Onitsuka H, Fukuya T, Masuda K (1994). CT of intra-abdominal desmoid-is the tumour different in patients with Gardner's disease? *AJR Am. J. Roentgenol.* 162(2):339-42.
- Kinzbrunner B, Ritter S, Doming J, Rosenthal CJ (1983). Remission of rapidly growing desmoid tumours after tamoxifene therapy. *Cancer* 52(12):2201-4.
- Lev-Chelouche D, Abu-Abeid S, Nakache R, Issakov J, Kollander Y, Merimsky O, Meller I, Klausner JM, Gutman M (1999). Limb desmoid tumours: A possible role for isolated limb perfusion with tumour necrosis factor alpha and melphalan. *Surgery* 126(5):963-7.
- Lim CI, Walker MJ, Mehta RR, Das Gupta TK (1986). Estrogen and anti-estrogen binding sites. *Eur. J. Cancer Clin. Oncol.* 22(5):583-7.
- Mariani A, Nascimento AG, Webb MJ, Sim FH, Podratz KC (2000). Surgical management of desmoid tumours of the female pelvis. *J. Am. Coll. Surg.* 191(2):175-83.
- Pack, GT, Ehrlich HE (1944). Neoplasms of the anterior abdominal wall with special consideration of desmoids tumors. Experience with 391 cases and a collective review of the literature. *Int. Abstr. Surg.* 79:177-198.
- Patel SR, Evans HL, Benjamin RS (1993). Combination chemotherapy in adult desmoid tumours. *Cancer* 72(11):3244-7.
- Posner MC, Shiu MH, Newsome JL, Hajdu SI, Gaynor JJ, Brennan MF (1989). Desmoid tumours-not a benign disease. *Arch. Surg.* 124(2):191-6.
- Reitamo JJ, Scheini T, Hayry P (1986). The desmoid syndrome-new aspects in the cause pathogenesis and treatment of desmoid tumours. *Am. J. Surg.* 151(2):230-7.
- Sacks B, Joffe N, Harris N (1978). Isolated mesenteric desmoids (mesenteric fibromatosis). *Clin. Radiol.* 29(1):95-100.
- Scates DK, Clark SK, Phillips RK, Venitt S (1998). Lack of telomerase in desmoids occurring sporadically and in association with familial adenomatous polyposis. *Br. J. Surg.* 85(7):965-9.
- Scopsi L, Cozzaglio L, Collini P, Gullo M, Bongarzone I, Giarola M, Radice P, Gennari L (1998). Concurrent phaeochromocytoma paraganglioma, papillary thyroid carcinoma and desmoid tumour. *Endocr. Pathol.* 9(1):79-90.
- Seiter K, Kemeney N (1993). Successful treatment of desmoid tumours with doxorubicin. *Cancer* 71(7):2242-4.
- Shapira O, Mavor E, Pfefferman R (1989). Retroperitoneal desmoids and familial polyposis coli: Harefuah 116(2):98-101.
- Waddell WR, Gerner RE, Reich MP (1983). NSAIDS and tamoxifen for desmoid tumours. *J. Surg. Oncol.* 22(3):197-211.
- Waddell WR, Kirsch WM (1991). Testolactone, sulindac, warfarin and Vit K for unresectable desmoid tumours *Am. J. Surg.* 161:416-21.
- Wikcken N, Tattersall MM (1991). Endocrine therapy for desmoid tumours. *Cancer* 68(6):1384-8.
- Wu C, Amini-Nik S, Nadesan P, Stanford WL, Alman BA (2010). Aggressive fibromatosis (desmoid tumor) is derived from mesenchymal progenitor cells. *Cancer Res.* 70(19):7690-8.