

Full Length Research Paper

# Evaluation of experimental infection with *Aeromonas hydrophila* in pacu (*Piaractus mesopotamicus*) (Holmberg, 1887)\*

Silvia Patrícia Carraschi<sup>1,2\*</sup>, Claudinei da Cruz<sup>2</sup>, Joaquim Gonçalves Machado Neto<sup>3</sup>, Flávio Ruas de Moraes<sup>4</sup>, Oswaldo Durival Rossi Júnior<sup>5</sup>, Antonio Nader Neto<sup>2</sup> and Neida Lucas Bortoluzzi<sup>4</sup>

<sup>1</sup>Centro de Aquicultura (Aquaculture Center) at Unesp – Jaboticabal Campus – São Paulo – Brazil.

<sup>2</sup>Núcleo de Estudos e Pesquisas Ambientais em Matologia (NEPEAM) (Weed Science Environmental Research Studies Centre) of the College of Agricultural and Veterinary Sciences at Unesp - Jaboticabal – São Paulo – Brazil.

<sup>3</sup>Laboratório de Ecotoxicologia dos Agrotóxicos e Saúde Ocupacional (Laborseg) (Pesticides Ecotoxicology and Occupational Health Lab) of the College of Agricultural and Veterinary Sciences at Unesp - Jaboticabal – São Paulo Brazil.

<sup>4</sup>Laboratório de Ictiopatologia (Fish Pathology Lab) of the College of Agricultural and Veterinary Sciences at Unesp - de Jaboticabal – São Paulo – Brazil.

<sup>5</sup>Departamento do Medicina Veterinária Preventiva (Preventive Veterinary Medicine Department) of the College of Agricultural and Veterinary Sciences at Unesp - Jaboticabal – São Paulo – Brazil.

Accepted 21 October, 2011

The aim of this work is to determine the concentration of *Aeromonas hydrophila* to be inoculated in pacu (*Piaractus mesopotamicus*), so as to induce bacterial infection but not death during a period of at least ten days and, therefore, enable the development of treatment protocols. The tested concentrations were established through the Mac Farland scale and fish were subjected to three *A. hydrophila* infection concentrations ( $1.2 \times 10^7$ ,  $2.4 \times 10^7$  and  $1.5 \times 10^8$  UFC.mL<sup>-1</sup>) through intracoelomic, intramuscular and subcutaneous injections. The clinical exam was done 24 h after inoculation, and the clinical signs suggested aeromonosis in all three groups. In the lowest concentration, animals demonstrated few clinical signs of disease, and in the highest concentration, all animals died within 24 h of aeromonosis induction with acute infection. In the intermediate concentration ( $2.4 \times 10^7$  UFC.mL<sup>-1</sup>), all animals presented clinical signs of aeromonosis and kept living at the beginning of the time of treatment. Therefore,  $2.4 \times 10^7$  UFC mL<sup>-1</sup> concentration was defined as viable for the study of experimental infection in pacu by *A. hydrophila*, as the fishes were kept alive at the beginning of the time of treatment protocol with pharmochemicals.

**Key words:** Bacterial infection, fish, disease, antibiotics.

## INTRODUCTION

The pacu (*Piaractus mesopotamicus*) is one of the native species that is mostly cultivated in Southeast and Midwest of Brazil showing great commercial value among the ones that have excellent flavor of meat. Its fast

growth and easy adaptation to artificial food can be explored for sport fishing. During the creation cycle, occurrence of many pathogens causes high mortalities and many economic losses. Among pathogens, the bacterium has the biggest problem. *Aeromonas hydrophila* is an integrant bacterium of intestinal microbiota of healthy fish (Trust et al., 1974), whose presence is not indicative of the disease caused by it; however, the stress presented in intensive fish farming is

\*Corresponding author. E-mail: [pacarraschi@yahoo.com.br](mailto:pacarraschi@yahoo.com.br).  
Tel: (+5516) 3209-2630.

the principal factor responsible for the outbreaks caused by this pathogen (Cipriano, 2001).

These bacteria cause hemorrhagic sepsis, characterized by small superficial wounds and localized bleeding which evolve to epidermal wounds, as petechiae in the gill and opercula, exophthalmia, celomatic distension and necrosis of internal muscular tissue (Harikrishnan, 2003). Considering losses related to high fish mortality in fish farming caused by aeromonosis, the need arises for experimental infection methods that enable the study of this pathogen and the development of possible treatment protocols, in order to establish adequate concentrations and doses of pharminochemicals to be used in the treatment of diseases in fish farming.

Thus, the aim of this work is to determine the appropriate concentration of *A. hydrophila* that should be inoculated in pacu (*P. mesopotamicus*), in order to induce bacterial infection but not death during a period enough to develop treatment protocols.

## MATERIALS AND METHODS

### Infection induction by *A. hydrophila*

The fish were from Aquaculture Center of Unesp-Jaboticabal Campus (São Paulo – Brazil) and the experiments were carried out in Weed Science Environmental Research Studies of Agricultural and Veterinary Science (NEPEAM) and in the Veterinary Pathology of the University Unesp - Jaboticabal (São Paulo – Brazil).

In the performance of this experiment, pacu (*P. mesopotamicus*) were used, weighing an average of  $33.08 \pm 5.0$  g. The fish (n=120) were kept in a 400 L tank and were captured twice a day for four days. After the fish was captured, they were immersed in water for two minutes in order to increase stress levels and decrease immunity (Garcia and Moraes, 2009).

After this period of stress induction, fish (n=12 for each experimental group) underwent infection by *A. hydrophila* through intracoelomic, intramuscular and subcutaneous injections of 0.2 mL bacterial solution with the following concentrations: control group with sterile saline solution and groups with  $1.2 \times 10^7$ ;  $2.4 \times 10^7$  and  $1.5 \times 10^8$  UFC.mL<sup>-1</sup> of saline solution<sup>-1</sup> (Mac Farland scale). They were distributed in 60 L tanks (n=12) for clinical evaluation.

After 24 h of the inoculation, two animals of each group were euthanized by immersion in a benzocaine bath (1 g.15 L<sup>-1</sup> of water) so as to evaluate clinical signs in internal organs. The clinical signs evaluated were corrosion of fins, exophthalmia, ascites and hemorrhaging of the tegument. Pigmentation, fibrin deposition, bleeding in internal organs – such as liver and kidney, and edema in the coelomic cavity were observed in necropsy (Harikrishnan, 2003).

The water quality variables were measured during the experiment and they were appropriate for the specie in the initial conditions: temperature  $25 \pm 2^\circ\text{C}$ ; pH between 6.5 and 7.5; dissolved oxygen between 7.0 and 8.0 mgL<sup>-1</sup> and electrical conductivity between 180.0 and 185.0  $\mu\text{S.cm}^{-3}$ . These were measured with YSI 556 MPS multiparameters prober (Yellow Springs).

### Reisolation of *A. hydrophila*

The animals euthanized for 24 h after experimental infection had samples of liver, integument and a swab of head kidney taken, as

well as a sample of water from each respective environment, in order to reisolate *A. hydrophila* bacteria. The liver, kidney and water samples (n=12 for each) were incubated in liquid tryptic soy agar (TSA) for enrichment and after 24 h later, was made to undergo plating in tryptone soy broth (TSB) with ampicillin and were incubated again for 24 h. From the cell cultures obtained from selective plating with ampicillin broth (TSB), the colonies that suggested *Aeromonas* sp. were selected and subcultured in phenol red starch ampicillin agar and in dextrin-ampicillin agar.

After the incubation period (24 h), the colonies were submitted at several biochemical tests like: Gram technique; triple-sugar iron agar (TSI) (Saad et al., 1995); motility tests (Mac Faddin, 1976) and oxidase test. The cell cultures that presented motility and positive oxidase characteristics were considered as *Aeromonas* sp.

For the phenotypic identification of the *A. hydrophila* specie, Aerokey II classification key was used (Carnahan et al., 1991) presenting the following evidence: esculin hydrolysis; gas from glucose; Voges-Proskauer (VP) and acid from arabinose.

## RESULTS AND DISCUSSION

### Infection induction by *A. hydrophila*

The experimental infection using  $1.2 \times 10^7$  UFC of *A. hydrophila* did not induce any clinical sign in the fish; with  $1.5 \times 10^8$  UFC mL<sup>-1</sup>, all the fish died within 24 h of induction and this was considered as the lethal concentration for this species (DL 50). The concentration of  $2.4 \times 10^7$  UFC mL<sup>-1</sup> induce the clinical signs, but was not lethal and the fish lived after inoculation, realizing the clinical signs and it is possible to begin a treatment protocol for this bacterium.

The effects of *A. hydrophila* in fish can vary according to the resistance to infection (Schlotfeldt and Alderman, 1995) and with the size of the animal (Oliveira et al., 2011). For this reason, different studies are faced with the challenge of knowing the sensibility of each fish species to this bacterium (Table 1), which is responsible for high mortality rates of fish farming.

The challenge with this bacterium helps in the development of treatment protocols for this bacterial, this is necessary to perform the infection of the fish with bacterium and test the pharminochemicals concentrations to know the efficacy and security of the method used in treatment.

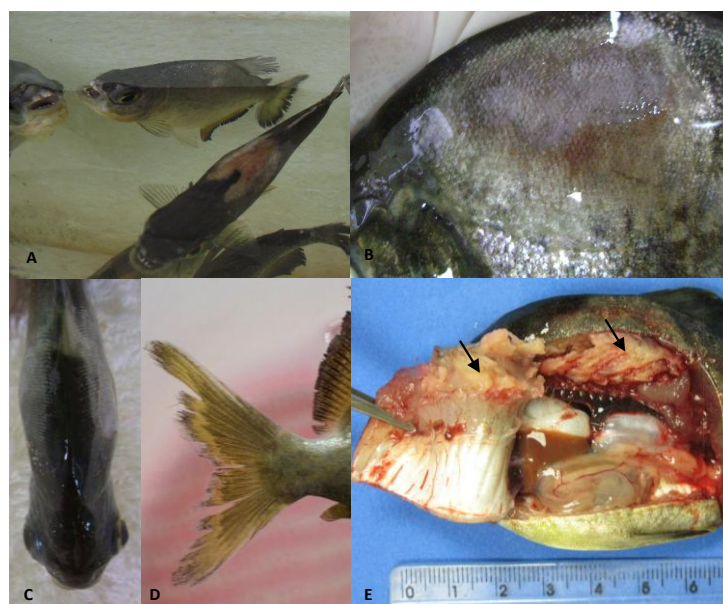
Then, establish the concentration which challenges the fish and keep them living from the beginning of the treatment; it is very important to test the pharminochemicals efficacy. Thus, the results of this research are inserted in this phase of the pharminochemicals development process.

### Reisolation

After 24 h of induced infection, animals presented signs that characterize aeromonosis such as: coelom distension (caused by accumulation of ascitic liquid) (Figure 1c); deep erosion wounds and both sides of tegument with red borders (Figure 1a, b); corrosion of caudal fin (Figure 1d); exophthalmia (Figure 1c). In

**Table 1.** Concentrations of *A. hydrophila* infection for several species.

Concentration (UFC.mL <sup>-1</sup> )	Specie	Signs	References
1.2×10 <sup>7</sup>	<i>P. mesopotamicus</i>	Any signal	This work
2.4×10 <sup>7</sup>	<i>P. mesopotamicus</i>	Fish realizing the clinical signs	This work
1.5 × 10 <sup>8</sup>	<i>P. mesopotamicus</i>	Fish died in 24 h	This work
8.6 × 10 <sup>4</sup>	<i>Plecoglossus altivelis</i>	LD50	Temminck and Schlegel (1846)
>10 <sup>8</sup>	<i>Anguilla japonica</i>	LD50	Temminck and Schlegel (1846)
>10 <sup>8</sup>	<i>Lepomis macrochirus</i>	LD50	Santos et al. (1991)
2.0 × 10 <sup>5</sup>	<i>Salmo trutta</i>	LD50	Santos et al. (1991)
>10 <sup>8</sup>	<i>Anguilla japonica</i>	LD50	Santos et al. (1991)
8.6×10 <sup>4</sup>	<i>Plecoglossus altivelis</i>	DL50	Santos et al. (1991)
1.3 × 10 <sup>9</sup> and 3.5 × 10 <sup>8</sup>	<i>Rhamdia quelen</i>	Lethal	Boijink and Brandão, (2001)
10 <sup>6</sup>	<i>Cyprinus carpio</i>	10% mortality in the 10 days	Harikrishnan et al. 2003
10 <sup>9</sup>	<i>Cyprinus carpio</i>	90% mortality 10 days after inoculation	Harikrishnan et al. (2003)
10 <sup>7</sup>	<i>Salmo salar</i>	95% mortality after 5 days	Ellis et al. (2007)
10 <sup>7</sup>	<i>Oncorhynchus mykiss</i>	mortality 14 days after infection induction	Nya and Austin (2009)
9×10 <sup>9</sup>	<i>Cyprinus carpio</i>	Increase of the production of mucus	Van der Marel et al. (2010)
6.66×10 <sup>11</sup>	<i>Brycon amazonicus</i>	LD50	Oliveira et al., 2011



**Figure 1.** Clinical signs of infection by *A. hydrophila*. A, Bilateral wounds; B, epidermis wounds with red borders; C, coelom distension and exophthalmia; D, corrosion of caudal fin; E, muscle necrosis, Arrow, necrosis of site of inoculation.

necropsy, the liver was friable and presented yellow pigmentation, kidneys from animals in the group with highest concentration presented a thin layer of fibrin and muscle presented necrosis on the site of inoculation (Figure 1e). Clinical signs were also observed in *Rhamdia quelen* (Quoy and Gaimard, 1824; Boijink and Brandão, 2001) and *Ictalurus punctatus* (Rafinesque,

1818); cyprinids, eels and trout (Plumb, 1994) and many teleost fish species (Miyazaki and Kaige, 1985) were infected by *A. hydrophila*.

The fish presented necrosis only on the site of bacterium inoculation in muscle tissue (Figure 1e). However, in freshwater fish, hemorrhaging and necrosis of the kidney occurred (Schlotfeldt and Aldermam, 1995)

**Table 2.** Biochemical tests of the samples from pacu.

Biochemicals tests	Results
TSA	+
TSB	+
Gram-negative	+
TSI	+
Motility tests	+
Oxidase tests	+
Esculin hydrolyze	+
VP test	+
Arabinose test	+

when they were infected by the same bacterium. The bacterial growths obtained from the samples were collected through swabs after undergoing biochemical tests. Table 2 proved that the bacterium used in this study is *A. hydrophila*.

### Conclusion

The  $2.4 \times 10^7$  UFC mL<sup>-1</sup> concentration was defined as viable for the study of experimental infection in pacu by *A. hydrophila*, due to the fact that it gave the fish a good living condition at the time of the treatment protocol with pharminochemicals.

**Abbreviations:** **TSA**, Tryptic soy agar; **TSB**, tryptone soy broth; **TSI**, triple-sugar iron agar; **VP**, Voges-Proskauer.

### REFERENCES

- Boijink CJ, Brandão DA (2001). Histological and behavioral changes caused by incubation of bacterial suspension (*Aeromonas hydrophila*) in juvenile catfishes (*Rhamdia quelen*). Rural Sci., 31(4): 687-690.
- Carnahan AM, Behram S, Joseph SW (1991). Aerokey II: A flexible key for identifying clinical aeromonas species. J. Clin. Microb., 29: 2843-2849.
- Cipriano RC (2001). *Aeromonas hydrophila* and motile aeromonad septicemias of fish. Fish Dis. Leaf, 68, 1-25.
- Ellis T, Bagwell N, Pond M, Baynes S, Scott AP (2007). Acute viral and bacterial infections elevate water cortisol concentrations in fish tanks. Aquac., 272: 707-716.
- Garcia F, Moraes FR (2009). Hematology and clinical signs of *Piaractus mesopotamicus* experimentally infected with *Aeromonas hydrophila*. Acta Sci. Biol. Sci., 31(1): 17-21.
- Harikrishnan R, Nisha RM, Balasundaram C (2003) Hematological and biochemical parameters in common carp, *Cyprinus carpio*, following herbal treatment for *Aeromonas hydrophila* infection. Aquac., 221: 41-50.
- Mac FJF (1976). Biochemical tests for identification of medical bacteria. Baltimore: The Williams and Wilkins Co, p. 312.
- Miyazaki TJ (1985). A histopathological study of motile *Aeromonas* disease in ayu. Fish Path., 20: 55-59.
- Nya EJ, Austin B (2009). Use of dietary ginger, *Zingiber officinale* Roscoe, as an immunostimulant to control *Aeromonas hydrophila* infections in rainbow trout, *Oncorhynchus mykiss* (Walbaum). J. Fish Dis., 32: 971-977.
- Oliveira SR, Souza RTYB, Brasil EM, Andrade JIA, Nunes, ÉS, Ono, EA, Affonso, EG (2011). LD50 of the bacteria *Aeromonas hydrophila* to matrinxã, *Brycon amazonicus*. Acta Am., 41(2): 321 - 326.
- Plumb JA (1994). Health maintenance of cultured fish. Principal microbial diseases. USA : CRC, p. 254.
- Saad SMI, Iaria ST, Furlanetto SMP (1995). Motile *Aeromonas* spp. in retail vegetables from São Paulo, Brazil. Microb. Mag., 26(1): 22-27.
- Santos Y, Bandín I, Nieto TP, et al. (1991). Cell-surface-associated properties of fish pathogenic bacteria. J. Aqu. An. Heal., 3: 297-301.
- Schlotfeldt HJ, Alderman DJA (1995). Practical guide for the fresh water fish farmer. Bull. Eur. Ass. Fish Pathol. 15(4): 134-157.
- Van der Marel M, Caspari N, Neuhaus H, Meyer W, Enss ML, Wang Q, Li J (2004). Tissue distribution and elimination of oxytetracycline in perch *Lateolabrus japonicus* and black seabream (*Sparus macrocephalus*) following oral administration. Aquac, 237: 31-40.