

Full Length Research paper

# Evaluation of immunohistochemistry with a panel of antibodies against recombinant mycobacterial antigens for the diagnosis of tuberculous lymphadenitis

S. Sumi and V. V. Radhakrishnan\*

Department of Pathology, Sree Chitra Tirunal Institute for Medical Sciences and Technology, Thiruvananthapuram - 695 011, Kerala, India.

Accepted 07 May, 2009

Diagnosis of tuberculous lymphadenitis can be an enigma owing to its varied clinical manifestation and also due to the low sensitivity of conventional bacteriological methods to confirm the presence of *Mycobacterium tuberculosis*. The present study was precisely designed to evaluate the potential diagnostic application of immunohistochemistry using a panel of antibodies against mycobacterial antigens for the diagnosis of tuberculous lymphadenitis. Immunohistochemistry was performed on the formalin-fixed paraffin sections of lymph node biopsies using rabbit polyclonal antibodies against four recombinant mycobacterial proteins, that is, ESAT-6, HspX, Tb8.4 and PlcA. The results of immunohistochemistry were correlated with Zeihl-Neelsen staining method. Immunohistochemistry using anti-ESAT-6 antibody was found to be highly sensitive (88.6%). Anti-ESAT-6 and anti-PlcA antibodies were found to be highly specific. Results of the study suggest that immunohistochemistry using anti-ESAT-6 antibody has potential application for the diagnosis of tuberculous lymphadenitis, in patients in whom conventional diagnostic methods did not confirm the presence of acid-fast bacilli.

**Key words:** Immunohistochemistry, tuberculous lymphadenitis, recombinant mycobacterial antigens.

## INTRODUCTION

Tuberculous lymphadenitis (TBL) is the most common clinical manifestation of extra-pulmonary tuberculosis (Appling and Miller, 1981). TBL is also one of the most frequent causes of lymphadenopathy in paediatric age group (Jindal et al., 2003). Diagnosis of TBL is usually made by the relevant clinical manifestations, supported by the characteristic histopathological features of lymph node biopsies, such as presence of granulomatous lesions (with or without caseation). Granulomatous lymphadenitis has extensive differential diagnosis and is known to occur in sarcoidosis, sarcoid-like granuloma-

tous reaction in the draining lymph nodes of malignancies of epithelial origin, fungal infection, parasitic infection (filariasis) and lymphogranuloma venerium. At times, the histopathological features in these diseases resemble closely TBL and can pose considerable diagnostic challenge.

Demonstration of the causative agent – acid-fast bacilli (AFB), *Mycobacterium tuberculosis* either by Ziehl-Neelsen (ZN) staining or by bacteriological culture is considered as the 'gold standard' for the diagnosis of TBL. Earlier published studies indicated that bacteriological methods are time-consuming and less sensitive (Kesarwani et al., 2004). There are two valid reasons that could account for the infrequent isolation of *M. tuberculosis* by conventional methods in TBL patients. (i) *M. tuberculosis* bacilli are often phagocytosed by macrophages and giant-cells in the tuberculous lesions and hence they either become non-viable or their morphological characteristics get distorted (ii) most patients with TBL have received a course of antituberculosis chemotherapy (ATT) prior to lymph node biopsy and hence the number of viable bacilli in lesions becomes sub-optimal.

\*Corresponding author. E-mail: [vv.radhakrishnan@yahoo.com](mailto:vv.radhakrishnan@yahoo.com).  
Tel: 91-471- 2524594, 91-471- 2524508. Fax: 91-471-2446433.

**Abbreviations:** TBL, Tuberculous lymphadenitis; IHC, Immunohistochemistry; AFB, Acid-fast bacillus; ZN, Ziehl-Neelsen; ATT, Antituberculous chemotherapy; FNA, Fine needle aspiration; ESAT-6, Early secreted antigenic target 6-kDa protein; Hsp, Heat shock protein; Plc, Phospholipase C.

TBL is a potentially curable disease with appropriate ATT. Any delay in the institution of ATT either due to inaccurate or delayed diagnosis may result in the dissemination of tuberculous lesions to the adjoining lymph nodes, particularly in immunocompromised subjects. Hence development of alternate diagnostic methods has become extremely relevant in the overall management of patients.

Immunohistochemistry methods have been applied in the diagnosis of infectious diseases including tuberculosis. Demonstration of mycobacterial antigens by immunohistochemistry (IHC) using polyclonal and monoclonal antibodies as an alternative to conventional acid-fast staining has been reported. Different mycobacterial antigens have been detected using immunohistochemical method in pleural tuberculosis (Baba et al., 2008) and intracranial tuberculoma (Sumi et al., 2001).

The present study was initiated to assess the potential application of immunostaining in demonstrating specific antigens of *M. tuberculosis* in the formalin-fixed paraffin sections of lymph nodes.

## MATERIALS AND METHODS

### Study subjects

In this retrospective study, formalin-fixed lymph node biopsies were collected from Department of Pathology, Medical College, Thiruvananthapuram. Paraffin blocks of 71 patients, (male = 39, female = 32) with a clinical diagnosis of lymphadenopathy were selected. The relevant clinical features of these patients were recorded from the case records. The age of these patients ranged between 19 and 65. The duration of lymphadenopathy at the time of biopsy ranged between 20 days and 24 months. (Mean duration = 3.2 months). The salient clinical features in most of these patients were pyrexia, weight-loss, anorexia, elevated erythrocyte sedimentation rate and cervical lymphadenopathy.

Fine needle aspiration (FNA) of the involved lymph nodes was initially attempted, but the aspirated material in most cases was adequate only for undertaking ZN staining and cytological studies. The results of FNA were inconclusive in majority of patients, and hence these patients subsequently underwent excision biopsy of lymph node to ascertain the precise etiological cause of lymphadenopathy. Lymph nodes from different anatomical locations in the cervical region were biopsied. The most common location was supraclavicular followed by posterior cervical, anterior cervical and axilla.

Lymph node specimens were subjected to routine histopathological, and ZN staining. Results of bacteriological culture were obtained from case records. Subsequently the IHC was performed on the paraffin sections using a panel of antibodies against *M. tuberculosis*.

### Patient groups

(A) In four patients, *M. tuberculosis* was demonstrated in the lymph nodes by ZN method. Haematoxylin and Eosin (H and E) stained paraffin sections of lymph nodes in these patients showed caseating granulomatous lesions. They were 'culture-positive' as per the case records. Hence these four cases were categorized as 'confirmed' TB-L cases.

(B) In thirty-one patients, there were histopathological evidences of caseating / non-caseating granulomatous lesion in lymph nodes but AFB was not demonstrated. Based on the relevant clinical features supported by compatible histopathological features and optimal clinical response to ATT, they were classified as 'probable TB-L'.

(C) In 12 lymph node biopsies, the histopathological features suggested metastatic carcinoma and in 6 patients the histopathological features were indicative of lymphomas.

(D) In 5 lymph node biopsies the histopathological features were due to fungal aspergillosis (n=3) and filariasis (n= 2). Histopathological features in 9 biopsies showed features of reactive follicular hyperplasia. In 4 cases, histopathological features were regarded as 'nonspecific' lymphadenitis of unknown aetiology.

Lymph node biopsy specimens in group (A) and (B) were regarded as TBL group (n= 35) and specimens in groups (C) and (D) were selected as 'disease control' for this study (n= 36).

### Cloning, expression and purification of *M. tuberculosis* antigens in *Escherichia Coli*

Three genes, *plcA*, *hspX* and *tb8.4* were PCR amplified from *M. tuberculosis* H<sub>37</sub>Rv genomic DNA (list of primers in Table 1), cloned into pET-32a expression vector (Novagen, Madison, WI), sequenced to verify reading frame, and recombinant plasmids were transformed into *E. coli* BL21(DE3)/pLysS expression host. A colony of transformed *E. coli* was used as a source of each protein. A single colony was cultured in Luria-Bertani (LB) medium supplemented with 60 µl/ml ampicillin, overnight at 37°C and 2 ml of this culture was inoculated into 100 ml LB media with 60 µl/ml ampicillin, induced with 1 mM IPTG and cultured at 28°C for 4 h. Culture was pelleted, cells were lysed, and expression of protein was confirmed by SDS-PAGE, followed by anti-His monoclonal antibody reactivity. The fourth gene - *esat-6* was cloned into pET-28a vector for over-expression of protein. Remaining steps were same as above, while pET-28a based transformed colonies were selected based on kanamycin resistance. Antigens were purified to near homogeneity by Ni-NTA affinity chromatography as per manufacturer's protocol (Promega Corporation, Madison, WI).

### Immunization schedule

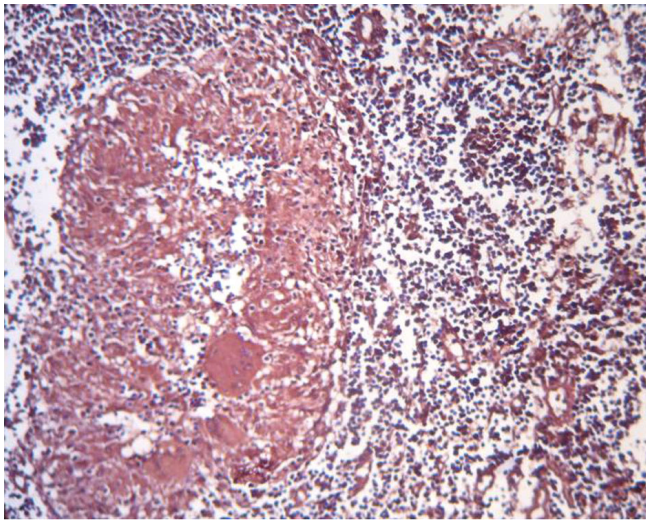
All the four recombinant mycobacterial antigens PlcA, HspX, Tb8.4 and ESAT-6 were used in immunization. Animal Experimentation Ethics Committee of this institute approved rabbit immunization protocols. Adult albino- rabbits were used as source of antisera for each antigen. 5 ml venous blood was collected and the serum was separated and labelled as pre-immune serum. In the primary immunization, each rabbit received an inoculum (50 µg of individual recombinant antigen, mixed in 2 ml of phosphate buffered saline (PBS) and 2 ml incomplete Freund's adjuvant). The inoculum was injected into intra muscular and subcutaneous sites. The immunization schedule was repeated on the 14<sup>th</sup>, 28<sup>th</sup> and 42<sup>nd</sup> day following the primary immunization. Gamma globulin fraction was isolated from the sera by 33% ammonium sulphate saturation followed by dialysis against PBS. IgG was isolated from the gamma globulin fraction by standard Protein-A Sepharose chromatography (Amersham-Pharmacia Biotech, NJ, USA). Protein concentration was estimated by Bradford's method (Bradford, 1976). Antibody titre was calculated by ELISA method (Engvall and Perlmann., 1972). Antibodies were dispensed in aliquots and stored at -20°C.

### Immunohistochemistry

5 µm thick paraffin sections of lymph nodes were deparaffinised,

**Table 1.** List of primers used for amplifying four genes from *M. tuberculosis* genome.

Primer name	Sequence
<i>esat-6</i> (Rv3875) forward	5'GGAATTCATATGACAGAGCAGCAGTGGAAATTC3'
<i>esat-6</i> (Rv3875) reverse	5'CCCAAGCTTGGGCTATGCGAACATCCCAGTGACG3'
<i>plcA</i> (Rv2351c) forward	5'GGGGTACCCCGATGTACGTCGAGAGTTTTTG3'
<i>plcA</i> (Rv2351c) reverse	5'CCCAAGCTTGGGTGAGCTGCACAGCCCGC3'
<i>hspX</i> (Rv2031c) forward	5'GGGGTACCCCGATGGCCACCACCTTCCCCTTC3'
<i>hspX</i> (Rv2031c) reverse	5'CCCAAGCTTGGGTGAGTTGGTGGACCGGATCTG3'
<i>tb8.4</i> (Rv1174c) forward	5'GGGGTACCCCGATGAGGCTGTCGTTGACCGCA3'
<i>tb8.4</i> (Rv1174c) reverse	5'CCCAAGCTTGGGTTAATAGTTGTTGCAGGAGC3'



**Figure 1.** IHC with anti-ESAT-6 antibody: The cytoplasm of macrophages and Langhan's giant cells are positive for mycobacterial antigens in a tuberculous granuloma (ABC X 200).

treated with xylene and serially hydrated by 100, 70, 50% ethanol and distilled water. Sections were then subjected to heat induced epitopes retrieval using the standard laboratory protocol. Endogenous peroxidase activity was inactivated by incubating the sections in 3% H<sub>2</sub>O<sub>2</sub> for 5 min. Sections were incubated with normal goat serum (5% in 1% BSA in PBS) for 30 min to eliminate non-specific background staining. Sections were incubated overnight with specific antibodies (0.5 µg/ml) at 4°C, subsequently washed in TBS-Tween-20 (TBST), followed by incubation with anti rabbit IgG-biotin conjugate for 40 min. Slides were washed in TBST, treated with Streptavidin horseradish peroxidase (30 min), rinsed, incubated with substrate 3-Amino-9-ethyl carbazole, for 5 min, counterstained with haematoxylin, cleared and mounted.

## RESULTS

### IHC

Immunostaining using the four antibodies gave positive results in all the 'confirmed' TBL cases. Mycobacterial antigens were demonstrated within the cytoplasm of

several macrophages and Langhans' giant cells in the tuberculous lesion. They appeared as granular brownish material (Figure 1). Negative immunostaining was obtained when an IHC with normal rabbit serum was performed on sections of lymph nodes from 'confirmed' tuberculosis (Figure 2). A polyclonal antibody to ESAT-6 was found to be highly reactive when compared to other three antibodies. Anti-ESAT-6 antibody detected 27 out of 31 'probable' TBL cases. Anti Tb8.4 and anti-HspX gave false positive results in two and three disease controls, respectively. However, false positive results were not obtained with anti-ESAT-6 and anti-PlcA antibodies. The results of the study in terms of sensitivity and specificity are given in Table 2.

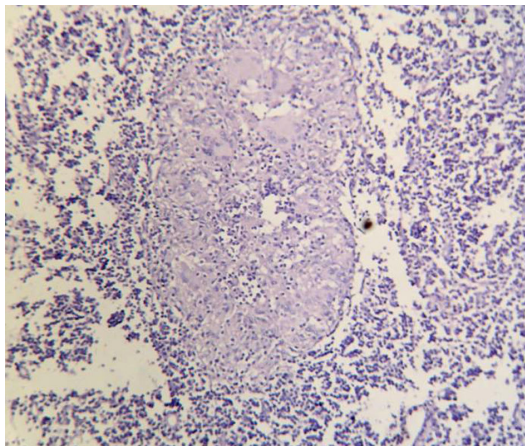
## DISCUSSION

Demonstration of *M. tuberculosis* bacilli by bacteriological methods in lymph node biopsies is considered as the 'gold-standard' for making a diagnosis in TBL. In our study AFB was demonstrated in only 4/35 TBL cases. Due to intensive phagocytotic activity by macrophages in tuberculous granulomas, the morphological characteristics of AFB often get distorted. This may account for the low detectability of ZN staining (Goel and Budhwar, 2008).

During the past decades IHC assumed greater significance in the diagnosis of several infectious diseases including tuberculosis. Role of IHC in the diagnosis of tuberculosis in formalin-fixed paraffin embedded lymph node biopsies have been reported in several published studies (Mukherjee et al., 2002; Purohit et al., 2007). Mukherjee et al. (2002) used a commercial anti-BCG antibody in their study and recorded 74% sensitivity, while Purohit et al. (2007) applied anti MPB-64 antibody with 80% positivity in patients with TBL. In another study, Goel et al. (2008) developed an immunocytochemical method using anti-38kDa antibody in the FNA of TBL specimens recording a sensitivity of 96.7%. It becomes relevant to explain that the sensitivity of IHC for TBL diagnosis depends on (a) distribution of mycobacterial antigen in granuloma (b) clinical stage of disease (c)

**Table 2.** Results of immunohistochemistry using antibodies against four mycobacterial antigens.

Antibodies	Sensitivity (%)			Specificity (%)
	Confirmed TBL (n=4)	Probable TBL (n=31)	Total TBL (n=35)	Disease control (n=36)
Anti-ESAT-6	100	87.1	88.6	100
Anti-PlcA	100	64.5	68.6	100
Anti-HspX	100	74.2	77.1	91.7
Anti-Tb8.4	100	67.7	71.4	94.4



**Figure 2.** IHC using normal rabbit serum: The cytoplasm of macrophages and Langhans' giant cells are devoid of immunostaining for mycobacterial antigens in a tuberculous granuloma (ABC X 200).

duration of ATT received prior to biopsy (d) specificity of primary antibody used in IHC.

In our earlier study (Anie et al., 2007), we used an in-house polyclonal antibody against tuberculous glycolipid antigen (TBGL) of *M. tuberculosis*. The assay was specific and was able to distinguish pleural fluids of tuberculous from non-tuberculous aetiology. When the same antibody was used in IHC studies, false positive results were obtained in granulomatous lymphadenitis of fungal aetiology (unpublished data). In an attempt to increase the specificity of IHC method, different mycobacterial antigens were evaluated. Due to diverse antibody response in TB patients, it becomes essential to study several immunoreactive mycobacterial antigens for the development of an efficient diagnostic assay to achieve desired levels of sensitivity and specificity. The slow growing nature of *M. tuberculosis* hinders large-scale purification of specific antigens. These situations lead to the application of recombinant technology, so as to produce pure antigens in large quantities. Hence in this study, we cloned, over-expressed, and purified four relevant and immuno-reactive mycobacterial antigens (ESAT-6, PlcA, HspX, and Tb8.4).

ESAT-6 is the early-secreted antigenic target 6-kDa protein, highly specific for *M. tuberculosis* complex, but is absent in *M. bovis* BCG (Munk et al., 2001). ESAT-6 is also reported to elicit strong antibody responses and delayed type hypersensitivity skin reactions in tuberculous guinea pigs (Brusasca et al., 2001). HspX (*acr* /16-kDa antigen / alpha-crystallin) was found to be superior to ESAT-6, CFP10 and antigen 85 in terms of sensitivity in serodiagnosis for the diagnosis of pulmonary tuberculosis (Shin et al., 2008). PlcA is a probable membrane associated phospholipase C1 of *M. tuberculosis*, whose activities seem to be restricted to pathogenic *Mycobacterium* sub-species. The factor that it is not present in *M. bovis* (Parra et al., 1991; Matsui et al., 2000) makes it an important candidate antigen for specific diagnosis in TB. Tb8.4 is another immunodominant T-cell antigen of *M. tuberculosis* studied for its cell-mediated immunological responses in human beings and animal models (Coler et al., 1998). These antigens were included in the study to evaluate their efficiency as a sensitive and specific diagnostic marker for TBL.

The results of IHC demonstrate the high sensitivity of anti-ESAT-6 antibody. In the four tuberculous lymphadenitis specimens where anti-ESAT-6 gave negative results, granulomas were replaced by extensive fibrosis, perhaps due to ATT given to the patients prior to biopsy. A reduction in mycobacterial antigen load resulted due to ATT may also account for the negative results in IHC using anti-ESAT-6 antibody. Anti-HspX antibody gave positive results in two cases of metastatic carcinoma cases and in one reactive hyperplasia patient. Tb8.4 antibody also gave positive immunostaining in two patients with metastatic carcinoma. These were regarded as false positive. The other two antibodies, anti-ESAT-6, and anti-PlcA did not give any false positive reaction in disease control group. In this IHC study, anti-ESAT-6 antibody was more sensitive than anti-PlcA.

Application of IHC assumes greater significance in situations such as 'sarcoid' like, non-caseating granulomatous lesions. The histopathological features in such lesions resemble TBL and become indistinguishable on histopathological grounds. In this study we have shown that IHC using anti-ESAT-6 holds promise for the specific detection of *M. tuberculosis* in tuberculosis involvement

of lymph nodes. IHC allows retrospective analysis of paraffin section without alteration in the intensity of immunostaining. The method is simple, sensitive, specific and user-friendly. We hence advocate the use of IHC using anti-ESAT-6 antibody for the diagnosis of TBL, in patients in whom conventional diagnostic methods did not confirm the disease.

## ACKNOWLEDGEMENTS

The authors thank the Director of this institute for his kind permission to perform and publish this work. The authors are indebted to Council for Scientific and Industrial Research (CSIR), New Delhi for providing fellowship to Ms S Sumi. Research facilities given by Dr. Sathish Mundayoor, Division of Molecular Microbiology, Rajiv Gandhi Centre for Biotechnology, Thiruvananthapuram is deeply acknowledged.

## REFERENCES

- Anie Y, Sumi S, Varghese P, Madhavi LG, Sathish M, Radhakrishnan VV (2007). Diagnostic approaches in patients with tuberculous pleural effusion. *Diagn. Microbiol. Infect. Dis.* 59: 389-394.
- Appling D, Miller RH (1981). *Mycobacterium cervical lymphadenopathy*: 1981 update. *Laryngoscope.* 91: 1259-1266.
- Baba K, Dyrhol-Riise AM, Sviland L, Langeland N, Hoosen AA, Wiker HG, Mustafa T (2008). Rapid and specific diagnosis of tuberculous pleuritis with immunohistochemistry by detecting *Mycobacterium tuberculosis* complex specific antigen MPT64 in patients from a HIV endemic area. *Appl. Immunohistochem. Mol. Morphol.* 16: 554-561.
- Bradford MM (1976). A rapid and sensitive method for the quantitation of microgram quantities of protein utilizing the principle of protein-dye binding. *Anal. Biochem.* 72: 248-254.
- Brusasca PN, Colangeli R, Lyashchenko KP, Zhao X, Vogelstein M, Spencer JS, McMurray DN, Gennaro ML (2001). Immunological characterization of antigens encoded by the RD1 region of the *Mycobacterium tuberculosis* genome. *Scand. J. Immunol.* 54: 448-452.
- Coler RN, Skeiky YA, Vedvick T, Bement T, Owendale P, Campos-Neto A, Alderson MR, Reed SG (1998). Molecular cloning and immunologic reactivity of a novel low molecular mass antigen of *Mycobacterium tuberculosis*. *J. Immunol.* 161: 2356-2364.
- ngvall E, Perlmann P (1972). Enzyme-linked immunosorbent assay, Elisa. 3. Quantitation of specific antibodies by enzyme-labeled anti-immunoglobulin in antigen-coated tubes. *J. Immunol.* 109:129-135.
- Goel MM, Budhwar P (2008). Species-specific immunocytochemical localization of *Mycobacterium tuberculosis* complex in fine needle aspirates of tuberculous lymphadenitis using antibody to 38 kDa immunodominant protein antigen. *Acta. Cytol.* 52: 424-433.
- Jindal N, Devi B, Aggarwal A (2003). *Mycobacterial cervical lymphadenitis in childhood.* *Indian. J. Med. Sci.* 57: 12-15.
- Kesarwani RC, Pandey A, Misra A, Singh AK (2004). Polymerase chain reaction (PCR): Its comparison with conventional techniques for diagnosis of extra-pulmonary tubercular diseases. *Indian. J. Surg.* 66: 84-88.
- Matsui T, Carneiro CRW, Leao SC (2000). Evidence for the expression of native *Mycobacterium tuberculosis* phospholipase C: recognition by immune sera and detection of promoter activity. *Braz. J. Med. Biol. Res* 33: 1275-1282.
- Mukherjee A, Kalra N, Beena KR.(2002). Immunohistochemical detection of mycobacterial antigen in tuberculous lymphadenitis. *Ind. J. Tub.* 49: 213-216.
- Munk ME, Arend SM, Brock I, Ottenhoff TH, Andersen P (2001). Use of ESAT-6 and CFP-10 antigens for diagnosis of extrapulmonary tuberculosis. *J. Infect. Dis.* 183:175-176.
- Parra CA, Londono LP, Portillo DP, Patarroyo ME (1991). Isolation, characterization, and molecular cloning of a specific *Mycobacterium tuberculosis* antigen gene: identification of a species-specific sequence. *Infect. Immun.* 59: 3411-3417.
- Purohit MR, Mustafa T, Wiker HG, Morkve O, Sviland L (2007). Immunohistochemical diagnosis of abdominal and lymph node tuberculosis by detecting *Mycobacterium tuberculosis* complex specific antigen MPT64. *Diagn. Pathol.* 2:36.
- Shin AR, Shin SJ, Lee KS, Eom SH, Lee SS, Lee BS, Lee JS, Cho SN, and Kim HJ (2008). Improved Sensitivity of Diagnosis of Tuberculosis in Patients in Korea via a Cocktail Enzyme-Linked Immunosorbent Assay Containing the Abundantly Expressed Antigens of the K Strain of *Mycobacterium tuberculosis*. *Clin. Vac. Immunol.* 15: 1788-1795.
- Sumi MG, Mathai A, Sheela R, Radhakrishnan NS, Radhakrishnan VV, Indhulekshmy R, Mundayoor S (2001). Diagnostic utility of polymerase chain reaction and immunohistochemical techniques for the laboratory diagnosis of intracranial tuberculoma. *Clin. Neuropathol.* 20: 176-180.