

Short Communication

Signet ring carcinoma of the esophagogastric junction in a Nigerian man

Aderemi O. Oluyemi^{1*}, Fatimah B. Abdulkareem² and Nicholas A. Awolola²

¹General Hospital, Ikorodu, Lagos State, Nigeria.

²Department of Morbid Anatomy, College of Medicine, University of Lagos, Idi-Araba, Lagos State, Nigeria.

Accepted 24 May, 2012

Globally, the majority of cancers of the esophagogastric junction are adenocarcinomas. Of the four histological subtypes, the signet ring carcinomas are rare. There is a dearth of reports of this relatively rare histological finding from patients in sub-Saharan Africa. We present such a case in 69 year old Nigerian with advanced malignant disease.

Key word: Signet ring carcinoma, esophagogastric junction, endoscopy, Nigeria.

INTRODUCTION

Adenocarcinomas that cross the esophagogastric junction (EGJ) are called adenocarcinomas of the EGJ, regardless of where the bulk of the tumor lies (Sons et al., 1986). The World Health Organization (WHO) classification distinguishes four histological types: papillary, tubular, mucinous, and signet ring cell adenocarcinoma (Hamilton and Aaltonen, 2000).

The disease appears to have a low prevalence rate in sub-Saharan Africa generally and Nigeria specifically (Kachala, 2010; Abdulkareem et al., 2008). Although, exact data about EGJ tumors is not presently available, its rarity can be inferred from other published work that investigated incidence and prevalence patterns of all esophageal and gastric cancers. A worrying increase in the incidence and prevalence of adenocarcinoma of the esophagus has been noted in Western countries (Vizcaino et al., 2002).

The signet ring cell subset of adenocarcinomas is characterized by abundant intracellular mucin accumulation leading to compressed nucleus which is eccentrically located within the cell. It must be distinguished from the mucinous variety which possesses abundant extracellular mucin. For the lesion to qualify as signet ring cell carcinoma, the adenocarcinoma's predominant component (more than 50%) must be composed of isolated malignant cells containing this

intracytoplasmic mucin. Primary signet ring cell carcinoma of the EGJ is infrequent (Hamilton and Aaltonen 2000).

This study presents the case of a 69 year old Nigerian with this rare histologic subtype and briefly discusses the clinical presentation and the prognostic implications of such a diagnosis.

CASE REPORT

A 69 year old male presented with a four month history of difficulty with swallowing and repeated vomiting. There was no history of blood and bile in the vomitus as it contained only recently ingested meals mixed with what he described as a slimy material. Dysphagia was associated with the feelings of food being "caught up in the chest", and frequently, he noted a feeling of fullness in his chest following meals which preceded the vomiting episodes. All symptoms had progressively increased in frequency leading to a considerable loss of weight over the course of the illness. There was no history of chronic heartburn nor regurgitation (these might have been suggestive of underlying reflux disease) and patient had never smoked in the past. No family history of gastrointestinal malignancy of any kind was reported in the patient.

His general examination findings were significant for cachexia with pallor and palmar erythema. The abdominal findings revealed a mobile mass palpable just below the xiphisternum. It was a freely mobile, firm and tender mass

*Corresponding author. E-mail: remioluyemi@yahoo.com.

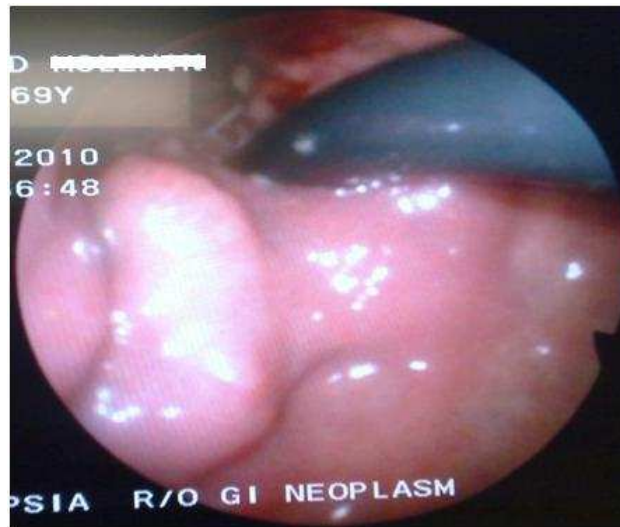

Figure 1. Esophagogastroduodenoscopy retroflexed view from within the stomach shows a large, irregular, ulcerated mass in the gastric cardia.

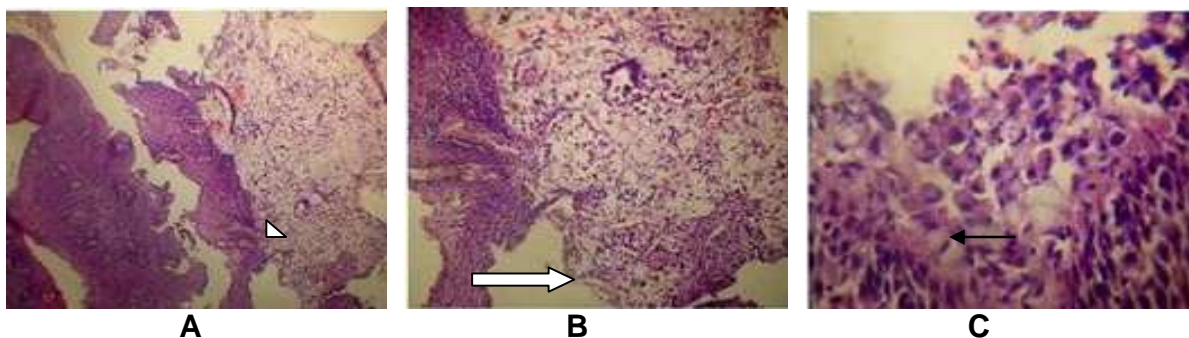


Figure 2. (A) Photomicrograph of signet ring carcinoma invading the stratified squamous epithelium of the esophagus. (white arrow) (hematoxylin and eosin stain; original magnification $\times 40$). (B) Same section as A, but at higher magnification showing localized area of epithelial erosion (bold arrow) (hematoxylin and eosin stain; original magnification $\times 100$). (C) Same section as A, but at higher magnifications showing signet ring cells having abundant mucin filled cytoplasm pushing the nuclei to the periphery (black arrow) (hematoxylin and eosin stain $\times 400$).

tender mass whose upper dimensions could not be made out on palpation. The bedside test for succussion splash was negative.

The esophagogastrosocopy revealed that the proximal portion of the esophagus was littered with food debris. At the lower end, there was a huge circumferential mass which had infiltrated the esophagogastric junction (EGJ) till near obliteration of the passage into the stomach. The distal portion of the esophagus was grossly dilated. There was a large, ulcerated, nodular mass in the gastric cardia which appeared to be in continuity with the esophageal mass, but its irregularity had very nearly completely distorted the architecture of the cardia (Figure 1).

Biopsy samples were taken from the esophageal and gastric ends of the mass and also at the level of the EGJ. The biopsy of the cardia showed an area of ulceration of

the epithelial lining by tumor cells which consist of poorly differentiated adenocarcinoma with more than 75% being diffusely disposed signet ring cells. These cells have pleomorphic hyperchromatic nuclei and mucin-distended cytoplasm and eccentrically located nuclei within the cell. Adjacent suppurative inflammatory reaction was also noted. Similar tumorous cells were found in the samples from the esophagus and the EGJ. Additionally, the esophageal mucosa showed no evidence of Barrett's or dysplasia (Figure 2A to C).

Computed tomography study revealed infiltrative masses in the liver suggestive of distant metastasis from the tumor and was referred to the gastrointestinal surgeon for co-management with oncologists. The patient was reviewed and adjudged not to be fit for surgery. Hence, palliative measures were instituted. The surgeons

put in a percutaneous gastrojejunostomy tube for feeding which helped ameliorate the patient's symptoms and the oncologists commenced anticancer regime which included the drug, imatinib. But the patient succumbed soon afterwards.

DISCUSSION

The first documented case of esophageal signet ring carcinoma was in Japan by Takubo et al. (1987). The case being reported here seeks to document the presence of this infrequent histologic type of adenocarcinoma of the EGJ in sub-Saharan Africa. A recent large pathology series from Lagos, Nigeria, one of the most densely populated cities in sub-Saharan Africa (Abdulkareem et al., 2008) reported that not a single case of esophageal carcinoma with similar histology was found. It is to be noted that the bulk of malignant esophageal tumors in this environment have been reported to be of the squamous cell carcinoma variety as this accounts for over 90% of cases (Pindiga et al., 1997). The age of the patient and clinical features are typical for the presentation of esophageal cancers in this part of the world (Pindiga et al., 1997).

Previous workers have highlighted late presentation and delay in diagnosis as the key factors responsible for the abysmal prognosis of esophageal carcinomas in Nigeria (Pindiga et al., 1997). Another mitigating factor to prompt diagnosis of this disease in our environment is the unavailability and inaccessibility of endoscopy services in general (Onyekwere et al., 2008; Agbakwuru et al., 2006). The case further emphasizes the importance of these two factors as the patient's alarm features of repeated vomiting with marked weight loss warranted both earlier presentation and endoscopic assessment.

Additionally, the prognosis of signet ring carcinoma of any organ is, in general, poor. This dismal outcome is mainly accounted for by the diffusely infiltrating nature of the neoplasm, leading to widespread metastases before being clinically apparent (Chirieac et al., 2005). In many cases, as illustrated by the index report, at the time of diagnosis, there is evidence distant metastasis.

REFERENCES

- Abdulkareem FB, Onyekwere CA, Awolola NA, Banjo AAF (2008). A clinicopathologic review of oesophageal carcinoma in Lagos. *Nig. Qt. J. Hosp. Med.* 18(2):53-56.
- Agbakwuru EA, Fatusi AO, Ndububa DA, Alatise OI, Arigbabu OA, Akinola DO (2006). Pattern and validity of clinical diagnosis of upper gastrointestinal diseases in south-west Nigeria. *Afr. Health Sci.* 6(2):98-103.
- Chirieac LR, Swisher SG, Correa AM, Ajani JA, Komaki RR, Rashid A, Hamilton SR, Wu TT (2005). Signet-Ring Cell or Mucinous Histology after Preoperative Chemoradiation and Survival in Patients with Esophageal or Esophagogastric Junction Adenocarcinoma. *Clin. Cancer Res.* 11:2229-2236.
- Hamilton SR, Aaltonen LA (Eds.) (2000). World Health Organization Classification of Tumours. Pathology and Genetics of Tumours of the Digestive System. IARC Press: Lyon.
- Kachala R (2010). Systematic review: epidemiology of esophageal cancer in sub-Saharan Africa. *Malawi Med. J.* 22(3):65-70.
- Onyekwere CA, Hameed H, Anomneze EE, Chibututu C (2008). Upper gastrointestinal endoscopy findings in Nigerians: a review of 170 cases in Lagos. *Nig. Postgrad. Med. J.* 15(2):126-129.
- Pindiga HU, Akang EE, Thomas JO, Aghadiuno PU (1997). Carcinoma of the Esophagus in Ibadan. *East Afr. Med. J.* 74(5):307-10.
- Sons HU, Borchard F (1986). Cancer of the distal esophagus and cardia. Incidence, tumorous infiltration, and metastatic spread. *Ann. Surg.* 203:188-195.
- Takubo K, Takai A, Yamashita K, Onda M (1987). Carcinoma with Signet Ring cells of the esophagus. *Acta. Pathol. Jpn.* 37(6):989-995.
- Vizzaino AP, Moreno V, Lambert R, Parkin DM (2002). Time trends incidence of both major histologic types of esophageal carcinomas in selected countries, 1973–1995. *Int. J. Cancer.* 99:860–868.