

Full Length Research Paper

An assessment of the histomorphometric evidences of doxorubicin-induced testicular cytotoxicity in Wistar rats

L. C. Saalu^{1*}, L. A. Enye¹ and A. A. Osinubi²

¹Department of Anatomy, Lagos State University College of Medicine, Ikeja Lagos, Nigeria.

²Department of Anatomy, College of Medicine, University of Lagos, Lagos, Nigeria.

Accepted 5 August, 2009

Doxorubicin (DOX) also known as hydroxydaunorubicin is a drug used in cancer chemotherapy. It is one of the earliest compounds derived from an antibiotic group of chemotherapy known as anthracycline. It strives to kill malignant cells and produces tumor regression in a variety of human neoplasms. However, its clinical usefulness is limited by its proven toxicity to certain organs particularly the heart and the kidney. In the present study, we evaluated the effect of a single dose of DOX on the seminiferous tubules of rats. Forty male adult (11 to 13 weeks old) wistar rats weighing 185-210 g were used for this research work. The rats were randomly divided into four groups of ten rats each. Group 1 rats were given a single dose of normal saline (2.5 ml/kg) body weight ip and then were sacrificed a day after. Group 2 animals had 10 mg DOX per kg body weight intraperitoneally (ip) as a single dose. These rats were sacrificed the day after DOX administration. Group 3 animals had 10 mg DOX per kg body weight ip as a single dose but were sacrificed on the 56th day. Group 4 rats had similar treatment as those in group 3, except that they were sacrificed at the end of the 16th week after DOX administration. The gross anatomical parameters assessed included the testicular weights and volumes while stereological parameters estimated include: diameter and cross-sectional area of the seminiferous tubules; number of profiles per unit area and numerical density of seminiferous tubules. The results showed that there was a general destruction along with degeneration of cells of the seminiferous epithelium following DOX administration. There was also a demonstrable progressive worsening of the testicular derangement with passage of time following DOX challenge. We conclude that DOX has a deleterious effect on the testis.

Key words: Doxorubicin, testis, histomorphometry.

INTRODUCTION

The history of Doxorubicin can be traced back to the 1950s, when an Italian research company, Farmitalia Research Laboratories, began an organized effort to find anticancer compounds from soil-based microbes. Even though DOX is classified as an antibiotic, it is not used as an antimicrobial agent. It strives to selectively kill malignant cells and produces tumor regression in a variety of human neoplasms.

It is highly effective in many human tumours and is currently the first line anti-cancer drug in many chemo-

responsive tumours such as ovarian cancers, breast cancers and lymphomas (Atessahin et al., 2006). The organ toxicity associated with DOX therapy, however limits the total cumulative dose and therapeutic success of active anticancer chemotherapy. In particular, the occurrence of infertility following treatment with this anticancer drug is a serious concern (Suominen et al., 2003; Prahalathan et al., 2005).

The biochemical mechanism by which DOX causes cytotoxicity is currently unclear. Several mechanisms have been postulated to account for the effects of DOX, both in terms of anticancer potential and adverse effects. It is however thought to have three major activities that vary with the type of cell. One mechanism of DOX cytotoxicity is intercalation in the DNA. Once the drug

*Corresponding author. E-mail: chiasaalu@hotmail.com. Tel: 234-8033200876.

penetrates into the cell, it binds to chromatin. It then forms a complex with the DNA by intercalation of its planar rings between nucleotide base pairs (Mornparler et al., 1976). It is also widely accepted that DOX-induced organopathy resides for the most part on oxidative stress and the production of free radicals (Quiles et al., 2002; Chularojmontri et al., 2005; Prahalthan et al., 2005). These free radicals could then cause membrane and macromolecule damage by three basic mechanisms; lipid peroxidation, deoxyribonucleic acid (DNA) fragmentation and protein oxidation (Pacher, 2007).

Mammalian spermatozoon is particularly vulnerable to lipid peroxidation because of the molecular anatomy of its plasma membrane. Unlike somatic cells, mammalian sperm cells present highly specific lipidic composition with high content of polyunsaturated fatty acids (PUFA), plasmalogenes and sphingomyelins. This unusual structure of sperm membrane is responsible for its flexibility and the functional ability of sperm cells. However, spermatozoa's lipids, especially PUFA are the main substrates for peroxidation, which may provoke severe functional disorder of sperm (Sachdev and Davies, 2008). A further site of action for doxorubicin may be at the cell membrane level: the drug can bind to cell membrane lipids and affect a variety of functions (Katzung, 2007).

A number of investigators (Quiles et al., 2002; Chularojmontri et al., 2005; Prahalthan et al., 2005) have attempted to study the effects of this chemotherapeutic drug on the reproductive system. However, none of these investigations extensively utilized the stereological tool to elucidate convincing histomorphometric evidences of DOX-mediated derangement of the testis. Previous reports also contain only early one point findings. There is therefore a dearth of information in the literature on the middle term as well as delayed responses of the testis challenged with DOX.

The aim of the present study is therefore to assess the short, mid, and long terms effects of a single dose treatment with DOX on the testes of rats using simple, but efficient stereological tools.

MATERIALS AND METHODS

Chemicals

Doxorubicin hydrochloride ([®]Adricin, Korea United Pharm. Inc., Chungnam, Korea) was obtained from Juli Pharmacy, Ikeja, Lagos State, Nigeria in the month of May, 2008.

Animals and interventions

Experimental procedures involving the animals and their care were conducted in conformity with International, National and institutional Guidelines for the care of laboratory animals in Biomedical Research and Use of Laboratory Animals in Biomedical Research as promulgated by the Canadian Council of Animal Care (CCAC, 1985). Further, the animal experimental models used conformed to the guiding principles for research involving animals as recommended by the Declaration of Helsinki and the Guiding Principles in the Care and Use of Animals (American Physiological Society, 2000).

The rats were procured from a breeding stock maintained in the Animal House of Lagos State University College of Medicine (LASUCOM). The animals were housed in well ventilated wire-wooden cages in the Animal Facility of the Department of Anatomy, LASUCOM, Ikeja, Lagos. An approval was sought and obtained from the Departmental ad-hoc Ethical Committee. The rats were maintained under standard natural photoperiodic condition of twelve hours of light alternating with twelve hours of darkness (that is L: D; 12:12) with room temperature of between 25 to 26°C and humidity of $65 \pm 5\%$. They were allowed unrestricted access to water and rat chow (Feedwell Livestock Feeds Ltd, Ikorodu, Lagos, Nigeria). They were allowed to acclimatize for 28 days before the commencement of the experiments. The weights of the animals were estimated at procurement, during acclimatization, at commencement of the experiments and twice within a week throughout the duration of the experiment, using an electronic analytical and precision balance (BA210S, $d=0.0001$ g) (Satorius GA, Goettingen, Germany).

Forty male adult (11 to 13 weeks old) wistar rats, weighing 185-210 g were used for this research work. The rats were randomly divided into four groups of ten rats each, such that the average weight difference between and within groups did not exceed $\pm 20\%$ of the average weight of the sample population. Group 1 rats were given a single dose normal saline (2.5 ml/kg) body weight ip and then were sacrificed a day after. Group 2 animals had 10 mg DOX per kg body weight intraperitoneally (ip) as a single dose. This dosage is well documented to cause testicular damage in rats (Howell and Shaler, 2001; Atessahin et al., 2006). These rats were sacrificed the day after DOX administration. Group 3 animals had 10 mg DOX per kg body weight ip as a single dose but were sacrificed on the 56th day (that is, 8 weeks after DOX treatment), the duration of spermatogenesis in rat being 51.6-56 days (Heller and Clermont, 1964; Jegou et al., 2002). Group 4 rats had similar treatment as those in group 3 except that they were sacrificed at the end of the 16th week after DOX administration.

Animal sacrifice and sample collection

The rats were at the time of sacrifice first weighed and then anaesthetized by placing them in a closed jar containing cotton wool sucked with chloroform anaesthesia. The abdominal cavity was opened up through a midline abdominal incision to expose the reproductive organs. Then the testes were excised and trimmed of all fat. The testes weights of each animal were evaluated. The testes were weighed with an electronic analytical and precision balance (BA 210S, $d=0.0001$ - Sartorius GA, Goettingen, Germany). The testes volumes were measured by water displacement method. The two testes of each rat were measured and the average value obtained for each of the two parameters was regarded as one observation.

The testes were fixed in 10% formal-saline and histological slides prepared. However, prior to embedding, it was ensured that the sections were orientated perpendicular to their long axes, and designated as "vertical sections".

Determination of morphometric parameters

For each testis, five vertical sections from the polar and the equatorial regions were sampled (Qin and Lung, 2002) and an unbiased numerical estimation of the following morphometric parameters was determined using a systematic random scheme (Gundersen and Jensen, 1987).

Diameter (D) of seminiferous tubules: The diameter of seminiferous tubules with profiles that were round or nearly round were measured for each animal and a mean, D , was determined by taking the average of two diameters, D_1 and D_2 (Perpendicular to

Table 1. The changes in gross anatomical parameters of wistar rats.

Treatment groups	Initial body weight (g)	Final body weight (g)	Body weight Diff.(g)	Testis weight (g)	Testis volume (ml)	Testis wt/ body wt ratio
1	190.7 ± 4.5	190.6 ± 4.3	0.1	1.45 ± 0.8	1.55 ± 0.6	0.007
2	186.2 ± 7.8	170.3 ± 4.5	15.9	0.56 ± 0.4*	0.58 ± 0.3*	0.003*
3	198.4 ± 5.7	145.6 ± 3.6	52.8	0.48 ± 0.6*	0.57 ± 0.4*	0.003*
4	200.5 ± 4.4	147.5 ± 4.3	53.1	0.43 ± 0.6*	0.45 ± 0.3*	0.003*

Group 1: had Normal saline 2.5 ml/kg body weight ip and were sacrificed the next day.

Group 2: had Doxorubicin 10 mg/kg body weight ip and were sacrificed the next day.

Group 3: had Doxorubicin 10 mg/kg body weight ip and were sacrificed at the end of the 8th week.

Group 4: had Doxorubicin 10 mg/kg body weight ip and were sacrificed at the end of the 16th week.

*represents significant decreases at $p < 0.01$ when compared to control values.

Values are means ± S.E.M. n = 10 in each group.

to one another). D_1 and D_2 were taken only when $D_1/D_2 \geq 0.85$.

Cross-sectional area (A_c) of the seminiferous tubules: The cross-sectional areas of the seminiferous tubules were determined from the formula $A_c = \pi D^2/4$, (where π is equivalent to 3.142 and D the mean diameter of the seminiferous tubules).

Number of profiles of seminiferous tubules in a unit area of testis (N_A): The number of profiles of seminiferous tubules per unit area was determined by using the unbiased counting frame proposed by Gundersen (1977). Using this frame, in addition to counting profiles completely inside the frame we counted all profiles with any part inside the frame provided they do not touch or intersect the forbidden line (full-drawn line) or exclusion edges or their extension.

Numerical Density (N_V) of seminiferous tubules: This is the number of profiles per unit volume and was determined by using the modified Floderus equation:

$$N_V = N_A / (D + T) \text{ (Gilliland et al., 2001)}$$

Where; N_A is the number of profiles per unit area, D is the diameter and T the average thickness of the section.

The evaluation of the diameter was done with calibrated eyepiece and stage grids mounted on a light research microscope. Estimation of volume density of testicular components and number of seminiferous tubules were done on a computer monitor onto whom a graph sheet was superimposed and on which slides were projected from a research light microscope.

Statistical analysis

All data were expressed as mean ± SD of number of experiments (n = 5). The level of homogeneity among the groups was tested using Analysis of Variance (ANOVA) as done by Snedecor and Cochran 1980. Where heterogeneity occurred, the groups were separated using Duncan Multiple Range Test (DMRT). A value of $p < 0.05$ was considered to indicate a significant difference between groups (Duncan, 1957).

RESULTS

Body weights, testes weights and testes volumes

There was a significant ($p < 0.01$) decrease in the testis weight, testis weight/body weight ratio and testis volume




Figure 1. Cross-section of testis of rat treated with normal saline (2.5 mg/kg) ip and then sacrificed the next day (controls), showing the seminiferous tubules; L, Lumen; S: Seminiferous epithelium; I, Interstitium; Stains, haematoxylin and eosin; Mag, x400.

in the DOX treated groups, with a delayed sacrifice (that is groups 3 and 4) as shown in Table 1.

Testes histo-morphometry

The cross-sections of the seminiferous tubules of control rats (group 1) were moderately circular or oval in outline with normal seminiferous epithelium and numerous spermatozoa within their lumen (Figure 1). Rats that were given DOX showed progressive degenerative changes in their seminiferous tubules. Thus, those that were sacrificed early (one day) after DOX therapy showed a significant reduction of the basal seminiferous epithelial cells resulting in apparent detachment of the basement membrane (Figure 2). Rats that were sacrificed mid-term (8 weeks) post- DOX treatment showed strikingly hypospermatozoa formation. Most seminiferous tubules lumens were empty of spermatids and spermatozoa (Figure 3). The animals which had delayed (16 weeks) post-DOX sacrifice showed marked testicular atrophy.

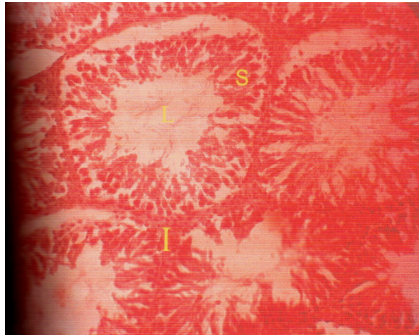


Figure 2. Cross-section of testis of rat treated with doxorubicin (10 mg/kg) ip and then sacrificed the next day, showing the seminiferous

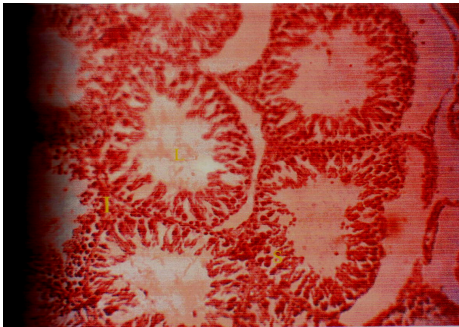


Figure 3. Cross-section of testis of rat treated with doxorubicin (10 mg/kg) ip and then sacrificed at the end of the 8th week, showing the seminiferous tubules; L; Lumen, S; Seminiferous epithelium, I; Interstitium, Stains; haematoxylin and eosin Mag, $\times 400$.

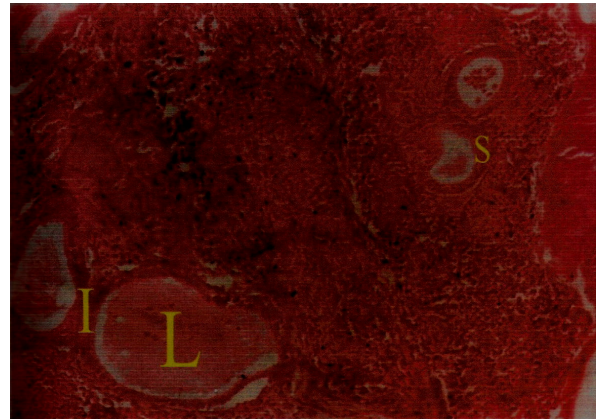


Figure 4. Cross-section of testis of rat treated with doxorubicin (10 mg/kg) ip and then sacrificed at the end of the 16th week, showing the seminiferous tubules; L; Lumen, S; Seminiferous epithelium, I; Interstitium, Stains; haematoxylin and eosin; Mag, $\times 400$.

$11.37 \pm 6.23 (\times 10^{-10}) \mu\text{m}^{-2}$ observed for those sacrificed the day after DOX treatment, $13.43 \pm 4.22 (\times 10^{-8}) \mu\text{m}^{-2}$, $8.63 \pm 7.65 (\times 10^{-8}) \mu\text{m}^{-2}$ observed for rats that were sacrificed 8 weeks post DOX and $8.41 \pm 1.33 (\times 10^{-8}) \mu\text{m}^{-2}$, $5.42 \pm 11.62 (\times 10^{-8}) \mu\text{m}^{-2}$ shown in animals that were sacrificed at the end of the 16th week post DOX therapy (Table 2).

DISCUSSION

Howell and Shaler (2001) reported that administration of DOX can decrease the testicular weight of rats. Prahalaathan et al. (2005) on the other hand did not report any significant testicular weight changes with DOX treatment. In this study however, the absolute testicular weights, testicular weight/body weight ratio and testicular volumes of rats that were administered DOX were significantly ($p < 0.01$) lower than those of the control groups. This could be attributed to severe parenchyma atrophy in the seminiferous tubules following DOX challenge.

Our results showed that there was a general destruction, coupled with derangement of cells of the seminiferous epithelium secondary to a single dose administration of DOX as demonstrated by significant reduction in their diameter, cross-sectional area, number of profiles and numerical density when compared to the control. This agrees with the findings by many investigators (Kato et al., 2001; Endo et al., 2003; Atessahin et al., 2006) who provide well documented evidences of testicular morphologic impairment following DOX challenge in animal models.

Howell and Shaler (2001) showed that the occurrence of male infertility following DOX chemotherapy is due to alterations in the sperm parameters. Spermatogenic cells constitute one of the body tissues that are susceptible to

The seminiferous tubules have been replaced mainly by interstitial cells (Figure 4).

The mean diameter (D) and cross-sectional area (A_c) of the seminiferous tubules in the control rats were $204.52 \pm 15.32 \mu\text{m}$ and $38.65 \pm 2.24 (\times 10^3) \mu\text{m}^2$, respectively. There was however, a progressive reduction in tubular diameter and cross-sectional area of the tubules over a 16 week post- DOX administration period. $130.35 \pm 15.20 \mu\text{m}$; $15.63 \pm 6.31 (\times 10^3) \mu\text{m}^2$ observed for those sacrificed the day after DOX treatment, $81.42 \pm 10.34 \mu\text{m}$; $9.41 \pm 8.34 (\times 10^3) \mu\text{m}^2$ observed for rats that were sacrificed 8 weeks post DOX and $70.37 \pm 8.14 \mu\text{m}$; $5.65 \pm 1.03 (\times 10^3) \mu\text{m}^2$ shown in animals that were sacrificed at the end of the 16th week post DOX therapy (Table 2).

The mean number of tubular profiles per unit area (N_A) and the mean numerical density (N_V) of seminiferous tubules in control groups were $35.21 \pm 1.14 (\times 10^{-8}) \mu\text{m}^{-2}$ and $15.9 \pm 4.92 (\times 10^{-10}) \mu\text{m}^{-2}$, respectively. There was a gradual but progressive reduction of the number of tubular profiles per unit area and the mean numerical density of seminiferous tubules over a 16 week post-DOX administration period: $20.46 \pm 5.21 (\times 10^{-8}) \mu\text{m}^{-2}$,

Table 2. The changes in morphometric parameters of wistar rats.

Treatment groups	D (μm)	Ac ($\times 10^3 \mu\text{m}^3$)	N _A ($\times 10^8 \mu\text{m}^{-2}$)	N _V ($\times 10^{10} \mu\text{m}^{-2}$)
1	205.41 \pm 9.14	38.5 \pm 7.13	35.17 \pm 8.16	15.16 \pm 4.92
2	130.35 \pm 15.20 ^a	15.63 \pm 6.31 ^a	20.46 \pm 5.21 ^a	11.37 \pm 6.23 ^a
3	81.42 \pm 10.34 ^b	9.41 \pm 8.34 ^b	13.43 \pm 4.22 ^a	8.63 \pm 7.65 ^c
4	70.37 \pm 8.14 ^c	5.65 \pm 1.03 ^c	8.41 \pm 1.33 ^b	5.42 \pm 11.62 ^a

Group 1: had Normal saline 2.5 ml/kg body weight ip and were sacrificed the next day.

Group 2: had Doxorubicin 10 mg/kg body weight ip and were sacrificed the next day.

Group 3: had Doxorubicin 10 mg/kg body weight ip and were sacrificed at the end of the 8th week.

Group 4: had Doxorubicin 10 mg/kg body weight ip and were sacrificed at the end of the 16th week.

^{a,b,c} represent significant decreases at $p < 0.05$, $p < 0.01$ and $p < 0.001$ respectively when compared to control values

Values are means \pm S.E.M. n = 10 in each group.

DOX-induced oxidative stress and apoptosis. Anthracyclines including DOX exert their antitumour effects as well as other organ toxicity by intracellular generation of free radicals and reactive oxygen species along with intercalation with DNA and subsequent inhibition of topoisomerase (Mormparler et al., 1976; Hrdina et al., 2000). This increased oxidative stress damages the sperm membranes, proteins and DNA (Kirsi and Timo, 2001; Kalender and Yel, 2005).

Oxidative stress and lipid peroxidation (self-propagating) mechanism of DOX cytotoxicity could provide an explanation for the progressive worsening of the testicular histomorphometric parameters following a single dose DOX therapy. Thus, the animals sacrificed two weeks post DOX had better testicular profiles than those that were autopsied 8 weeks post-DOX. Those that were sacrificed 16 weeks after DOX treatment were shown to have the worst testicular derangement.

The present study has therefore provided an addition to the body of evidence that doxorubicin chemotherapy induces morphological and morphometric impairments of the testis of wistar rats. It was also shown that there is progressive worsening of testicular derangement with time, following a single dose of doxorubicin treatment.

REFERENCES

- Ateşahin AI, Karahan G, Turk S, Yilmaz S, Ceribasi AO (2006). Protective role of lycopene on cisplatin induced changes in sperm characteristics, testicular damage and oxidative stress in rats. *Reprod. Toxicol.* 21: 42-47.
- Canadian Council of Animal Care (1985). Guide to the handling and Use of experimental animals. Ottawa: Ont.; 2 United States NIH publications 85(23): 45-47.
- Chularojmontri L, Wattanapitayakul SK, Herunsalee A, Charuchongkolwongse S, Niomsakul N, Srichairat S (2005). Antioxidant and cardioprotective effects of Phyllanthus urinaria L. on doxorubicin-induced cardiotoxicity. *Biol. Pharm. Bull. Pubmed.* 15997091. 28 (7): 1165-1171
- Duncan BD (1957). Multiple range tests for correlated and heteroscedastic means. *Biometrika.* 13: 359-364.
- Endo FF, Manabe H, Takishima (2003). Protecting spermatogonia from apoptosis induced by doxorubicin using luteinizing hormone-releasing hormone analog leuporelin. *Int. J. Urol.* 10: 72-77.

- Gundersen HJG (1977). Notes on the edge of the numerical density of arbitrary profiles: the edge effect. *J. Microsc.* 111: 219-223.
- Gundersen HJG, EB Jenson (1987). The efficiency of systematic sampling in stereology and its prediction. *J. Microsc.* 147: 229-263.
- Heller CG, Clermont Y (1964). Spermatogenesis in man: An estimate of its duration. *Sci.* 140: 184-186.
- Howell ST, Shaler SM (2001). Testicular function following chemotherapy. *Hum. Reprod.* 7: 363-369.
- Hrdina R, Gersl VI, Klimtova T, Simunek J (2000). Anthracycline-induced cardiotoxicity. *Acta Med.* 43 (3): 75-82.
- Jegou BC, Pineau J, Toppari (2002). Spermatogenesis in vitro in mammals. In: de Jonge CJ, Barratt CLR (Editors). Assisted Reproductive Technology: Accomplishments and New Horizons. 1st Edition. Cambridge: Cambridge University Press 3: 60.
- Kalender Y, Yel M (2005). Doxorubicin hepatotoxicity. The effect of Vit. E. *Toxicol.* 209: 39-45.
- Kato MS, Makino H, Kimuru J (2001). Sperm notion analysis in rats treated with doxorubicin and its applicability to male reproductive toxicity studies. *J. Toxicol. Sci.* 26: 51-59.
- Katzung BG (2007). Anthracycline antibiotics. Basic and Clinical Pharmacology. Tenth Ed. McGraw Hill pp.878-880.
- Kirsi T, Timo J (2001). Toxic effects of doxorubicin. *Cancer Res.* pp.634-644.
- Mormparler RL, Karon M, Siegel SE, Avila F (1976). Effect of Adriamycin on DNA, RNA and Protein synthesis in cell free systems and intact cells. *Cancer Res.* 36: 2891-2895.
- Pacher P (2007). FRs induce Chain reaction. *Physiol. Rev.* 87: 315-424.
- Prahalathan C, Selvekuma E, Varalakshmi P (2005). Lipoic acid ameliorates adriamycin-induced testicular mitochondriopathy. *Pubmed:* 15808794. *Reprod. Toxicol.* 20: 111-116
- Qin D, Lung MA (2002). Morphometric study on Leydig cells in capsule-tomized testis of rats. *Asian J. Androl.* 4: 49-53.
- Quiles JL, Huertas JR, Battino M, Mataix J, Ramirez-Tortosa E (2002). Antioxidant nutrients and adriamycin toxicity. linkinghub.elsevier.com/retrieve/pii/S0300483X02003839. *Toxicol.* 180: 79-95.
- Sachdev SK, Davies B (2008). Molecular biology. *Free Rad. Biol. Med.* 44: 215-223.
- Snedecor GW, Cochran WG (1980). Statistical Method, 7th edn. Iowa: Iowa State University Press p. 215.
- Suominen JS, Linderborg J, Nikula H, Hakovirta H, Parvinen M, Toppari J (2003). The effects of mono- 2- ethylhexyl phthalate, adriamycin and N-ethyl-nitrosourea on stage-specific apoptosis and DNA synthesis in the mouse spermatogenesis. *Toxicol. Lett.* 143: 163-173.