

Full Length Research paper

Experimental chronic inflammation induced in mice periodontium by *Actinomyces israelii* entrapped in alginate gel

Vagner Rodrigues Santos^{1*}, João Luis Duval Cândido da Silva¹, Sérgio Monteiro Lima Jr¹, Felipe Alcântara Braga¹, Mariana Passos De Luca¹, Vladimir Reimar A. Souza Noronha¹, Evandro Guimarães Aguiar¹ and Márcio M. Mattos²

¹Laboratory of Microbiology and Biomaterials, Faculty of Dentistry, Universidade Federal de Minas Gerais (UFMG), Belo Horizonte, Minas Gerais, Brazil.

²Laboratory of Pharmacology, Faculty of Pharmacy, Universidade Federal de Minas Gerais (UFMG), Belo Horizonte, Minas Gerais, Brazil.

Accepted 17 September, 2010

Experimental chronic inflammation in periodontal actinomycosis was studied with INCQS standard *Actinomyces israelii* infected mandibula in Swiss/NIH mice (n = 45), male and female with 21 days of age. Tissue responses of the experimentally induced chronic inflammation were investigated in mice by clinical and light microscopy. After anesthetization, the animals were inoculated in paraperiosteal periodontium anterior mandibula with 10⁸ UFC/mL *A. israelii* (n = 45) associated with sodium alginate gel particles. The animals had been evaluated clinically and microscopically at 1, 3, 7, 15, 21, 30 and 45 days after inoculation. Chronic inflammation was induced in all the mice when compared to the control animals. As such, both groups had normal general health throughout the study. In the control mice (n = 10), no lesions were noted. However, the clinical and histopathology evolutions of actinomycosis lesions had been observed and are discussed in this work.

Key words: *Actinomyces israelii*, chronic infection, alginate gel, experimental actinomycosis, periodontium, mice.

INTRODUCTION

Actinomycosis is a chronic granulomatous and suppurative disease (Nishimura, 1986; Kaplan et al., 2009; Alamillos-Granados et al., 2000) caused by *Actinomyces israelii* (Reichenbach et al., 2009), which can be isolated from various sites, including the oral mucosa, dental plaque, deep dental caries cavities and periodontal pockets (Hoshino, 1985; Asgor Moral et al., 1998; Pulverer et al., 2003; Kamma et al., 2004). The cervico-facial actinomycosis is a severe infection of importance in dentistry and oral pathology, presenting itself as an area of difficulty to palpation and fistulas, in which the sulfur granules characteristics of actinomycosis are externalized along with purulent exudate. Usually, the

cause of injury is related to the surgical exposure of the oral cavity and the presence of bacteria in vulnerable patients. *A. israelii* usually occurs in the abdominal, thoracic and cerebral cavities, and in the periapical region of the teeth (Cintron et al., 1996; Nagler et al., 1997; Shen et al., 2005). If an experimental animal model of this orofacial disease were to be established, we could understand more clearly its pathogenesis. In general, it is difficult to induce experimental chronic inflammatory reactions such as those in actinomycosis (Bak et al., 1972; Soler et al., 2009; Tseng et al., 2009). However, there are only a few published reports on experimental actinomycosis (Brown and Lichtenberg, 1970; Behbehani and Jordan, 1982; Behbehani et al., 1983; O'Grady and Reade, 1988; Finley and Beeson, 2010). On the other hand, animal models have been often used to understand periapical pathosis (Walton and Ardjmand, 1992; Baldursdóttir et al., 2010). In these, the alveolar tissues

*Corresponding author. E-mail: vegneer2003@yahoo.com.br.
Tel: +55 31- 3409-2497. Fax: +55- 031-31- 3481-9766, +55- 031-31- 3499-2430.

and/or apical pulpal tissues are exposed to the mouth after surgery, and the invading bacteria easily eliminated by acute inflammatory responses. Thus, the bacterial irritation was not persistent and the tissue responses in these models differ from those in clinical chronic cervico-facial lesions. Sumita et al. (1998) and Reichenbach et al. (2009) reported an animal model of chronic actinomycotic infection in the mouse peritoneum and demonstrated that the use of an entrapping alginate gel is effective for the induction of chronic inflammation.

However, the peritoneal lesion is not satisfactory for an exact understanding of the clinical cervico-facial chronic lesion, because the periodontium tissue is surrounded by calcified bone that is very different from the peritoneum. Microorganisms of *A. israelii* were entrapped in alginate gel and injected into the subcutaneous tissue over the periosteum of the mouse cranium (Asgor Moral et al., 1998; Biszewska et al., 2008; Crossman and Herold, 2009). Thus, it is suggested that this animal model is useful for inducing experimental chronic infectious lesions. If actinomycosis could be produced more efficiently in tissues such as collagenous connective tissue and calcified bone, it would no doubt help to clarify the process of actinomycotic cervico-facial pathosis. However, in cervico-facial actinomycosis, there is no impairment of mandibular alveolar bones (Danic et al., 2008). Furthermore, the development of chronic actinomycotic lesions is yet to be fully elucidated at the level of light microscopy. Our purpose now is to clarify the tissue responses to experimental actinomycosis in the mouse periodontium tissues using light microscopy and observing clinical changes.

MATERIALS AND METHODS

Preparation of the innoculum and induction of the inflammation response

Standardized strain of *A. israelii* (INCQS 00274), which originated from the National Institute of Health Control and Quality (Fundação Oswaldo Cruz -Rio de Janeiro, Brazil), was grown in a brain-heart infusion broth (Difco, USA), supplemented with 0.1% hemin and 0.1% menadione (Sigma, USA) at 37°C for 6 days in an anaerobic globe box (Type Forma Scientific, Marietta, USA), with an atmosphere of 5% CO₂ and 10% H₂, in 85% nitrogen. The bacteria were harvested by centrifugation, washed twice with sterile saline and suspended in 1% solution of sodium alginate (Jeltrate/ Dustless - Dentsply, Argentina). The suspension was agitated and then dropped into 0.07M CaCl₂ solution to make gel particles (0.8 to 1 mm diameter) containing bacteria. The particles in the solution were stirred with a magnetic stirrer for 5 min to prevent their aggregation during curing. The particles were then collected in a stainless-steel wire net of 0.5 mm diameter mesh to eliminate smaller particles. As such, it was washed twice with sterile saline and suspended in 5 ml of sterile saline. The suspension of alginate particles which contained 1.0 x 10⁸ UFC/mL of micro-organism were used for inoculation. Forty-five Swiss/NIH mice with 21 days of age, male and female (Ecology and Fisiology Microorganism Laboratory-ICB-UFMG- Brazil) were inoculated in paraperiosteal periodontium of the anterior mandibula with *A. israelii*. In the same manner, gel particles without bacteria were also prepared and injected into 10 mice, as a control. This experiment was approved by the Ethics

Committee in Animal Experimentation/UFMG (CETEA /UFMG Nº 11/2002).

Identification of bacteria recovered from induced lesions

For the microorganism, identification of the purulent exudate was obtained by pressure from the area of the abscess exudates and was recovered through the fistula, homogenized in 1.0 mL of phosphate-buffered saline (pH 7.0) and diluted in 10-fold (10⁻¹ - 10⁻⁶). Aliquots of 0.1mL of the original solution and of each dilution were cultured on brain-heart infusion blood agar plates supplemented with 0.1% hemin and 0.1% menadione (Sigma, USA) at 37°C for 7 days in anaerobic globe box (Type Forma Scientific, Marietta, USA) with an atmosphere of 5% CO₂ and 10% H₂, in 85% nitrogen (CLSI, 2007). Bacterial genera and species were identified according to Bergey's manual (Hillier and Moncla, 1995) and API diagnostic kits (International Microbio- France).

Clinical evaluation

The animals were clinically evaluated every day during the whole experiment, until the day of sacrifice in each group. The clinical features observed during the study were edema, hyperemia, abscess, fistula and or the presence of purulent secretion.

Microscopical observation

Biopsia materials were collected at 1, 3, 7, 15, 21, 30 and 45 days after inoculation. At each stage, the chosen animals were anaesthetized by intraperitoneal injection of chloral hydrate (400 mg/Kg) and perfused through the ascending aorta with physiological saline, followed by 4% paraformaldehyde in 0.1M phosphate buffer (pH 7.4). The mandibula with induced lesions along with the adjacent tissue were removed and immersed in the same fixative overnight before demineralization in 10% nitric acid at 4°C for 72 h. The demineralized tissues were dehydrated through a graded series of ethanol and embedded in parafin. Parafin sections, 5 µm in thickness, were stained with haematoxylin-eosin (HE) and observed by one researcher in Standar 20 Binocular Zeiss Microscope (Carl Zeiss, Germany), although the subjective criteria for the evaluation and classification of the tissue alterations had been adapted (Orstavik and Mjör, 1988).

RESULTS

The viability and pureness of cultured bacteria had been tested by the colony morphology, stain and biochemical characteristics of the microorganisms collected at the moment before the animals death. The collected microorganism had been compatible with *A. israelii* (Figure 1).

The excrement culture in tioglicolate broth, compared with the culture of samples of the buccal injuries, did not show the presence of bacteria in excrements demonstrating that these microorganisms do not colonize the studied animals (Table 1).

Clinical avaiation

Actinomycotic lesions were induced in all mice (n = 45),

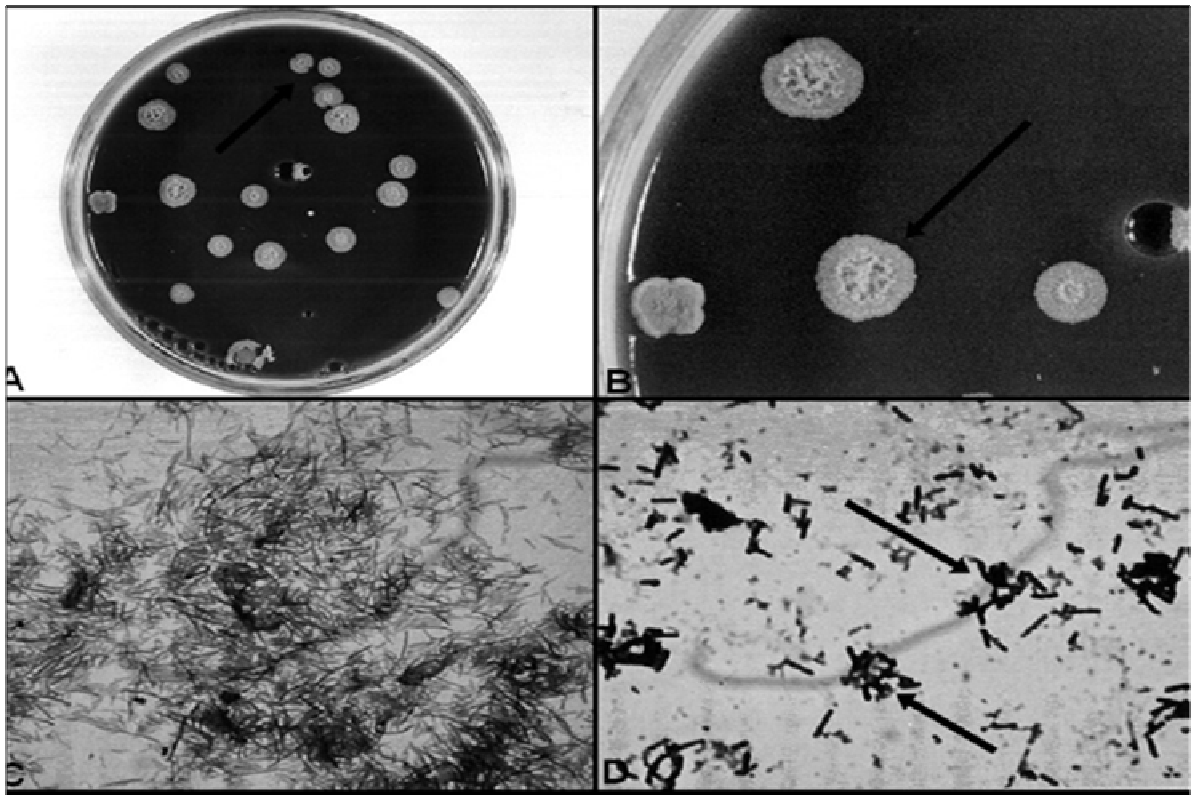


Figure 1. (A) Clinical aspect of actinomycotic abscess/fistula in mice mandibula; (B) Alginate granules content, *A. israelii*, in tissue (HE-40X); (C) Histology aspects of alginate granules and the acute abscess and numerous neutrophils in the mice alveolar bone space; (D) Histology aspects of alginate granules surrounded by foam cells and chronic inflammation with numerous plasm cells in the mice alveolar bone space.

and as such, no lesions were observed in the mice control group (n = 10). In the lesion, the mandible region of the skin was firm, elevated and had lost hair and an erythematous appearance. Abscesses and fistulas were observed on the fourth and seventh day, respectively after inoculation (Figure 2). Fistula had remained until the sacrifice of the animals and had presented various stages of acute abscess. The abscesses and fistulas, if located in the anterior submandibular region, presented a crust with the region of fibrous underlying indications of chronic abscesses. As such, the fistulas remained for 45 days until the sacrifice.

Microscopy

After 1 day, in all the animals that were in the core of the lesion, there was a mass of unstained amorphous material in which bacteria were scattered, corresponding to the injected alginate gel containing *A. israelii*.

After 1 day of inoculation, it was observed that inoculated animals (n = 45) were infiltrated by neutrophils and necrosis areas (Figure 2). These alterations had been observed in circumjacent soft tissues and the medular spaces of the alveolar bone. In the control

groups, numerous neutrophils surrounded the alginate gel, and their numbers and aggregation were less than in the experimental group.

After 3 to 7 days, neutrophil is the predominant cell. In the stained sections, gram-positive bacteria appeared both in the alginate gel and in the masses of neutrophils. In the control group, there are now fewer neutrophils surrounding the lesion and, after 7 days, macrophage-like round cells with a rich cytoplasm were observed. The alginate gel tended to disappear in the control, similar to the previous stage.

After 15 to 21 days, the lesion was more developed. Large cells that appeared foamy by light microscopy had emerged in the area of eosinophilic amorphous structures containing degenerated neutrophils and they invaded the alginate gel islands. The cytoplasm of foamy cells contained clear and/or brown granules. As such, bacteria and neutrophils decreased in number.

In the control group, no lesion was found between the muscle layer and periosteum.

After 30 days, the lesion had become static and the numbers of bacteria had decreased considerably (1.0×10^3 UFC/mL), while the numbers of large foamy cells had increased and invaded the alginate gel islands, taking the place of neutrophils. Consequently, a conspicuous

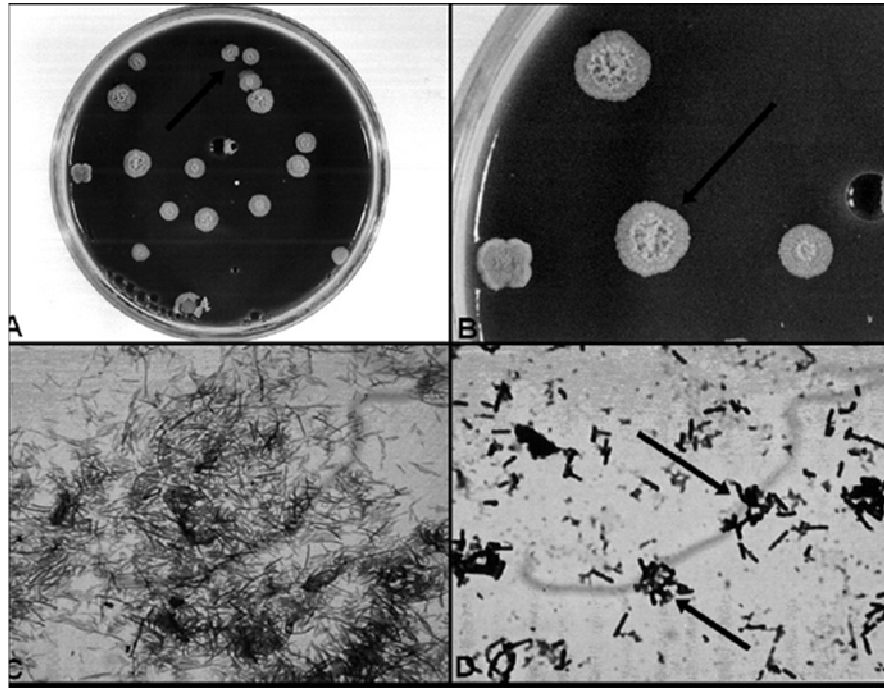


Figure 2. (A) Clinical aspect of actinomycotic abscess/fistula in mice mandibula; (B) Alginate granules content, *A. israelii*, in tissue (HE-40X); (C) Histology aspects of alginate granules and the acute abscess and numerous neutrophils in the mice alveolar bone space; (D) Histology aspects of alginate granules surrounded by foam cells and chronic inflammation with numerous plasm cells in the mice alveolar bone space.

collagenous capsule was seen around and in the alginate gel that surrounds the individual islands as well as the whole lesion. Bacteria were recognizable in the gel, but their number was considerably reduced. However, plasm cells and linphocytes are predominant. After 45 days, the number of neutrophils decreased considerably, whereas foamy and plasm cells remained (Figure 2), and the lesions had become smaller than in the previous stages where a few bacteria were recognizable in the gel.

DISCUSSION

This work follows the experimental model considered by Asgor et al. (1998). This microorganism is bacterium autoctone of the mouth and is related with root canals infections and periodontal abscesses (Hoshino, 1985; Kamma et al., 2004; Shen et al., 2005). As such, the cervicofacial actinomycotic lesions have been isolated (Pulverer et al., 2003).

Microorganisms were entrapped in alginate gel so that most of them were not directly exposed to the host immune system at the initial stage of lesion formation. Thus, bacterial irritation of the host immune system was prolonged. In addition, a known number of bacteria could be injected, and the bacteria in the gel could be restricted to the injected area (Figure 2). Therefore, few bacteria

(10^6 UFC/mL) were able to induce a lesion effectively, and the micro-organisms could survive for a long time, at least for 60 days, in the lesions' gel. It has been recently reported that alginate, a polymer of mannuronic acid and glucuronic acid, occurs naturally in the cell wall of micro-organisms such as *Pseudomonas* spp., and depresses phagocytosis by neutrophils of *Pseudomonas* strains (Yu and Stashenko, 1987). Alginate gel may help to produce chronic infection (Asgor Moral et al., 1998), although experimental actinomycosis has been produced in mice by *Actinomyces* organisms alone (Brown and Lichtenberg, 1970; Bak et al., 1972; Behbehani and Jordan, 1982; Behbehani et al., 1983; Sumita et al., 1997), especially by strains of *A. israelii* that produce granular sediment in broth media (Behbehani et al., 1983).

Experimental actinomycotic lesions, produced in mice (Behbehani et al., 1983; Sumita et al., 1994) and bovine (Verschooten et al., 2000), have some histopathological features identical to those of clinical actinomycotic lesions (Cintron et al., 1996; Nagler et al., 1997).

Fundamentally, Moral et al. (1998) did not observe a clinical picture in the infected animals. In our study, one had been diagnosed of acute abscesses in infected animals two days earlier. Clinically, the abscesses had remained until day 45 after inoculation, when animals of *A. israelii* were carried. This result proves the high

virulence of the wild sample of *A. israelii* when compared with *A. israelii* (ATCC 10048) used by the cited authors. In this work, the clinical aspect which is very important will be an exact understanding of actinomycotic periodontal chronic lesion. Abscesses and extra-buccal fistule approved the chronic nature of the lesion after 30 days.

Diverse researchers have attempted to establish an animal model of periapical infection (Yu and Stashenko, 1987; Walton and Ardjmand, 1992; Tani-Ishi et al., 1994); however, it has not been observed, in literature, in the studies of actinomycosis in periodontics of laboratory animals. Also, the authors have mainly demonstrated the acute inflammatory reply that pathologically differs from the clinical actinomycosis cervico-facial, which is a chronic process. We here demonstrate that infections can be maintained in at least 45 days, and that they are chronic inflammation in periodontium. As such, the experimental chronic lesions at 120 days (Asgor et al., 1998) are demonstrated in the cranium. The alveolar trabeculae of the bone and the soft tissues surrounded mandibula differ in the cranium. Moreover, we believe that the appearance of abscesses in day 2 with permanence until day 45 in the animals with *A. israelii* is related to the virulence of the used microorganism. Liofilized samples, congealed in a long time, can intervene with the biology of the microorganism and can delay the reply immune of the host. Microorganisms were entrapped in alginate gel; thus, the bacterial irritation of the host immune system was prolonged. In addition, knowing the number of would be bacteria that could be infected, and the number of would be bacteria in the gel, could be restricted to the injected area.

It is very important that the would-be bacteria will survive longer, at least 45 days, in the alginate gel. Therefore, in this study, when the progression of the illness for the chronic period of training faster was compared with those of the authors, it was exactly similar with the results of other authors (Sumita et al., 1998; Quirino et al., 2007). In this experiment, actinomycotic lesions, produced in mice, have some histopathological features similar to those of the clinical actinomycotic lesions observed in humans (Metzler et al., 2009; Crossman and Herold, 2009), including periapical actinomycosis (O'Grady and Reade, 1988; Yu and Stashenko, 1987; Oppenheimer et al., 1978; Nishimura, 1986). As such, the typical clinical actinomycotic lesions contained the so-called s-granules by which they are diagnosed as actinomycosis.

The wild *A. israelii* used in this study, representing the "rough" strain, which grows *in vitro*, is granulated into densely packed and intermeshed filaments. Physically, it may be difficult due to neutrophils and macrophages that phagocytose them (Behbehani et al., 1983) and may be explained by the aggressiveness of the microorganism observed through the abscess formation two days after inoculation with the chronic injury in a lesser period to the

one observed. Moreover, Asgor et al. (1998) stated that they used cepa ATCC10048 called "smooth" strain. Based on the present results and earlier studies (Brook, 2008; Lancella et al., 2008; Baldursdóttir et al., 2010), it seems possible that *A. israelii*, by itself, can induce human actinomycotic lesions. However, in natural infections, the source of *A. israelii* would be likely to include mixtures of other organisms. Colonization of the oral cavity in germ-free rats by *A. israelii* and *P. acnes* was difficult and it required repeated inoculations. However, in gnotobiotics rats, colonized with *A. israelii* and *P. acnes*, periodontal pathology was developed in infected animals, including PMN accumulation, gingival migration, alveolar bone resorption and tooth exfoliation (Quirino et al., 2007; Tseng et al., 2010). In this work, the main feature of the study's model is the development of persistent actinomycotic lesions, analogous to chronic actinomycosis in humans.

It is probable also, that other oral bacteria, entrapped by alginate gel, could induce chronic infectious lesions (Howell et al., 1962; Jordan and Kelly, 1983; Murakami et al., 1999). If so, our animal model could also be regarded as representing the clinical chronic cervico-facial pathosis, and might help us to understand the mechanisms of actinomycotic cervico-facial chronic inflammation.

ACKNOWLEDGEMENTS

The authors are grateful to the National Council for Scientific and Technological Development / Ministry of Science and Technology of Brazil and the Research Support Foundation of Minas Gerais for financial support and scholarships in the scientific initiation (PROBIC / PIBIC) of the study.

REFERENCES

- Alamillos-Granados FJ, Dean-Ferrer A, García-López A, López-Rubio F (2000). Actinomycotic ulcer of the oral mucosa: an unusual presentation of oral actinomycosis. *Br. J. Oral Maxillofacial. Surg.*, 38: 121-123.
- Asgor Moral MA, Ohshima H, Maeda T, Hoshino E (1998). Experimental chronic infection induced in mice by *Actinomyces israelii* entrapped in alginate gel. *Arch. Oral Biol.*, 43: 485-496.
- Bak UB, Yamamoto H, Azuma R (1972). Experimental actinomycotic abscess in mice of several strains. *Nation. Instit. Anim. Health Q.*, 12: 232-243.
- Baldursdóttir E, Jónasson L, Gottfredsson M (2010). The many faces of Actinomycosis. Results from a retrospective study in Iceland, 1984-2007. *Laeknabladid*, 96: 323-328.
- Behbehani MJ, Jordan HV (1982). Comparative pathogenicity of *Actinomyces* species in mice. *J. Med. Microbiol.*, 15: 465-473.
- Behbehani MJ, Heeley JD, Jordan HV (1983). Comparative histopathology of lesions produced by *Actinomyces israelii*, *Actinomyces naeslundii* and *Actinomyces viscosus* in mice. *Am. J. Pathol.*, 110: 267-274.
- Biszewska J, Różańska-Kudelska M, Rogowski M, Michalczyk I (2008). Actinomycosis of sinus maxillaries- case report. *Otolaryngol. Pol.*, 62: 782-783.

- Brook I (2008). Actinomycosis: diagnosis and management. *South Med. J.*, 101: 1019-1023.
- Brown JR, von Lichtenberg F (1970). Experimental actinomycosis in mice: study of pathogenesis. *Arch. Pathol.*, 90: 391-402.
- Cintron JR, Pino AD, Duarte B, Wood D (1996). Abdominal actinomycosis. *Dis. Colon Rectum.*, 39: 105-108.
- CLSI/National Committee for Clinical Laboratory Standards (2007). *Methods for Dilution Antimicrobial Susceptibility Tests for Bacteria That Grow Aerobically*; Approved Standard-Fifth Edition:M7-A5 CLSI, Wayne, PA.
- Crossman T, Herold J (2009). Actinomycosis of the maxilla - a case report of a rare oral infection presenting in general dental practice. *Br. Dent. J.*, 206: 201-202.
- Danic D, Penavic IP, Rubin O, Pandak N, Matic I, Hadzibegovic AD (2008). Actinomycosis and osteochondronecrosis of the hyoid bone and thyroid cartilage. *J. Otolaryngol. Head Neck Surg.*, 37: E62-64.
- Finley AM, Beeson MS (2010). Actinomycosis osteomyelitis of the mandible. *Am. J. Emerg. Med.*, 28: 118-120.
- Hillier SL, Moncla BJ (1995). *Peptostreptococcus*, *Propionibacterium*, *Eubacterium*, and other Nonsporeforming anaerobic Gram-positive Bacteria. In: Murray PR, Baron EJ, Pfaller MA, Tenover FC, Tenover RH, editors. *Manual of Clinical Microbiology*. Washington: ASM Press, p. 587-602.
- Hoshino E (1985). Predominant obligate anaerobes in human carious dentine. *J. Dent. Res.* 64: 1195-1198.
- Howell A, Stephan RM, Paul F (1962). Prevalence of *Actinomyces israelii*, *A. naeslundii*, *Bacterionema matruchotii*, and *Candida albicans* in selected areas of the oral cavity and saliva. *J. Dent. Res.*, 41: 1050-1058.
- Jordan HV, Kelly DM (1983). Persistence of associated Gram-negative Bacteria in Experimental Actinomycotic lesions in mice. *Infect. Immun.*, 40: 487-489.
- Kamma JJ, Nakou M, Gmur R, Baehi PC (2004). Microbiological profile of early onset/ aggressive periodontitis patients. *Oral Microbiol. Immun.*, 19: 314-321.
- Kaplan I, Anavi K, Anavi Y, Calderon S, Schwartz-Arad D, Teicher S, Hirshberg A (2009). The clinical spectrum of Actinomyces-associated lesions of the oral mucosa and jawbones: correlations with histomorphometric analysis. *Oral Surg. Oral Med. Oral Pathol. Oral Radiol. Endod.*, 108: 738-746.
- Lancella A, Abbate G, Foscolo AM, Dosdegani R (2008). Two unusual presentations of cervicofacial actinomycosis and review of the literature. *Acta Otorhinolaryngol. Ital.*, 28: 89-93.
- Mettler S, Brunner F, Lambrecht JT (2009). Cervicofacial actinomycosis: two cases reports. *Schweiz. Monatsschr. Zahnmed.* 119:239-251.
- Murakami S, Azuma R, Oomi H, Watanabe T, Suzuki S, Koeda T, Fujiwara H (1999). Experimental actinomycosis caused by Actinomyces-like bacteria in mice and a sow. *Zentralbl. Veterinarmed. A.*, 46: 533-543.
- Nagler R, Peled M, Laufer D (1997). Cervico facial actinomycosis. *Oral Surg. Oral Med. Oral Pathol. Oral Radiol. Endod.*, 83: 652-656.
- Nishimura RS (1986). Periapical actinomycosis. *J. Endod.*, 12: 76-79.
- O'Grady JF, Reade PC (1988). Periapical actinomycosis involving *Actinomyces israelii*. *J. Endod.*, 14: 147-149.
- Oppenheimer, S.; Millaer, G.S.; Kenneth, K.; Blechman, H (1978). Periapical actinomycosis: An unusual case report. *Oral Surg.*, 46: 101-106.
- Orstavik D, Mjör IA (1988). Histopathology and x-ray microanalysis of the subcutaneous tissue response to endodontic sealers. *J. Endod.*, 14: 45-49.
- Pulverer G, Schutt- Gerowitz H, Schaal KP (2003). Human cervicofacial actinomycosis: microbial data for 1997 cases. *Clin. Infect. Dis.*, 37: 490-497.
- Quirino LC, Gomes RT, Lima Jr SM, Braga FA, Nicoli JR, Matos MM, Santos RS (2007). Experimental oral chronic infection induced by *Actinomyces israelii* and *Propionibacterium acnes*. *Arq. Odontol. (UFMG)*, 43: 73-78.
- Reichenbach J, Lopatin U, Mahlaoui N, Beovic B, Siler U, Zbinden R, Seger RA, Galmiche L, Brousse N, Kayal S, Gungör T, Blanche S, Holland SM (2009). Actinomyces in chronic granulomatous disease: an emerging and unanticipated pathogen. *Clin. Infect. Dis.*, 49: 1703-1710.
- Shen S, Samaranyake LP, Yip HK (2005). Coaggregation profiles on the microflora from root surface caries lesions. *Arch. Oral Biol.*, 50: 23-32.
- Soler Sendra A, Subirana Pozo FX, Consola Maroto B, Serra Carreras J, Cuquet Pedragosa J (2009). Tonsillar actinomycosis manifested as expectorated debris. *Acta Otorrinolaringol. Esp.*, 60: 372-374.
- Sumita M, Iwaku M, Hoshino, E (1998). Experimental actinomycosis in mice using alginate gel particles containing Actinomyces israelii. *Endodont. Dent. Traumatol.*, 14: 137-143.
- Tani-Ishi N, Wang CY, Tanner A, Stashenko P (1994). Changes in root canal microbiota during the development of rat periapical lesions. *Oral Microbiol. Immun.*, 9: 129-135.
- Tseng SK, Tsai YL, Li UM, Jeng JH (2009). Radicular cyst with actinomycotic infection in an upper anterior tooth. *J. Formos Med. Assoc.*, 108: 808-813.
- Verschooten F, Vermeiren D, Devriese L (2000). Bone infection in the bovine appendicular skeleton: a clinical, radiographic, and experimental study. *Vet. Radiol. Ultrasound*, 41: 250-260.
- Walton RE, Ardjmand K (1992). Histological evaluation of the presence of bacteria in induced periapical lesions in monkeys. *J. Endod.*, 18: 216-221.
- Yu SM, Stashenko P (1987). Identification of inflammatory cells in developing rat periapical lesions. *J. Endod.*, 13: 535-540.