

Full Length Research Paper

Percutaneous bone marrow grafting in delayed union and non-union

Iftikhar H. Wani^{1*}, Vikas Padha², Masrat Jan³ and Abdul Q. Salaria⁴

¹Government Hospital for Bone and Joint Surgery, Barzulla Srinagar J & K, India.

²Senior resident IndraGandhi Medical College Shimla, India.

³Department of Anesthesia and Critical Care Medicine, Government Medical College Srinagar, Kashmir, J & K India.

⁴Department of Orthopaedics, Achariya Shri Chander College of Medical Sciences (ASCOMS) Jammu, J & K India.

Accepted 5 November, 2012

Percutaneous bone marrow injection is a simpler method of performing autologous bone grafting with less morbidity than standard technique. Autologous bone grafting has been a standard operative method used for the treatment of delayed union and non-union for decades but has been associated with numerous complications. In recent times, percutaneous bone marrow grafting has emerged as a successful alternative to traditional method of open bone grafting. The medical records and radiographs of 50 patients of delayed and non-union were analysed between 2007 to 2010 in our institution. Among those, 38 cases were of delayed union and 12 of non-union involving different bones of the body, with tibia as the most common site (54%). 39 cases were males and 11 females. Mode of injury was road traffic accident in 70% of the cases. Duration of injury was 20 to 24 weeks in 22% of cases followed by 24 to 28 weeks in 18% of cases. Among 50 cases, local anaesthetic was used in 39 cases. Only one injection was given in 30 cases (60%) and two injections in 20 cases (40%). 73.3% cases of delayed union required only one injection and out of 12 cases of non-union, 10 cases (83.3%) required two injections. The cases were evaluated radiologically after a variable period of time for callus formation. Mean time taken for union in successful cases was 14.6 weeks in delayed union and 18.4 weeks in non-union. Out of 50 cases, union was achieved in 46 cases. Union rate was more in case of delayed union (97.37%). In case of non-union, percutaneous bone marrow injection was successful in only 75% of the cases. We concluded that percutaneous autologous bone marrow grafting has been most useful for preventive treatment of non-union by early injection in delayed union, with less complications and morbidity. The general idea is that the minimally invasive technique of percutaneous bone marrow grafting is worth exploring before embarking on a more extensive open surgery.

Key words: Percutaneous bone marrow grafting, delayed union, non-union, injection.

INTRODUCTION

Autologous bone grafting has been a standard operative method used for the treatment of delayed union and non-union for decades but has been associated with numerous complications. Autologous bone potentially contributes three vital components for healing which are

osteoconduction, osteoinduction and osteogenic cells but operative harvesting is associated with numerous complications both at donor and recipient sites. In addition, the need to open the recipient site has added to the risk of devascularisation of the fracture where healing

*Corresponding author. E-mail: drihwani@yahoo.co.in. Tel: +91-9469212594.

is already impaired. The non-operative methods include the use of low intensity ultrasound, electrical stimulation and electromagnetic stimulation but all these procedures are tedious, require sophisticated equipments, expertise and anaesthesia for surgery and are time consuming, hence a continuous search has been made to find out such an alternative method of treating delayed and non-union which is safe, easy and economical.

In recent times, percutaneous bone marrow injection has emerged as a successful alternative to traditional methods of treatment. Bone marrow injection has shown to have stimulated callus formation where autologous bone grafting has failed. Though all of these methods have shown varying degrees of excellent to good results but most of the techniques are tedious and require sophisticated equipments, expertise, anaesthesia and are time consuming, with added risk of infection (Garg et al., 1993). Osteogenic precursor cells which are capable of producing bone have been demonstrated among the stromal and endosteal cells of bone marrow, which are the key elements in the process of bone formation and fracture healing (Friedenstein, 1973). The determined and inducible marrow cells supplement periosteal and primitive mesenchymal cells to form cellular component of bone healing (Gray and Elves, 1979). It is a minimally invasive procedure with negligible complications.

Encouraged by the simplicity and minimal complication rate of bone marrow grafting for delayed and non-union in experimental studies and clinical trials, the prospective study has been taken in our institution to evaluate the efficacy of this procedure.

MATERIALS AND METHODS

50 cases of post-traumatic delayed and non-union (out of 50 cases 38 were delayed and 12 were non-union), irrespective of their age and sex, were selected from orthopaedic out patient department from 2007 to 2010 after which they were examined clinically and radiologically to establish the diagnosis on the basis of following criteria.

Inclusion criteria

Clinical criteria include: 1. Age of fracture more than 12 weeks; 2. Abnormal mobility at the fracture site; 3. Tenderness at the fracture site; 4. Pain on applying bending stresses.

Radiological criteria include: 1. Gap at the fracture site; 2. Insufficient amount of callus; 3. Sclerosis of fracture ends; 4. Obliteration of bone marrow cavity at the fracture sites.

Exclusion criteria

Patients with infection and local malignancy were excluded from the study.

Operative technique

The procedure was performed as an outdoor/indoor procedure under local/short general anaesthesia. Under all aseptic

precautions, patient was put in supine position and donor and recipient sites were prepared separately but simultaneously to prevent cross contamination of needles. Bone marrow was aspirated from the donor iliac crest with a bone marrow aspiration needle connected to a 20 ml syringe. About 10 to 15 ml of marrow was aspirated from one site and to obtain more, multiple aspirations were done. The aspirated marrow was injected percutaneously immediately at the recipient fracture site with the help of a 16 gauge spinal needle under image intensifier. On random basis, aspirate slides were made to confirm bone marrow cells under microscope. After bone marrow injection, the recipient site was immobilised either by plaster of Paris cast or with the help of braces. Donor site was dressed and sealed. Serial X-rays were taken at interval of 4 to 6 weeks (including special views to see callus formation) and if needed second injection was given.

Assessment of results

All cases were followed after an interval of 4 to 6 weeks for 6 months following the bone marrow injection and then after a variable period of time depending on callus formation. The clinical as well as radiological assessment of union was done.

Criteria for union

Clinical criteria for union include: 1. No abnormal mobility at the fracture site; 2. No pain at the fracture sites on applying bending stresses; 3. No tenderness.

Radiological criteria for union include: 1. No gap at the fracture site; 2. Sufficient amount of callus.

RESULTS

Percutaneous bone marrow grafting was done in 50 patients of delayed union and non-union over a period of two years and was followed for an average period of 18 months. Out of 50 patients, 33 (66%) were found in the age group of 21 to 40 years. One case was above 60 years and 2 patients were below 21 years of age. 39 (78%) cases were males and 11 (22%) were females. 35 (70%) of our cases had road traffic accident as mode of injury, 11 (22%) cases as fall and 4 (8%) cases as assault. Duration of injury is shown in Table 1. Mean duration of injury was 28.1 weeks.

The study included 38 (76%) cases of delayed union (Case 1) (Figures 1, 2, and 3) and 12 (24%) cases of non-union. Prior to bone marrow injection various modes of internal fixation (Case 2) (Figures 4, 5, and 6) were done in 17 (85%) cases and external fixation in 3 (15%) cases and rest of 30 cases were treated conservatively before bone marrow injection. Out of 50 cases, local anaesthesia was used in 39 cases and in 11 cases, procedure was done in short general anaesthesia. Only one injection was needed in 30 (60%) cases and in 20 (40%) cases, injection was repeated. In none of the cases, more than two injections were given. Out of 12 cases of non-union, 10 of them required second injection. Results were finalised after careful clinical and radiological examination and final inference was made as given in Table 2.

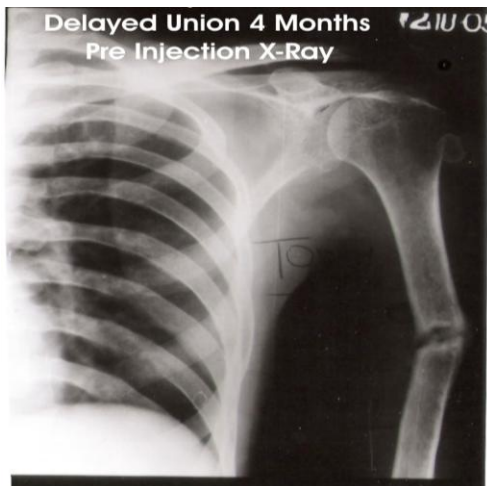

Figure 1. Delayed union humerus.

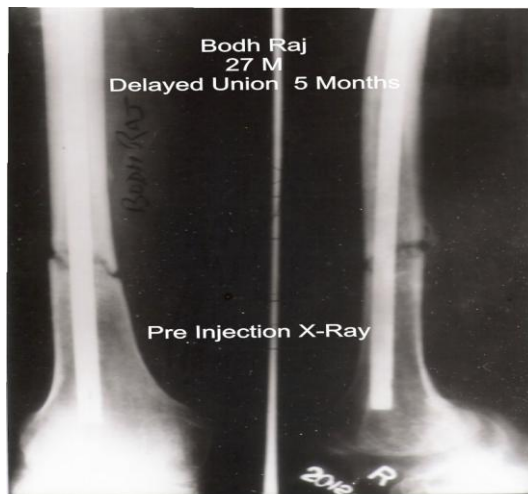


Figure 4. Delayed Union distal femur, 5 months.

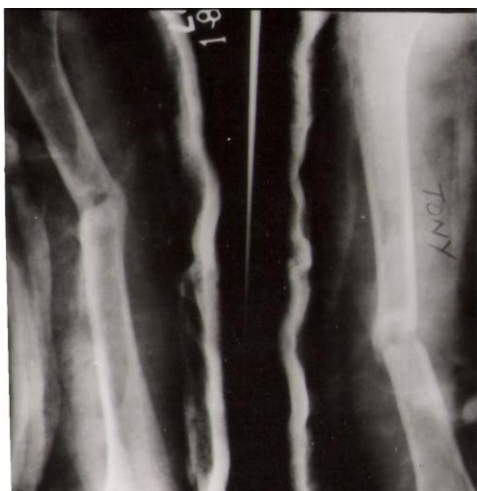


Figure 2. 6 Weeks after bone marrow injection.

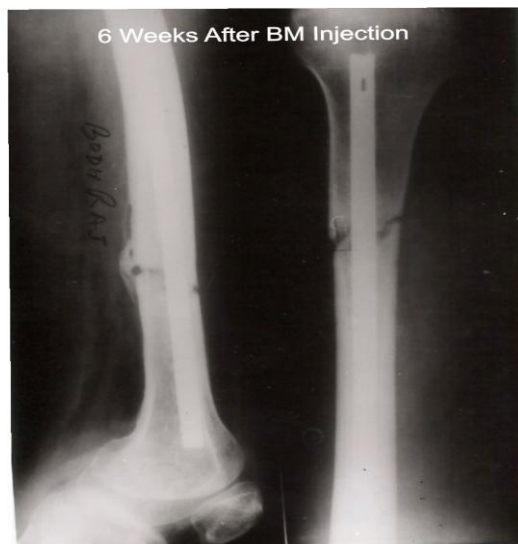


Figure 5. Distal femur delayed union, 6 weeks after bone marrow injection.

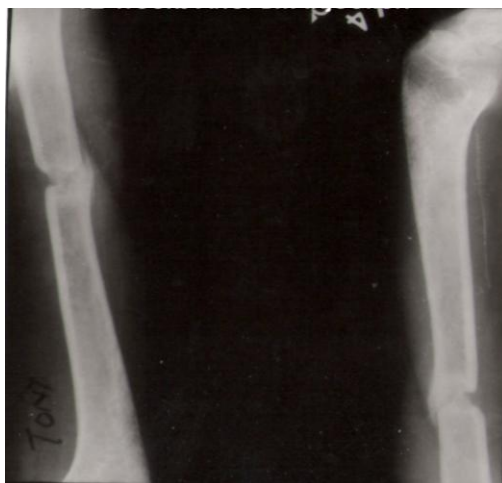

Figure 3. 12 weeks after bone marrow injection.

Out of the 4 cases in which union was not achieved, three of them were non-union and one delayed union. The mean time for appearance of callus in successful cases was 4.9 weeks and most of the cases united within 12 to 22 weeks after bone marrow injection. Mean time taken for union in successful cases is given in Table 3. In our series of 50 cases of delayed union and non-union grafted with autologous bone marrow by percutaneous complication was seen. There was no complication at recipient site. No sign of infection at donor or recipient was encountered in any patient included in this study. It was observed that at times, the injection of bone marrow injection except for little pain during aspiration of bone marrow (that too under local anaesthesia), no at fracture site became difficult whenever there was slight delay in

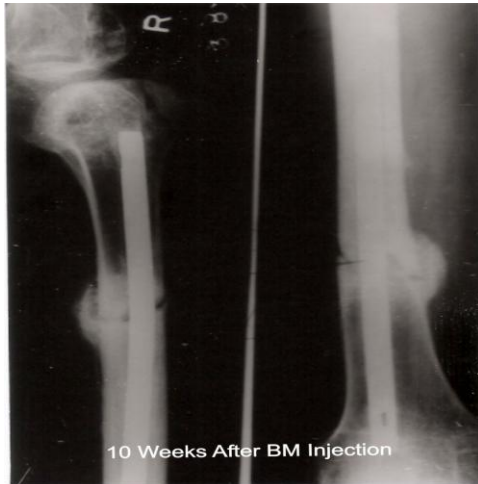

Figure 6. Distal femur delayed union, 10 weeks after bone marrow injection.

injecting the aspirated marrow at the fracture site. This technical difficulty was avoided by inserting the 16-gauge spinal needle at the fracture site under image intensifier prior to aspiration of bone marrow from iliac crests that the procedure could be completed as rapidly as possible.

DISCUSSION

Delayed union and non-union are rare but well known complications of long bone fractures which present a major challenge to an orthopaedic surgeon despite continued advances in their treatment. For long, autologous cancellous bone grafting has been the standard of treatment. But this bone grafting has not been without complications such as painful scar, hematoma, infection, fracture or subluxation and gait disturbances. Various methods of treating delayed and non-unions have been described such as Onlay bone grafting with or without internal fixation (Campbell, 1939; Phemister, 1947), cancellous insert grafts (Nicoll, 1956), subcortical iliac bone grafts (Forbes, 1961), dual only bone grafts (Boyd, 1941), stimulation by direct current through implanted electrodes (Peterson and Lewis, 1980) and by an electro magnetic field about the site of fracture (Sharrard et al., 1982). In bone grafting, the bone grafts mainly act as a scaffold with most of the cellular elements dying out and being replaced by creeping substitution (Charls, 1992). Bone marrow injection has shown to have stimulated callus formation where autologous bone grafting has failed. Though all of these methods have shown varying degrees of excellent to good results, but most of the techniques are tedious and require sophisticated equipments, expertise, anaesthesia and are time consuming with added risk of infection (Garg et al., 1993).

McGaw and Habin (1934) were among the first to demonstrate the osteogenic activity of bone marrow. They

Table 1. Duration of injury.

Duration of injury (weeks)	No. of cases	Percentage
12-16	5	10
16-20	8	16
20-24	11	22
24-28	9	18
28-32	3	6
32-36	2	4
36-40	5	10
40-44	3	6
44-48	1	2
48-52	1	2
>52	2	4
Total	50	100

Mean duration of injury was 28.1 weeks.

Table 2. Final results after careful clinical and radiological examination.

Outcome	No. of cases	Percentage
Union achieved (success)	46	92
Union not achieved (failure)	4	8
Total	50	100

Table 3. Mean time taken for union in successful cases.

Parameter	No. of successful cases	Time in weeks
Delayed union	37	14.6
Non-union	9	18.4
Total	46	15.3

Table 4. The types of cases in our study were both delayed and non-union in comparison to other studies.

Parameter	Delayed union	Non-union
Our study	38	12
Healey et al. (1990)	8	0
Connolly et al. (1991)	0	15
Verma and Kulshershtha (1997)	0	35
Goel et al. (2005)	0	20

They grafted bone defect in dog fibulae with bone marrow alone and compared this with contralateral ungrafted defect. Only the bone marrow grafted defect filled the gap with bone. The osteogenicity of bone marrow has been traced to the stromal and endosteal cells of the marrow. Two types of osteoprogenitor cells (OPC) have been demonstrated. One that is induced to produce bone (IOPC) and the other that is determined to produce bone

Table 5. Comparison of repeated bone marrow injections with other studies.

Parameter	Injections			
	1	2	3	4
Our study	30	20	0	0
Garg et al. (1993)	0	15	0	0
Verma and Kulshershta (1997)	0	0	0	35
Goel et al. (2005)	2	9	4	0

In our study, we repeated bone marrow injection for the second time after interval of 6 weeks in 20 cases which included 10 cases of non-union out of 12 and 10 cases of delayed union out of 38 in comparison to other studies as given in Table 6.

Table 6. Comparison of results with other studies.

Study	Success rate% (union achieved)
Healey et al. (1990)	62.5 (5 out of 8 patients)
Connolly et al. (1991)	90 (18 out of 20 patients)
Goel et al. (2005)	75 (15 out of 20 patients)
Our series	92 (46 out of 50 patients)

The results achieved are comparable to other studies.

(DOPC) (Sharrard et al., 1982). The former (IOPC) exists in all connective tissue and the latter (DOPC) is found only in the marrow. Because bone marrow is the only tissue that contains an abundance of both determined and inducible osteoprogenitor, it is a logical graft choice (Budenz and Bernard, 1980).

The concept of bone grafting percutaneously was introduced by Herzog (1951). He used a large bore needle and small cancellous chips to graft a non-union. Since bone marrow has a liquid texture, combining the percutaneous grafting technique introduced by Herzog (1951) and the bone marrow graft introduced by McGaw and Habin (1934) seemed a logical step. An experimental study on percutaneous bone marrow grafting of fractures and bony defects was conducted by Paley et al. (1986) on thirty adolescent white rabbits. Bone marrow and saline control was injected percutaneously in to fracture site of bony defects. Results showed that bone marrow grafting sites had earlier and more abundant callus. Similarly, the bony defect which were grafted with bone marrow united by a bony bridge whereas the saline control did not. These effects were optimal when used early in the fracture healing process.

The types of cases in our study were both delayed and non-union in comparison to other studies as given in Table 4. We included cases in which either internal or external fixation was done prior to bone marrow injection in comparison to study by Verma and Kulshershta (1997) and Goel et al. (2005). The mean duration of fracture in our study was 7 months in comparison to studies by Goel et al. (2005). In our study we repeated

bone marrow injection for the second time after interval of 6 weeks in 20 cases which included 10 cases of non-union out of 12 and 10 cases of delayed union out of 38 in comparison to other studies as given in Table 5. Union was achieved in 92% cases (46 out of 50 cases) after a mean time of 15.3 weeks. The results achieved are comparable to other studies as given in Table 6. This high success rate proves beyond doubt the high osteogenicity of bone marrow and it has established that bone marrow grafting by percutaneous injection is equally effective as open bone grafting and that too, with numerous advantages. So percutaneous bone marrow grafting is a simple, minimally invasive technique, which can be done as an outdoor procedure. It is safe, easy, practical and time saving. Moreover, it is economical and shortens the hospital stay of the patient. It is an easy treatment for a difficult problem.

Conclusion

Our study has established that bone marrow has high osteogenic potential and can be grafted percutaneously successfully. This procedure of bone marrow grafting by percutaneous injection has tremendous clinical potential with no complications. This minimally invasive procedure is a biological method of bone grafting as it does not disturb the vascularity at the fracture site. It is an easy, safe, simple, economical and short procedure that can be performed as an outdoor procedure under local anaesthesia. So, it is a very useful procedure for those patients who are not fit for general anaesthesia. It is both patient friendly as well as surgeon friendly procedure. In short, it is an easy solution for a complex problem.

REFERENCES

- Boyd HB (1941). Congenital pseudarthrosis: Treatment by dual bone grafts. *J. Bone Joint Surg.* 23(3):497-515.
- Budenz RW, Bernard GW (1980). Osteogenesis and leukoporesis diffusion-chamber implants of isolated bone marrow sub population. *Am. J. Anat.* 159:455-74.
- Campbell MC (1939). Onlay bone graft for un-united fracture. *Arch. Surg.* 38:313-27.
- Charls JT (1992). Delayed union and nonunion fractures. In: Crenshaw AH (ed), *Campbell's Operative Orthopaedics Vol. 2*, 8th ed. CV Mosby Company, St. Louis. pp. 1287-345.
- Connolly JF, Guse R, Tiedman J, Dehna R (1991). Autologous marrow injection as a substitute for operative grafting of tibial non-union. *Clin. Orthop. Relat. Res.* 266:259-270.
- Forbes DB (1961). Subcortical iliac bone grafts in fracture of the tibia. *J. Bone Joint Surg. Br.* 43:672-9.
- Friedenstein AJ (1973). Determined and inducible osteogenic precursor cells. In: *Hard tissue growth repair and remineralization*. Ciba Foundation Symposium II, New York. pp. 169-81.
- Garg NK, Gaur S, Sharma S (1993). Percutaneous autogenous bone marrow grafting in 20 cases of ununited fractures. *Acta. Orthop. Scand.* 6:671-2.
- Goel A, Sangwan SS, Siwach RC, Ali AM (2005). Percutaneous bone marrow grafting for the treatment of tibial non-union. *Injury* 36:203-206.
- Gray JC, Elves MW (1979). Early osteogenesis in compact bone

- isografts. A quantitative study of the contributors of the different graft cells. *Clacif. Tissue Int.* 29:225-30.
- Healey JH, Zimmerman PA, Macdonnell JM, Lane JM (1990). Percutaneous bone marrow grafting of delayed union and non-union in cancer patients. *Clin. Orthop. Rel. Res.* 256:280-285.
- Herzog K (1951). Verlängerungosteotomic unter Vernen dungdes percutan gezielt Verriegelten Markangels. *Unfallheikunde* 42:226-30.
- McGaw WH, Harbin M (1934). The role of bone marrow and endostium in bone regeneration. An experimental study of bone marrow and endosteal transplants. *J. Bone Joint Surg.* 14:816-21.
- Nicoll EA (1956). The treatment of gaps in long bones by cancellous insert grafts. *J. Bone Joint Surg. Br.* 38:70-82.
- Paley D, Yound MC, Wiley AM (1986). Percutaneous bone marrow grafting of fractures and bony defects. An experimental study in rabbits. *Clin. Orthop.* 208:300-12.
- Peterson DC, Lewis G (1980). Treatment of delayed union and non-union with an implanted direct current stimulator. *Clin. Orthop.* 148:117-28.
- Phemister DB (1947). Treatment of un-united fracture by only bone graft without screw or tie fixation and without breaking down of the fibrous union. *J. Bone Joint Surg.* 29:946-60.
- Sharrard WJW, Sutcliffe ML, Robson MJ, MacEachern AG (1982). The treatment of fibrous non union of fractures by pulsing electromagnetic stimulation. *J. Bone Joint Surg. Br.* 64:189-93.
- Verma N, Kulshershtha K (1997). Osteogenic re-activation in implant failure. *Indian J. orthopaedics* 31(3):179-185.