

*Full Length Research Paper*

## Assessing the surgical anatomy of the ethmoid sinus in adult Nigerians using computerized tomography scan

S. A. Ameye<sup>1\*</sup>, Y. B. Amusa<sup>1</sup>, J. A. E. Eziyi<sup>1</sup> and O. C. Famurewa<sup>2</sup>

<sup>1</sup>Otorhinolaryngology, Head and Neck Surgery Department, Obafemi Awolowo University Teaching Hospitals Complex, Ile-Ife, Osun State, Nigeria.

<sup>2</sup>Department of Radiology, Obafemi Awolowo University Teaching Hospitals Complex Ile-Ife, Osun State, Nigeria.

Received 8 November, 2014; Accepted 8 December, 2014

We undertook this study to describe the morphology and anatomical variations of ethmoidal sinus in adult Nigerians using computerized tomographic scan, bearing in mind the significance of this sinus in inflammatory pathologies of the other paranasal sinuses and endoscopic sinus surgery. This was a descriptive study of computerized tomographic scans of the paranasal sinuses of 114 subjects constituting 228 ethmoids. All the slides were examined to identify the ethmoidal sinuses and the various anatomical variations. The dimensions of the ethmoids were also measured. There were 83 (72.8%) males in this study. The mean age was  $45.6 \pm 19.3$  years. The means of the length, anterior width, posterior width and height of the ethmoid were 41.4, 11.8, 16.7 and 30.1 mm, respectively. Keros Type III olfactory fossa was found in 163 sides (71.5%). Agger nasi cell was the commonest variation present in 102 sides (44.7%). The most frequent pattern of attachment of uncinat process seen is to the lamina papyracea (191, 32%). We concluded that the dimensions of the ethmoids among the Nigerians studied are similar to findings in other studies. The predominant type of olfactory fossa depth and pattern of insertions of uncinat process suggest that the study population may be at higher risk of certain complications during functional endoscopic sinus surgery (FESS).

**Key words:** Anatomical variations, olfactory fossa, Nigerians.

### INTRODUCTION

The ethmoidal sinus is important in the functioning of the sinus system because the drainage pathway of the paranasal sinuses is either through or adjacent to its lateral wall (Terrier and Stell, 1991). The dimensions of the ethmoids is an important landmark parameter in

functional endoscopic sinus surgery (FESS) especially in simulation and haptic for training otorhinolaryngologist for FESS (Nogueira et al., 2008). Although the anatomy of the paranasal sinuses and hence the ethmoids differ significantly from patient to patient, certain distinct variations

\*Corresponding author. E-mail: sanyaameye@hotmail.com. Tel: +234 806 7444284.

Author(s) agree that this article remain permanently open access under the terms of the [Creative Commons Attribution License 4.0 International License](http://creativecommons.org/licenses/by/4.0/)

**Table 1.** The means of the dimensions of ethmoids and olfactory fossa depth comparing sexes.

Parameter	Female (N=62)	Male (N=166)	Total (N=228)
	Mean $\pm$ SD (mm)	Mean $\pm$ SD (mm)	Mean $\pm$ SD (mm)
Anterior Width	12.2 $\pm$ 2.0	11.6 $\pm$ 1.4	11.8 $\pm$ 1.6
Posterior Width	17.3 $\pm$ 3.5	16.4 $\pm$ 3.9	16.7 $\pm$ 3.8
Length	41.2 $\pm$ 4.6	41.5 $\pm$ 3.8	41.4 $\pm$ 4.0
Height	29.7 $\pm$ 5.4	30.2 $\pm$ 6.0	30.1 $\pm$ 5.8
Olfactory fossa depth	7.7 $\pm$ 3.1	9.1 $\pm$ 3.1	8.7 $\pm$ 3.2

**Table 2.** Percentage distribution of olfactory depth according to Keros' classification.

Keros type	Frequency (%) N=228
I	6 (2.6)
II	59 (25.9)
III	163 (71.5)

are found most frequently among the general population. Varying incidences of such variations have been reported by series of investigators, but very few of these have been studied in Africans (Mazza et al., 2007; Badia et al., 2005).

## MATERIALS AND METHODS

This was a descriptive study of computerized tomographic (CT) scan of the paranasal sinuses of adult patients at the Otorhinolaryngology Department of Obafemi Awolowo University Teaching Hospital, Ile-Ife. Patients with history of major trauma to the face involving the paranasal sinuses, paranasal sinus tumours and previous sinus surgeries were excluded. Informed consent was obtained from consecutive eligible participants. The CT study was taken with Brightspeed (GE Medical System) Tomographic machine at the Department of Radiology of the same hospital. Images acquired were transferred to a Clearcanvas Workstation Version 2.0 (Clearcanvas Inc., Toronto Canada). All measurements were performed at window width of 2000 and at a window level of 40 for each side following standard protocol (Jones et al., 2002). The study parameters were age, sex, dimensions of the ethmoids (anterior width, posterior width, length, height). Presence of specific anatomical variations was also recorded (pneumatized middle turbinate, paradoxical middle turbinate, bifid middle turbinate, infra-orbital cells, sphenoidal cells, agger nasi cells, fronto-orbital cells, aerated crista galli).

The ethmoid widths and length were measured by selecting the most rostral axial slice where the septum, sphenoidal sinuses, nasal bone and sphenoidal ostia were visible. The anterior width was measured at a level of the posterior border of the nasal bone. The posterior width was measured at the juncture between the medial orbital wall and anterior wall of the sphenoid. The length was measured from the midpoint of horizontal line at the level of the posterior border of the ethmoid to the midpoint of the anterior wall of the ethmoid for each side. The height of the ethmoid was obtained by measuring the vertical distance from the midpoint of the

roof of ethmoid to the horizontal line at the level of the inferior attachment of the uncinat process that is, the superior border of the inferior turbinate. This measurement was taken in the most posterior coronal slice showing orbits, anterior skull base, middle turbinate and hard palate. The depth of olfactory fossa was obtained by measuring the vertical distance between the horizontal line passing through the supraorbital ridge and the cribriform plate (Jones et al., 2002) (Figure 1). The height of the olfactory fossa was classified according to Keros (Keros, 1962). The anatomical variations were identified using definitions utilized by similar work (Bolger et al., 1991). Analysis of data was done with SPSS version 17. Statistical significance was inferred at p less than or equal to 0.05.

## RESULTS

A total of 114 patients were recruited into the study constituting 228 ethmoidal sinuses. There were 83 (72.8%) males. Their age ranged from 17 to 73 years (mean 45.6  $\pm$  19.3). The mean age of male is 47.7  $\pm$  19.4 years and the mean age of female is 40.0  $\pm$  18.0 years. The mean dimensions of the ethmoid and the olfactory fossa depth are shown in Table 1. Table 2 shows the distribution of Keros classification of olfactory fossa depth. At least one anatomical variation was demonstrated in 107 (93.9%) of the subjects and 91 (79.8%) showed more than one anatomical variation. Table 3 shows the prevalence of the anatomical variations and the pattern of insertion of uncinat process is show in Table 4.

## DISCUSSION

In this study, we found slightly higher dimensions of the ethmoids with respect to height and anterior width compared

**Table 3.** Various anatomical variations identified and frequency.

<b>Anatomical variation</b>	<b>N=114 (%)</b>	<b>Total occurrence (%) N = 228</b>
<b>Pneumatized middle turbinate</b>		
Unilateral	23 (20.1)	71 (31.1)
Bilateral	24 (21.1)	
<b>Paradoxical middle turbinate</b>		
Unilateral	3 (2.6)	17 (7.5)
Bilateral	7 (6.1)	
<b>Bifid middle turbinate</b>		
Unilateral	8 (7.0)	24 (10.5)
Bilateral	8 (7.0)	
<b>Infra-orbital cells</b>		
Unilateral	8 (7.0)	8 (3.5)
Bilateral	0 (0.0)	
<b>Sphenoethmoidal cells</b>		
Unilateral	6 (5.3)	6 (2.6)
Bilateral	0 (0.0)	
<b>Agger nasi cells</b>		
Unilateral	34 (29.8)	102 (44.7)
Bilateral	34 (29.8)	
<b>Fronto-orbital cells</b>		
Unilateral	5 (4.4)	59(25.9)
Bilateral	27 (23.7)	
<b>Aerated crista galli<sup>a</sup></b>	1 (0.9)	

<sup>a</sup>for crista galli, N can only be 114 since it has only single occurrence per subject.

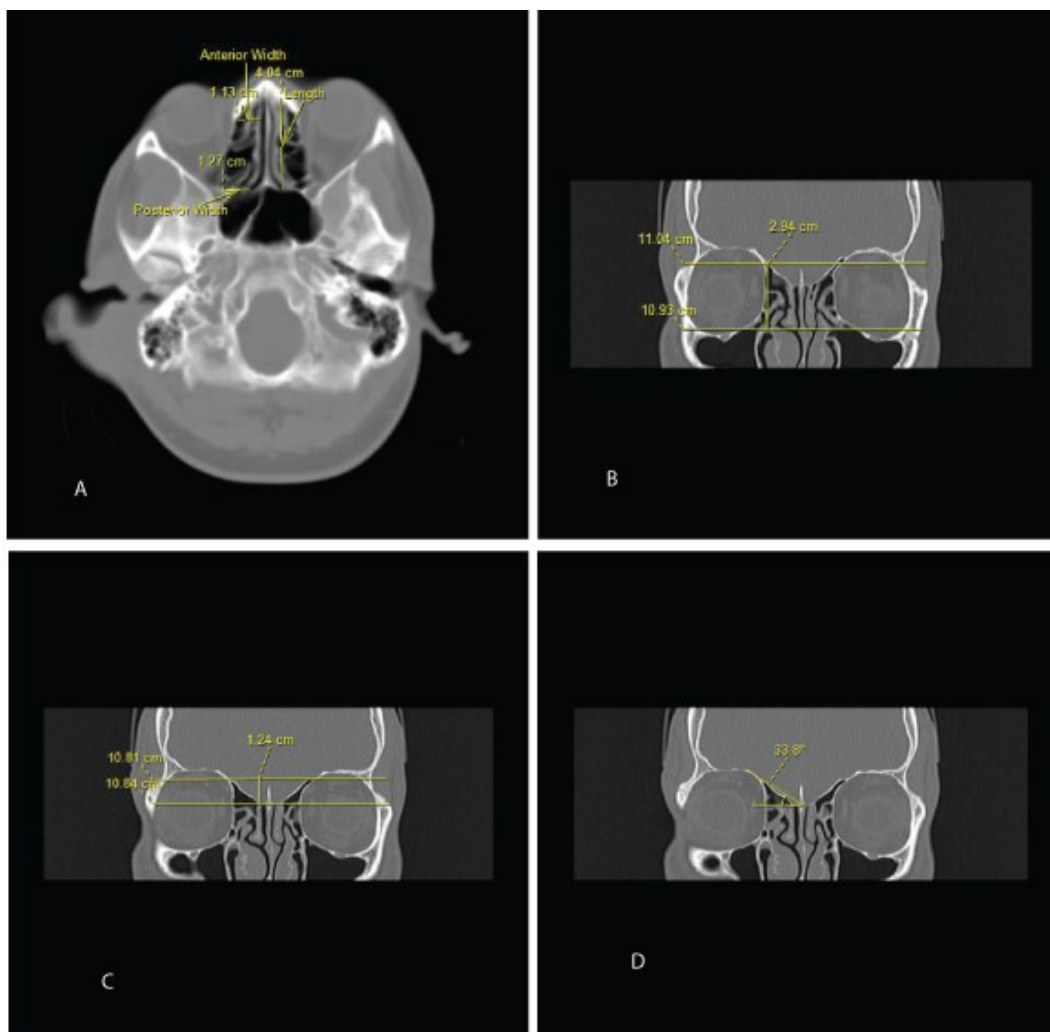
**Table 4.** Types of insertion of the uncinat process and frequency.

<b>Superior attachment of the uncinat process</b>	<b>Frequency (%) N = 228</b>
Lamina Papyracea	191 (83.8)
Middle Turbinate	32 (14.0)
Roof Of Ethmoid	5 (2.2)

with previous study (Polavaram et al., 2004). This could be due to the fact that the dimensions obtained from CT do not have to contend with the thickness of mucosa lining compared with what is obtained when taking measurement from cadaver. Also, the anterior width was not taken at the apex of the ethmoids because on CT, the apex tapers to almost zero width and thus a relatively

more meaningful and consistent landmark was chosen. The height of the ethmoid was also taken from the level of inferior attachment of the uncinat process as a consistent landmark (Figure 2). Such landmarks were not specified by previous study.

Over two-third of the olfactory fossa type in this study were Keros Type III which is not consistent with findings



**Figure 1.** Measurement of dimensions of the ethmoids and olfactory depth. (A) Anterior width, posterior width and length (B) Height (C) Olfactory fossa depth (D) Olfactory fossa take-off angle.

in any of the literature referenced. We are however aware that other works too have not shown consistent findings across ethnic nationalities. In adult Thai, type II was most common followed by type III and type I (Nitinavakarn et al., 2005). Type I fossa was found in 86.1% of Filipinos (Paber et al., 2009). In Italians, the mean was found to be 5.94 mm (Type II) (Meloni et al., 1992). The significance of Type III fossa is the increased risk of inadvertently damage to the anterior cranial fossa during endoscopic sinus surgery.

This study shows that there is high prevalence of anatomical variation which further support their relevance. Similar works have shown prevalence of these variations to be less (Bolger et al., 1991; Perez et al., 2000; Tonai and Baba, 1996). However, finding of

prevalence of 93% has been shown by another study (Earwaker, 1993). In this study, pneumatization of the middle turbinate (PMT) was present in 41.2% of the subject and 31.1% of the total ethmoidal sinuses analyzed. This is similar to other studies which showed the prevalence of PMT to be between 34 and 53% (Bolger et al., 1991, Sazgar et al., 2008, Stallman et al., 2004, Subramanian et al., 2005, Nitinavakarn et al., 2005). This wide variation in the prevalence may be due to difference in criteria used to define PMT (Perez et al., 2000; Zinreich et al., 1987). In this study, pneumatization of the middle turbinate regardless of size or location was regarded as PMT.

The prevalence of agger nasi cells (ANC) has been shown to have wide range of variability due to varying

anatomical definitions. Values as low as 2% (Lloyd, 1990) and as high as 98.5% (Bolger et al., 1991) have been reported. This study, using the criteria used by Bolger et al. (1991) found ANC in 59.6% of the subjects studied. In one half of these subjects, the occurrence is bilateral. Although, this finding is similar to the finding of 56.7% prevalence of ANC in a study performed in Iranian (Talaiepour et al., 2005). This study used the criteria specified by Bolger et al. (1991), which is more inclusive, and still found value much lower than what was obtained. Thus, one can surmise that despite the fact that the ANC is the most prevalent variation in this study; the value obtained is still relatively lower than what obtained for other populations.

This study found the prevalence of paradoxical middle turbinate (PMT) to be 8.8% and occurred more than twice bilaterally than unilaterally. This value is higher than value of 5.3% obtained in similar study in Thai (Sukalaya and Vachiranubhap, 2005) but lower than values obtained in other studies (Calhoun et al., 1991; Lloyd, 1990). This study found infra-orbital cells (IOC) in 7% of the study population. All were unilateral. The results of the present study are in accordance with others in that the IOC is an infrequent finding among the variations in paranasal sinus anatomy. However, despite the low value of 2% reported by Lloyd (1990), Bolger et al. (1991) reported its occurrence in 45.1% of his study population using same criteria as Lloyd. Other reported values include 9.4% by Sukalaya and Vachiranubhap (2005), 10% by Zinreich et al. (1987) and 18% by Kantarci et al. (2004). The relative intermediate prevalence (18%) occurrence of this cell in Kantarci's report has been attributed to the large sample size studied. The clinical significance of IOC is that it has been implicated as a possible etiologic factor in recurrent maxillary sinusitis due to their negative influence on maxillary sinus ventilation by narrowing the infundibulum and ostium.

Sphenoethmoidal cell (SOEC, Onödi Cell) is the most posterior ethmoid air cell that extends laterally. This extension is in close proximity to the carotid canal and the optic nerve, which underscores the clinical importance of this anatomic variation prior to any attempt of invasive intervention. The endoscopic surgeon must pay close attention to the occasional SOEC cell in preoperative evaluation to avoid potential complications of endoscopic sinus surgery. It is also strongly associated with rhinogenic optic neuritis and rarely isolated mucocele of the sphenoethmoidal cell may cause optic neuropathy (Nonaka et al., 2007; Ogata et al., 1998). This study found SOEC in 5.3% of the subjects. Reported prevalence rates were 7% by Talaiepour et al. (2005), 8% by Stammberger and Kennedy (1995) and 51% by Yeoh and Tan. (1994).

Fronto-orbital cells (FOOC) were found in 28.1% of the cases in this study. Reported values in the literature were

18% by Meloni et al. (1992) and cited works of Onodi and Muray (Japanese skulls) by Meloni with values of 10 and 61%, respectively. The importance of FOOC is related to the neurosurgical approach to the orbit performed from the anterior cranial fossa. The presence of this recess may jeopardize the sterility of the operating field. One instance of aerated crista galli was found in this study. An aerated crista galli may communicate with the fronto-nasal duct creating the potential for involvement of the crista galli in sinusitis and/or mucocele formation (Oliverio et al., 1995).

The insertion of superior attachment of the uncinate process is variable and has been classified generally into three groups. In this work, most of insertions of the uncinate process were into the lamina papyracea. With this, the ethmoid infundibulum and the frontal recess are separated from each other, and so the frontal sinus drains into the middle meatus medial to the infundibulum.

In conclusion, this study has shown that the dimensions of the ethmoids in the study population who are blacks are consistent with findings in other works done among other races. Type III olfactory fossa type predominates in the study population. This type of olfactory fossa is regarded as the dangerous type since the roof of the ethmoid is low-lying. Anatomical variations of the ethmoids described in other studies are present in the study population and the prevalence of these variations is consistent with some published works.

### Conflict of Interest

The authors report no conflicts of interest.

### REFERENCES

- Badia L, Lund VJ, Wei W, Ho WK (2005). Ethnic variation in sinonasal anatomy on CT-scanning. *Rhinology* 43:210-4.
- Bolger WE, Butzin CA, Parsons DS (1991). Paranasal sinus bony anatomic variations and mucosal abnormalities: CT analysis for endoscopic sinus surgery. *Laryngoscope* 101:56-64.
- Calhoun K, Waggenspack G, Simpson C, Hokanson J, Bailey B (1991). CT evaluation of the paranasal sinuses in symptomatic and asymptomatic populations. *Otolaryngology* 104:480.
- Earwaker J (1993). Anatomic variants in sinonasal CT. *Radiographics* : a review publication of the Radiological Society of North America, Inc, 13:381-415.
- Jones TM, Almahdi JM, Bhalla RK, Lewis-Jones H, Swift AC (2002). The radiological anatomy of the anterior skull base. *Clin. Otolaryngol. Allied Sci.* 27:101-5.
- Kantarci M, Karasen RM, Alper F, Onbas O, Okur A, Karaman A (2004). Remarkable anatomic variations in paranasal sinus region and their clinical importance. *Eur. J. Radiol.* 50:296-302.
- Keros P (1962). On the practical value of differences in the level of the lamina cribrosa of the ethmoid. *Z Laryngol. Rhinol. Otolaryngol.* 41, 809.
- Lloyd GAS (1990). CT of the paranasal sinuses: study of a control series in relation to endoscopic sinus surgery. *J. Laryngol. Otol.* 104, 477-481.

- Mazza D, Bontempi E, Guerrisi A, Del Monte S, Cipolla G, Perrone A, Lo Mele L, Marini M (2007). Paranasal sinuses anatomic variants: 64-slice CT evaluation. *Minerva Stomatol.* 56:311-8.
- Meloni F, Mini R, Rovasio S, Stomeo F, Teatini GP (1992). Anatomic variations of surgical importance in ethmoid labyrinth and sphenoid sinus. A study of radiological anatomy. *Surg. Radiol. Anat.* 14:65-70.
- Nitinavakarn B, Thanaviratnanich S, Sangsilp N (2005). Anatomical variations of the lateral nasal wall and paranasal sinuses: A CT study for endoscopic sinus surgery (ESS) in Thai patients. *J. Med. Assoc. Thai* 88:763-8.
- Nogueira JF, Stamm AC, Lyra M, Balieiro FO, Leão FS (2008). Building a real endoscopic sinus and skull-base surgery simulator. *Otolaryngol. Head Neck Surg.* 139:727-8.
- Nonaka M, Fukumoto A, Nonaka R, Ozu C, Baba S (2007). A case of a mucocele in an Onodi cell. *J. Nippon Med. Sch.* 74:325-8.
- Ogata Y, Okinaka Y, Takahashi M (1998). Isolated mucocele in an Onodi cell. *ORL J. Otorhinolaryngol. Relat. Spec* 60:349-52.
- Oliverio PJ, Benson ML, Zinreich SJ (1995). Update on imaging for functional endoscopic sinus surgery. *Otolaryngol. Clin. N. Am.* 28:585.
- Paber JELB, Cabato MSD, Villarta RL, Hernandez JG (2009). Radiographic Analysis of the Ethmoid Roof based on KEROS Classification among Filipinos. *Philippine J. Otolaryngol. Head Neck Surg.* 23:15-19.
- Perez P, Sabate J, Carmona A, Catalina-Herrera CJ, Jimenez-Castellanos J (2000). Anatomical variations in the human paranasal sinus region studied by CT. *J. Anat.* 197 ( Pt 2), 221-7.
- Polavaram R, Devaiah AK, Sakai O, Shapshay SM (2004). Anatomic variants and pearls--functional endoscopic sinus surgery. *Otolaryngol. Clin. North Am.* 37:221-42.
- Sazgar AA, Massah J, Sadeghi M, Bagheri A, Rasool E (2008). The incidence of concha bullosa and the correlation with nasal septal deviation. *B-ENT* 4:87.
- Stallman JS, Lobo JN, Som PM (2004). The incidence of concha bullosa and its relationship to nasal septal deviation and paranasal sinus disease. *Am. J. Neuroradiol.* 25:1613.
- Stammberger HR, Kennedy DW (1995). Paranasal sinuses:anatomic terminology and nomenclature. The Anatomic Terminology Group. *Ann. Otolaryngol. Rhinol. Laryngol. Suppl.* 167:7-16.
- Subramanian S, Lekhraj RGR, Wong E, Mastura S, Razi A (2005). Concha bullosa in chronic sinusitis. *Med. J. Malaysia* 60:535
- Sukalaya LM, Vachiranubhap B (2005). Prevalence of anatomic variation demonstrated on screening sinus computed tomography and clinical correlation. *J. Med. Assoc. Thai* 88:S110-5.
- Talaiepour A, Sazgar A, Bagheri A (2005). Anatomic Variations of the Paranasal Sinuses on CT scan Images. *J. Dent. Tehran Univ. Med. Sci.* 2:142-146.
- Terrier G, Stell PM (1991). Rhinosinusal endoscopy: diagnosis and surgery, Zambon Group.
- Tonai A, Baba S (1996). Anatomic variations of the bone in sinonasal CT. *Acta Otolaryngol. Suppl (Stockh)* 525:9-13.
- Yeoh KH, Tan KK (1994). The optic nerve in the posterior ethmoid in Asians. *Acta Otolaryngol.* 114:329-36.
- Zinreich S, Kennedy D, Rosenbaum A, Gayler B, Kumar A, Stammberger H (1987). Paranasal sinuses: CT imaging requirements for endoscopic surgery. *Radiology* 163:769.