

Case Report

Rhabdomyosarcoma followed six episodes of squamous cell carcinoma in a Nigerian albino: A case report

Wilson I. B. Onuigbo^{1*}, James C. Nwozo² and Richard E. Nnabuko²

¹Department of Pathology, National Orthopaedic Hospital, Enugu, Enugu State, Nigeria.

²Plastic Surgery, National Orthopaedic Hospital, Enugu, Enugu State, Nigeria.

Received 13 December, 2013; Accepted 8 October, 2014

Beginning from 1975, a Nigerian albino aged 27 years developed squamous cell carcinoma that recurred a total of seven times, the last being a rhabdomyosarcoma in 2005 at the age of 61 years. In this context, we are aware of published cases of carcinoma but not of sarcoma. With special reference to albinism, squamous cell carcinomas superabound. If at all, resections are scarcely carried out more than once.

Key words: Rhabdomyosarcoma, squamous cell carcinoma, albino, Nigeria.

INTRODUCTION

Albinos, who are distinguished by their lack of skin pigmentation stand out among the dark-skinned individuals. They also differ on account of cancer caused by exposure to sunlight. Health education is therefore geared towards cancer prevention. This is receiving the opposite major attention (Hong et al., 2006; Opara and Jiburum, 2010; Lund and Graigher, 2002).

However, another point of interest is the histological differentiation of the resultant growths themselves. Hitherto, squamous cell carcinoma had been mostly in focus. Thus, a histological review of 86 albino biopsy specimens in Tanzania showed squamous cell carcinoma to be more common than basal cell carcinoma (Kiprono et al., 2014).

Surgical treatment is in vogue. It may require to be carried out more than once. Asuquo et al. (2009) reported

tumors being excised with a recurrence in a man who also had adjuvant therapy with poor response. In a Malawian case, the "treatment dilemma" was owing to "multiple surgical excisions for squamous cell carcinomatous lesions" (Mapurisa and Masamba, 2010). Therefore, this study present a patient in whom six excisions of this particular carcinoma was followed by a sarcoma.

MATERIALS AND METHODS

This series consists of cases of albinos whose specimens were studied in a Regional Orthopaedic and Plastic Surgery Center between 1974 and 2014. Only one individual met the rare qualification of having had multiple biopsies of the rather common squamous cell carcinoma while the seventh surgery was for sarcoma

*Corresponding author. E-mail: wilson.onuigbo@gmail.com. Tel: +234-8037208680.

Author(s) agree that this article remain permanently open access under the terms of the [Creative Commons Attribution License 4.0 International License](http://creativecommons.org/licenses/by/4.0/)

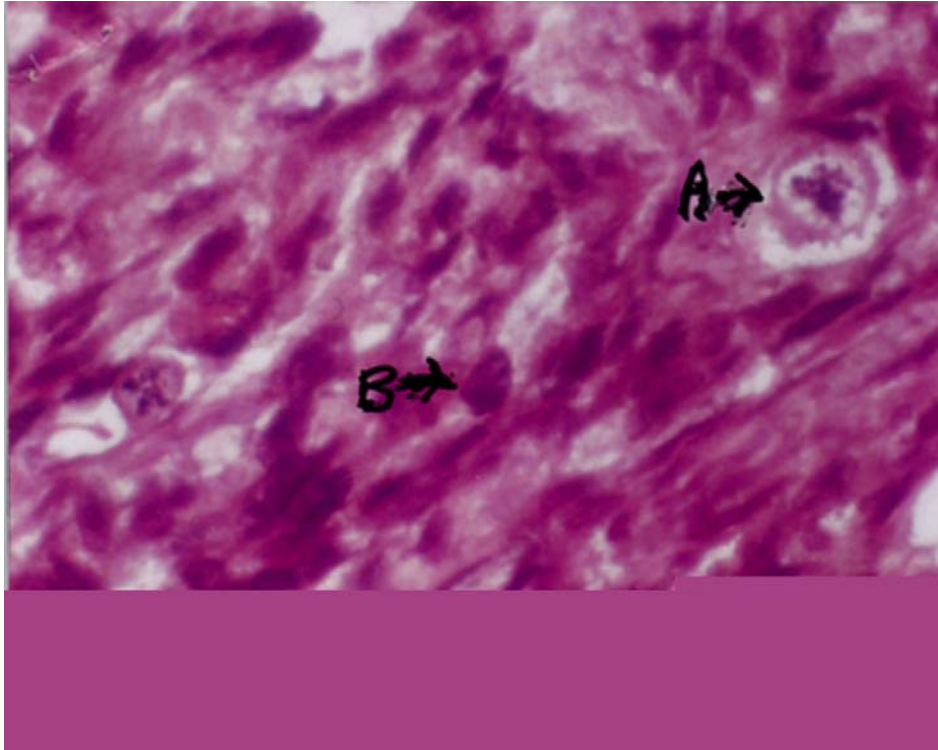


Figure 1. The lesion showed mitotically active, strap-like pleomorphic cells indicative of sarcomatous change of the rhabdomyosarcoma type.

A=> points to odd mitotic figure; **B=>** points to plump pleomorphic variably elongated cells.

CASE PRESENTATION

An albino was presented to the Regional Orthopaedic and Plastic Surgery Center in October, 1975, at the age of 27 years. His face, chest and neck were involved. All histopathologic sections were diagnosed by Wilson I. B. Onuigbo as squamous cell carcinoma. Over the years, the other presentations of this particular carcinoma were as follows: November, 1976 (lower lip); May, 1981 (forehead and neck); April, 1983 (neck); March, 1995 (cheek); and October, 1995 (periauricular region).

The last appearance was in March, 2010, when he presented to the other surgeon (Richard E. Nnabuko) at 61 years of age. This time, the forearm was the part involved. This lesion was biopsied.

GROSS AND MICROSCOPIC FINDINGS

At the histopathology laboratory, the tissue which was preserved in 10% formolsaline consisted of a 3 × 2 cm albino skin ellipse with a shallow ulcer centrally. Histology showed, deep to the ordinarily inflamed ulcer, a very pleomorphic growth with numerous tumor giant cells as well as occasional cross striations (Figure 1). The resection margin was free of tumor cells. A diagnosis of rhabdomyosarcoma was made.

DISCUSSION

The albino is known to suffer frequently from sun-induced squamous cell carcinoma (MacSween and Whaley, 1992). a rare case in which squamous cell carcinoma occurred in one facial focus with both basal cell carcinoma and adenocystic carcinoma have been published previously (Onuigbo and Nnabuko, 2009). Here, a peculiar case with multiple carcinomas which began with recurrences and then ended as a sarcoma have been reported. We are not aware of such an outcome being reported in the literature.

Interest in the development of skin cancer in albinos in Nigeria was kindled by a dermatologist who undertook the survey of the whole country (Okoro, 1975). Recent reports have appeared from this country, namely, Yakubu and Mabogunje (1993), Opara and Jiburum (2010), and Asuquo et al. (2010).

There is a common problem in cancer cases in developing countries. Patients are often lost to follow-up, e.g., the Tanzanian report by Mabula et al. (2012) and Nigerian by Opara and Jiburum (2010). Hence, our patient exhibited perseverance of a notable order. The present paper has added a rarity, namely, rhabdomyosarcoma of the pleomorphic type. Incidentally, the rarity of rhabdomyosarcoma itself is shown by the case published recently (Manasseh et al., 2009). Our case

featured a sarcoma that has followed a series of carcinomas.

Therefore, what of the concurred carcinoma and sarcoma? Aptly, named as carcinosarcoma, the combinations are worthy of citations. Actually, internet search revealed other examples, namely, congenital case (Ahmed et al., 1999), uterine corpus (Garrett et al., 2012), sinonasal involvement (Erkul et al., 2012), childhood (Roma et al., 2012), and cell death pathways as therapeutic targets (Fulda, 2012).

Conclusion

Sunlight is accepted as the preventable cause of cancer in albinos. Usually, concerning the squamous cell carcinoma type, a rare case has been presented in which 6 recurrences of this type from age 27 to 61 years culminated in the *de novo* development of rhabdomyosarcoma. This characteristic presentation is noteworthy since it followed on healed carcinomas rather than concurred with any of them. This case illustrates the use of Macartney et al. (1980) article concerning the employment of histopathology data pool in epidemiological analysis in the UK. Conclusively, the Nigerian case is worthy of publication in an international journal.

Conflict of Interests

The author(s) have not declared any conflict of interests.

REFERENCES

- Ahmed OA, Hussain A, King DJ, Holmes JD (1999). Congenital rhabdomyosarcoma. *Br. J. PlastSurg.* 52:304-307.
- Asuquo ME, Ngim O, Ebughe G, Bassey EE (2009). Skin cancers amongst four Nigerian albinos. *Int. J. Dermatol.* 48:636-638.
- Asuquo ME, Otei OO, Omotoso J, Bassey EE (2010). Skin cancer in albinos at the University of Calabar Teaching Hospital, Calabar. *Dermatol. Online J.* 16:14.
- Erkul E, Pinar D, Yilmaz I, Hakan C, Engin C, Murat S (2012). Rare adult sinonasalembryonalrhabdomyosarcoma with optic involvement. *Otolaryngology* 2:3.
- Fulda S (2012). Cell death pathways as therapeutic targets in rhabdomyosarcoma. *Sarcoma Article ID 326210*:5.
- Garrett LA, Harmon DC, Schorge JO (2012). Embryonal rhabdomyosarcoma of the uterine corpus. *J. Clin. Oncol.* 31:e41-e50.
- MacSween RNM, Whaley K (1992). *Muir's Textbook of Pathology*, 3th Ed. London: Arnold. P 271.
- Manasseh AN, Echejoh GO, Silas OA, Tanko MN, Jegede SK, Mandong BM (2009). Testicular embryonal rhabdomyosarcoma: A case report. *Int. J. Med. Med. Sci.* 1(11):470-472.
- Okoro AN (1975). Albinism in Nigeria. A clinical and social study. *Br. J. Dermatol.* 92:485-492.
- Onuigbo WIB, Nnabuko RE (2009). Three different carcinomas clustered in one facial focus in albino. *Niger. J. Surg. Sci.* 19:38-40.
- Roma J, Almazan-Moga A, de Toledo JS, Gallego S (2012). Notch, Wnt, and Hedgehog pathways in rhabdomyosarcoma: from single pathways to an integrated network. *Sarcoma Article ID 695603*:7.
- Yakubu A, Mabogunje OA (1993). Skin cancer in African albinos. *Acta Oncol.* 32:621-622.