

Full Length Research Paper

Computerized nuchal translucency three dimensional reconstruction, visualization and measurement for trisomy 21 prenatal early assessment

Lai Khin Wee^{1,2*}, Hum Yan Chai² and Eko Supriyanto²

¹Biomedical Engineering Department, Faculty of Computer Science and Automation, Institute of Biomedical Engineering and Informatics, Technische Universität Ilmenau, 98684, Ilmenau, Thuringia, Germany.

²Department of Clinical Science and Engineering, Faculty of Health Science and Biomedical Engineering, Universiti Teknologi Malaysia, 81310 Skudai, Johor, Malaysia.

Accepted 13 July, 2011

Conventionally, measurement of ultrasonic marker, nuchal translucency or NT is accomplished by manual assessment in two dimensional ultrasound images for trisomy 21 early detection. Nonetheless, the efficiency of 2D measurement depends heavily on the image position and any deviation will prompt inaccurate measurement. Therefore, in this paper we proposed the reconstruction, visualization and measurement of nuchal translucency using three dimensional approaches for real time computation. Open-source visualization toolkit VTK was implemented for 3D interactive graphics supports. The methodology entails the virtual slider cutting plane to explicit the internal structure of ultrasound marker. It is concluded in our findings that 3D measurements of nuchal translucency provide higher accuracy and consistency of thickness measurement.

Key words: Ultrasound, three dimensional, nuchal translucency, rendering, VTK, visualization, reconstruction, trisomy.

INTRODUCTION

With continuous improvement of ultrasound equipment and innovative technology in current research and development, real-time three-dimensional (3D) ultrasound technology has been widely used in clinical research and diagnosis, particularly in prenatal care aspects. In late 1980's, 3D ultrasound imaging becomes reality due to the rapid development of computing technology in terms of both hardware and software. There are three different 3D ultrasound imaging formation, which includes surface rendering, transparent volumetric rendering and multi-planar imaging. Nevertheless, the formations of these 3D ultrasound imaging are still heavily influenced by quality of the 2D image. Besides, the visualization techniques of 3D ultrasound imaging also include static 3D ultrasound, dynamic 3D Ultrasound and real-time 3D ultrasound. Static 3D ultrasound

is the formation with spatial resolution based on multiple 2D image slices. Dynamic 3D ultrasound is the static 3D ultrasound intersection with time resolution. Real-time 3D ultrasound visualization can be achieved through a series of techniques. The common existing method is applying mechanical rotation of 2D transducer planar array, where the ultrasonic probe remained static and accesses the 3D volume data of subject interest directly. Nevertheless, the practical engineering of 2D planar array involves large number of array elements, each array element requires configuration to appropriate channels. Therefore, various issues remained unsolved in terms of technical complexity and the tradeoff of system cost. 3D ultrasound technologies have been developed rapidly and gradually entering the clinical utility stage over the last decades. In early clinical studies, it focuses more on obstetrics and gynecology diseases; this is due to the unique anatomical and physiological characteristics in gynecological pathology. In present study, we have proposed a 3D ultrasound reconstruction and visualization

*Corresponding author. E-mail: khin-wee.lai@tu-ilmenau.de.

for a specific ultrasound marker, namely nuchal translucency or NT, which is the important measurement parameter to assess the risk of trisomy 21 in early pregnancy. Measurements of NT were conducted in 3D spaces through the proposed state-of-art computerized algorithms. The proposed method has encountered the difficulty of current manual assessment method on using conventional B mode ultrasonic images. 3D visualization and measurement of ultrasound marker NT will improve the findings accuracy and consistency. The paper is organized as follows. Study of trisomy 21 and the specific ultrasound marker implemented in current studies were reviewed. Then we describe the proposed open-source visualization toolkit, VTK and its implementation on 3D ultrasound marker reconstruction and visualization. Followed by the performance of developed algorithms in 3D volumetric modeling and NT measurement. Finally, we summarize with the conclusions of the study.

Background

Trisomy 21, also known as Down's syndrome, is a congenital defect caused by an extra copy of chromosome 21 as compare to normal pair of chromosome. It was firstly reported (Down, 1866) and it is name after him as Down syndrome. The main characteristics of this syndrome are severe mental retardation, with a unique facial and body deformities (Wee and Supriyanto, 2010; Supriyanto et al., 2010; Wee et al., 2010a, 2010b). In actual life, patient with trisomy 21 requires life-long care and supports from their families, which will definitely cause heavy burden in both mental and economic wise.

The cause of trisomy 21 with an extra copy of chromosome is still unknown, but early researches have proved that it is highly associated with the ages of pregnant women. Unfortunately, there are no effective prevention and treatment measures for this disease until now. In recent years, ultrasound screening in first trimester of pregnancy provides the most effective way of chromosomal abnormalities screening. The application of ultrasound imaging to detect fetal abnormalities in early pregnancy has aroused great attention of genetic workers. Previous researches show that assessment of particular ultrasound markers offer promising non-invasive method for fetal abnormalities detection, such as nuchal translucency, nasal bone, long bone biometry, maxillary length, cardiac echogenic focus and ductus venous (Nicolaidis et al., 1999) (Figure 1). So far, measurement of NT thickness in the first trimester of pregnancy has been screening for trisomy 21, 18 and 13(Snijders et al., 1998). However, the drawback of current ultrasound manual measurement technique

is restricted with inter and intra-observer variability and inconsistency of results (Chai et al., 2011a, 2011b, 2011c; Abuhamad, 2006; Pandya et al., 1995). Therefore, the proposed methods are aimed to encounter all the restriction earlier mention. The term nuchal translucency was coined by Nicolaides and colleagues to describe the collection of fluid that is normally present behind the neck of the first trimester fetus. The stagnant fluids are obviously seen during 10 to 14 weeks gestation age, and then it will gradually decrease after 20 weeks and while making it difficult to detect the presence of key fold thickness. Fold thickness is a vital key marker to assess trisomy 21 of early pregnancy. 5 MHz or 3.5 MHz abdominal ultrasound probe was used to scan the abdomen of pregnant women, where distance between fetal neck and the membrane cervical spine soft tissue in sagittal plane were measured as NT thickness. It should be essentially careful not to confuse the amniotic membrane as the layer of NT. According to fetal medicine foundation (FMF), NT measures considered abnormal were 3 mm and above and with 64% sensitivity for trisomy 21 (Nicolaidis, 1992).

Based on the past research in Harris Birthright research centre for fetal medicine (Snijders et al., 1998), have coordinated the largest study to assess NT accuracy. It was conducted at 22 ultrasound centres in England on 96,127 women who were 10 weeks to 14 weeks pregnant. The risk for trisomy 21 was calculated by multiplying the NT probability ratio by the prevalence of this trisomy at different maternal and gestational ages. The test was positive for 5% of the population which included 77% of the trisomy 21 cases (Kagan et al., 2009). It has been proved that NT is the most powerful marker for trisomy 21 screening (Snijders, 1998). The importance of measuring NT as a screening tool can be evaluated from the fact that all over Europe, America and UK, NT measurement is included in their prenatal screening programs.

According to national institute of health and clinical excellence (NICE) guideline the combined test, (NT, beta human chorionic gonadotropins and pregnancy associated plasma protein-A) should be offered to screen Down syndrome between 11 weeks and 13 weeks + 6 days to all pregnant women (NICE, 2008). Besides, Cicero et al. (2003a, b) published the first large prospective trial of nasal bone assessment in a high risk population undergoing CVS to assess for trisomy 21. They deter-mined that absence of nasal bone during first trimester was associated with Down syndrome. Because of high likelihood ratio for Down syndrome with an absent nasal bone and similarly low negative likelihood ratio when nasal bone is present, the authors estimated that assessment of nasal bone would significantly improve the performance of first trimester ultrasonography for Down

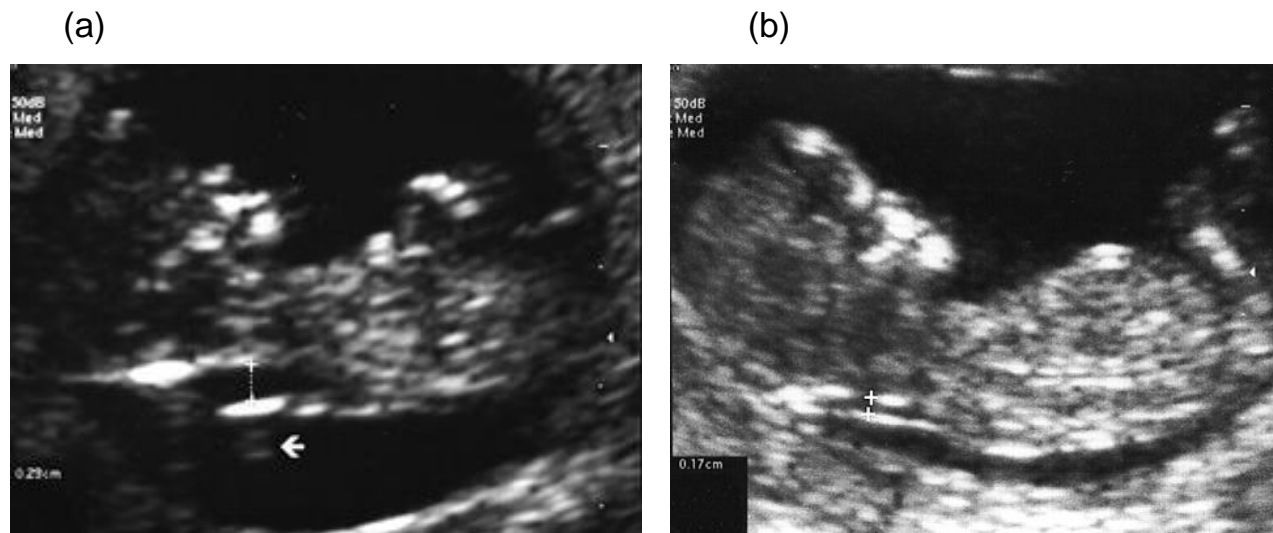


Figure 1. Comparison of NT measurements with normal and abnormal fetal: (a) abnormal fetal 2.9 mm (b) normal fetal 1.7 mm.

syndrome (Rosen et al., 2005). Also, Kagan et al. (2009) have proved that assessment of fetal nasal bone improves the performance of first trimester screening for trisomy 21. Has et al. (2008) had reported that the absence of fetal nasal bone has a high positive likelihood ratio for Down syndrome in the first trimester screening, and the presence of nasal bone may potentially lower the need for invasive testing. Orlandi et al. (2003) concluded that absence of the nasal bone can be used as a marker for abnormalities screening and they have demonstrated inclusion of nasal bone in current screening protocol along with nuchal translucency, free beta-hCG and PAPP-A, can achieve high detection at a very low false-positive rate (Larose et al., 2003). In most studies that assess nasal bone at 11 to 13 weeks plus 6 days of gestation findings from trisomy postnatal were confirmed; the nasal bone was not visualized in 60 to 80% of cases (Cicero et al., 2001; Otano et al., 2002; Zoppi et al., 2003; Malone et al., 2004). From the medical researches earlier mention, it is known that trisomy 21 characteristic can be extracted from fetal ultrasound image with measuring of nuchal translucency and nasal bone. However, manual ultrasound measurement indicated that assessment may have been hampered either by poor magnification, unfavorable section, unfavorable scanned plane, or by untrained operator. Reproducibility studies suggest that reproducibility of measurement is variable among groups and poor in some studies (Kanellopoulos et al., 2003; Bekker et al., 2004). It is possible that learning curve for this measurement is much longer for NT measurement (Cicero et al., 2003a, b).

METHODOLOGY

In this study, we have proposed the development of 3D

manipulation algorithms using VTK visualization toolkit. VTK is an open source, free computer graphics, image processing and visualization toolkit. It has excellent structure and operating mechanism, causing it to be widely used in the international visualization research area. The development kit supports multiple programming languages such as Tcl, Tk, Java and C++. The existing class libraries are organized in a hierarchical structure, which is similar to the Microsoft MFC. In recent years, VTK has become a popular research tool in the field of three dimensional image reconstruction and visualization. The open-sources C++ classes are developed based on OpenGL features, which provide rapid and efficient three dimensional graphics supports. In term of codes execution efficiency, it is able to run on multiple platforms with different language environment supports.

In our investigation, the developed algorithm can achieve a variety of interactive visualization and measurement simulation by modifying part of VTK class, and adjusting the appropriate means of implementation and execution of code embedded in personalized coding. Since the implementation of VTK class library having high flexibility and efficiency in real time interactive simulation, we decided to use C++ programming language for the proposed 3D ultrasound marker investigation.

VTK Widget event handling mechanism

VTK Widget can be defined as the geometry and behavior control of the displayed object information. It allows the direct interaction of programmer with the data in three-dimensional data field manipulation. The widget control is depending on the mouse click and move triggered. It will receive the activated control of interactive events and generate appropriate behaviors according to the sign given by the users. The VTK widget features are separated into two parts, one part inherited from *vtkAbstractWidget* class for event handling, and the other part inherited from *vtkWidgetRepresentation* class for geometry description, as shown in Figure 2. It can be observed that *vtkWidgetRepresentation* is subclass of *vtkProp*, and it combines with *vtkAbstractWidget* subclass to produce a 3D widget.

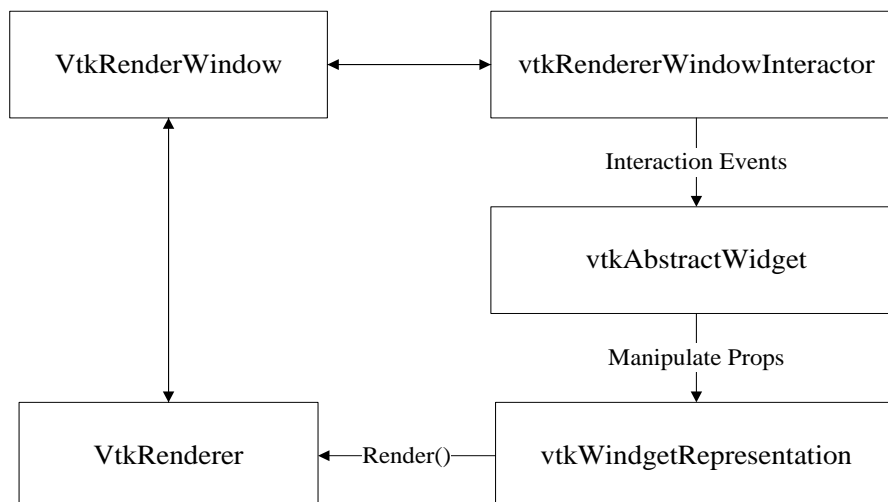


Figure 2. VTK Widget event handling description.

Three dimensional reconstructions

In general, there are two main principles of three-dimensional ultrasound reconstruction and visualization, which are surface rendering and volume rendering. Our previous work published (Wee et al., 2011) described the details of data extraction for ultrasound contour surface rendering using simplified marching cubes method. The main pipeline VTK design mechanism for volume rendering is very similar to surface rendering, but it is using the basic unit of volume data and data manipulated by ray casting techniques. The difference of volume rendering in present studies is to express the object's internal information, in our case, we will simulate the 3D nuchal translucency in real-time computation. It is followed by the NT thickness measurement using Euclidean distance equation in 3D formation. In the proposed study, multi frames of DICOM ultrasound data were collected for 3D volume reconstructions. The collected DICOM files are stored in 8 bit, and digital unsigned characteristic with the grey scale values between 0 and 255. The total numbers of frames stored are 150 frames with spacing value at 3.57 pixels. The scanned subject in the present studies is ultrasound marker called nuchal translucency or NT, with the resolution 963 × 768 pixels using trans-abdominal 3.5 MHz ultrasound transducer with freeze capability. Figure 3 shows the proposed algorithm flows of the case data to form a three dimensional scalar topology rendering. The *vtkImageCase* class from VTK is used to receive case data, and retrieved its *SetDimensions* function is to set the dimension of the data, *SetSpacing* function set the pixel spacing (pixels interval must be in strict accordance with the pixel interval of the original data set, otherwise it will results visual imbalance). The output of *vtkImageCase* will access *vtkRayCasting*, and forming 3D volumetric rendering. In order to show the internal structure of nuchal translucency explicitly, we have proposed a three dimensional virtual slider cutting plane, using implementation of *vtkPlaneWidget*, as shown in Figure 3. *vtkPlaneWidget* will be implemented as a grid plane with an arrow direction, which indicates the current position of three dimensional grid planes. The movement of virtual slider can be controlled through the interaction of mouse click and movement triggered. To perform this, the algorithms need an extra *AddObserver* on *vtkPlaneWidget* class, which specifies the interception event such as *vtkCommand::InteractionEvent*. Whenever the position of the virtual slider was changed, the location information need to be updated, and

activating the changing of the rendering view. This interactive simulation requires a *Callback* command to response the mouse call event. The parent class of this *Callback* command is *vtkCommand*; it will obtain the latest location information by adding its member function *vtkPlane*, which acts as a pointer to record the *vtkPlaneWidget* location.

Realization of three-dimensional nuchal translucency measurement

VTK rendering scene can be divided into two models, operator 3D widget model and renderer data model. In order to update the control information of operator 3D widget model on renderer data model, *Callback* command is required to activate the response accordingly. The *AddObserver* acts as an external module to observe and reflect the real time data model status. In present studies, computing three dimensional measurement of nuchal translucency is accomplished through *vtkPicker* widget. *Observer* will converts the *vtkPicker* data into geometrical and physical parameters in the rendering scene. Once *vtkPicker* updated its parameters, *Observer* will updates the data simultaneously through the interface connection established. Figure 4 shows the interactive algorithm connection for three dimensional measurement of nuchal translucency. The proposed system will send mouse and keyboard input messages to *vtkPicker* through command updating. For the three dimensional Euclidean distance computation, two worlds Cartesian coordinate are required. The point picker in computer screen is only two dimensional coordinates which has no direct relation with the three dimensional objects, and therefore, conversion into world coordinates is necessary. The distinct difference between two dimensional coordinates and world coordinates is that the latter contains depth information, which reflects the depth of Z-coordinate spaces. In current studies, the selected two dimensional coordinates will be introduced as a straight line extended into Z spacing, which might penetrate the three dimensional rendering objects followed by acquiring the coordinate intersection with the surface of rendering objects. Straight line may intersect with more than one plane; therefore, several interactions are possible. The algorithms then compare the distance of all the intersecting point with the initial point coordinates. The coordinates with the shortest distance calculated will be selected as the three dimensional world coordinates.

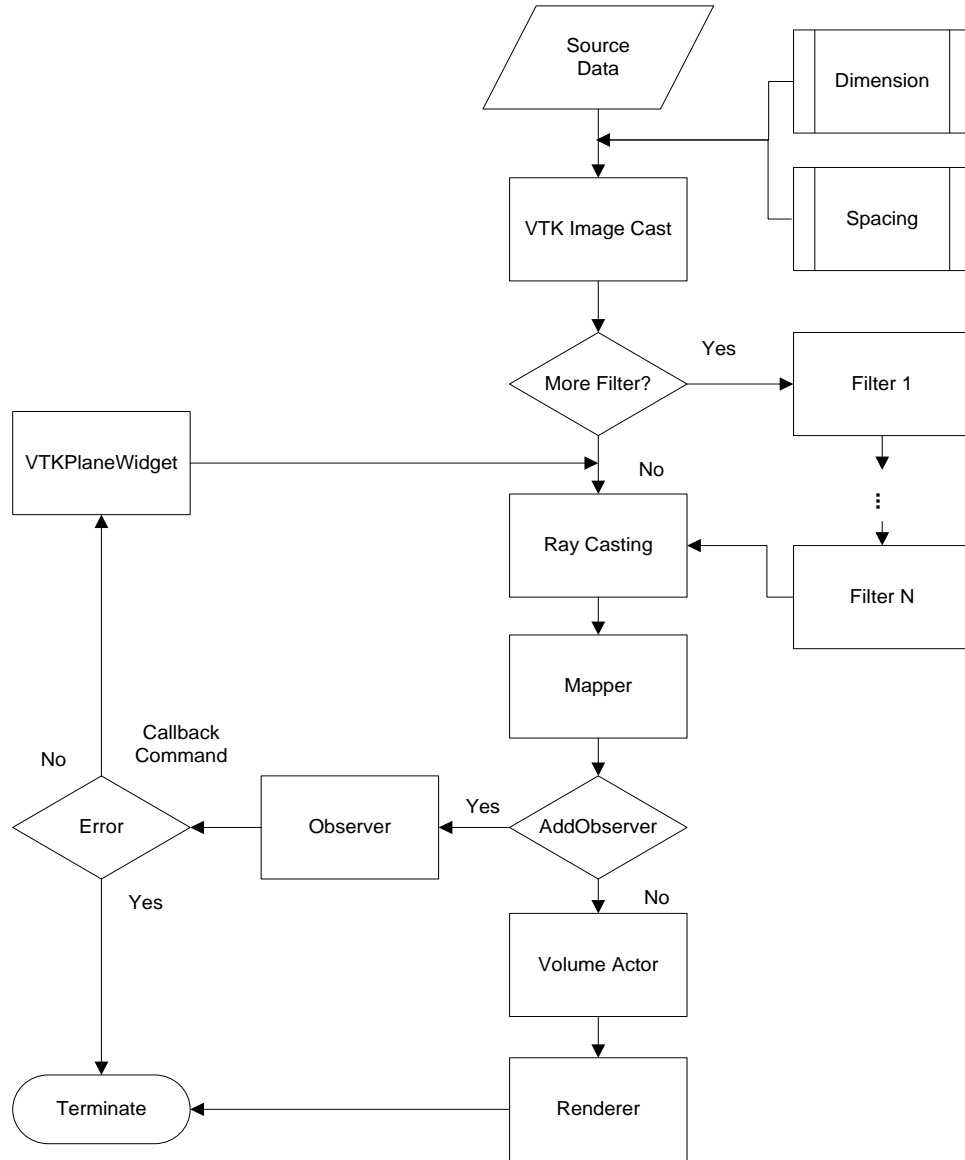


Figure 3. Process flow for proposed algorithms.

RESULTS

Figure 5 shows the original two dimensional ultrasound images which contain the interest region, nuchal translucency. Figure 6 shows part of the experimental simulation results in three dimensional volumetric rendering. The resultant 3D reconstruction can be visualized in any orientation, where the virtual slider position can be altered and updating the internal view structure of the ultrasound volumetric images. It can be observed that the proposed simulation having great advantage as compared to conventional two dimensional B-mode ultrasound images in terms of its visualization, measurement, accuracy, flexibility and consistency. To

examine the fold thickness of nuchal translucency, the user must drag the virtual slider to cover the region of maximum NT length, as shown in Figure 7. Figure 8 shows the finalized three dimensional distance measurement by applying Euclidean distance equation that follows:

$$\begin{aligned}
 E(p, q) &= \sqrt{(p_1 - q_1)^2 + (p_2 - q_2)^2 + \dots + (p_n - q_n)^2} \\
 &= E(q, p) = \sqrt{\sum_{i=1}^n (q_i - p_i)^2}
 \end{aligned}
 \tag{1}$$

E denotes Euclidean distance between point q and p with the vector line (\overline{qp}) . In our case, we have:

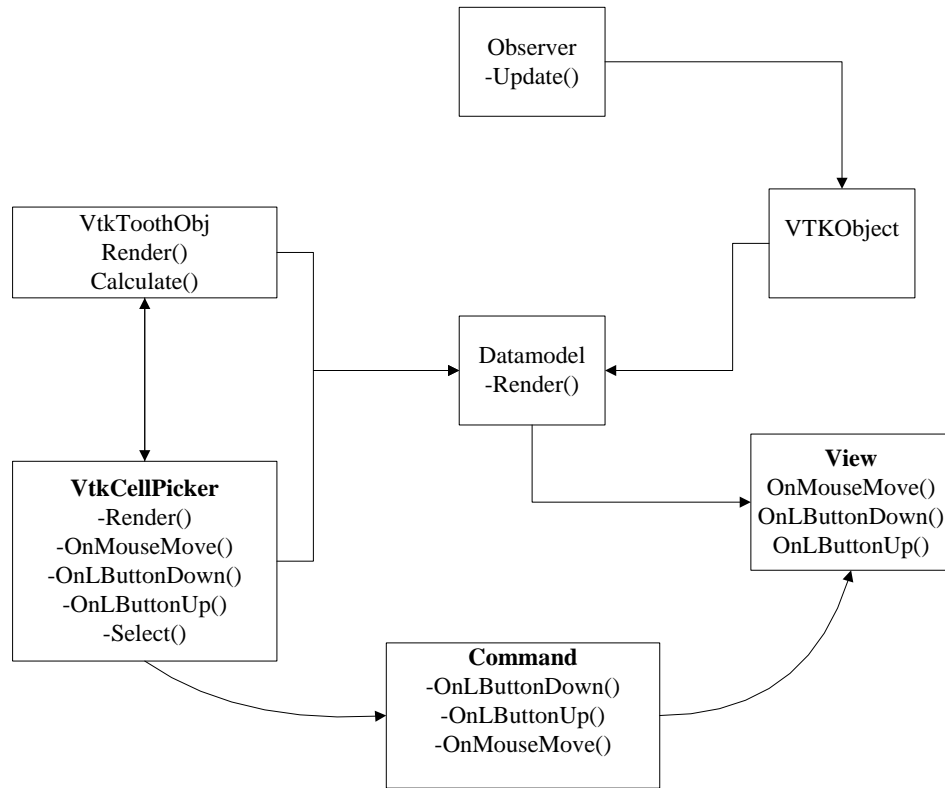


Figure 4. Algorithm connection between *vtkPicker* and renderer data model.

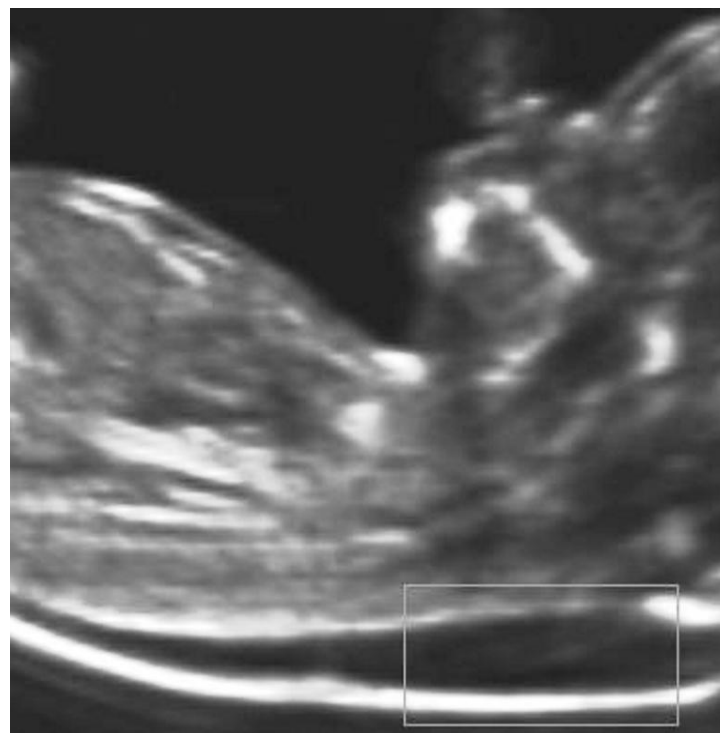

Figure 5. Two dimensional ultrasound images with ultrasound marker, nuchal translucency.

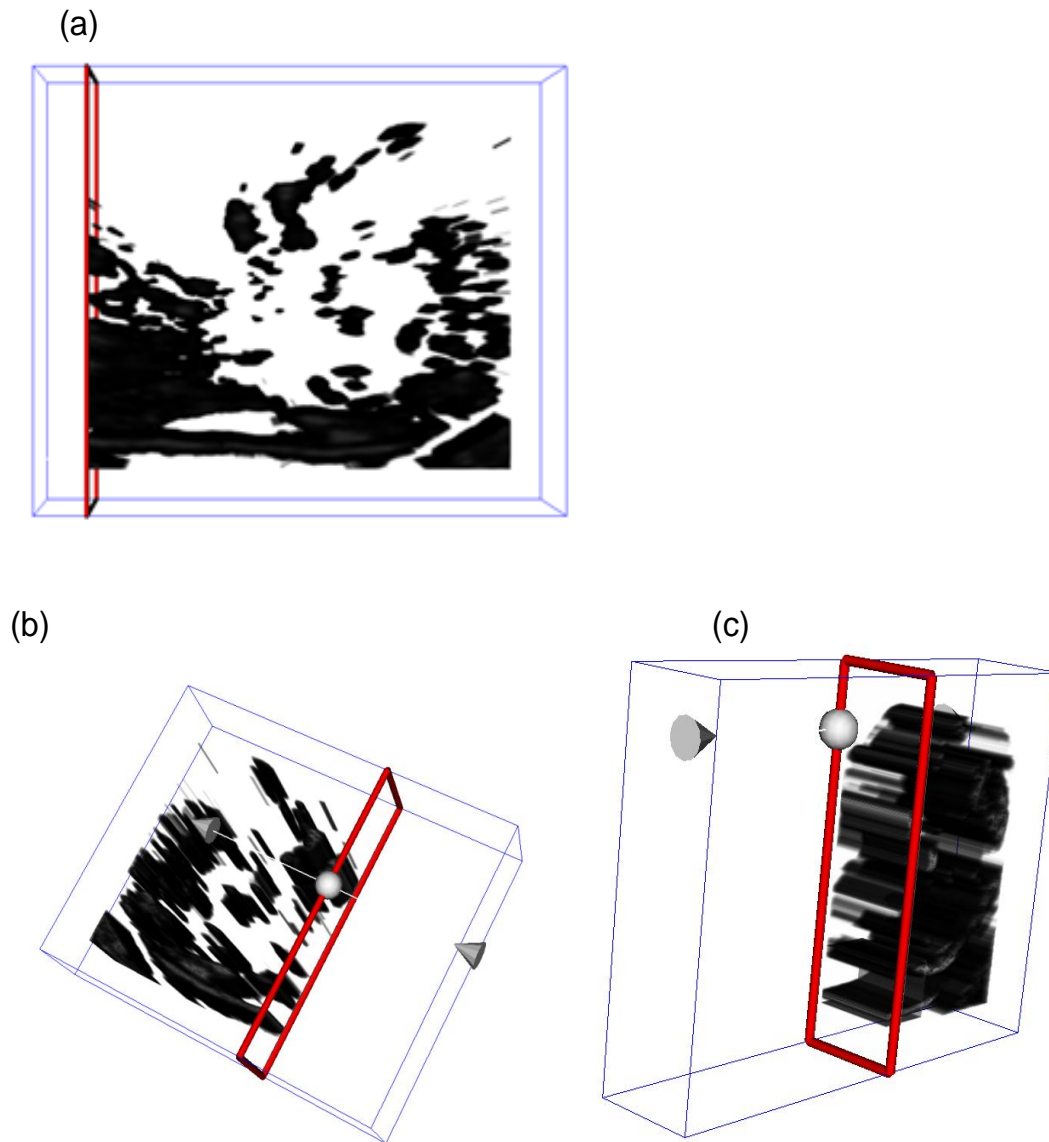


Figure 6. Experimental simulation of three dimensional ultrasound fetal images: (a) front view (b) left view (c) right view.

$$E(p, q) = \sqrt{(p_1 - q_1)^2 + (p_2 - q_2)^2 + (p_3 - q_3)^2} \quad (2)$$

Conclusion

We have proposed an interactive simulation of ultrasound marker visualization and its three dimensional expression of length measured for trisomy 21 assessment. We have implemented VTK widget class combining

Observer command to realize the virtual slider scene corresponding to users' mouse click and movement triggered. The findings show that the method is feasible.

ACKNOWLEDGEMENTS

The researchers are so indebted and would like to express our thankfulness to Professor Dr. -Ing. Habil. Haueisen and Dr. Rer. Nat. Uwe Graichen for their support, comments and guidance throughout the project.

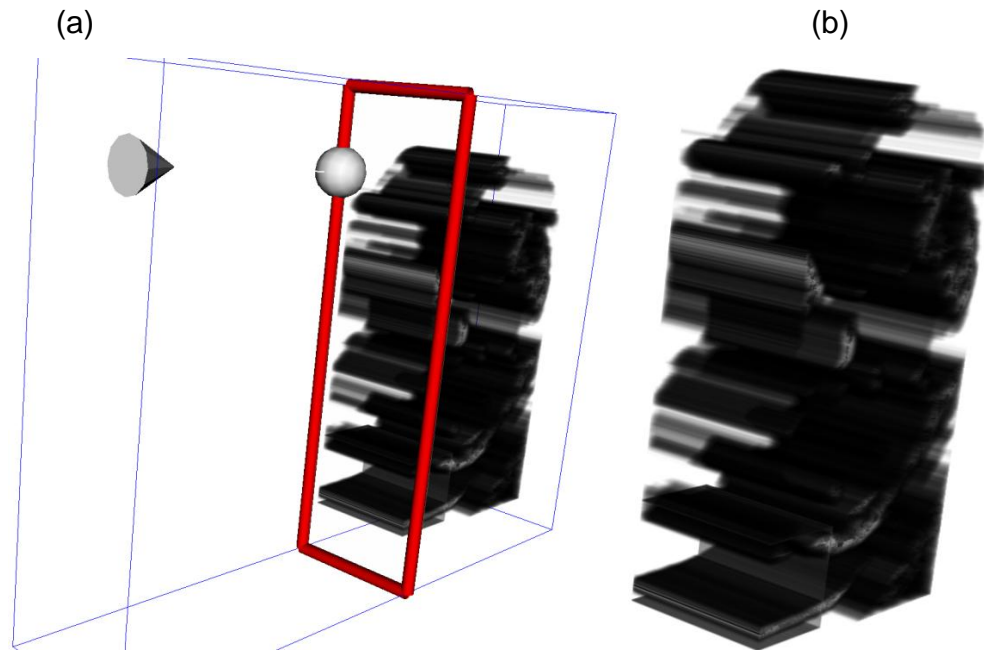


Figure 7. Explicit view of internal structure ultrasound marker: (a) changed position of virtual slider (b) zoom visualization for clear ultrasound marker viewing.

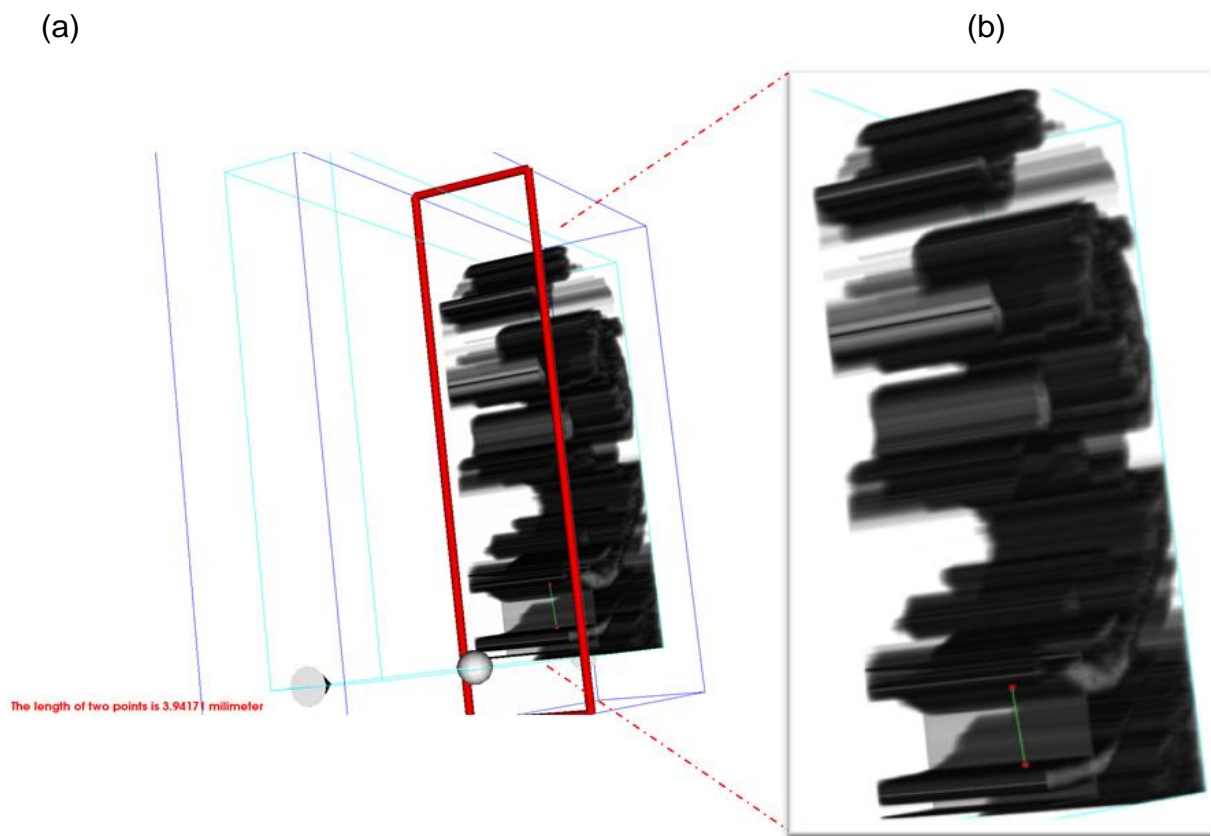


Figure 8. Three dimensional NT marker measurement: (a) length of NT was displayed at 3.9417 mm (b) two world coordinates conversion.

We would also like to thank DAAD - Deutscher Akademischer Austausch Dienst for financial support provided to student who conducts the project at TU-Ilmenau, Germany. Our appreciation also goes to all the members of BMTI, Technische Universität Ilmenau, Germany, for their ideas and support to the project.

REFERENCES

- Abuhamad A (2006). Technical aspects of nuchal translucency measurement. *Seminars in perinatol.*, 29: 376-379.
- Bekker MN, Twisk JW, Van Vgt JM (2004). Reproducibility of fetal nasal bone length measurement. *J. Ultrasound Med.*, 23(12): 1613-1618.
- Cicero S, Curcio P, Papageorgiou A, Sonek J, Nicolaides K (2001). Absence of nasal bone in fetuses with trisomy 21 at 11-14 weeks of gestational observational studies. *Lancet.*, 358: 1665-1667.
- Cicero S, Dezerega V, Andrade E, Scheier M, Nicolaides KH (2003a). Learning Curve for sonographic examination of fetal nasal bone at 11-14 weeks. *Ultrasound Obstet. Gynecol.*, 22(2): 135-137.
- Cicero S, Longo D, Rembouskos G, Sacchini C, Nicolaides KH (2003b). Absent nasal bone at 11-14 weeks of gestation and chromosomal defects. *Ultrasound Obstet Gynecol.*, 22: 31-35.
- Supriyanto E, Lai KW, Too YM (2010). Ultrasonic Marker Pattern Recognition and Measurement Using Artificial Neural Network. 9th WSEAS Int. Conference on Signal Process, pp. 35-40.
- Chai HY, Lai KW, Tan TS, Sh-Hussain SAK, Ariff K (2011a). Gray-Level Co-occurrence Matrix Bone Fracture Detection. *Am. J. Appl. Sci.*, 8(1): 26-32.
- Chai HY, Lai KW, Tan TS, Sheikh H (2011b). GLCM based Adaptive Crossed Reconstructed (ACR) k-mean Clustering Hand Bone Segmentation. 10th WSEAS Int. Conference on Signal Process. Robotics and Automation, pp. 192-197.
- Chai HY, Lai K, Wee, Tan TS, Sh-Hussain S (2011c). Adaptive Crossed Reconstructed (ACR) K-mean Clustering Segmentation for Computer aided Bone Age Assessment System. *Int. J. Math. Models Methods Appl. Sci.*, 5(3): 628-635.
- Kagan KO, Wright D, Nicolaides KH (2009). Fetal Nasal Bone in Screening for Trisomies 21, 18, 13 and Turner Syndrome at 11-13 Weeks of Gestation. *Ultrasound in Obstetrics and Gynecol.*, 33: 259-264.
- Kanellopoulos V, Katsetos C, Economides DL (2003). Examination of fetal nasal bone and repeatability of measurement in early pregnancy. *Ultrasound Obstet. Gynecol.*, 22: 131-134.
- Larose C, Massoc P, Hillion Y, Bernard JP, Ville Y (2003). Comparison of fetal nasal bone assessment by ultrasound at 11-14 weeks and by postmortem X-ray in trisomy 21: a prospective observational study. *Ultrasound in Obstetrics and Gynecology.* 22: 27-30.
- Malone FD, Ball RH, Nyberg DA, Comstock CH, Saade G, Berkowitz RL, Dugoff L, Craigo SD, Carr SR, Wolfe HM, Tripp T, D'Alton ME, FASTER Research Consortium (2004). First trimester nasal bone evaluation for aneuploidy in the general population. *Obstet. Gynecol.*, 104(6): 1222-1228.
- NICE (2008). Clinical Guideline 62, "Antenatal Care", Routine care for healthy pregnant women.
- Nicolaides (1992). Fetal nuchal translucency: ultrasound screening for chromosomal defects in first trimester of pregnancy. *Med J.*, 304: 867-869.
- Nicolaides K, Sebire N, Snijders R (1999). The 11-14 weeks scan: the diagnosis of fetal abnormalities. Parthenon Publishing, pp. 154-180.
- Orlandi F, Bilardo CM, Campogrande M, Krantz D, Hallahan T, Rossi C, Viora E (2003). Measurement of nasal bone length at 11-14 weeks of pregnancy and its potential role in Down syndrome risk assessment. *Ultrasound Obstet. Gynecol.*, 22(1): 36-39.
- Otaño L, Aiello H, Igarzábal L, Matayoshi T, Gadaw EC (2002). Association between first trimester absence of fetal nasal bone on ultrasound and Down syndrome. *Prenatal diagnosis*, 22: 930-932.
- Pandya, PA, Brizot D, Pettersen M, Nicolaides KH (1995). Repeatability of measurement of fetal nuchal translucency thickness. *Ultrasound on Obstetrics and Gynecol.*, 5: 335-337.
- Has R, Ibrahim K, Atil Y, Lemi I, Hayri E, Alkan Y (2008). Fetal Nasal Bone Assessment in First Trimester Down Syndrome Screening. *Fetal Diagn. Ther.* 24: 61-66.
- Snijders (1998). Assessment of risk of trisomy 21 by maternal age and fetal nuchal-translucency thickness at 10-14 weeks of gestation. *Lancet.*, 351: 343-346.
- Snijders RJ, Noble P, Sebire N, Souka A, Nicolaides KH (1998). UK multicenter project on assessment of risk of trisomy 21 by maternal age and fetal nuchal translucency thickness at 10-14 weeks of gestation. *Lancet.*, 352: 343-346.
- Rosen T, Mary E, Alton D (2005). Down syndrome screening in first and second trimester: What do the data show? *Semin. Perinatal.* 29: 367-375.
- Wee LK, Adeela A, Eko S (2010a). Computerized Automatic Nasal Bone Detection based on Ultrasound Fetal Images Using Cross Correlation Techniques. *WSEAS Trans. Inform. Sci. Appl.*, 7(8): 1068-1077.
- Wee LK, Chai HY, Supriyanto E (2011). Surface Rendering of Three Dimensional Ultrasound Images using VTK. *J. Sci. Indust. Res.*, 70(6): 421-426.
- Wee LK, Eko S (2010). Automatic Detection of Fetal Nasal Bone in 2 Dimensional Ultrasound Image Using Map Matching. 12th WSEAS Int. Conference on Automatic Control, Modeling Simulation, 305-309.
- Wee LK, Too YM, Adeela A, Eko S (2010b). Nuchal Translucency Marker Detection Based on Artificial Neural Network and Measurement via Bidirectional Iteration Forward Propagation. *WSEAS Trans. Inform. Sci. Appl.*, 7(8): 1025-1036.
- Zoppi MA, Ibba RM, Axiana C, Floris M, Manca F, Monni G (2003). Absence of fetal nasal bone and aneuploidies at first trimester nuchal translucency screening in unselected pregnancies. *Prenatal diagnosis*, 23: 496-500.