

Full Length Research Paper

A comparative morphometric analysis of the stomach in rat *Rattus norvegicus*, Bat *Eidolon helvum* and pangolin *Manis tricuspis*

***Ofusori D. A¹, Enaibe B.U², Falana B. A³, Adeeyo O. A⁴, Yusuf U. A⁴, and Ajayi S.A³**

¹ Department of Anatomy, School of Basic Medical Sciences, Igbinedion University, Okada, P.M.B 0006, Benin City, Edo State, Nigeria.

² Department of Human Anatomy, Faculty of Basic Medical Sciences, University of Ilorin, Ilorin, Nigeria.

³ Department of Anatomy and Cell Biology, Faculty of Basic Medical Sciences, Obafemi Awolowo University, Ile-Ife, Nigeria.

⁴ Department of Human Anatomy, Faculty of Basic Medical Sciences, Ladoké Akintola University of Technology, Ogbomosho, Oyo State, Nigeria.

Accepted 10 February, 2008

The difference in the feeding habits of these three mammals necessitated this study, (pangolin being insectivorous, bat frugivorous and rat omnivorous). This study compared the macro and micro-morphometric adaptations adopted by the stomach of the three mammals to cope with their feeding habits. The study was carried out using sixteen rats, sixteen bats and eight pangolin of both sexes randomly divided into two equal groups each that is, A and B. The animals were sacrificed by cervical dislocation and the stomachs were quickly excised following abdominal incision. Those in group A were subjected to macro-morphometric analysis while those in group B have their excised stomach fixed in 10% formol saline and following histological processes, where subjected to micro-morphometric analysis. The results revealed that the stomach of the three mammals have a great deal of correlation with their feeding pattern; with that of the pangolin being significantly different ($p < 0.05$) compared to the other two mammals due to their high chitinous diet. It is therefore concluded that the differences in the morphometric assessment is due to the different feeding pattern in the three mammals.

Key words: Feeding habit, morphometric, analysis, mammals, stomach, pangolin, bat, rat.

INTRODUCTION

The stomach is an organ used to digest and store food. Its primary function is not the absorption of nutrients from digested food; this task is usually performed by the intestine (Saladin and Kenneth, 2004). In animals, the main job of the stomach is to breakdown large molecules into smaller ones, so that they can be absorbed into the intestine more readily (sheewood, 2004). General sections of the mammalian gut are usually specialized to suit dietary requirement of particular species (Hildebrand and Goslow, 2001). The pangolins for instance, have no teeth unlike the bat and rat. The gizzard like stomach is therefore specially adapted for churning food (Ofusori et

al.,2007; Ofusori and Caxton-Martins, 2005). The process is helped along by small stones and sand which pangolins consume (Redford and Dorea, 1984) and (Nisa et al., 2005). Pangolin (Figure 1a) consumes a very specific insectivorous diet. They use their sense of smell to locate termite and ant nests. They dig the insects from mounds with their claws and use their extremely long tongues (up to 16 inches in larger pangolins) to eat them. In a resting position the tongue is pulled back into a sheath that retracts into the chest cavity. Large salivary glands coat the long tongue with gummy mucus to which ants and termites stick (Griffiths, 1990). *Eidolon helvum* (Figure 1b) is frugivorous. Food can be consumed while hanging by the phalanges of the feet. The food is eaten noisily. The juices are ingested and the fibrous material is discarded. In addition to consuming fruit juices, these

*Corresponding author. E-mail: davidofus234@yahoo.com. Tel: +234-803-445-5715.

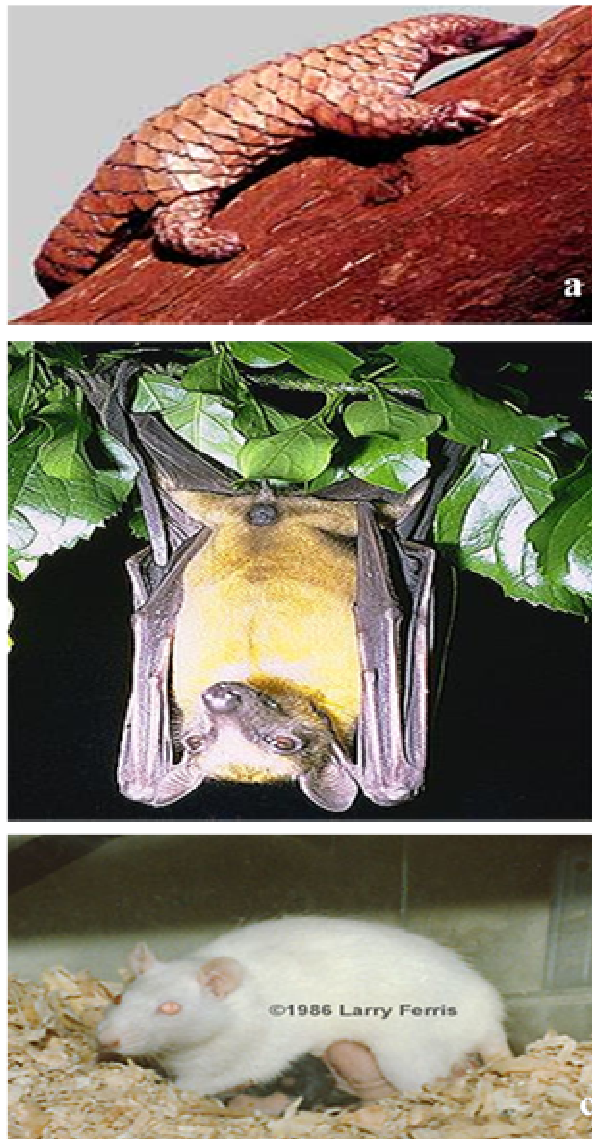


Figure 1. Photograph of the three mammals showing (a) Pangolin, *Manis tricuspis*. (b) Bat, *Eidolon helvum* (c) Rat, *Rattus norvegicus*. Courtesy Redford and Dorea 1984.

animals are reported to chew up wood and bark, apparently to obtain moisture. Foods eaten include: *Borassus spp.*, dates, baobab flowers, *Adansonia digitata*, *Bombax spp.*, *Erythrina spp.*, mangoes, pawpaws, avocado pears, figs, passion fruit, custard apples and loquats. (Nowak and Ronald., 1997; Smithers and Reay, 1983 and Okon, 1974).

Rattus norvegicus (Figure 1c) is a true omnivore and will consume almost anything, but with cereals forming a substantial part of the diet. Martin Schein, founder of the Animal Behaviour Society in 1964, studied the diet of brown rats and came to the conclusion in his paper "A Preliminary Analysis of Garbage as Food for the Norway Rat" that the most-liked foods of brown rats were (in

order) scrambled eggs, macaroni and cheese, and cooked corn kernels. Their least-liked foods were raw beets, peaches, and raw celery. They are usually active at night and are good swimmers, both on the surface and underwater, but (unlike the related Black rat *Rattus rattus*) are poor climbers. They dig well, and often excavate extensive burrow systems. A 2007 study found rats to possess metacognition, a mental ability previously only found in humans and some primates (Science Daily, 2007; Caroline et al., 2003). The morphometric work of Glenn and Robert (1997) revealed that in all species, the tunical muscularis consists of the inner circular and outer longitudinal smooth muscle layer. The tunica muscularis is thickest in the horse, in which the two layers are nearly

Table 1. Comparative macro-morphometry of the stomach of pangolin, bat and rat

Studied characteristics	Pangolin	Bat	Rat
Weight of Animal (g)	1351 ± 12.79	294 ± 5.55*	236 ± 3.28**
RWS(cm)	0.034 ± 0.0009	0.011± 0.0006*	0.010±0.0002**
RLS(cm)	0.15 ± 0.0006	0.35 ± 0.0061*	0.13± 0.0014 **
Length of the stomach (cm)	14.06 ± 0.092	6.26 ± 0.118*	4.40 ± 0.088**
Diameter of stomach (cm)	10.49 ± 0.11	3.50 ± 0.08*	4.18 ± 0.12**
Volume of stomach (ml)	56.75 ± 0.61	2.68 ± 0.09*	2.96 ± 0.12**

KEYS: n = 8; Values are recorded as Mean ± S.E.M; * (Significantly different, Bat and Rat VS. Pangolin, P<0.05);

* (Significantly Different, Bat vs. Rat, P<0.05).

RWS = Relative weight of the stomach to the absolute body weight

RLS = Relative length of the stomach to the nose-tail length

equal in thickness with a total thickness of 1,150 mm. The morphology of gastrointestinal tract in primates and comparison with other mammals in relation to diet revealed that the ratio of stomach and large intestine to small intestine (by area, weight, and volume) are low in frugivores and high in folivores; the continuous spread of coefficients reflect the different degrees of adaptation of these two dietary extremes (David and Hladic, 2001). Also, the volume of stomach and large intestine in faunivores is related to actual body size, where as these chambers are more voluminous in larger frugivores and mid-gut fermenter; fore-gut fermenters show a marked decrease in capacity with increasing body size (David and Hladic, 2001).

The absolute weights of the body, heart, kidney, spleen, pancreas, liver, gonads, digestive tract and oviduct were determined in adult female and male African white bellied tree pangolin (Ozegbe et al. 2000); Statistical analysis of sex effects showed that all the organs except the length of the esophagus relative to the nose tail length were significantly different (p<0.05).

In this study we set to determine the thicknesses of the layers (coats) of the stomach of the three mammals as well as to take the appropriate measurements of the wet weight, length, diameter and volume. These data was analyzed using descriptive inferential statistics. Our ultimate objective is to investigate if there is any reflection of the diets of these three mammals on the morphometric assessment of their stomach.

MATERIALS AND METHODS

Care of animals

Sixteen rats, sixteen bats and eight pangolin of both sexes were used for this research work. Each of the animals was randomly divided into two groups (A and B). Each group therefore had eight animals except for pangolin where each group had four animals due to their scarcity. The rats were obtained and maintained in the Animal Holdings of the Department of Anatomy and Cell Biology Obafemi Awolowo University, Nigeria. They were fed with the rat pellets and given water liberally. The bats were harvested from their roosting colony on the Obafemi Awolowo university Campus following ethical clearance, and maintained in the Animal Holdings of

the same Department. They were fed with ripe bananas and water. The pangolins were procured 24 h prior sacrifice. The animals were carefully assessed, screened and confirmed to be presumably free of any pathological conditions. The animals were handled in accordance with the rules and guidelines for animal research as detailed in the NIH G for the care and use of laboratory animals (NIH publications 85-93, 1985).

Excision of the gastrointestinal tract

The stomach were excised after the sacrifice of the animals by cervical dislocation. Following careful removal of the mesentery, the stomach were cut on regional basis that is cardia, fundus, corpus and pylorus. Those in group A (eight rats eight bats and four pangolins) had their excised stomach washed in saline (physiological) and blotted dry on a filter paper. They were then subjected to macro-morphometric analyses, which include taking the wet weight of the stomach using a metler (Pb 153) balance. Its relative weight was then calculated (by dividing the stomach weight by the absolute body weight) and recorded (gram). Also, the diameter of the stomach as well as the length were recorded (centimeter) using a flexible tape measure. The relative length of the stomach was also calculated and recorded (centimeter) by dividing its length by the nose-tail length. Stomach volume was determined using the water displacement method and recorded to the nearest milliliter. Those in group B (consisting of eight rats eight bats and four pangolins) have their excised stomach immediately fixed in 10% formal saline for histological analyses. Stained slides from this group were subjected to micro-morphometric analyses by measuring the different layers (coats) of the stomach using the eye piece micrometer procedure of W.H.O (1991) which include focusing oculometer fixed into a microscope through stained sections of the tissues using a 4x objective lens (numerical aperture 0.75).

Statistical analysis

Data were expressed as mean ± standard error of mean (S.E.M). The student's t-test method (for periodic data) was used for the determination of the level of significance where applicable. P<0.05 was taken to denote a statistically significant which mean that the differences cannot easily be explained by sampling error, when the calculated value falls within the critical region in the t-test chart. If non significant, it means difference observed can be attributed to chance if samples were selected randomly.

RESULTS

The mean (M) and the standard error of mean (S.E.M)

Table 2. Comparative micro-morphometry of different layers (coats) of the stomach of pangolin, bat and rat. (Mean \pm S.E.M)

	PANGOLIN				BAT				RAT			
	Cardia	Fundus	Corpus	Pylorus	Cardia	Fundus	Corpus	Pylorus	Cardia	Fundus	Corpus	Pylorus
ME	580 \pm 48.26	892 \pm 26.48	2686 \pm 82.67	1768 \pm 48.26	282 \pm 22.37*	324 \pm 15.29*	239 \pm 7.50*	281 \pm 25.75*	537 \pm 26.14* **	177 \pm 7.50* **	290 \pm 41.22* ∞	178 \pm 26.14* **
SM	156 \pm 8.67	164 \pm 5.00	182 \pm 8.67	156 \pm 22.93	243 \pm 13.24*	199 \pm 27.85 $^\circ$	182 \pm 22.93*	121 \pm 5.00*	121 \pm 10.01* **	143 \pm 18.89 $^\circ$ **	113 \pm 5.00* **	208 \pm 8.67* **
M	347 \pm 5.00	459 \pm 18.03	1378 \pm 22.93	910 \pm 39.71	355 \pm 27.85 $^\circ$	381 \pm 30.43*	355 \pm 20.00*	373 \pm 5.00*	797 \pm 26.47* **	719 \pm 18.04* **	849 \pm 43.61* **	451 \pm 32.81* **
TT	2886 \pm 31.24	2990 \pm 82.66	4420 \pm 229.25	2167 \pm 105.89	971 \pm 18.04*	945 \pm 30.43*	45 \pm 39.07*	693 \pm 10.01*	1257 \pm 75.71* **	997 \pm 10.01* **	1031 \pm 5.00* **	793 \pm 35.02* **
RM	0.12 \pm 0.16	0.15 \pm 0.06	0.31 \pm 0.10	0.42 \pm 0.38	0.37 \pm 1.54 $^\circ$	0.40 \pm 1.00 $^\circ$	0.48 \pm 0.51 $^\circ$	0.54 \pm 0.50 $^\circ$	0.64 \pm 0.35* ∞	0.72 \pm 1.80 $^\circ$ ∞	0.82 \pm 8.72 $^\circ$ ∞	0.57 \pm 0.94 $^\circ$ ∞
RSM	0.05 \pm 0.28	0.06 \pm 0.01	0.04 \pm 0.03	0.07 \pm 0.22	0.25 \pm 7.39 $^\circ$	0.13 \pm 0.92 $^\circ$	0.24 \pm 0.59 $^\circ$	0.17 \pm 10.0 $^\circ$	0.10 \pm 0.14 $^\circ$ ∞	0.14 \pm 1.89 $^\circ$ ∞	0.11 \pm 1.00 $^\circ$ ∞	0.27 \pm 0.25* ∞
RME	0.20 \pm 0.85	0.29 \pm 0.10	0.61 \pm 0.36	0.82 \pm 0.46	0.29 \pm 1.24 $^\circ$	0.36 \pm 0.50 $^\circ$	0.32 \pm 0.19 $^\circ$	0.41 \pm 2.57 $^\circ$	0.43 \pm 0.35 ∞	0.18 \pm 0.20 $^\circ$ ∞	0.28 \pm 8.24 $^\circ$ ∞	0.23 \pm 0.75 $^\circ$ ∞

KEYS: n = 6; ME = Muscularis externa; SM = Submucosa; M = Mucosa; TT = Total Thickness; RM = Relative thickness of the mucosa; RSM = Relative thickness of the submucosa; RME = Relative thickness of the muscularis externa; Measured in microns

$^\circ$ (not significantly different) = $p > 0.05$ vs. pangolin; $^\circ$ (not significantly different) = $p > 0.05$ bat vs. rat

* (significantly different) = $p < 0.05$ vs. pangolin; ** (significantly different) = $p < 0.05$ bat vs. rat

of the macro-morphometric analysis are provided in Table 1.

The data got were then used to determine the level of significance. In all cases, the measured parameters showed a significant difference ($P < 0.05$).

Also, the mean (M) and the standard error of mean (S.E.M) data (micro-morphometric analysis) of the thickness of various layers (coats) of the stomach of the three mammals are provided in Table 2.

When the relative thickness of the mucosa, submucosa and muscularis externa were compared in the three mammals, they showed a non significant difference ($p > 0.05$) with the exception of the relative thickness of the mucosa of the rat's cardia and the relative thickness of the submucosa of rat's pylorus which showed a significant difference ($p < 0.05$) when compared with that of pangolin. In contrast, the mucosa, submucosa and muscularis externa were observed to be significantly different in the three mammals when compared ($p < 0.05$).

The results are as presented in Table 2.

DISCUSSION

Morphometric analysis

Macro-morphometry: A comparative morphometry of the weight, length, diameter, volume, relative weight of the stomach to the absolute body weight and relative length of the stomach to the nose-tail length in the three mammals, were observed to be statistically significantly different ($p < 0.05$).

This observation may be related of the varying sizes and weights of the three mammals as reported by David and Hladic (2001) and Ozegebe et al. (2000); but more importantly, may also be a reflection of their different feeding behaviour. The need for the pangolins' stomach to accommodate volumes of sand, pebbles and ditrus which add bulk to the digestive load (to compensate for the lack of teeth), coupled with a large volume of their daily intake (150 to 200 g) of insects (pangolin specialist group, 1996), may provide an explanation to the significant increase ($p < 0.05$) in its stomach macro-morphometry over the other two

mammals (bat and rat).

Mirco-morphometry

Mucosa (Epithelium, lamina propria and muscularis mucosa): A comparative relative thickness of the mucosa appeared not to be significantly different ($p > 0.05$) in the regions of the stomach considered. In contrast, the comparative thickness of the mucosa was observed to be statistically higher in pangolin than in the other two mammals ($p < 0.05$). This observation may be related to the functional differences. This finding buttresses the work of Webster and Leeming (1975). However, more studies may throw light in this regard as the literature is scanty in this area.

Submucosa

A comparison of the relative thickness of the submucosa in the stomach of the three mammals was not statistically significantly different ($p > 0.05$). This may reflect similar and consistent role-played

in maintaining the structural integrity throughout the stomach. This finding is in line with the observation of Lord et al. (1977) and Douglas and Robert (1997). This finding and the histological findings also suggest a non-directional proportionality between the submucosa and its content.

Muscularis externa (Outer longitudinal and inner circular muscles): The study comparing the relative thickness of the muscularis externa in the three mammals showed a non-significant difference ($p > 0.05$). This finding may be a pointer to the similar functional implication of this part relative to their respective diets of the three mammalian species.

The need for an increased surface area for the proper alignment of the elastic fibers needed for the stretching and recoiling property of the pangolin's stomach (to make way for the soft internal part of the ingesta, Redford 1984; and to accommodate air for buoyancy, pangolin specialist group (1996), explains the reason for a significant increase in the thickness of its muscularis externa ($p < 0.01$) compared to the other two mammals. Our findings agree with the observations of Heath et al (1999); Douglas and Robert (1997). The significant increase in the overall thickness of the smooth muscle fibers in the pangolin's stomach compared with the bat and rat ($P < 0.05$), is an indication of increased metabolic activities which may be an adaptation needed to successfully churn and propel the hard ingesta. These observations agree with the findings of Adams (1967) and Ofusori et al. (2007) who reported that the distribution of the smooth muscle fibers corresponds to the metabolic active sites.

It is therefore worthy to conclude that the morphometric assessment of the stomach in the three mammals has a functional implication as regard their respective diets.

REFERENCES

- Caroline MS, Gross, Dian-Marie (2003): Fiber digestion in mammals. Pak. J. Biol. Sci. 6(17): 1564-1573.
- David JC, Hladic CM (2001). Morphology of the gastrointestinal tract in primates: Comparisons with other mammals in relation to diet. J. Mor. 1051660306.
- Douglas SL, Robert CH (1997). Histology for Pathologists 2nd ed. Philadelphia.
- Glenn HS, Robert EP (1987). Histology of pathologist, 2nd ed Philadelphia.
- Griffiths M, Greenslade PJM, Miller L, Kerle JA (1990). The diet of the spring-ant eater *Tachyglossus Aculeatus Acanthion* in tropical habitats in the northern territory. The Beagle. 7:79-80.
- Heath JW, Young B, Burkitt HG (1999). Gastrointestinal tract. Wheater's functional histology. 3rd ed. pp. 247-270.
- Hildebrand M, Goslow GE (2001). Analysis of vertebrate structure 5th ed. John Wiley and sons, Inc. New York. pp. 201-217.
- Lord MG, Valies P, Broughton AC (1977). A morphology study of the submucosa of the large intestine. Surg. Gynecol. Obstet. 145: 55-60.
- Nisa C, Kitamura N, Sasaki M, Agungprijono S, Choliq C, Budipitojo T, Yamada J, Sigit K (2005). Immunohistochemical study of the distribution and relative frequency of endocrine cells in the stomach of Malayan pangolin *Manis jaranica*.
- Nowak, Ronald M, (1997). "Straw-colored fruit bat" (On-line). Walker's Mammals of the World Online, Version 5.1. Accessed November 25, 2003.
- Ofusori DA, Caxton-Martins EA, Adenowo TK, Ojo GB, Falana BA, Komolafe AO, Ayoka AO, Adeeyo AO, Oluyemi KA (2007). Morphometric Study of the Stomach of African Pangolin (*Manis tricuspis*). Sci. Res. Essays. Vol. 2 (10), pp. 465-467.
- Ofusori DA, Caxton-Martins EA (2005). A comparative histological investigation of the gastrointestinal tract in pangolin, bat and rat (preliminary study): Bk of abstract 3rd Anatomical society of Nigeria annual conference. p. 35.
- Okon EE (1974). Fruit bats at Ife: Their roosting and food preferences. Nigerian field. 39: 33-40.
- Ozegbe PC, Ogunsanmi AO, Ogunjobi EO (2000). Weights and linear measurements of the body and some organs of the adult African white-bellied tree pangolin. Bk of abstract, 9th scientific congress of the Anatomical Society of West Africa 19th-22nd Oct. 2000.
- Pangolin specialist Group (1996). *Manis tricuspis*. IVCN Red list of threatened species. IVCN 2006.
- Redford KH, Dorea JG (1984). The nutritional value of invertebrates with emphasis on ants and termites as food for mammals. J. Zool. 203: 385-395.
- Saladin, Kenneth S (2004). "Anatomy and Physiology – The unity of form and function" (international ed, 3rd ed). The McGraw-Hill companies p.950..
- Science Daily. (2007) sourced from university of Georgia. Rats Capable of Reflecting on Mental Processes. Retrieved on 2007-08-02.
- Sherwood, L (2002). Human Physiology- From cells to systems (international Student Edition, 5th ed) p604 Books/cole-Thomson learning.
- Smithers, Reay HN (1983). The Mammals of the Southern African Subregion. Pretoria: University of Pretoria Press.
- Webster SGP, Leeming JT (1975). The appearance of the small bowel mucosa in old age. Age Ageing. 4:168-174.
- Wilson JP (1967). Surface area of the small intestine in man. Gut. 8: 618-621.
- World Health Organization (1991). Calibrating the microscope. In Basic laboratory methods in medical parasitology. ISBN 92.4.154410.4.