

Full Length Research Paper

Fine structure of adrenal gland of Indian wild caught female bat *Taphozous kachhensis* (Dobson)

Pankaj Chavhan* and Amir Dhamani

Department of Zoology, N. H. College, Bramhapuri 441206, India.

Received 24 September, 2013; Accepted 20 November, 2013

The Indian wild caught bat, *Taphozous kachhensis* at Ambai Nimbai (Maharashtra) shows continuous asynchronous breeding, exhibiting a seasonal polyoestry. The adrenal gland of *T. kachhensis* is made up of adrenocortical and chromaffin tissues. The adrenocortical tissue is comprised of two main types of cells, the steroid cells with abundance of lipid inclusions and eosinophilic cells with eosinophilic granular cytoplasm. The chromaffin tissue is intermingled with adrenocortical tissue. They are formed of adrenaline and noradrenaline secreting cells with different electron density and variable sizes. The zona glomerulosa during estrus shows spherical nuclei with prominent nucleoli. Adrenal gland of pregnant female shows striking differences in ultrastructural features than those observed in the adrenal gland of non-pregnant female. During pregnancy, the cells of zona glomerulosa are hypertrophied and synthetically very active. The lysosomes and few lipid droplets are seen in cytoplasm of cell. The cells of zona fasciculata are large, vacuolated and arranged in cords of polygonal cells having mitochondria with tubular and lamellar cristae. The lipid droplets are observed in close association with smooth endoplasmic reticulum and mitochondria suggesting the role of these organelles in steroidogenesis. The cells of zona reticularis are loaded with lipid droplets. The mitochondria are spherical in shape with collapsed cristae. The cells of zona reticularis are in close association with blood vessels. Few lysosomal bodies are seen in the cytoplasm. Adrenal medulla consists of two types of cells depending on the presence of secretory granules. Nor-epinephrine cells are predominant in the medulla of pregnant bat while epinephrine cells are predominant in the medulla of estrus bat.

Key words: Bat, adrenal gland, medulla, ultrastructure, reproductive cycle.

INTRODUCTION

A primary function of the adrenal gland is to protect the organism against acute and chronic stress. In acute stress, catecholeamines of the medulla mobilize glucose and fatty acids for energy and prepare the heart, lungs and muscles for action. Glucocorticoids protect against over reactions of the body's responses to stress, and in the more chronic stress of food and fluid deprivation stimulate gluconeogenesis to maintain the supply of glucose. Stress as well as hyper- and hypo-function of the adrenal gland is known to suppress reproduction in

mammals (Rivier et al., 1986; Burrow, 1991).

The adrenal gland is composed of two distinct cell layers, the cortex and the medulla. The medulla is located in the middle of the adrenal gland and is composed of chromaffin cells that produce the hormones epinephrine and nor-epinephrine. These hormones provide short-term response to a stressor (Charmandari et al., 2005). Epinephrine and nor epinephrine have a more basic hormonal structure, which allows for rapid synthesis permitting an immediate response to hazardous situations.

*Corresponding author. E-mail: panksphd@gmail.com.

Author(s) agree that this article remain permanently open access under the terms of the [Creative Commons Attribution License 4.0 International License](http://creativecommons.org/licenses/by/4.0/)

MATERIALS AND METHODS

The collection of the specimens commenced in February, 2006 and the last specimen was collected in May, 2009. The specimens of *Taphozous kachhensis* were collected from Ambai Nimbi, about 45 kilometers from Bramhapuri (MS). Many collections were made during the breeding season so as to coincide with the time of reproductive cycle and to get an accurate pregnancy record. For the electron-microscopic studies, adrenal glands were immediately removed from estrus bat and pregnant bats after they were killed by decapitation. The tissues were fixed in fresh ice-cold 3% glutaraldehyde for 3 h and then 4 h in 0.1 M cacodylate buffer. The tissues were washed in buffer and then post fixed for one to two hours in 1% 0.067 M cacodylate-buffered osmium tetroxide. After dehydration with graded series of alcohol, the tissues were cleared in propylene oxide solution and embedded in araldite resin which would be polymerized at 600°C. Then, ultrathin sections from selected blocks were cut with glass knife and picked up on 400-mesh copper grids. Sections were double stained with 10% alcoholic uranyl acetate for 20 min and for 10 min in Reynold's lead citrate. The sections were examined under a JEM Jeol-100s electron microscope (Japan) at 80 KV accelerating voltage and photographed.

RESULTS

Adrenal gland of pregnant female shows striking differences in ultrastructural features than those observed in the adrenal gland of non-pregnant female. During estrus, zona glomerulosa is made up of circular cords or acini like structure and each acinus is made up of 4 to 6 cells which are compactly arranged as compared to other two zones (Figure 1). The nucleus is oval to spherical in shape and shows prominent nucleoli. Chromatin clumps are attached to the inner surface of the nuclear membrane and flakes of chromatin material are scattered throughout the nucleoplasm. The golgi complex is juxta-nuclear in position. The smooth endoplasmic reticulum is in the form of tubule and scattered throughout the cytoplasm. The rough endoplasmic reticulum is rare and there are numerous free ribosomes seen distributed throughout the cytoplasm. The mitochondria are numerous, circular to elongated in shape with lamellar cristae associated with lipid droplets and distributed throughout the cytoplasm. Lipid droplets are many and mostly round to oval in shapes (Figure 2).

The zona fasciculata constituted the major portion of the adrenal cortex and contain cells larger than those of the zona glomerulosa. The cells are arranged in radial cords and separated from each other by a strand of connective tissue. The nuclei are spherical to oval in shape with slight indentation. A thin rim of chromatin material is attached to the inner part of the nucleus. Chromatin clumps are scattered throughout the nucleoplasm. Nuclear pores are also seen. The cytoplasm is more vacuolated and contains several cell organelles (Figure 3). The smooth endoplasmic reticulum is in the form of small circular vesicle and distributed throughout the cytoplasm. The rough endoplasmic reticulum is rare and there are numerous free ribosome observed throughout

the cell cytoplasm. The lipid droplets are abundant and usually appear as large vacuole. These vacuoles are round to oval in shape and are more in number than zona glomerulosa (Figure 4).

The golgi network is extensive. The golgi region is occupied by flattened to dilated saccules of varying degree. The numbers of mitochondria are more as compared to zona glomerulosa and are uniformly distributed throughout the cytoplasm. These are circular with lamellar cristae and granular matrix. Few lysosomes are seen in the cytoplasm (Figure 4). Zona reticularis is the inner most cortical zone. Its cells are small and form cords which appear to intertwine in an anatomizing network. Polygonal cells have homogenous cytoplasm and spherical nucleus. The chromatin material is attached to the inner surface of nuclear membrane. Nucleolus is distinctly marked (Figure 5). Lipid droplets are present in the cytoplasm, these are less in number as compared to zona fasciculata. Mitochondria are spherical and seen throughout the cytoplasm. Prominent smooth endoplasmic reticulum and small golgi apparatus is also observed in the cytoplasm. Numerous free ribosomes are seen throughout the cell cytoplasm (Figure 6).

In *T. kachhensis* medulla consist of small groups of chromaffin cells surrounded by blood capillaries and connective tissue. The ultrastructural studies show two types of cells in the medulla distinguished by their nuclear shape and volume of secretory granules. Type I shows large circular nucleus, secretory granules are less electron dense which are separated from the surrounding membrane by an electron lucent space. Type II shows irregular nucleus and the secretory granules are electron dense. Type I cells are polygonal and show large rounded nucleus. Cellular junction is clearly marked and free ribosomes are observed in the cytoplasm. Mitochondria are small, circular with collapsed cristae (Figure 7). Type II cells are polygonal. The nucleus is irregular with chromatin material attached to the inner margin of nuclear membrane. The nucleoplasm is granular and some mitochondria are seen with collapsed cristae. The distinguished feature of the medullary cells is the chromaffin granules, which appear as a membrane bound body of variable electron density. Some cell contains predominantly dense black granules, while adjacent cells show scattered empty vesicle with small amount of granular material (Figure 7).

The ultra structural observation during early pregnancy shows the more cellular development than the estrus. The cells of zona glomerulosa are large and polygonal in shape. The nucleus is spherical to irregular in shape. The nucleolus is compact and present toward the nuclear membrane and nuclear pores are visible (Figure 8). The mitochondria are numerous and scattered throughout the cytoplasm and appear in various shape and size with lamellar cristae (Figure 9). The smooth endoplasmic reticulum are seen in the form of tubule and present near the nucleus. Rough endoplasmic reticulum

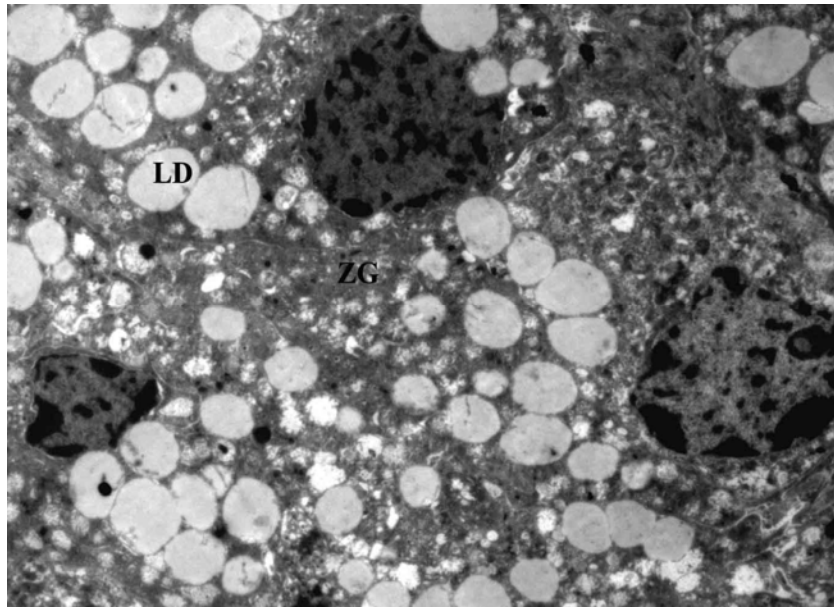


Figure 1. Electron micrograph of zona glomerulosa (ZG) during estrus showing acini like group of cell. Note the presence of oval to round shaped nuclei (N) and many lipid droplets (LD) $\times 5000$.

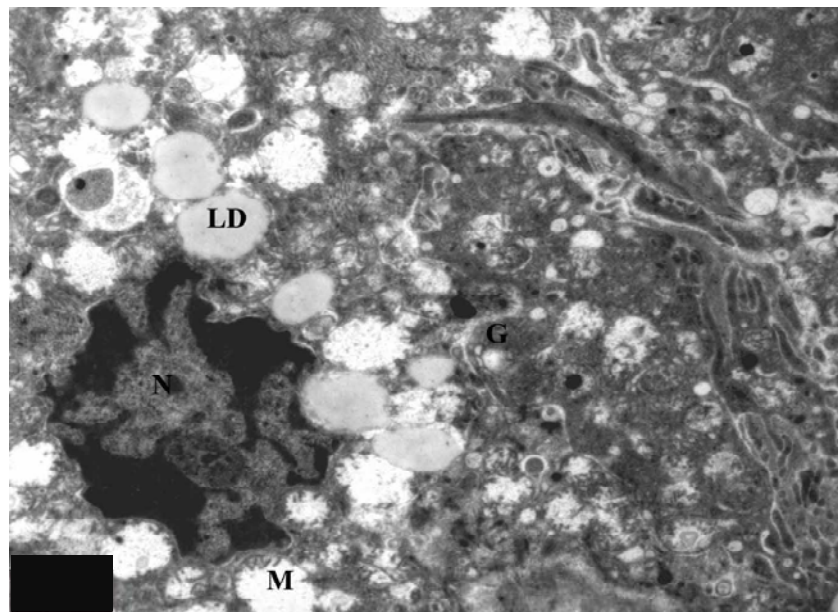


Figure 2. Electron micrograph of zona glomerulosa (ZG) during estrus. Note the presence of indented nucleus (N) with clumps of chromatin material, numerous circular mitochondria (M) with collapsed cristae, lipid droplets (LD) and smooth endoplasmic reticulum (SER). $\times 8000$.

are not observed in the cytoplasm of the cell. The lysosomes and few lipid droplets are seen in cytoplasm of cell. The cells of zona fasciculata are large, vacuolated and arranged in cords of polygonal cells. The space between the cords is occupied by blood vessels. The nucleus

is irregular with chromatin material attached to the inner membrane and also seen scattered in the nucleoplasm. Mitochondria are randomly distributed in the cytoplasm and appear in various shapes. Golgi bodies are observed in cytoplasmic matrix.

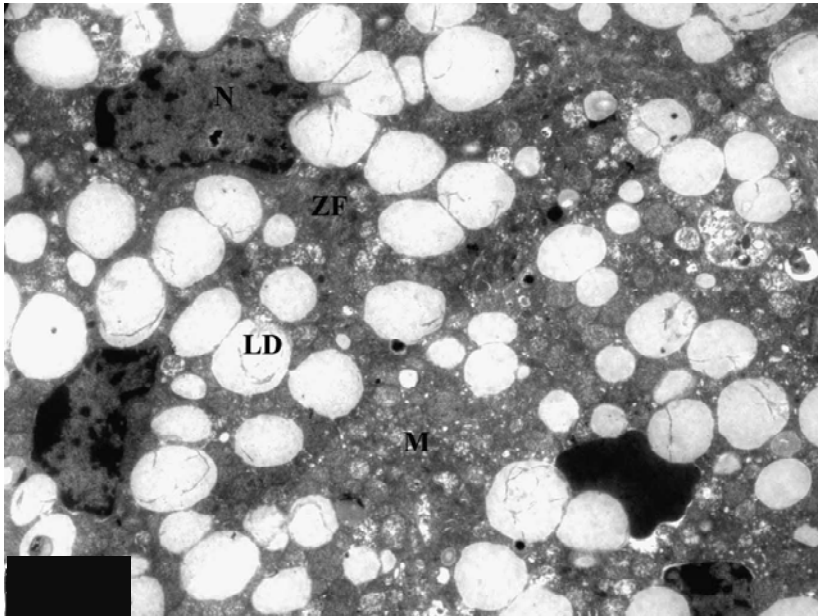


Figure 3. Electron micrograph of zona fasciculata (ZF) during estrus. Note the presence of several round shaped lipid droplets (LD), associated with mitochondria (M). Note the presence of blood vessel (BV). $\times 4000$.

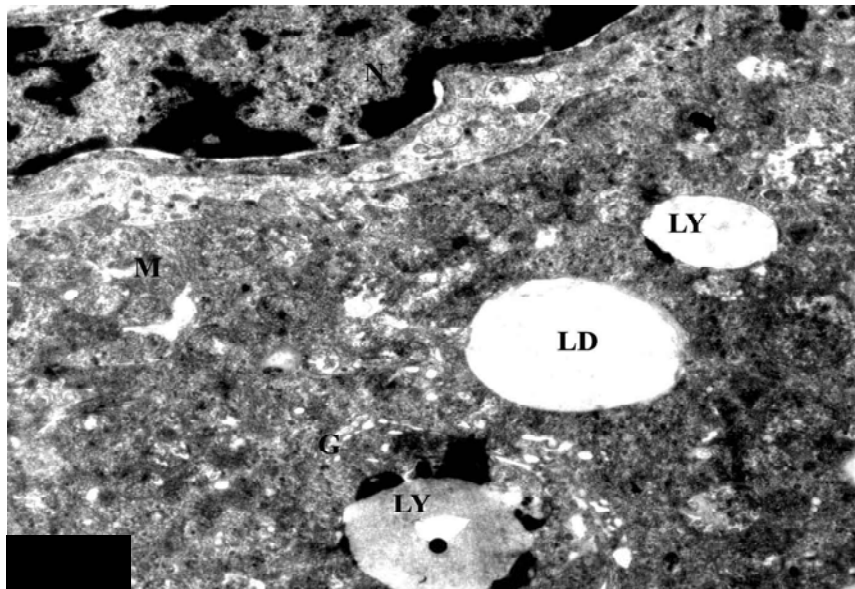


Figure 4. Electron micrograph of zona fasciculata [ZF] during estrus. Note the presence of rounded mitochondria [M] with tubular cristae. Small Golgi zone [G] is observed in the cytoplasm. Tubular profile of smooth endoplasmic reticulum [SER] is scattered throughout the cytoplasm and some lysosomal bodies [LY] are also seen. $\times 12000$.

The cells of zona fasciculata have tubular profiles of smooth endoplasmic reticulum in the cytoplasm. Lipid droplets are large in size and are abundant in this zone than those found in zona glomerulosa. The lipid droplets

are observed in close association with smooth endoplasmic reticulum and mitochondria, suggesting the role of these organelles in steroidogenesis (Figure 10).

The cells of zona reticularis are smaller than the cells of

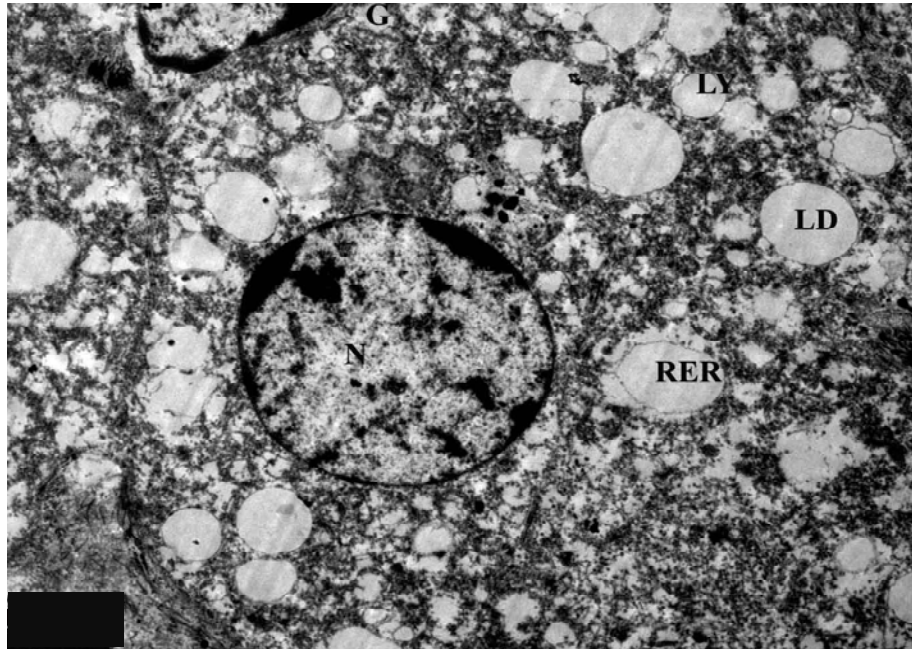


Figure 5. Electron micrograph of zona reticularis (ZR) during estrus showing many mitochondria (M), lipid droplet (LD), dilated rough endoplasmic reticulum (RER). Note the presence of many free ribosomes in the cytoplasm. $\times 10000$.

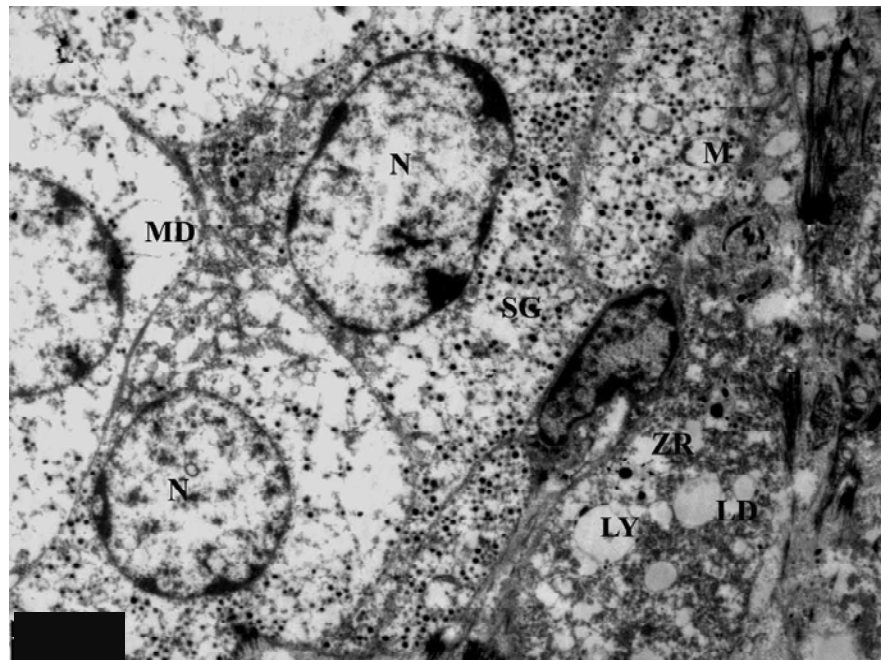


Figure 6. Electron micrograph of medulla (MD) during estrus. Note the presence of type II medullary cell or epinephrine (EP) cell with round to oval nucleus (N) and zona reticularis (ZR) above. $\times 8000$.

zona fasciculata. These cells are polyhedral having spherical nuclei with one or two well developed nucleoli. The plasma membrane is smooth and at places shows localized thickening probably giving rise to junctional

complex. The cells are loaded with lipid droplets (Figure 11). The mitochondria are spherical in shape with collapsed cristae. The cells of zona reticularis are in close association with blood vessels. Few lysosomal bodies are

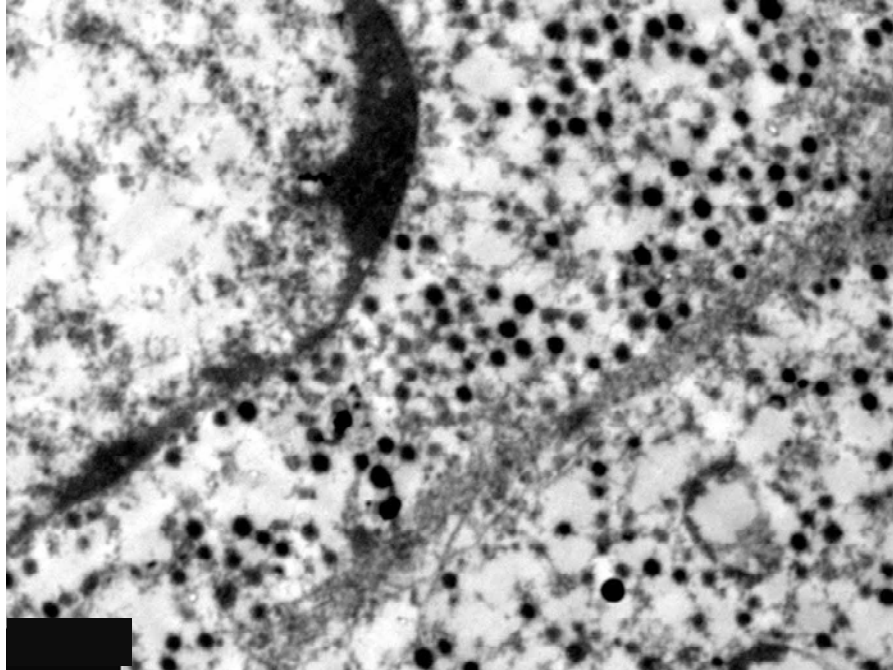


Figure 7. Magnified view of type II medullary cell during estrus showing secretory granules (SG) with dense core. Hypertrophied mitochondria (M) with collapsed cristae are also observed in the cytoplasm. $\times 20000$.

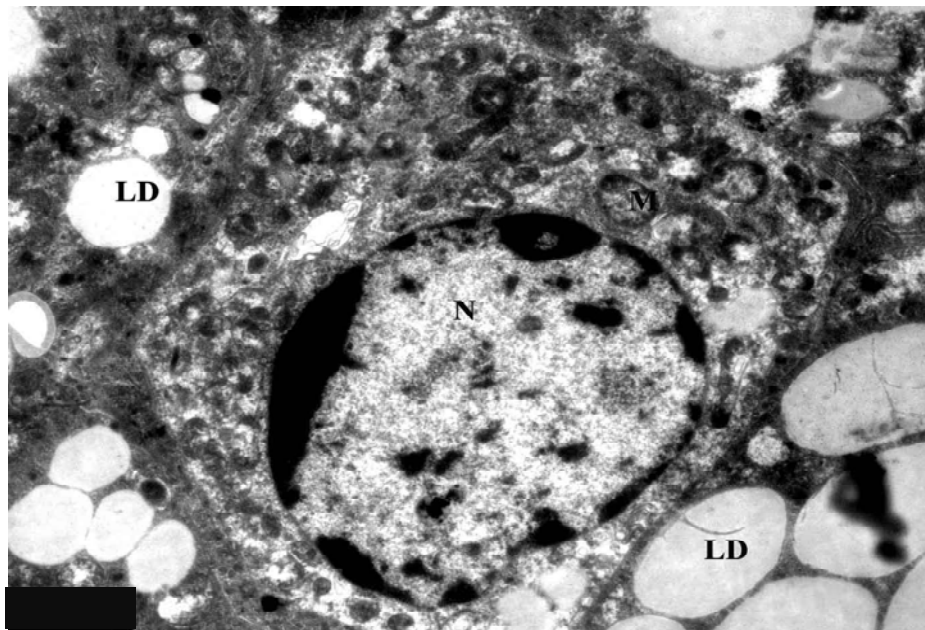


Figure 8. Electron micrograph of zona glomerulosa (ZG) during early pregnancy showing round nucleus (N), few lipid droplets (LD) and many circular mitochondria (M), few lysosomes (LY) and small Golgi apparatus (G). $\times 4000$.

seen in the cytoplasm (Figure 11). Medulla is well developed during early pregnancy.

Chromaffin cells are surrounded by blood capillaries.

These cells are irregular in outline and contain oval nucleus and chromatin material attached to the inner part of the nuclear membrane. Mitochondria are hypertrophied

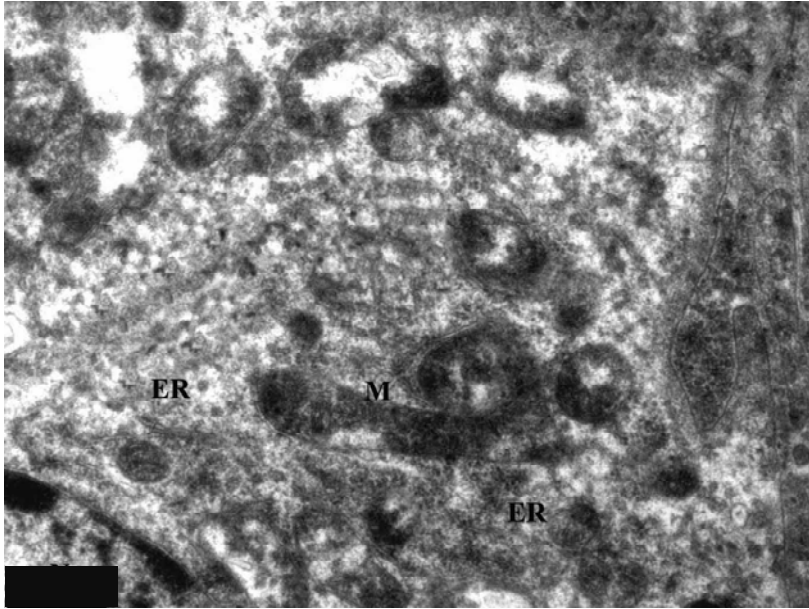


Figure 9. Magnified view of zona glomerulosa (ZG) during early pregnancy showing round to elongated mitochondria (M) some with collapsed cristae and some mitochondria (M) with lamellar cristae, tubular profile of smooth endoplasmic reticulum (SER) is seen scattered in the cytoplasm. $\times 15000$

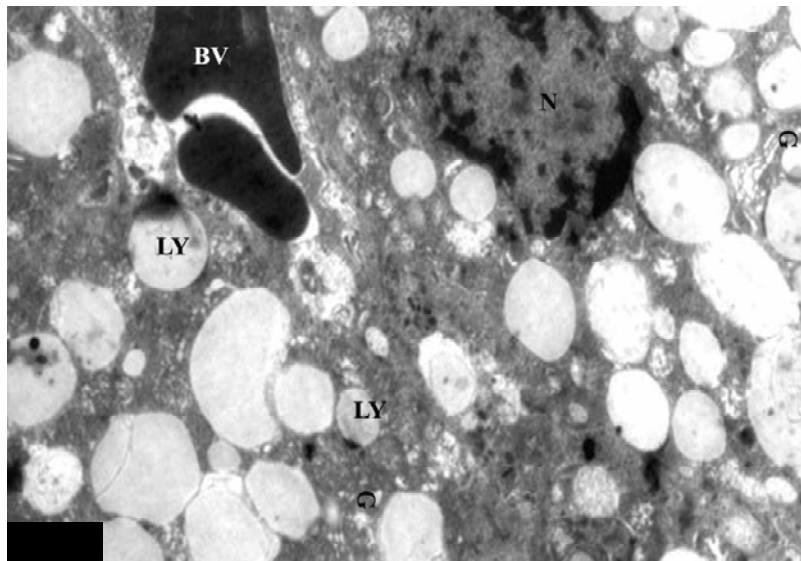


Figure 10. Electron micrograph of zona fasciculata (ZF) during early pregnancy showing elongated cord of cell surrounded by many lipid droplets (LY), blood vessel and few lysosomes (LY) is seen in the cytoplasm. $\times 3000$.

and distributed throughout the cytoplasm. Well developed golgi complex is seen in the cytoplasm. Rough endoplasmic reticulum is well developed and are scattered in the cytoplasm. Two types of cells are identified in this bat. The first type of cell is called nor-epinephrine cells and contains electron dense granules. The second type of cell is called epinephrine cell and contains less electron dense granules. There is no electron lucent space between the

membrane and dense core of the granules (Figure 12).

During late pregnancy, cells of zona glomerulosa are polygonal and they are in the form of acini. The nucleus is spherical and somewhat eccentrically placed. Chromatin material is attached to the nuclear membrane. The nuclear pores are predominant and the nucleolus is large and prominently placed at the nuclear membrane.

A well developed golgi apparatus is situated close to

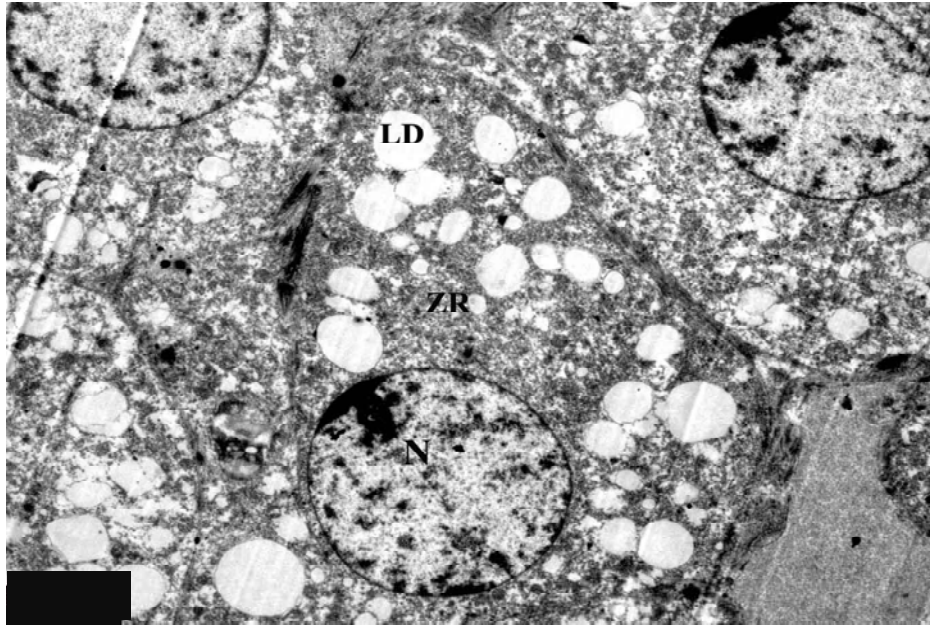


Figure 11. Electron micrograph of zona reticularis (ZR) during early pregnancy. Note the polygonal shape of cell with spherical nucleus (N) and well developed nucleolus (NO) and the presence of lipid droplets (LD), hypertrophied mitochondria (M) with collapsed cristae and golgi apparatus (G). Few lysosomes (LY) are also seen. $\times 10000$.

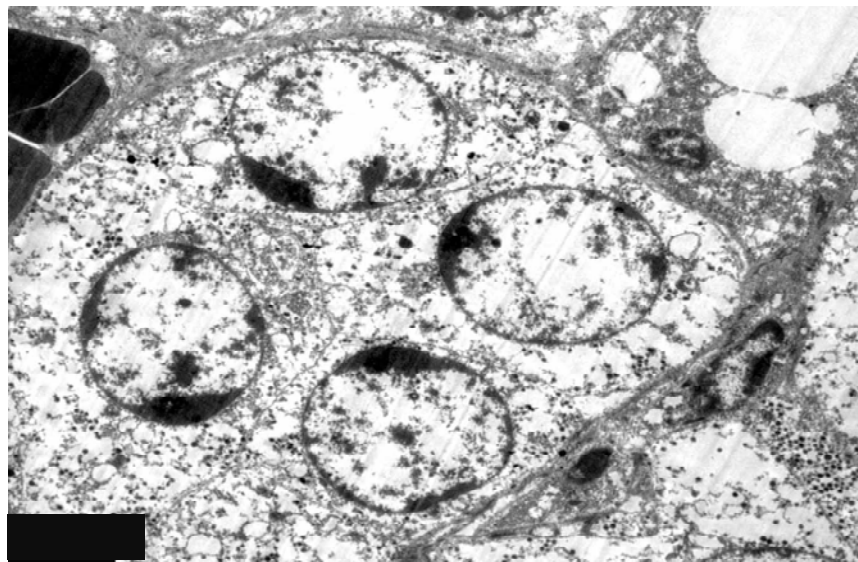


Figure 12. Electron micrograph of medulla (MD) during early pregnancy. Note the spherical shaped nucleus (N) cell cytoplasm is filled with few secretory granules (SG). Note the presence of rough endoplasmic reticulum (RER) and mitochondria (M) with collapsed cristae. $\times 10000$.

the nucleus. The golgi apparatus is made up of array of parallel cisternae with numerous associated vesicles. Numerous rounds to oval shaped mitochondria are observed in the glomerulosa cell. In some mitochondria, there is loss of cristae but most mitochondria contain vesicular cristae. Rough endoplasmic reticulum is rare

but some free ribosomes are seen in the cytoplasm. Most glomerulosa cells have few lipid droplets.

Mitochondria and smooth endoplasmic reticulum are occasionally found in close association with lipid droplets. Few lysosomes are observed in zona glomerulosa during late pregnancy (Figure 13). The most striking feature of

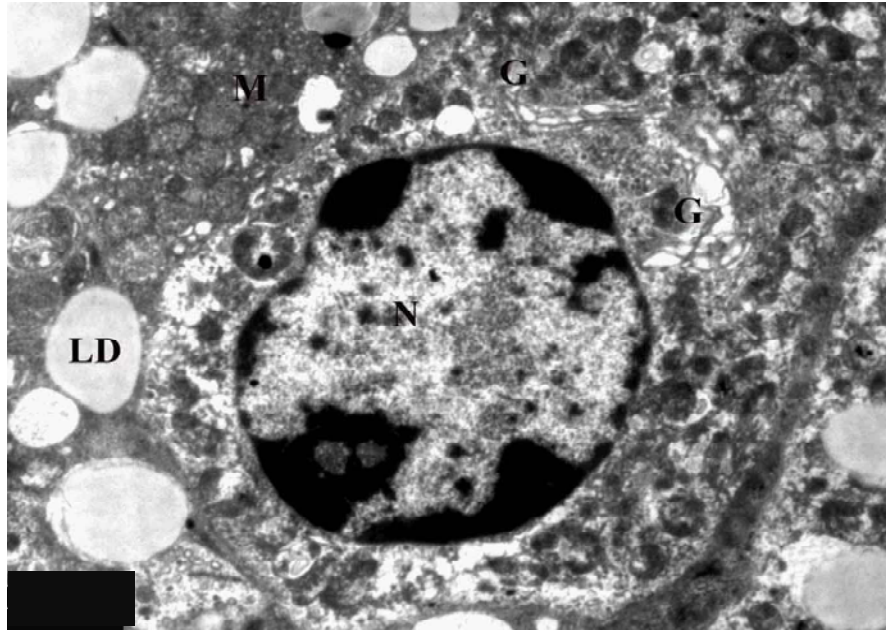


Figure 13. Electron micrograph of zona glomerulosa (ZG) during late pregnancy showing lipid droplets (LD), many mitochondria (M). Note the presence of cell junction (CJ). $\times 4000$.

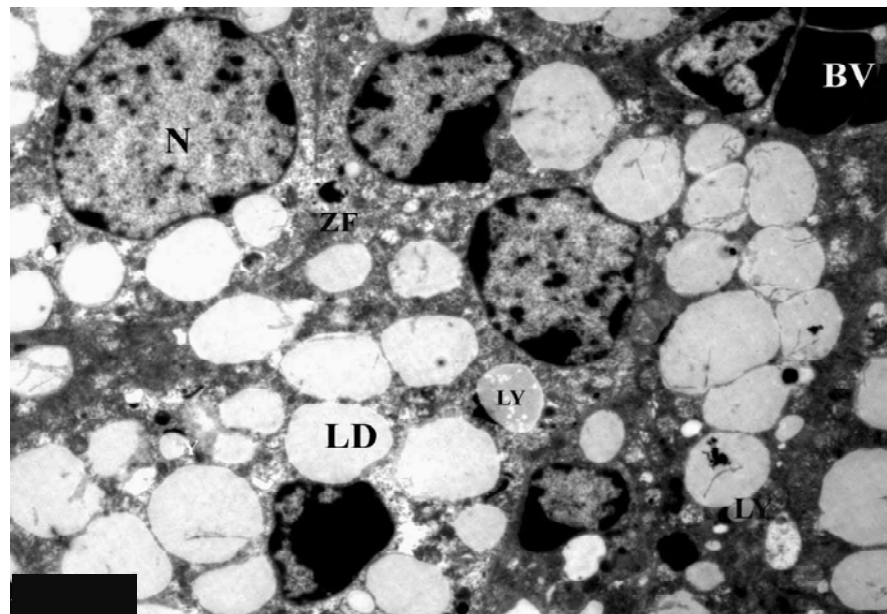


Figure 14. Electron micrograph of zona fasciculata (ZF) during late pregnancy showing elongated cord and large number of lipid droplets (LD) in the cytoplasm. $\times 4000$.

cytology of zona fasciculata is the development of smooth endoplasmic reticulum and condenses of lipid droplets. The cells of zona fasciculata are polygonal. The nucleus is spherical and large with chromatin clumps. The nucleolus is present toward the periphery of the nucleus. Mitochondria are spherical to oval in shape. Some

mitochondria are seen with collapsed cristae. Golgi complex is inconspicuous. Lipid droplets are abundant in this zone and are observed in close association with mitochondria. Few lysosomal bodies are also seen (Figure 15). The cells of zona reticularis are polygonal in shape having spherical nuclei with thin rim of chromatin material attached to the inner membrane of the nucleus.

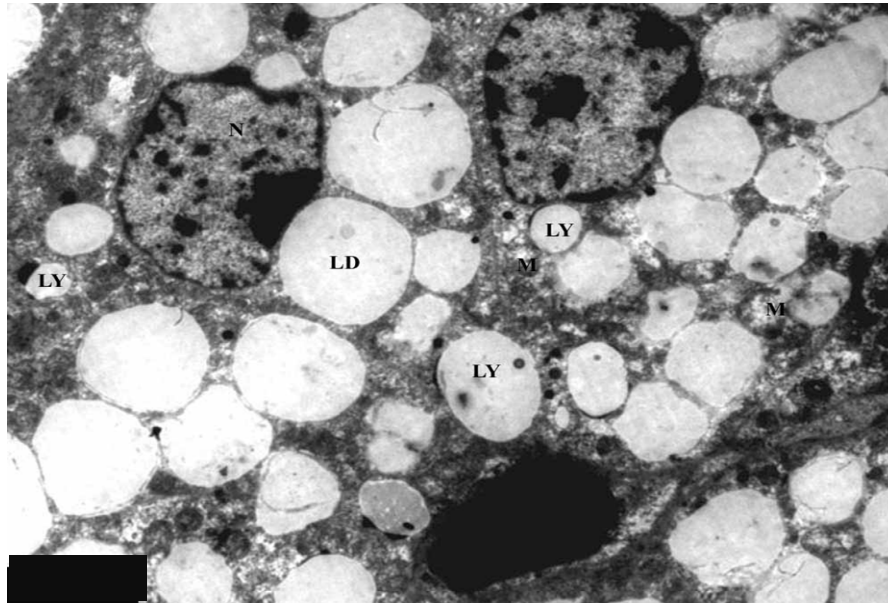


Figure 15. Electron micrograph of zona fasciculata (ZF) to show many lipid droplets in association with smooth endoplasmic reticulum (SER) mitochondria and mitochondria. Note the presence of blood vessel (BV).x8000.

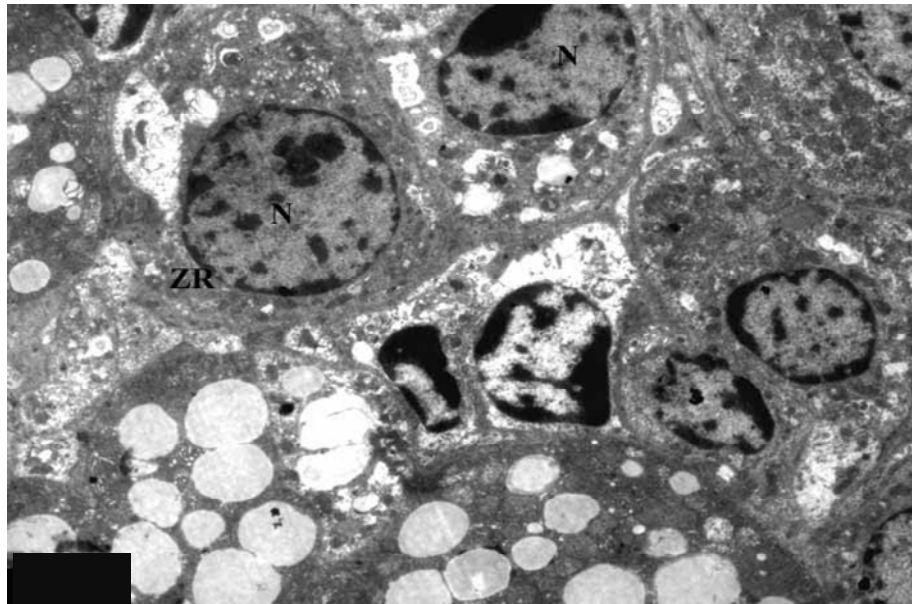


Figure 16. Electron micrograph of zona reticularis (ZR) during late pregnancy showing spherical nucleus (N) with well developed nucleolus (NO), few mitochondria (M) are seen with collapsed cristae. Golgi zone (G) is observed and it is associated with small vesicle. Very few lipid droplets (LD) are seen in the cytoplasm. x8000.

The nucleoplasm is homogenous. There are number of spherical mitochondria seen present in the matrix (Figure 16). Lipid droplets are few in this stage. Golgi bodies are very well developed and juxtannuclear in position (Figure 17). Medulla is very well developed than the early pregnancy. Chromaffin cells of medulla during late pregnancy contain mostly Type I cells that is, nor-

epinephrine cells. Secretory granules are more in number than in early pregnancy and are uniformly distributed through the cytoplasm. Golgi apparatus is well developed. Mitochondria are spherical to oval in shape, with collapsed cristae. Profiles of rough endoplasmic reticulum are seen in the form of elongated tubular cisternae (Figure 18).

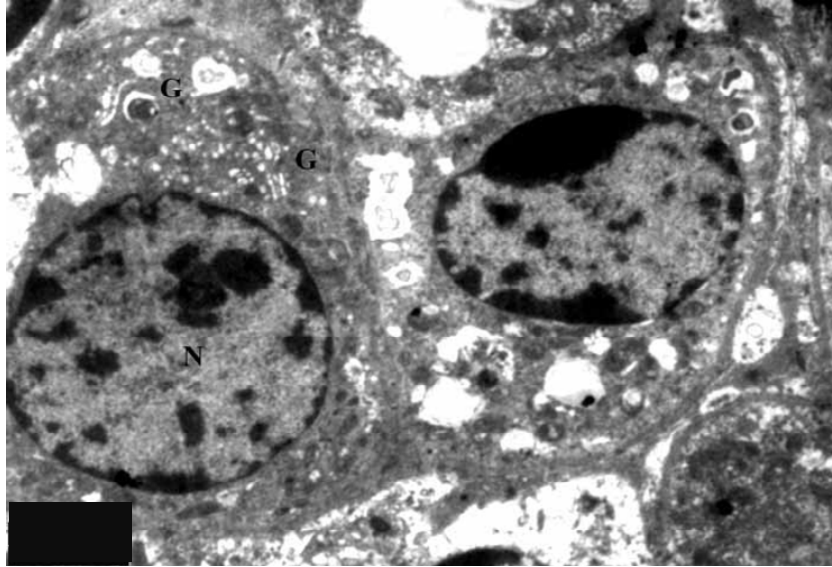


Figure 17. Enlarged view of zona reticularis during late pregnancy showing mitochondria (M) with collapsed cristae. Golgi zone (G) is observed and it is associated with small vesicle. Few lipid droplets (LD) are seen in the cytoplasm. $\times 8000$.

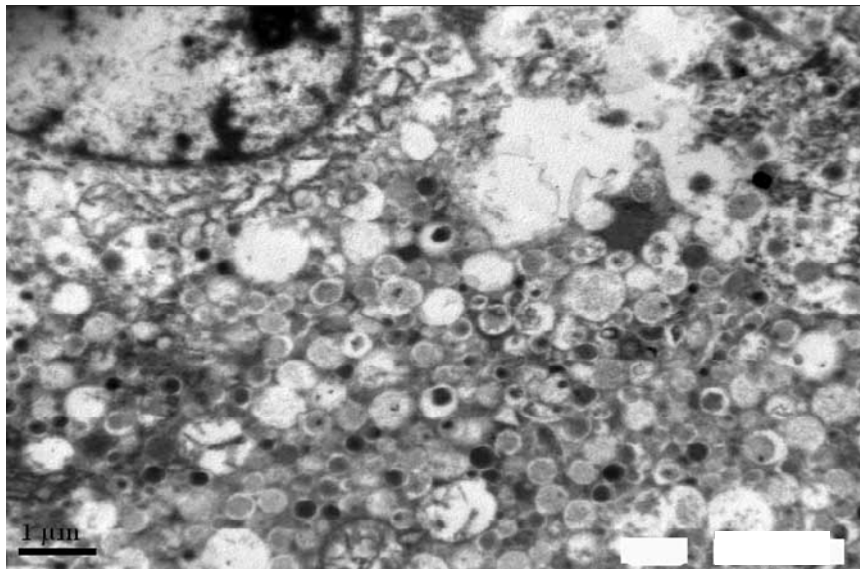


Figure 18. Electron micrograph of medulla during late pregnancy showing Type I cell. Note the presence of dilated tubules of rough endoplasmic reticulum (RER), electron dense granules (DG) and mitochondria with collapsed cristae (M). $\times 12000$.

DISCUSSION

The adrenal cortex plays a tremendous number of vital activities in the human body. This importance is due to the fact that the adreno cortical zones synthesize and secrete steroid hormones. The adrenal cortex in *T. kachhensis* of female bat is differentiated into three zones including: zona glomerulosa, zona fasciculata and zona reticularis. A distinct zonation of the cortex is observed in

Megaderma lyra (Sonwane, 2010). *Miniopterus schreibersii* (Panel et al., 1961) and *Pipistrellus pipistrellus* (Saidapur and Nadkarni, 1976). While in *Taphozous longimanus* Nerkar (2012) has reported that the cortex is differentiated into two zone including, zona glomerulosa and zona fasciculata. Zona reticularis is absent.

The fine structure of adrenal gland during estrus pregnancy shows much striking features. During estrus,

zona glomerulosa is made up of circular cords or acini like structure and each acinus is made up of 4 to 6 cells which are compactly arranged as compared to other two zones. The acinuses are separated from each other by connective strands. The nucleus is oval to spherical in shape and shows prominent nucleoli. Chromatin clumps are attached to the inner surface of the nuclear membrane and flakes are scattered throughout the nucleoplasm. The golgi complex is juxtannuclear in position. The smooth endoplasmic reticulum is in the form of tubules and scattered throughout the cytoplasm. The rough endoplasmic reticulum is rare and there are numerous free ribosomes distributed throughout the cytoplasm. The mitochondria are numerous and appear as a profile of various shapes from circular to elongated, with lamellar cristae associated with lipid droplets. Lipid droplets are many and variable in size and mostly round to oval in shapes. These observations indicate the secretory activity during this phase.

The cells of zona glomerulosa during early pregnancy are large and polygonal. The nucleus is spherical to irregular in shape. A thin rim of chromatin material is attached to the periphery of the nucleus. The nucleolus is compact and present toward the nuclear membrane and nuclear pores are visible. The numerous mitochondria are scattered throughout the cytoplasm and appear in various shape and size with lamellar cristae. The smooth endoplasmic reticulums are seen in the form of tubule and present near the nucleus. The lysosomal bodies and few lipid droplets are also seen.

Cells of zona glomerulosa during late pregnancy are polygonal and they are in the form of acini. The nucleus is spherical and somewhat eccentrically placed. Chromatin material is attached to the nuclear membrane. The nuclear pores are predominant and the nucleolus is large and prominently placed at the nuclear membrane. Plasma membrane is thickened at many places. A well developed golgi apparatus is situated close to nucleus and is made up of array of parallel cisternae with numerous associated vesicle. Numerous round to oval mitochondria are observed. In some mitochondria, there is loss of cristae but most mitochondria contain vesicular cristae. Rough endoplasmic reticulum is rare but some free ribosomes are seen in the cytoplasm. Few lipid droplets are also seen. Mitochondria and smooth endoplasmic reticulum occasionally found in close association with lipid droplets. Few lysosomes are observed in the cell during late pregnancy.

The ultrastructural characteristic of zona glomerulosa of non-pregnant adult female and pregnant female bat, *T. longimanus* (Nerkar, 2012) shows the striking difference. During estrus bat shows euchromatic nucleus with prominent nucleolus. Golgi complex is inconspicuous. Mitochondria are numerous and distributed in the cytoplasm. The high amount of smooth endoplasmic reticulum is seen in the cytoplasm. Pregnant bat shows spherical nucleus, mitochondria are seen in large number

of various sizes. No rough endoplasmic reticulum is seen but smooth endoplasmic reticulum is seen in the cytoplasm. The zona glomerulosa is more developed during pregnancy than the estrus, supporting our observations.

In *M. lyra lyra* (Sonwane, 2010), during estrus zona glomerulosa is less developed as compared to pregnancy and lactation. Zona glomerulosa shows the presence of stacks of golgi in the form of small vesicles. Mitochondria are with lamellar cristae. Smooth endoplasmic reticulum is in the form of small tubules and free ribosomes are observed in the cytoplasm. At an early stage, the zona glomerulosa is extensively developed. All the cell organelles are distinct and extensively developed. Smooth endoplasmic reticulum, golgi complex and vesicular mitochondria were observed. Lipid droplets are increase in size. Lysosomal bodies are seen in the cytoplasm of cell. These observations support the present observations.

The zona fasciculata during estrus constituted the major portion of the adrenal cortex and contain cells larger than those of the outer zone. The nuclei are spherical to oval in shape with slight indentation. A thin rim of chromatin material is attached to the inner part of the nucleus. Chromatin clumps are scattered throughout the nucleoplasm. The nucleoplasm shows the presence of nucleoli. Nuclear pores are seen. The cytoplasm is more vacuolated and contains several cell organelles. The smooth endoplasmic reticulum is in the form of small circular vesicle and distributed throughout the cytoplasm. The rough endoplasmic reticulum is rare and there are numerous free ribosome observed throughout the cell cytoplasm. The lipid droplets are abundant and usually appear as large vacuole. The golgi network is extensive. The numbers of mitochondria are more, as compared to zona glomerulosa and are uniformly distributed throughout the cytoplasm. These are circular in shape with lamellar cristae and granular matrix. Few lysosomes are seen in the cytoplasm.

Cells of zona fasciculata during early pregnancy are large, vacuolated and arranged in cords of polygonal cells. The nucleus is irregular with chromatin material attached to the inner part of nuclear membrane and also seen scattered in the nucleoplasm. Mitochondria are circular to elongated in shape and randomly distributed in the cytoplasm. Golgi bodies are observed in cytoplasmic matrix. The cells of zona fasciculata show tubular profile of smooth endoplasmic reticulum in the cytoplasm. Lipid droplets are large in size and are abundant in this zone. The lipid droplets are observed in close association with smooth endoplasmic reticulum and mitochondria suggesting the role of these organelles in steroidogenic function.

The most striking feature of cytology of zona fasciculata during late pregnancy is the development of smooth endoplasmic reticulum and condenses of lipid droplets. The cells of zona fasciculata are polygonal. Plasma

membrane does not show the cellular junction. The nucleus is spherical, large with chromatin clumping. The nucleolus is present toward the periphery of the nucleus. Mitochondria are spherical to oval in shape. Golgi complex is inconspicuous. Lipid droplets are observed in close association with mitochondria. Lysosomal bodies are seen in these cells. The ultrastructure of the adrenal gland of non-pregnant female bat and pregnant female bat, *Hipposideros lankadiva* (Seraphim, 2004) shows striking difference in cortical region of adrenal gland. The zona fasciculata is more developed in the pregnant female bat than the non pregnant adult female bat. The cells of zona fasciculata of non-pregnant bat show presence of vesicular smooth endoplasmic reticulum, numerous spherical mitochondria with vesicular cristae and lipid droplets indicating that cells are synthesizing steroid hormones.

Zona fasciculata of pregnant female bat shows presence of well developed golgi network, vesicular cisternae of smooth endoplasmic reticulum, mitochondria with vesicular cristae and numerous lipid droplets. These ultrastructural features indicate that there is an increase in the rate of steroid synthesis in the cells of zona fasciculata during pregnancy, supporting the present observations. Ultrastructural characteristics of mammalian adrenal gland suggest that the fasciculata is the main engine of steroid hormone synthesis (Beloni et al., 1987; Vinson, 2002) and granulosa is the site of cell proliferation, recruitment, differentiation and aldosterone, biosynthesis and secretion (Zoncanoro et al., 1997).

In *T. longimanus* (Nerkar, 2012), zona fasciculata is well developed during estrus. The mitochondria have vesicular cristae. Tubular profile of smooth endoplasmic reticulum is scattered throughout the cytoplasm. Lipid droplets are more in number than zona glomerulosa. During pregnancy, cells are hypertrophied with pleomorphic mitochondria. Smooth endoplasmic reticulum is observed in the form of network. Ultrastructural observations on the adrenal gland in this species of female bat are in well conformity with its functional role of steroid biosynthesis. The increase in the weight of adrenal gland during pregnancy confirms the more synthetic activity during this period. Similar observation were reported in *H. lankadiva* (Seraphim, 2004) and *T. longimanus* (Nerkar and Gadegone, 2009).

Zona reticularis is the inner most zone. During estrus, its cells are small and form cords which appear to intertwine in an anatomizing network. Polygonal cells have homogenous cytoplasm and spherical nucleus. The chromatin material is attached to the inner surface of nuclear membrane. Nucleolus is distinctly marked. Lipid droplets are present in the cytoplasm. Mitochondria are spherical in shape and seen throughout the cytoplasm. Prominent smooth endoplasmic reticulum, small golgi apparatus is also observed in the cell cytoplasm. Numerous free ribosomes are also seen.

The cells of zona reticularis during early pregnancy are

polyhedral having spherical nuclei with one or two well developed nucleoli. The plasma membrane is smooth and at places shows localized thickening probably giving rise to junctional complex. The cells are loaded with lipid droplets. The mitochondria are spherical in shape with collapsed cristae. The zona reticularis cells are in close association with blood vessels. Few lysosomal bodies are seen in the cytoplasm of the cells. The cells of zona reticularis during late pregnancy are polygonal having spherical nuclei. A thin rim of chromatin material attached to the nuclear membrane. Large number of spherical mitochondria is seen in the matrix. Lipid droplets are few in this stage. Golgi bodies are well developed and juxtannuclear in position.

The cells of zona reticularis is distinguished by their richness of rounded mitochondria with electron dense tubular cristae, smooth endoplasmic reticulum, lysosomes and lipid droplets with varying sizes. Their nuclei are spherical or ovoid in shape containing condensed heterochromatin, and prominent nucleoli, widened and clear blood sinusoids.

In *M. lyra lyra* (Sonwane, 2010), zona reticularis during estrus show large number of small size lipid droplets. Mitochondria are circular and more in number with lamellar cristae. Smooth endoplasmic reticulum is well developed. During pregnancy, zona reticularis is hypertrophied and all the cell organelles are well developed. The present observations are in conformity with the observations reported on the adrenal gland of *T. kachhensis* in the present study. The present observations clearly suggest that the adrenocortical zone of bat *T. kachhensis* are more developed during pregnancy than the non-pregnant stage. This might be due to the more steroid needed to cope up with the stress during pregnancy. Further, among the cortical zone, the zona fasciculata and zona reticularis are more prominently developed than zona glomerulosa. This might be due to less mineralcorticoid needed during the different reproductive period. The adrenal medulla is the core of the adrenal gland and is surrounded by the adrenal cortex. It secretes approximately 20% nor-epinephrine and 80% epinephrine (Dunn et al., 2011). The chromaffin cells of the medulla, named for their characteristic brown staining with chromic acid salts, are the body's main source of the circulating catecholamines adrenaline (epinephrine) and noradrenalin (norepinephrine).

The ultrastructural studies of medulla of female bat during estrus in this species show two types of cells which are distinguished by their nuclear shape and volume of secretory granules. Type I cell shows large circular nucleus with secretory granules and are less electron dense, which are separated from the surrounding membrane by an electron lucent space. Type II cell shows irregular nucleus and the secretory granules are electron dense. The distinguished feature of the medullary cells is the chromaffin granules which appear as a membrane bound body of variable electron density.

Some cell contains predominantly dense black granules, while adjacent cells show scattered empty vesicle with small amount of granular material.

Medulla is well developed during early pregnancy. Chromaffin cells are surrounded by blood capillaries. Mitochondria are hypertrophied and distributed throughout the cytoplasm. Well developed golgi complex is seen in the cytoplasm. Rough endoplasmic reticulum is well developed, during late pregnancy than the early pregnancy. Chromaffin cells of medulla contain mostly Type I cells that is, nor-epinephrine cells. Secretory granules are more in number and are uniformly distributed through the cytoplasm. Golgi apparatus is well developed. Mitochondria are spherical to elongated in shaped, with collapsed cristae. Rough endoplasmic reticulum is seen in the form of elongated tubular cisternae.

The present study suggests that two types of cells are present in *T. kachhensis*, similar to that observed in *T. longimanus* (Nerkar, 2012) and *M. lyra lyra* (Sonwane, 2010).

Conclusion

The adrenal cortex of *T. kachhensis* is differentiated in to three zones including, zona glomerulosa, zona fasciculata and zona reticularis. The adrenal gland is well developed during pregnancy than estrus. Cortical cells are well equipped with cell organelles required for steroidogenesis. Thus it is suggested that the adrenal cortex of *T. kachhensis* is responsible for the production of glucocorticoids. The medullary cells of adrenal gland are loaded with chromaffin granules (epinephrine and nor-epinephrine) during different phases of reproductive cycle. The medullary secretion may mobilize the glucose and fatty acid for energy production and prepare the heart, lung and muscles of the bat against acute and chronic stress during estrus, pregnancy and lactation. Thus present study demonstrates that all the endocrine play a vital role during various phases of reproductive cycle and also maintain the internal body conditions in accordance with the reproductive cycle.

Conflict of Interests

The author(s) have not declared any conflict of interests.

REFERENCES

- Belloni AS, Mazzocchi G, Mantero F, Nussdorfer GG (1987). The human adrenal cortex: Ultrastructure and baseline Morphometric data. *Submicrosc. Cytol.* 19(4):657-68.
- Burrow GN (1991). The thyroid gland and reproduction. In: SC Yen, RB Jaffe (eds.), *Reproductive Endocrinology*, 3rd edn. WB Saunders, Philadelphia. pp. 555–575.
- Charmandari E, Constantine T, Chrousos G (2005). Endocrinology of the stress response. *Ann. Rev. Physiol.* 67: 259-284.
- Dunn RB, Kudrath W, Passo SS, Wilson LB (2011). "10". *Kaplan Usmle Step 1. Physiol. Lec. Notes* 263–289. (<http://www.vivo.colostate.edu/hbooks/pathphys/endocrine/adrenal/m edhormones.html> date 29/03/2012).
- Nerkar AA (2009). Histoarchitectural alterations in the adrenal gland of the female Emballonurid bat, *Taphozous longimanus* (Hardwicke) during the reproductive cycle. *J. Cell Tissue Res.* 9(3):2005-2011.
- Nerkar AA, Gadegone MM (2012). Fine structure of adrenal cortex in the Indian sheath- tailed bat *Taphozous longimanus* (Hardwicke) during the reproductive cycle. *Pharm. Biol. Sci.* 3(3):9-13.
- Planel H, Guilhem A, Soleihavoup JP (1961). Le cycle annuel du cortex surrenal d'un semihibernant *Miniopterus schreibersii*. *C. r. Assoc. Anat.* 47:620-633
- Rivier C, Rivier J, Vale W (1986). Stress-induced inhibition of reproductive functions: Role of endogenous corticotropin-releasing factor. *Science* 232:607-609.
- Saidapur S K, Nadkarni V B (1976). Histochemical observations on the adrenal gland of bat *Vesperugo pipistrellus* (Dobson). *Endocrinology* 67(2):244-7
- Seraphim ER (2004). Endocrine Interaction during different phases of the Female Reproductive Cycle in *Hipposideros lankadiva* (Kelaart), Ph. D. thesis, RTM Nagpur University, Nagpur.
- Sonwane DP (2010). Endocrine Regulation of Reproduction in the Indian Female Vampire Bat *Megaderma lyra lyra* (Geoffroy). Ph.D. thesis submitted to Rashtra sant Tukdoji Maharaj, Nagpur University, Nagpur, Maharashtra, India.
- Vinson GP (2002). Adrenocortical zonation and ACTH. *Microscopy Res. Tech.* 61(3):227-239.
- Zoncanoro C, Malatesta M, Vogel P, Fakan S (1997). Ultrastructure of the adrenal cortex of hibernating, aurosing and euthermic dormouse, *Muscardinus avellanarius*. *I.* 249(3):359-364.