

*Full Length Research Paper*

# Prospective study of ingestional hair dye poisoning in Northern India (Prohina)

P. K. Jain, Navneet Agarwal, Awadhesh Kr Sharma\* and Asif Akhtar

Department of Medicine, M. L. B. Medical College, Jhansi (U.P.) – 284128, India.

Accepted 23 November, 2010

**Hair dye (paraphenylene di-amine, PPD) poisoning has high morbidity and mortality and its incidence has increased dramatically in the past 4 years. A prospective study was planned to assess the clinical profile and outcome with different treatment approaches and mortality rate in patients with hair dye ingestion. The material comprised 1020 cases admitted in Medicine Department of MLB Medical College, Jhansi, U. P. from July 2004 to March 2009. Out of 1020 cases, 697 cases were of stone hair dye poisoning and 323 cases were of other branded hair dyes (powdered form containing less amount of paraphenylene diamine). Diagnosis was made solely on the basis of the history given by cases/attendant and symptoms of neck swelling, black colored urine and muscular pain. The cases were thoroughly studied for different complications (renal, hepatic and cardiac etc) and were treated accordingly. Out of 1020 cases studied, majority were females in the age group of 15 to 45 years (n=734) while the rest were males. A total of 161 (15.78%) cases expired during treatment. Neck swelling, respiratory distress and whole body muscular pain were most common symptoms at presentation, oliguria, chest pain, palpitation, presyncope/syncope, pain in abdomen, nausea with vomiting and dysphagia were other common symptoms. Paraphenylene diamine is highly toxic. Cases who consumed up to 10 gm of PPD usually survived if they are presented to hospital within 4 h of dye ingestion in whom proper management can be delivered in the form of i/v methyl prednisolone and other supportive care. Severe edema of face, neck and floor of mouth, renal failure and myocarditis were poor prognostic factors.**

**Key words:** Paraphenylene diamine, hair dye ingestion, rhabdomyolysis, myocarditis, angioneurotic edema, myoglobinuria, intravenous methyl prednisolone, hemoglobinurea.

## INTRODUCTION

Hair dye is available in several forms and the commonest cheap form is stone hair dye which is available in 20 gms pack. Other branded hair dyes like 'Godrej', Kesh kala, colour mate etc. are available in powder or liquid forms. It is used in hair dye formulation, photographic developers,

tyre cord industry, accelerating vulcanization, used with "Hinna" for dyeing hands and feet of women. The concentration of active substance that is, para phenyl diamine varies from 70 to 90% in stone hair dye and 2 to 10% in branded dyes which are used for giving black color to hair. The stone hair dye is extremely cheap and freely available, making it an attractive option for suicidal intent. It was reported that contact with PPD causes skin irritation, dermatitis, arthritis, asthma, conjunctivitis,

\*Corresponding author E-mail: [awakush@gmail.com](mailto:awakush@gmail.com).

chemosis, lacrimation, exophthalmos and even permanent blindness. Systemic toxicity occurs either by percutaneous exposure or oral ingestion.

The chemical used in hair dye is a derivative of para nitro-aniline and is called paraphenyl-diamine (PPD). It is brownish to black coloured solid which is partially soluble in water and easily soluble in hydrogen peroxide (H<sub>2</sub>O<sub>2</sub>). PPD is a good hydrogen donor and is metabolized by electron oxidation to an active radical by cytochrome P450 peroxidase to form a reactive benzoquinone diamine. This is further oxidized to a trimer known as Brandowaski's base, a compound reported to cause anaphylaxis as well as being strongly mutagenic.

Oral ingestion of PPD causes mainly two types of toxic effects: The first manifestation is angioneurotic edema presenting as rapid development of severe edema of face, neck, pharynx, tongue and larynx with respiratory distress sometimes requiring emergency tracheostomy. The time of onset of symptoms after ingestion was about 4 to 6 h and at the time of admission, majority of the patients are presented with acute angioneurotic edema of the head and neck and wooden hard swollen protruded tongue with swelling of pharynx and larynx, and these are typical diagnostic feature of acute hair dye poisoning (Figure 1). Initial insult is due to local irritation of the mucous membrane and the skin, causing intense edema. Experimentally, a characteristic edema of head and neck was produced by intraperitoneal injection of PPD HCl in rabbits and cats. Edema of the eyes may be very severe and may cause exophthalmos.

Muscle pain was the next most common presentation of hair dye poisoning following angioneurotic edema. Limbs are usually swollen, tender and stiff (Figure 3). Muscle pain typically occurs about 10 to 12 h after ingestion of hair dye. Acute hair dye poisoning leads to rhabdomyolysis and muscle necrosis.

Patients pass chocolate brown colour urine (Figures 2 and 4) which along with typical orofacial swelling is diagnostic of acute hair dye poisoning specially in those cases where history of dye ingestion is lacking. This chocolate brown colour of urine is due to the presence of myoglobin and hemoglobinuria. In the later phase, rhabdomyolysis and acute tubular necrosis supervene.

The myoglobin is released because of rhabdomyolysis and muscle necrosis which reach the renal tubules and clog them, leading to pathologic features of acute tubular necrosis responsible for oliguria and acute renal failure. Acute renal failure was seen as the late cause of death in acute hair dye poisoning cases. Tubular obstruction by myoglobin casts is regarded as the principal mechanism for producing ARF. ARF by rhabdomyolysis can be diagnosed apart from the history by the elevation of CPK

and aldolase levels in the blood. Both rhabdomyolysis and hemolysis can induce ARF particularly in hypovolemic or acidotic individuals. Myoglobinuric ARF complicates approximately 30% of cases of rhabdomyolysis. By the 2nd or 3rd day, patient develops oliguria. Vomiting, gastritis, hypertension, hypotension, vertigo, tremors, seizure, nasal regurgitation, myocarditis have all been reported.

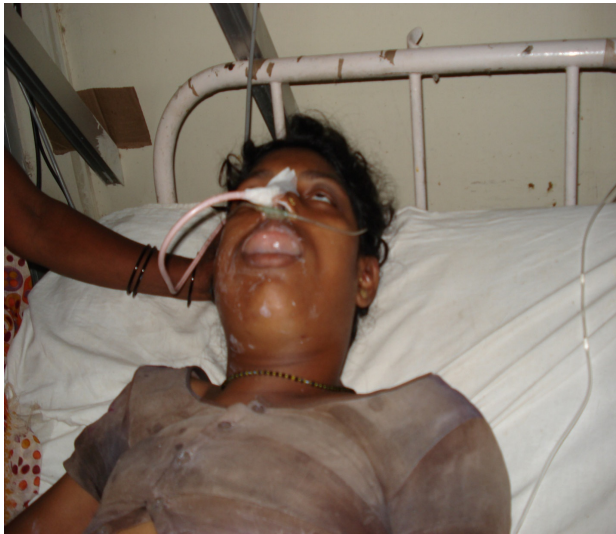### **Myocarditis due to hair dye ingestion**

Myocarditis is a dangerous complication of hair dye ingestion leading to decrease in blood pressure, arrhythmias, ventricular tachycardia and sudden death. The clinical features were fatigue, dyspnoea on exertion/rest, chest pain, palpitation, presyncope (feeling of giddiness, faintness) / syncope with non specific ECG changes in the form of sinus tachycardia, T wave inversion, ST segment elevation or depression, bundle branch blocks, atrial and ventricular premature complexes, atrial fibrillation and ventricular tachyarrhythmia (Figures 5 and 6). Cardiac biomarkers like Troponin T may be positive (more than 0.1 ng/ml was positive) in some cases. Transthoracic echocardiographic (TTE) showed regional wall motion abnormality and decreased left ventricular ejections fraction (LVEF≤35%) which subsequently improved on follow up. Cardiac dilatation in the absence of regional coronary artery disease and evidence of rapid recovery of ventricular function occur during follow up in some cases.

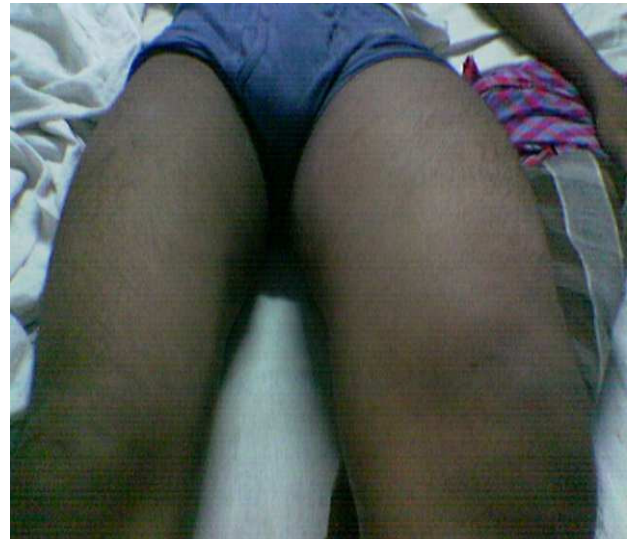Patients having suspicion of myocarditis as per ECG changes and clinical features had high mortality rate of around 3.62% and those who developed ventricular tachyarrhythmias had mortality rate of approximately 0.58%, despite standard medical management. Patients who were hemodynamically unstable that is, those with decreased blood pressure or shock (systolic BP < 90 mm of Hg) had mortality rate of around 4% and should be kept on vasopressures support. Cardiovascular that compromises because of ventricular tachycardia should promptly be treated with DC cardioversion followed by i/v amiodarone drip.

### **Lethal dose**

The lethal dose of para phenylene diamine is not well known although estimates vary from 7 gms and above. What is known is that the toxic effects of PPD are dose related. Lethal dose also depends upon individual susceptibility, death are also reported even at the dose of 2 gms.



**Figure 1.** A 26 years old girl with facial edema after hair dye ingestion.



**Figure 3.** A young male showing calf muscles edema after hair dye ingestion



**Figure 2.** Urine samples collected in plastic bottles showing cola coloured urine suggestive of myoglobinuria after hair dye.



**Figure 4.** Changing pattern of urine colour after hair dye ingestion as time passes. Bottles from right to left shows collected urine samples on day 1,2,3,4.

### Management plan

Supportive management is life saving if instituted early in course as little delay is disastrous leading to death. Diagnosis is easy to make but requires a higher degree of suspicion as clinical features are quite distinctive that is, oro-facial edema, chocolate brown urine and history of

PPD intake.

Till now, no definite guideline of management has been given, despite exhaustive literature search. As a result, we formulated our own line of management. After a quick clinical examination, special attention was given to vital parameters. As the immediate cause of death was

Electrocardiogram of Ramesh 26 years old male admitted with history of hair dye poisoning 6 h before

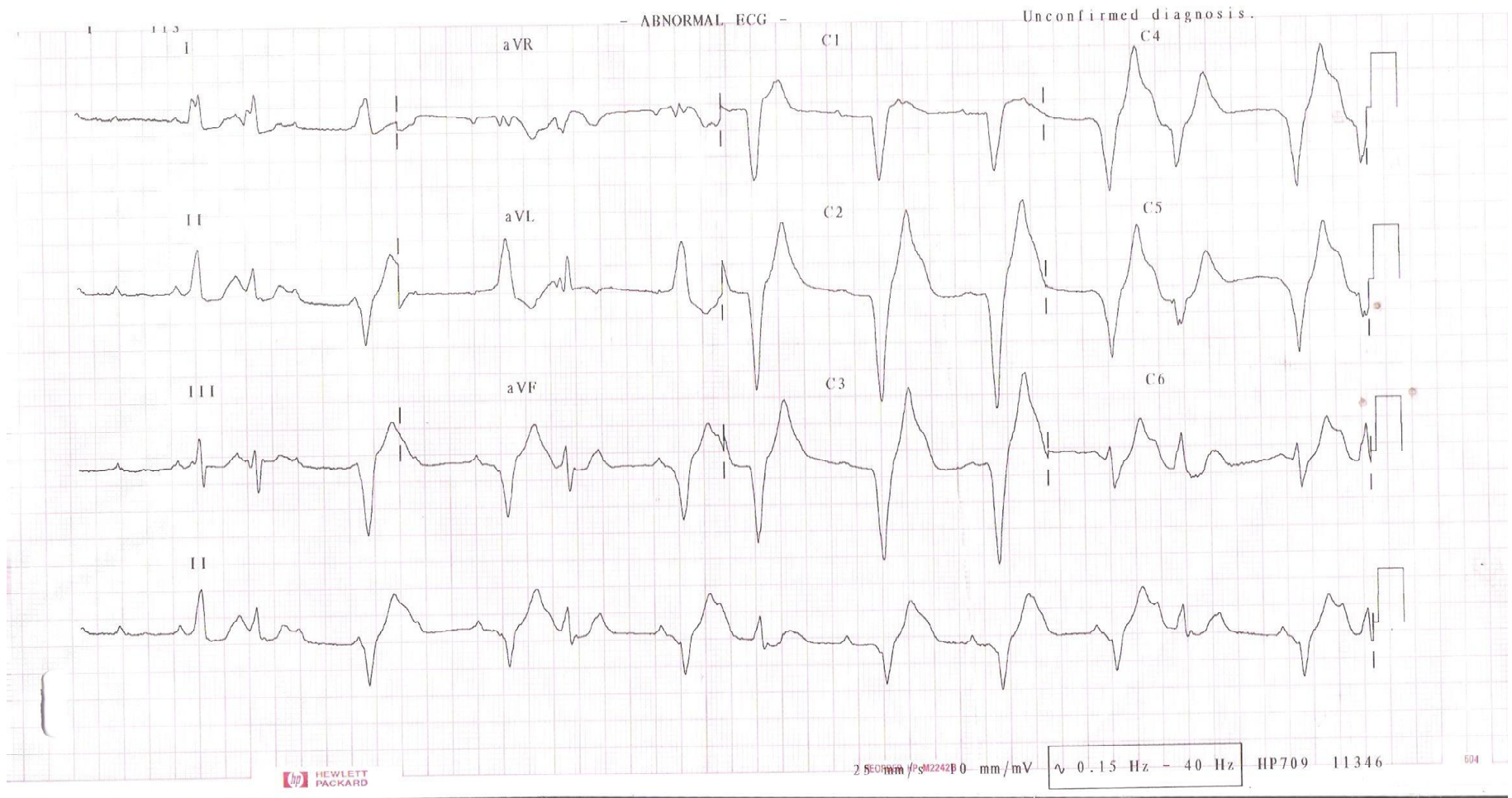
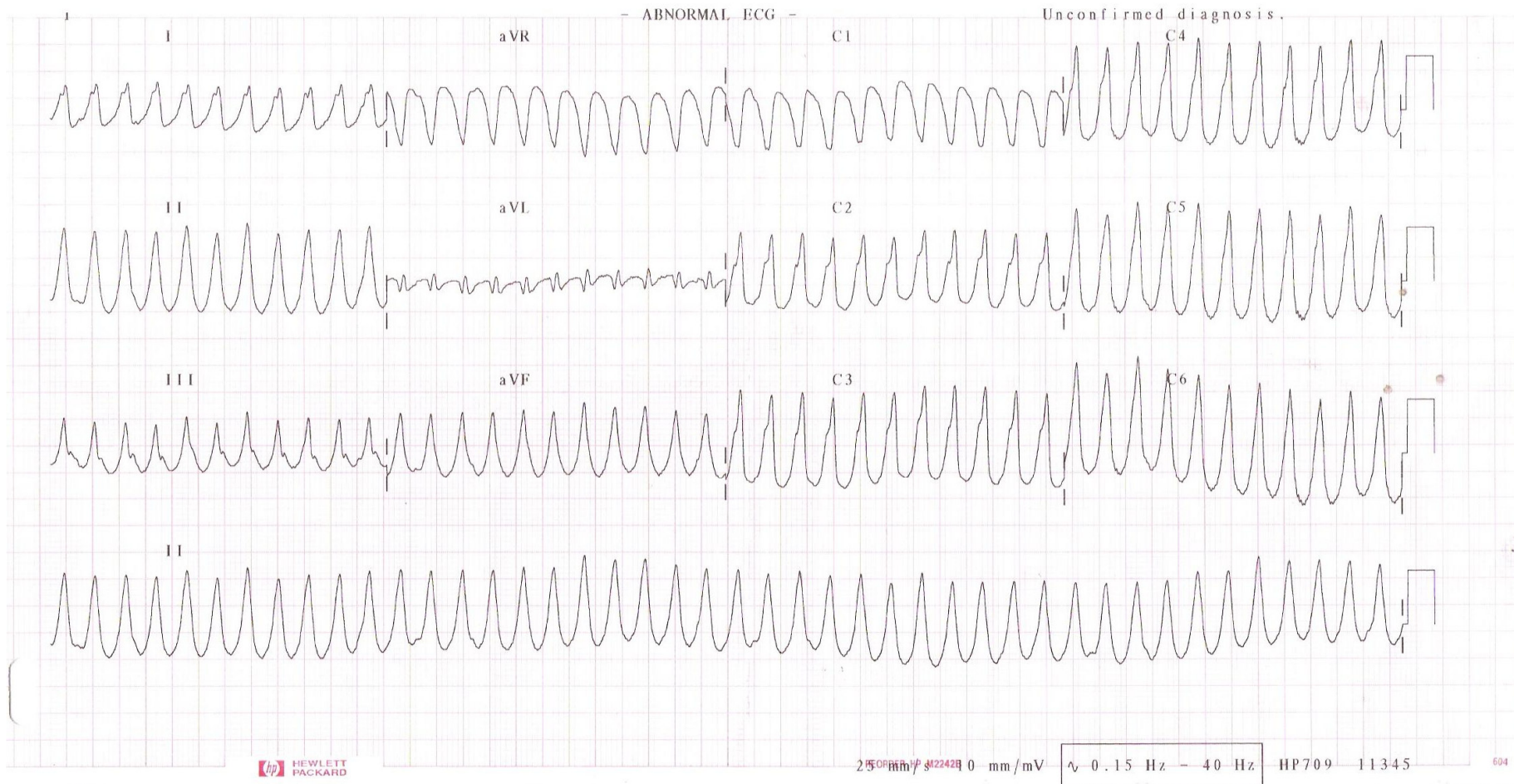


Figure 5. ECG of a patient showing non specific changes with frequent premature ventricular complexes suggestive of myocarditis after hair dye ingestion.

**Patient Preeti 28 yrs. old female admitted with history of hair dye poisoning landed up into ventricular tachycardia on the 5th day of hair dye poisoning.**



**Figure 6.** ECG of a patient showing ventricular tachycardia suggestive of myocarditis after hair dye ingestion.

**Table 1.** Design of the study.

Description of cases	No of cases
Cases excluded	363
Brought dead	67
Died with in 5 h	83
Mild/no symptoms	16
Not willing to part	41
Known cardiac/renal disease	5
Cases included in study after PPD ingestion	1020
Total	1383

Table 1 shows the design of the study. Total of 1383 cases were chosen, out of which 363 were excluded on different ground and final study comprised 1020 cases of PPD ingestion.

hypoxia, airway patency was maintained by Goodle's airway and emergency tracheostomy. Endotracheal intubation was not possible in majority of the cases because of massive angioedema.

Circulatory volume and pressure were maintained by giving appropriate fluid therapy. The treatment was based on the following principles:

1. Since no antidote is available against PPD, management was basically supportive.
2. Gastric lavage was done with activated charcoal and tap water.
3. Oxygen was administered for hypoxic cases proved by ABG analysis or in patients who have massive angioedema. Emergency tracheostomy, which is life saving is used to tackle hypoxia (immediate cause of death), as patient is in severe distress; and oral endotracheal intubation is not possible because of marked orofacial swelling.
4. Intravenous hydrocortisone (200 mg stat dose then 100 mg every 6 h) is used till angioneurotic edema subsides. This is the mainstay of treatment for angioneurotic edema which decreases mortality and morbidity later on. Now in the last 2 years we are using intravenous Methyl Prednisolone (1 gm/day as IV infusion for 5 days) which has shown promising results and leading to decreased morbidity and mortality as evidenced by early subsidence of angioneurotic edema. Although no randomized control trial has been done but it was noticed in a prospective study that it hastens recovery and decreases hospital stay.
5. Sodium bicarbonate was administered to prevent myoglobin precipitation in kidney (average dosage was 1 ampule containing 22.5 meq. in 500 ml normal saline

every 8 h) along with loop diuretics (furosemide or torsemide) to maintain adequate urine volume.

6. Chlorpheniramine maleate (one ampule IV every 8 h) was used till orofacial edema subsided (average 3-5 days).

7. Calcium gluconate was given to counteract hypocalcemia (10% calcium gluconate 10 ml every 8 h).

8. Vasopressors (intravenous Dopamine and/or noradrenaline) were used if hypotension persisted, despite adequate fluid therapy.

9. Dialysis- hemodialysis or peritoneal dialysis was used for cases with renal shut down and resistant hyperkalemia.

10. Intravenous amiodarone and defibrillation were used for ventricular tachyarrhythmia management.

## MATERIALS AND METHOD

Prospectively collected data of 1383 cases that ingested hair dye with suicidal intention were studied. The study comprised 1383 cases, 67 cases were brought dead in emergency that had history and features suggestive of hair dye poisoning. 83 cases died within first 5 h of admission after gastric lavage, drugs and I/V fluid therapy. These cases were excluded from the study because the aim of this study was to assess the clinical profile and outcome with different treatment approaches in patients with ingestional hair dye with suicidal intention. Out of 1233 remaining cases, 167 cases of dye ingestion did not have any feature of toxicity and were discharged or absconded in the first 12 h. 41 cases of hair dye ingestion who had relatively mild disease did not opt for investigations and those treated with I/V fluids and I/V antihistaminic were excluded from this study. 3 cases of known cardiac and 2 cases of known renal diseases were excluded from the study. Finally, the study comprised 1020 cases who were thoroughly investigated and treated (Table 1).

In 631 cases (61.86%) out of 1020 cases, ECG was done at 1<sup>st</sup> hour after admission because of symptoms suggestive of

**Table 2.** Distribution of cases according to age and sex.

Age group (years)	Male	Female	Total no.	Percentage
15-25	102	349	451	44.21
26-35	85	325	410	40.20
36-45	79	32	111	10.88
> 45	20	28	48	4.71
Total	286	734	1020	100.0

Table 2 shows the distribution of cases according to age and sex. Majority of the cases belong to young age group and were females.

myocarditis and then cardiac monitoring was done in ICCU.

It was realized later in the study that cases of stone hair dye that died suddenly were developing ventricular tachyarrhythmias.

Therefore in the later half of the study after admission in emergency ward cases were immediately shifted and managed in intensive care unit with cardiac monitoring because of sudden cardiac death due to ventricular tachyarrhythmias.

The reason for ingesting dye was mainly suicidal (96.64%). The remaining was accidental. The exact dose taken by each patient was not known.

The data were analyzed from the following points:

1. Demographic profile
2. Clinical profile
3. Morbidity and mortality pattern
4. Outcome with different management strategy given in the hospital.

## RESULTS

Of all the total cases collected in this study, 734 were females and 286 were males (Table 2).

The reason for ingesting drug was mainly suicidal (998 cases (97.84%). The remaining were accidental (19 cases (1.86%) and homicidal 3 (0.29%). Symptomatology was directly related to the dose of PPD ingested, type of hair dye (serious complication mainly occurs in stone hair dye that is indigenous brand), intensity of ingestion (suicidal intention was associated with worse prognosis) and the time lapse of swallowing (more worse complications if dye was kept for more time in oral cavity before ingestion).

Two types of presentations were seen: one, those in whom neck swelling occurred predominantly and others in whom myocarditis developed. It seems that patients who after putting the dye in the mouth thought whether to ingest or not developed prominent edema of throat; lower tongue jaw, eye lids, conjunctiva and neck may be due to more prolonged time of contact with oral-pharyngeal mucosa. While those who immediately swallowed

sufficient quantity of dye developed myocarditis and renal failure later on.

Severe edema of face, neck and tongue were present in 73.03% (n = 745) cases and lead to respiratory distress, hypoxia and dysphagia (Table 3).

Muscle pain was the next most common presentation seen in about 47.05% (n = 480) cases. Limbs were swollen, tender and stiff. In these patients PPD poisoning leads to rhabdomyolysis and muscle necrosis.

Dysphagia was present in most of the cases presenting with severe edema of face and neck (71.17%).

Nasal twang of speech was found in 59 cases (5.78%) while nasal regurgitation was observed in 25 cases (2.45%) only (Table 3).

Chest pain, palpitation and presyncope (the feeling of dizziness and fainting)/syncope were another common manifestations. These patients were at high risk of developing cardiac complication.

238 cases were having strong suspicion of myocarditis on the basis of clinical features and ECG changes. The clinical features were fatigue, dyspnoea on exertion/rest, chest pain, palpitation; presyncope/syncope with positive ECG changes seen in these cases were sinus tachycardia, T wave inversion, ST segment elevation or depression, bundle branch blocks, atrial and ventricular premature complexes, atrial fibrillation and 21 cases developed ventricular tachyarrhythmia during therapy. Troponin T was positive in 136 cases of positive ECG changes (more than 0.1 ng/ml was positive). Transthoracic echocardiographic (TTE) was done in 238 cases. The finding was regional wall motion abnormality and decreased left ventricular ejections fraction (LVEF $\leq$ 35%) in 126 cases on days 2-5 which subsequently improved on follow up. Cardiac dilatation in the absence of regional coronary artery disease and evidence of rapid recovery of ventricular function during follow up in 98 cases out of 238 cases were observed.

Patients developing suspicion of myocarditis as per ECG changes and clinical features were having high

**Table 3.** Distribution of cases according to clinical features.

S. No.	Symptoms/sign	No. of cases	Percentage
1	Severe edema of face and neck	745	73.03
2	Dysphagia	726	71.17
3	Chocolate brown colour urine	549	53.82
4	Pain /rigidity of limb	480	47.05
5	Respiratory difficulty	229	22.45
6	Tachycardia	214	20.98
7	Hypotension	149	14.61
8	Chest pain	141	13.82
9	Palpitation	139	13.63
	Decreased urine output	130	12.75
10	Anuria	46	4.51
	Oliguria	84	8.24
11	Rise in blood pressure	80	7.84
12	Nasal twang of voice	59	5.78
13	Presyncope / Syncope	47	4.61
14	Nasal regurgitation	25	2.45
15	Convulsion	23	2.25

**Table 4.** Distribution of cases according to serum creatinine level.

Serum creatinine (mg/dl)	No. of cases	Mortality	
		No.	Percentage
Normal (0.6 - 1.4)	759	79	10.41
1.5 - 3.0	102	21	20.59
3.1 - 4.5	39	7	23.07
4.6 - 6	37	11	29.72
6.1 - 7.5	48	20	41.67
>7.5	35	21	60

morbidity and mortality (67 out of 238 expired) and those who developed ventricular tachyarrhythmias 21(8.82%) were having further bad prognosis and 12 cases expired out of 21, despite standard medical management.

Chocolate brown colour urine was found in 549 (53.82%) cases especially in those cases that had marked orofacial swelling, limb edema and muscle tenderness. This chocolate brown colour of urine was due to the presence of myoglobin and hemoglobinuria which was detected by dip-stick test (Table 3).

Decreased urine output was found in 130 cases (12.74%), and 46 cases (4.51%) had anuria. Mortality was much higher in anuric cases (63.04%).

Albuminuria was observed in 376 cases (36.86%)

which were detected by dip-stick test. Albuminuria reflects impaired absorption and processing of filtered proteins by injured proximal tubules. Myoglobinuria (detected by dip-stick test) was present in 549 cases (53.82%) suggestive of rhabdomyolysis. Renal biopsy was done in 10 cases only which showed acute tubular necrosis in all the cases.

In this study, a total of 261 (25.58%) cases had increased blood urea and creatinine levels (Table 4). This increment was noticed on 2nd day onwards associated with oliguria or anuria in 130 cases. This increase in blood urea and creatinine was strongly associated with high level of CPK which is due to rhabdomyolysis.

549 cases (53.82%) showed raised serum CPK levels.



**Table 5.** Mortality according to time duration since admission after ingestion of PPD.

Time duration since admission	No. of cases expired	Percentage of expired cases
5 - 24 h	34	21.11
1 - 5 days	74	45.96
5 - 10 days	33	20.49
>10 days	20	12.42
Total	161	15.78

Table 5 shows that in 1020 pts 161(15.78%) died during treatment inspite of best efforts, out of which maximum number of cases died during 1-5 days, that is, 74(45.96%).

**Table 6.** Total mortality after ingestion of PPD

Clinical status of pts	No. of cases	Percentage
Brought dead	67	21.54
Brought live		
0-5 h	83	26.68
>5 h	161	51.76
Total	311	22.48

Table 6 shows that in 1383 pts total of 311(22.48%) died after Hair dye ingestion. In which 161(15.78%) died during treatment inspite of best efforts which were included in study. While 67 cases that is, 21.54% brought dead at emergency & 83cases ie 26.68% died within 5hrs of admission, which were excluded from study.

Maximum value of serum CPK level was reported as 281,000 IU/L. This raised CPK level was associated with rhabdomyolysis in cases with chocolate brown coloured urine and having stiff and tender limbs.

Total 137 cases (13.43%) showed hyperkalemia during their hospital course. 62 cases (6.08%) had serum potassium in the range of 5.5 to 6.0 meq/L, 51 cases were in the range of 6.0 to 6.5 meq/L and 24 cases in the range of >6.5 meq/L. The mortality was 62.50% in cases with serum, K<sup>+</sup> >6.5 meq/L despite medical management and dialysis, while it was only 27.42% in cases who had serum K<sup>+</sup> in range of 5.5 to 6.0 meq/L.

A total of 88 cases (8.62%) of hair dye poisoning needed dialysis during their hospital course. 50 cases were hemodialysed out of which 12 cases (24%) died. Peritoneal dialysis was done in 38 cases and 25 patients (65.79%) died. Cases in which dialysis was indicated, hemodialysis showed good results as compared to peritoneal dialysis. A total of 392 cases (38.43%) showed hypocalcemia. A total of 68 cases had marked hypocalcemia (Serum calcium <6 mg%) and it was observed that 21 cases (30.88%) out of these severely hypocalcemic cases (n=68) developed classic features of hypocalcemic tetany along with seizures.

Serum bilirubin was raised in 62 cases whereas SGOT/SGPT was raised in a large number of cases that is, 685 cases (67.16%). It appears that increase in SGOT/SGPT was indicative primarily of muscle injury and not liver necrosis. It was observed that SGOT was higher as compared to SGPT. In 206 cases SGOT levels were >1000 IU/L. A total 161 cases (15.78 %) died after consuming hair dye poison (Table 5). While total mortality after ingestion of PPD was 311 cases that is, 22.48% including those patients who were brought dead in emergency and those who died within 5 h of treatment initiation (Table 6).

A pilot study done in department revealed that 5 days duration of injected methyl prednisolon produced optimum results; the duration of steroid was guided primarily by oro-facial edema, swallowing difficulty and change in colour of urine. The morbidity and mortality decreased significantly from 27.77 to 14.02% (Table 7).

## DISCUSSION

The present study showed that hair dye poisoning is more common among females (74.86%) and younger

**Table 7.** Decrement in mortality after use of i/v methyl prednisolone.

IV Corticosteroid	Duration of treatment (Days)	No. of Patients	Disappearances of edema (Days)	No. of death	Mortality (%)
Hydrocortisone (300 mg/d)	7	300	8 ± 2	83/300	27.77
Methyl prednisolone (1 mg/d)	5	720	4 ± 1	101/720	14.02

Table 7 shows that in 300 pts treated with i/v hydro cortisone 83 cases (22.48%) died after consuming hair dye poison. While after use of i/v methyl prednisolone in 720 cases only 101 cases (14.02%) died.

age group of 15 to 25 years (44.21%); maximum number of cases (97.84%) was of suicidal intent and mortality rate was 22.48%.

Ayoub and Liham (2006) in eleven years (1992 to 2002) study of over 374 cases showed female preponderance (77%) with the majority of poisoning being intentional (78.1%) and their population was also young (15 to 35 years old age groups accounting for 69.5%). 21.1% of poisoning cases was fatal and the source / route of poisoning was by ingestion (93%).

Clinical features in the present study were typical orofacial edema (73.03%), dysphagia (71.17%), chocolate brown color urine (52.82%) pain and or rigidity and stiffness of limbs (47.05%), respiratory difficulty (22.45%), hypotension (14.61%), decreased urine output (12.75%), increased BP (7.84%) and convulsion (2.06%) comparable to the study by Kallel et al. (2005) whose cases were dominated by cervicofacial edema (79%), chocolate brown coloured urine (74%), upper airway tract edema (68.4%), oliguria (36.8%), muscular edema (26.3%) and shock (26.3%).

In the present study, renal failure was observed in 261 (25.88%) cases with 130 cases (12.75%) showing anuria or oliguria. Anuria showed a poor prognosis with more electrolyte disturbances, 10 cases showed acute tubular necrosis on biopsy. In the earliest report of PPD intoxication from India two cases had renal biopsy proven acute tubular necrosis by Chugh et al. (1982).

Sumeet et al. (2005) reported a case of PPD poisoning with characteristic features and biopsy proven ATN with oliguria.

Very few cases of myocardial damage have been reported due to PPD intoxication. Zeggwagh et al. (2003) reported TTE proven case of myocarditis with left ventricular apical thrombus. The finding of thrombus was not observed in our cases.

Brahmi et al. (2006) reported a case of myocarditis with myocardial infarction induced by PPD which was confirmed by angiography that showed septoapical hypokinesia due to spasm of the anterior interventricular coronary artery. Jatav et al. (2008) reported a case of

myocardial damage in hair dye poisoning with similar findings.

In present study, clinical manifestations of acute myocarditis ranged from asymptomatic to fatal. ECG features such as multiple ventricular and supraventricular ectopics, ST-T wave changes, bundle branch blocks, ventricular tachyarrhythmias, positive troponin-T and decreased left ventricular ejection fraction (< 35%) and regional wall motion abnormality in large number of cases with subsequent improvement in LVEF further support the cardiac myolysis .

## Conclusion

Hair dye is available in several forms and the commonest cheap form is stone hair dye which is available in 20 gms pack. In northern India especially in Bundelkhand Region, peoples are using it for suicide in recent years. Poisoning was more common in female (M:F=0.86) and in younger age group (15 to 25 years). Maximum number of cases (97.98%) was of suicidal intent. Overall mortality rate after ingestion of PPD was 22.48%. Route of poisoning was ingestional in all cases of acute hair dye poisoning. Time elapsed in seeking hospital admission and early management influenced the mortality and morbidity. Early clinical diagnosis and interventions are the cornerstone of management. Respiratory failure mainly determined the short term prognosis, whereas long term prognosis was affected by the importance of muscular and renal damage. Good results of IV methyl-prednisolone in cases with marked cervicofacial oedema were seen in this study. It reduced oedema markedly and improved associated respiratory distress. Preventing renal failure was a very important goal in systemic PPD intoxication, since its occurrence was associated with high mortality and an increase in ICU stay. Prevention was based on abundant fluid infusion, alkalization of urine and the correction of the hemodynamic disturbances. Preventing renal failure was a very important goal in systemic PPD intoxication, since its occurrence was associated with

high mortality and an increase in ICU stay. The use of intravenous corticosteroids and antihistamines appears to be logical and life saving but further randomized control trials is needed to show the efficacy of this approach. It is important that medical fraternity should be aware of this poison because the poison is available quite freely and used extensively. Diagnosis requires a high degree of suspicion, as the clinical features are quite distinctive. Immediate ban of the sale of local unauthorized stone hair dye in whole of the Northern India and nearby areas, prohibition of PPD importation and its pure sale in combination with other dye along with the regulation of its industrial use is urgent, so that PPD should be used for “dyeing and not for dying”.

#### REFERENCES

- Ayoub F, Liham S (2006). A retrospective study of acute systemic poisoning of paraphenylenediamine in Morocco. *Afr. J. Trad. CAM*, 3(1): 142-149.
- Brahmi N, Kouraichi M, Blel Y, Mourali S, Thabet H, Mechmeche R, Amamou M (2006). Acute myocarditis and myocardial infarction induced by paraphenylene diamine interest of angiography. *Int. J. Cardiol.*, p. 113.
- Chugh KS, Malik GH, Singhal PC (1982). Acute renal failure following paraphenylenediamine (hair dye) poisoning report of two cases. *J. Med.* 13: 131-137.
- Jatav OP, Jeelima Singh, Gupta RJ, Tailor ML (2008). Myocardial damage in hair dye poisoning. *J. Assoc. Physicians India*, 56: 463-464.
- Kallel H, Chelly H, Dammak H, Bahloul M, Ksibi H (2005). Clinical manifestations of systemic paraphenylene diamine intoxication. *J. Nephrol.*, 18(3): 308-311.
- Nott HW (1924). Case report of hair dye poisoning in a hairdresser. *BMJ*, 1(321): 421-422.
- Sumeet S, Sanjeev M, Lal AK, Pulin G, Agarwal AK (2005). Paraphenylenediamine (PPD) poisoning. *J. IACM*, 6(3): 236-238.
- Zeggwagh AA, Abouqcal R, Abidi K, Madani K, Zekraui A, Karkeb O (2003). Left ventricular thrombus and myocarditis induced by PPD poisoning. *Ann. Fr. Anesth. Reanim.* (ISSN : 0750-7658) 22: 639-641.