

Full Length Research Paper

Histological characterization of wound healing of flank verses midline ovariohysterectomy in different age groups of cats

Faisal ayub kiani, Allah Bux Kachiwal, Muhammad Ghiasuddin Shah, Muhammad Shoaib Khan, Ghulam Murtaza Lochi, Abdul Manan, Israr ul HaQ and Faiz Muhammad khan

Sindh Agriculture University Tandojam, Pakistan

Received 18 December, 2013; Accepted 27 February, 2014

The study was carried out to determine the histological characterizations of wound healing in cats. For the purpose, 24 feral/stray with mean age of 7 to 33 months and body weight between 1.72 to 4.02 kg cats were selected and divided in 4 subgroups. Ovariohysterectomy was performed in all the cats. The cats operated through flank approach healed earlier and histological characterization showed better wound healing through flank in adult cats. All the cats did not heal on the 12th day, and the trend of healing showed bit maturation. Parameters studied are histological characterization of wound healing were acute inflammation, chronic inflammation, granulation tissue amount, granulation tissue amount and fibroblast maturation, collagen deposition, re-epithelization and neovascularization.

Key words: Cats, ovariohysterectomy, flank, midline, healing.

INTRODUCTION

Ovariohysterectomy is a surgical procedure to remove the uterus along with the ovaries which is adopted as one means of population control in cats (Levy et al., 2003). It is commonly carried out either through midline coeliotomy or through flank laparotomy.

Over population of feral and stray cats is a major problem over the years throughout the world (Bloomberg, 1996). The signs of estrus in small animals are the major reasons for pet owners to seek veterinary advice. Suppression of estrus is frequently required in order to avoid vaginal bleeding, attraction of males, behavioral changes and undesired mating (Valle and Junior, 1999).

Surgical wound healing is a highly regulated process of cellular, humoral, and molecular events activated at the time of acute injury as stated by Clark (1993). Knowledge

of the histologic features of this process is of great importance to our understanding of the mechanisms behind successful versus unsuccessful surgical outcomes. An efficient scoring system should be allow for standardized reporting on histologic findings following any surgical intervention (Abramov et al., 2007).

Morphologic changes in the endothelium after wounding have been studied in cats (Horn et al., 1977; Ogita et al., 1981; Ling et al., 1988) and in dogs (Befanis et al., 1981). Functional disturbances have been less well characterized, with endothelial barrier function during healing of severe wounds (Ota, 1975; Sawa et al., 1983). In order to better characterize endothelial function during healing, endothelial permeability after endothelial wounding was measured (Horn et al., 1977).

*Corresponding author. E-mail: Kiani4vet@yahoo.com.

Author(s) agree that this article remain permanently open access under the terms of the [Creative Commons Attribution License 4.0 International License](http://creativecommons.org/licenses/by/4.0/)

Basal cells in stratified epithelial tissues are intimately associated with the basement membrane, a thin acellular layer that separates the epithelium from the connective tissue. The basement membrane is a dense network of complex macromolecules including collagens, proteoglycans, laminins, vitronectin, fibronectin and hyaluronic acids (Kleinman et al., 1993; Kuhn, 1994; Marinkovich et al., 1993; Timpl, 1996; Uitto and Pulkkinen, 1996). However, basement membrane proteins are now considered to be involved in the regulation of a variety of epithelial cell processes such as migration, proliferation, differentiation and adhesion (Zieske et al., 1994).

Impaired wound healing is a common clinical problem, which is a consequence of disordered collagen formation and underlying predisposing conditions (Gohel et al., 2005). A weak scar may result from a large number of local or systemic factors (Cotran et al., 1999). Wound healing in the skin illustrates the general principles of healing that apply to all tissues and provides excellent models to study the factors that modulate the healing process. Whether a wound heals by primary or secondary intention is determined by the nature of the wound rather than by the healing process itself (Cotran et al., 1999).

The only differences are quantitative not qualitative (Walter and Israel, 1987). Collagen the most abundant protein in the body plays a critical role in the successful completion of wound healing. Type I collagen is the major component of extra cellular matrix in skin. Type III, which is also normally present in skin, becomes more prominent and important during the repair process. Individual changes that take place with regard to individual collagen fibrils include increased diameter, increased interfibril binding, and rearrangement of fibrils with time and become more organized in a manner that maximizes strength (Baum et al., 2005; Edward, 1958).

The orderly collagen formation at different stages of wound healing at different days can be seen microscopically by both routine Haematoxylin and Eosin and Masson's Trichrome stained sections (Mustafa, 1997). In Masson's Trichrome stain, old collagen fibres take deep blue colour and the new collagen fibres stain light blue, represents mature or early collagen. Microscopically, collagen fibre orientation, its different pattern, variable amount of early and mature collagen (Figure 6), as well as presence or absence of inflammatory cells, granulation tissue and its amount are also observed. Based on these histological parameters, actual healing state of a wound can be identified. Clinically wound healing of skin in maxillofacial region occurs by 3 to 5 days (Watkinson et al., 2000) and in oral cavity, mucosal wound healing occurs by 5 to 7 days (Gordon et al. (1987). From day 3 onwards, the quantitative increase in collagen synthesis occurs and continues up to early 2nd week. According to Cotran et al. (1999), quantitative increase in collagen synthesis ends in 10 days. And as in 9 or 10th day the wound is moderately well healed and much greater proportion of tensile strength required and then become progressively stronger. So, tissue specimen

at the 7th day of wound healing can provide a fair histological estimation of the process. For these reason, intention of the present study is to evaluate the histological state of wound healing in postoperative cases of abdominal wounds with or without risk factors after collecting the surgical tissue specimen at 0, 4, 8 and 12th day after the surgery in cats, using a modified histologic scoring system.

MATERIALS AND METHODS

Ovariohysterectomy was performed in 24 intact feral/stray cats with mean age of 7 to 33 months and body weight between 1.72 to 4.02 kg procured from Tandojam and kept in Indoor Patient Ward, Department of Surgery and Obstetrics, Sindh Agriculture University, Tandojam. Cats were kept in the department one month before surgical procedure in order to adopt familiarize with the surroundings.

Cats were randomly assigned into different groups based on age for ovariohysterectomy, that is, Group-F (Flank approach) and Group-M (Midline approach), placing 12 cats in each group. Both groups were being further subdivided into two subgroups, each comprising of 6 cats, on the basis of age to determine the efficient wound healing in both approaches. The subgroups "Fy" and "My" had young cats, while the second subgroup, that is, "Fa" and "Ma" had adult cats. Thus, there were a total of four groups which were named as Fy, My, Fa, Ma (Table 1). Flank ovariohysterectomy was performed as suggested by (Shuttleworth and Symthe, 2000) and midline ovariohysterectomy was performed as described by Fingland (1998). In order to evaluate the better and faster wound healing for ovariohysterectomy in different age groups of cats various parameters of histological characterization of wound healing (acute inflammation, chronic inflammation, granulation tissue amount, granulation tissue and fibroblast maturation, collagen deposition, re-epithelization and neovascularization) were determined.

Anaesthetic protocol

Cats were pre-anesthetized with acepromazine at recommended dose of 0.2 mg/kg body weight and diazepam at dose of 0.5 mg/kg body weight. Cats were anesthetized with ketamine HCL at recommended dose of (10 mg/kg, body weight i/m) as suggested by Howe (1997).

Excision of tissue sample

The abdominal skin was prepared with pyodine-iodine 70% solution. Unilateral standardized 6 mm full-thickness circular segments were excised from the abdominal skin using a dermatologic biopsy punch from the site of incision on day 0, 4, 8 and then same sized piece of healed surgical wound tissue was removed from cats on day 12 post-surgery. The removed tissues were processed and stained with Hematoxylin-Eosin (H&E). Wound healing was evaluated through histological scoring method as described by Greenhalgh et al. (1990) and Abramov et al. (2007). At each time, the wounds were harvested, and their histologic features were assessed in paraffin-embedded sections using H&E stains at a magnification of 10 to 40x. All specimens were evaluated separately by pathologists. The main histologic outcome measures included the amount of acute and chronic inflammatory infiltrates, the amount and maturation of granulation tissue, collagen deposition, re-epithelialization, and neovascularization. A modified

Table 1. Experimental design.

Group	Approach	Sub group	Cat
F	Flank	Fy	Fy1, Fy2, Fy3, Fy4, Fy5, Fy6
		Fa	Fa1, Fa2, Fa3, Fa4, Fa5, Fa6
M	Midline	My	My1, My2, My3, My4, My5, My6
		Ma	Ma1, Ma2, Ma3, Ma4, Ma5, Ma6

Fy, Young queens that were approached through flank; My, young queens that were approached through midline; Fa, adult queens that were approached through flank; Ma, adult queens that were approached through midline.

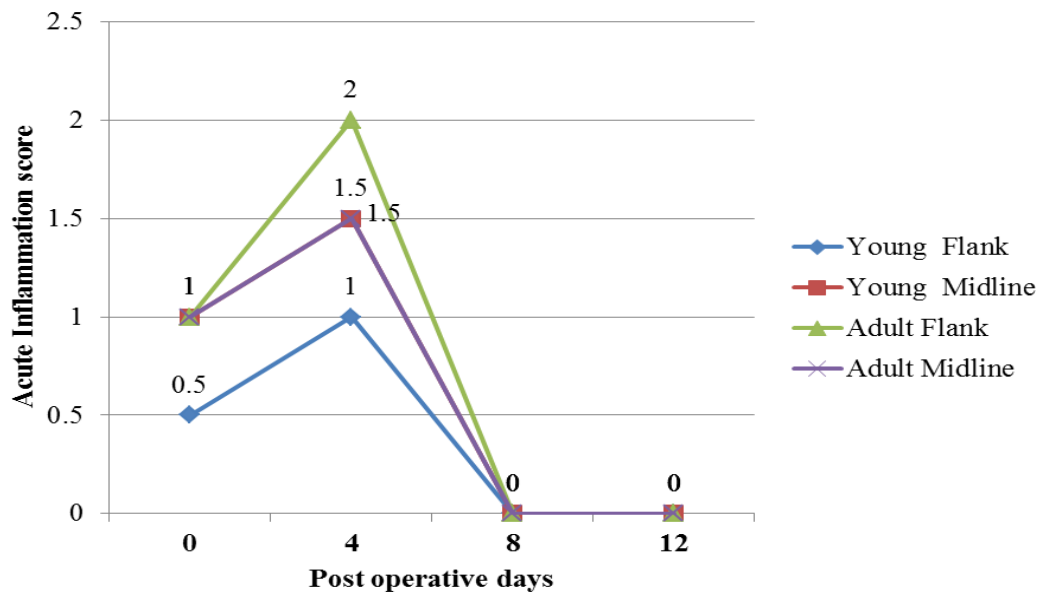


Figure 1. Acute inflammation (score) during wound healing in Group-F and Group-M. Score: 0, None; 1, scant; 2, moderate; 3, abundant.

histologic scoring system developed specifically for this study based on the scoring system suggested by Greenhalgh et al. (1990). Greenhalgh's scoring system compiled several histologic parameters simultaneously to create a single score. A modified scoring system was adopted as suggested by Abramov et al. (2007) for assessment of each parameter independently and gave it a score of 0 to 3. The amount and maturation of granulation tissue as well as both acute and chronic inflammation were determined. Acute inflammation was defined as the presence of neutrophils, while chronic inflammation was defined as the presence of plasma cells and monocytic cells. The degree of granulation tissue maturation was determined by the shape and alignment of the fibroblasts, while mature fibroblasts were thin and usually arranged in compacted parallel layers, immature fibroblasts were stellate-shaped and less organized. The average scores of the pathologists were calculated for each histologic specimen.

Statistical analysis

Data was analyzed by using A Mann-Whitney-U.

RESULTS

The study was carried out to determine the histological

characterizations of wound healing in cats. For the purpose, 24 cats were selected and divided in 4 subgroups, kept in Indoor Patient Ward, Department of Surgery and Obstetrics, Sindh Agriculture University, Tandojam. The cats operated through flank approach healed earlier and histological characterization showed better wound healing through flank in adult cats. All the cats did not heal on the 12th day, and the trend of healing showed bit maturation. The following parameters for histological characterization of wound healing were studied. The results are the following.

Histological characterization of wound healing in cat of Group-F and Group-M

Acute inflammation

The acute inflammation of wound in Group-F and Group-M was scored and results are shown in Figure 1 and Plate 1. The average score rated for the acute inflammation in all subgroups Fy, My, Ma and subgroup-

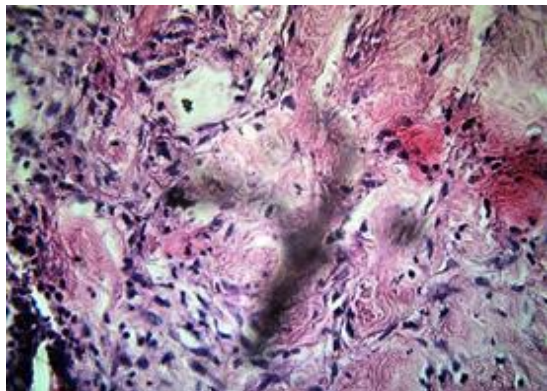


Plate 1. Photograph of abdominal skin with acute inflammation.

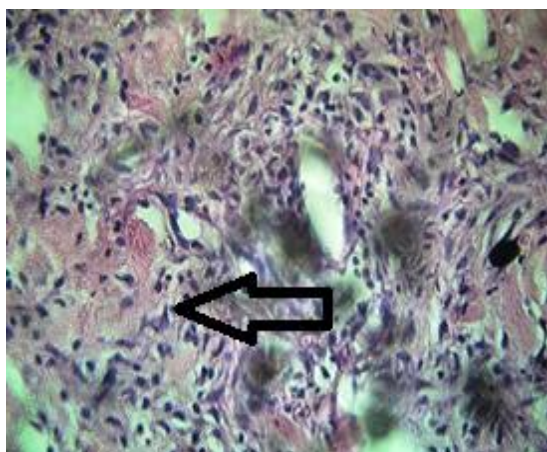


Plate 2. Photograph of abdominal skin wound with (arrow) chronic inflammation.

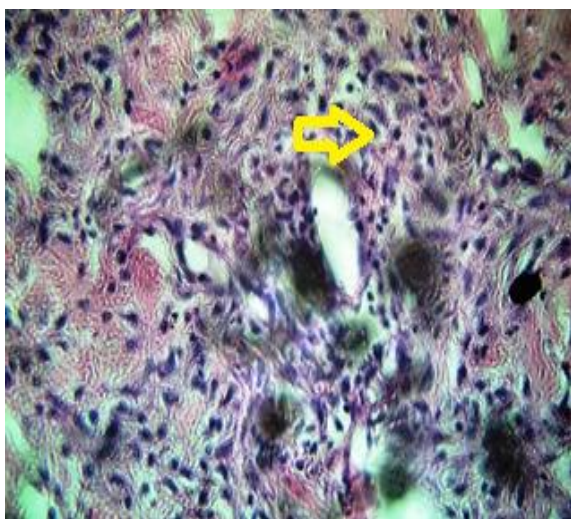


Plate 3. Photograph of abdominal skin wound inflammatory cells.

Fa showed that it was increased scored 1, 1.5, 1.5, and 2, respectively at the 4th day after surgery, then resolved in 8 days scored 0.

Chronic inflammation

The chronic inflammation in wound of Group-F and Group-M was noted and scored as shown in Figure 2 and Plate 2. The results showed that the chronic inflammation was started after the 4th day. The score for chronic inflammation in subgroup-Fa and subgroup-Ma was 0 and 1.5 on the 8th day, respectively and it was decreased to 0 and 0.5 on the 12th day of post operation. While the chronic inflammation in subgroup-Fy and in subgroup-My was scored 1 up to the 8th day and it remained constant in subgroup-My (scored 1) at the 12th day, but resolved in subgroup-Fy (scored, 0.5) up to 12th day of surgery.

Granulation tissue amount in Group-F and Group-M

The granulation tissue amount in the wound of subgroup-Fy and subgroup-My was scored and results are shown in Figure 3 and Plate 3. The average score showed that the granulation tissue amount started after the operation and increased to 8th day of post operation. The granulation tissue amount perceived the score for subgroup-Fy was 1 and subgroup-My was 0.5 up to 4th day, but it increased as 2.5 in subgroup-Fy and 2 in subgroup-My after 8 days and then received less score as 0.5 in subgroup-Fy and 1 in subgroup-My upto 12th day of post operation. While the score for granulation tissue amount in wound of subgroup-Fa was 2 and in subgroup-Ma was 1.5 after 4th day and it was 3 and 2.5 after 8th day, respectively. At the 12th day, score for subgroup-Fa was 0 and subgroup-Ma was 0.5.

Granulation tissue fibroblast maturation in Group-F and Group-M

The granulation tissue and fibroblast maturation for Group-F and Group-M was observed and score is shown in Figure 4 and Plate 4. The average score for the granulation tissue and fibroblast maturation in wound of in subgroup-Fy was 1 and in subgroup-My was also 1 up to the 4th day, but received more as 2 in subgroup-Fy and 1.5 in subgroup-My after the 8th day and 2 and 2.5 up to the 12th day of post operation. While the granulation tissue and fibroblast maturation scored for subgroup-Fa was 1.5 and subgroup-Ma was 1 after the 4th day and it was increased after the 8th day upto 2 for both subgroups, but was found to be higher than 3 for subgroup-Fa than that of subgroup-Ma which was 2 after 12th day of operation.

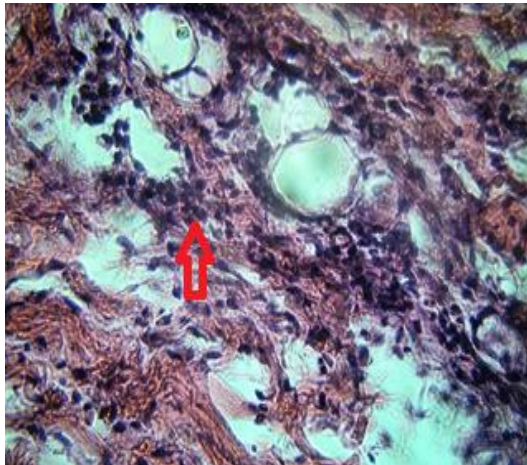


Plate 4. Photograph of abdominal skin (arrow) with (arrow) granulation.

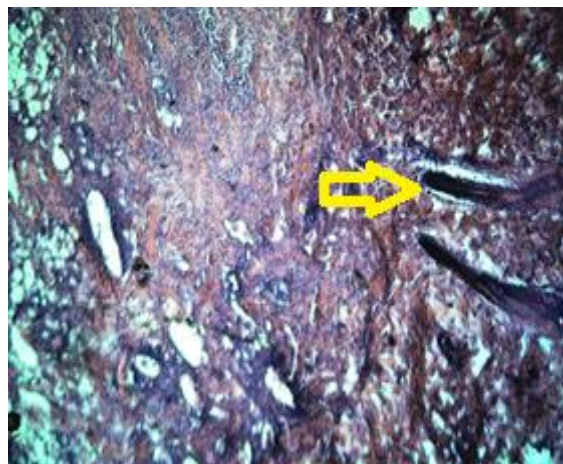

Plate 5. Photograph of abdominal skin wound (arrow) neovascularization.

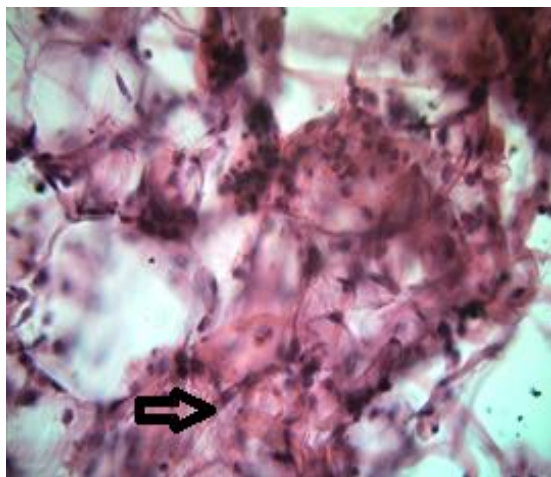


Plate 6. Photograph of abdominal skin wound with (arrow) collagen fibres.

Collagen deposition in Group-F and Group-M

The collagen deposition in wound of Group-F and Group-M was observed and score was shown in Figure 5 and Plate 6. The rated score showed that the collagen deposition started after the operation was increased day by day and peaked up to 12th day. The score for collagen deposition in wound of subgroup-Fy was 1.5 and in subgroup-My was 1 after 4th day, 2 and 1.5 respectively after 8th day and 2.5 and 2 respectively after 12th day of post operation. While the score for collagen deposition in wound of subgroup-Fa was 2 and in subgroup-Ma was 1.5 after 4th day, 3 and 2 after 8th day and 3 and 2.5, respectively after 12th day of operation.

Neovascularization in skin wound of Group-F and Group-M

The neovascularization in wound of Group-F and Group-M was noted and score is presented in Figure 6 and Plate 5. The average score perceived for neovascularization showed that it was increased smoothly up to 12th day of post operation. The neovascularization score for subgroup-Fy was 1.5, 2 and 2.5 than those of subgroup-My 1, 1.5 and 2 at the day of 4, 8 and 12, respectively after operation, while the score for neovascularization in wound of subgroup-Fa was 2, 3 and 3, and in subgroup-Ma it was 1.5, 2 and 2.5 at the day 4, 8 and 12, respectively after operation.

Re-epithelization

The score was rated for changes in the re-epithelization for Group-F and Group-M and results are shown in Figure 7. The average score showed that re-epithelization started after the operation and increased and peaked up to 12th day of surgery. The re-epithelization score for subgroup-Fy was 1 and subgroup-My was 1 up to the 4th day and increased to 1.5 after the 8 day, 2 and 1.5, respectively up to the 12th day of surgery, while the re-epithelization score for subgroup-Fa and subgroup-Ma was 1.5 after the 4th day and it was increased after day 8 as 2 for subgroup-Fa, but remained constant for subgroup-Ma. Score was 3 and 2.5 for subgroup-Fa and subgroup-Ma after day 12 of the operation.

DISCUSSION

In this study, the average score rated for the acute inflammation in subgroup-Fy and subgroup-Fa showed that it increased (score 1.5) up to day 4 after operation and then was resolved in day 8 to 1 and 0 on day 12 after operation, while in case of subgroup-My and subgroup-Ma similarly acute inflammation increased (score, 1.5) up

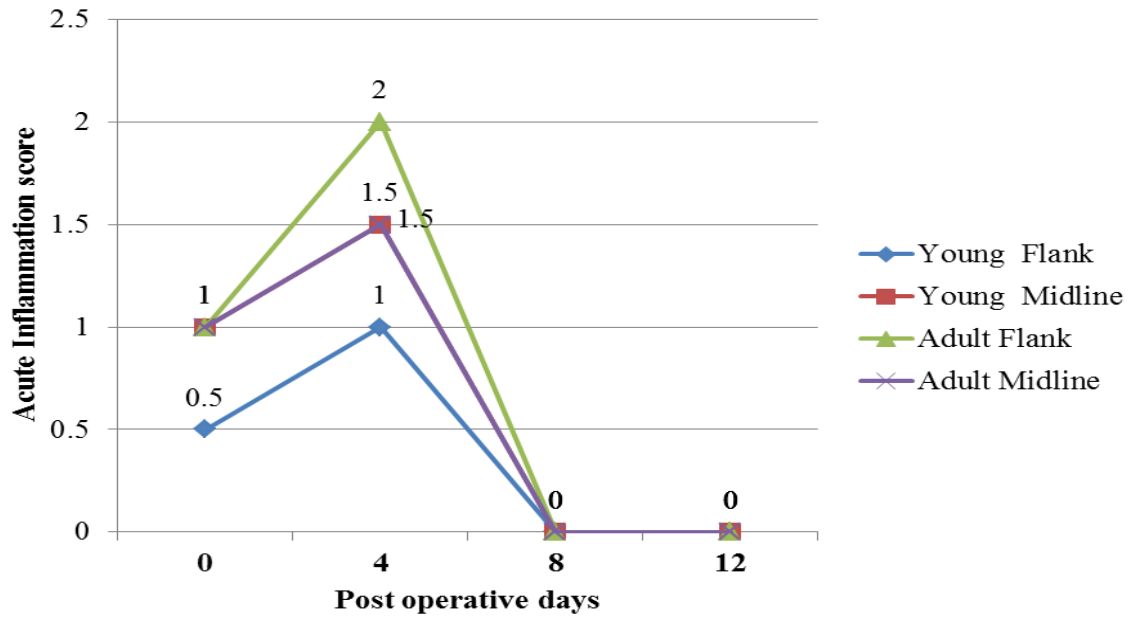


Figure 1. Acute inflammation (score) during wound healing in Group-F and Group-M. Score: 0, None; 1, scant; 2, moderate; 3, abundant.

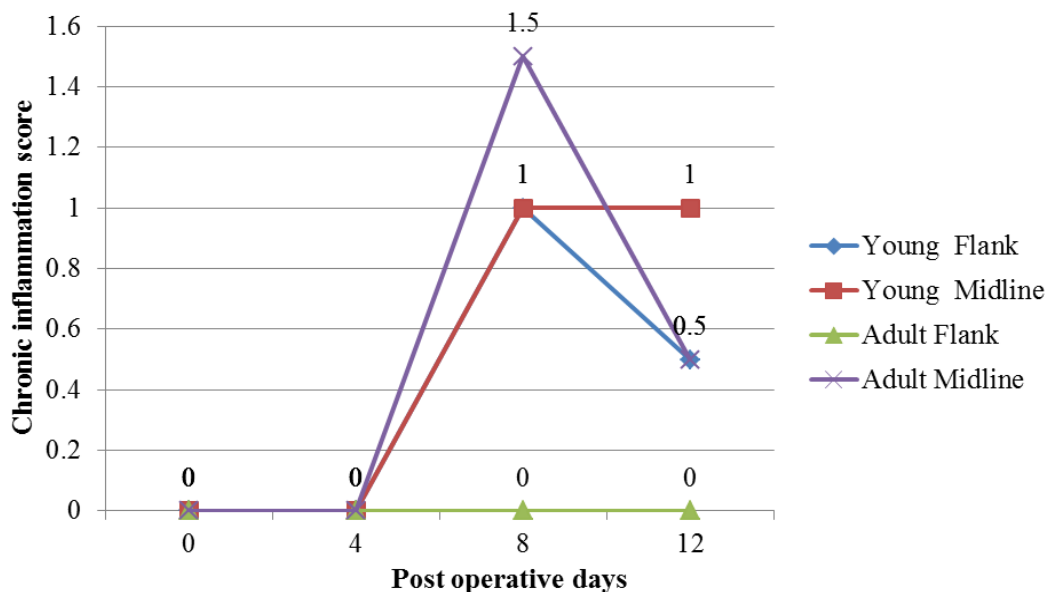


Figure 2. Chronic inflammation (score) during wound healing in Group-F and Group-M. Score: 0, None; 1, scant; 2, moderate; 3, abundant.

to day 4 and continued up to day 8 (score, 1.5) after operation and then declined to score 1 and 0.5, respectively on day 12 after operation. Abramov et al. (2007) reported that the acute inflammation was increased after wounding and was peaked at day 4; thereafter, it was reduced gradually and score declined to 0 at day 14. Counter regulatory anti-inflammatory processes that restore normal equilibrium and result in gradual disappearance of the inflammatory cells normally follow the initial inflammatory response.

The score for chronic inflammation in subgroup-Fa and subgroup-Ma was perceived high as 2.5 and 2 on day 4 and it was decreased to 2 and 1.5 on day 8 and 0 and 0.5, respectively on day 12 after operation, while the chronic inflammation in subgroup-Fy and subgroup-My was increased (Score for each, 1.5) up to day 4 and it remained similar for subgroup-Fy, but reduced for subgroup-My (score, 1) up to day 8 and after day 12 of operation, the chronic inflammation in subgroup-Fy was found to decrease (Score, 0.5). However, the results of

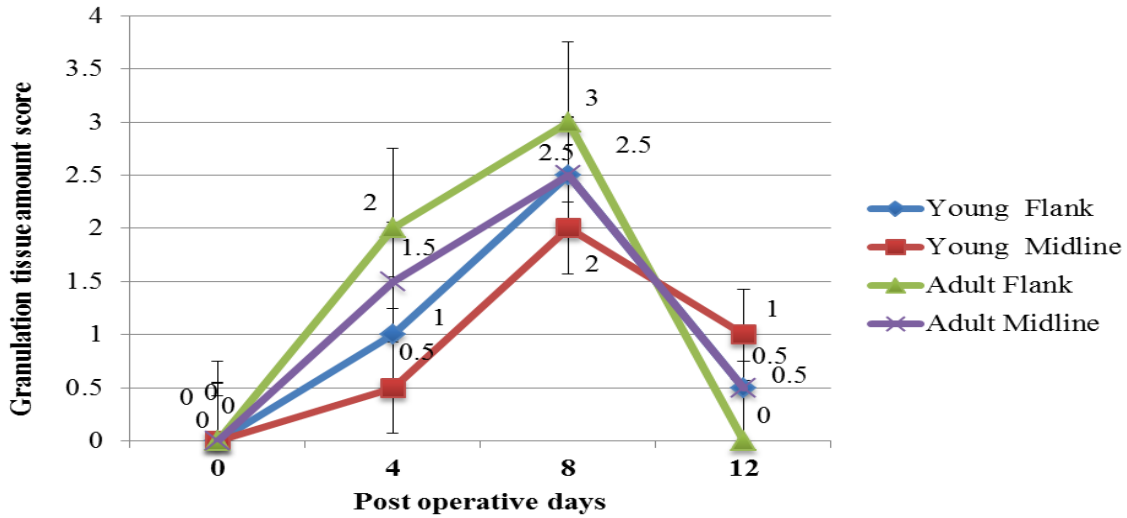


Figure 3. Score for granulation tissue in wound of Group-F and Group-M. Score:0, None; 1, Scant; 2, Moderate; 3, Abundant.

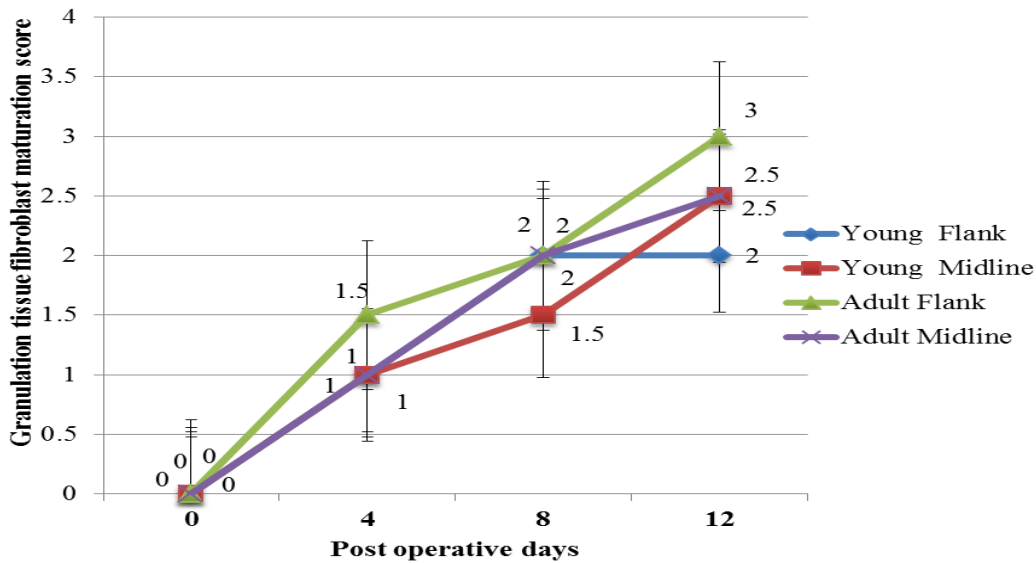


Figure 4. Score for granulation tissue and fibroblast maturation in wound of Group-F and Group-M. Score: 0, Immature; 1, Mild maturation; 2, Moderate maturation; 3, Fully matured.

Abramov et al. (2007) illustrated that the chronic inflammation increased more (score, 2) and peaked at days 4 to 7 and gradually declined until day 28. Some degree of chronic inflammation, however, persisted at these time points in both tissues of both approaches. In this study, the chronic inflammation in wound of subgroup-My declined more gradually in post-wounding day 12, it could be argued that this process may persist longer than the others studied.

In the present study, the granulation tissue amount increased at day 4 (score 1 and 0.5, respectively) and day 8 (score 2.5 and 2, respectively) for subgroup-Fy and

subgroup-My, but declined at day 12 (0.5 and 1) after operation. In case of wound of subgroup-Fa and subgroup-Ma, the granulation tissue amount increased more (2 and 1.5 respectively) at day 4 and 3 and 2.5 at day 8, but declined to 0 and 0.5, respectively at day 12 after operation. Abramov et al. (2007) reported that the amount of granulation tissue increased significantly after wounding and peaked at 4 to 7 days and it then declined gradually, reaching baseline levels. The wound and surrounding tissues become inflamed and cells, particularly neutrophils and monocytes are mobilized to infiltrate the clot and start the processes involved in granulation

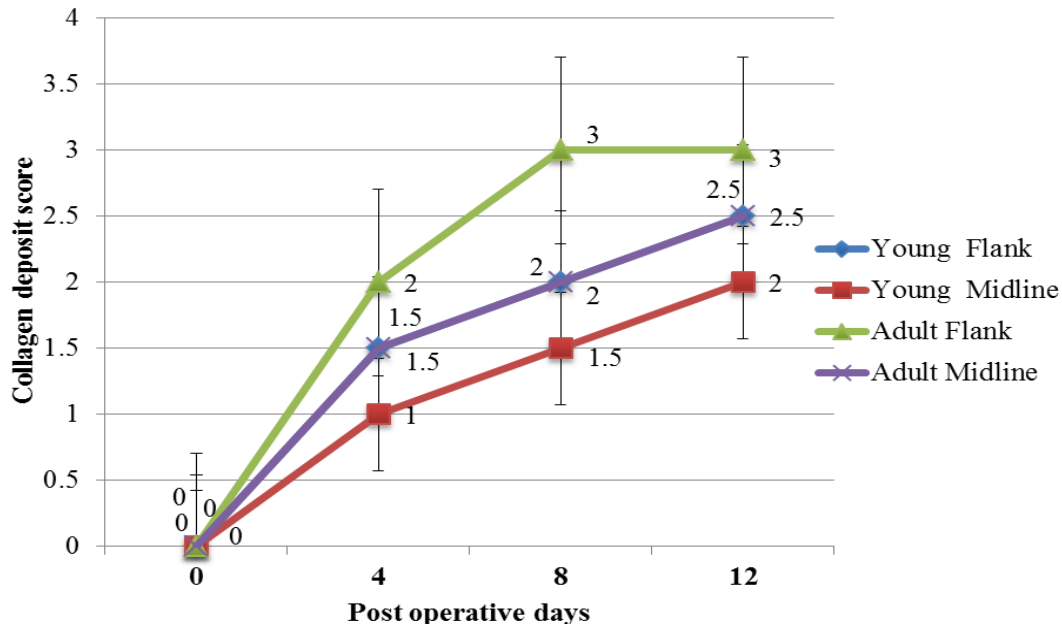


Figure 5. Score for collagen deposition in wound of Group-F and Group-M. Score: 0, None; 1, Scant; 2, Moderate; 3, Abundant.

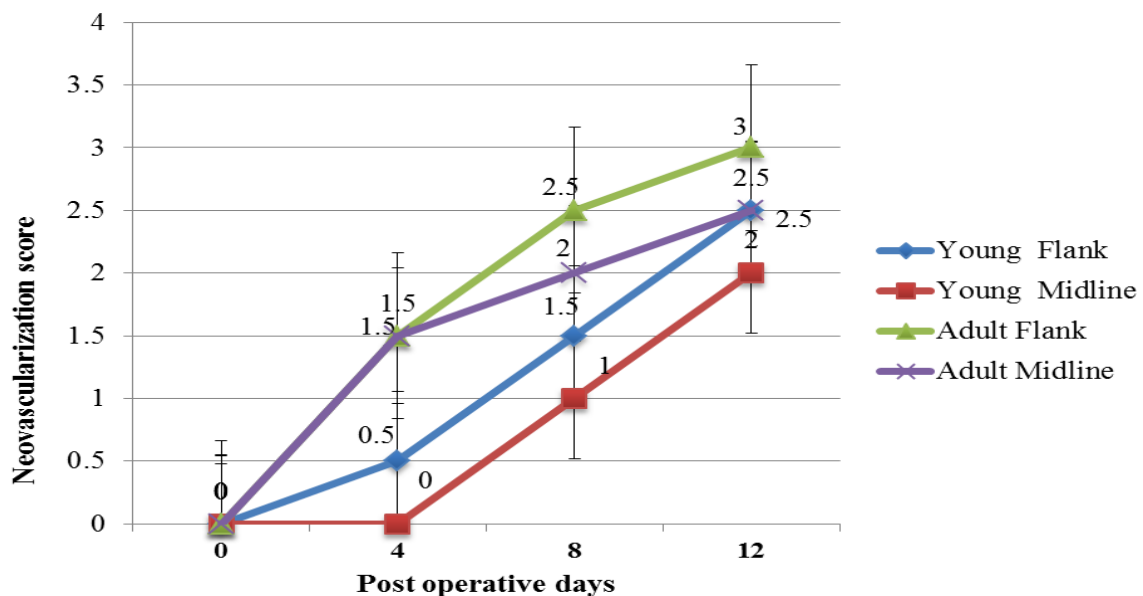


Figure 6. Score for neovascularization in wound of Group-F and Group-M. Score: 0, None; 1, Upto 5 vessels per HPF; 2, 6-10 vessels per HPF; 3, More than 10 vessels per HPF.

tissue synthesis (Abdalbari, 2009).

In this study, the granulation tissue and fibroblast maturation in wound of subgroup-Fy and subgroup-My was increased at day 4 (score, 1 for each), at day 8 (score, 2 and 2.5) and up to day 12 (score, 2 and 2.5) after operation. In case of subgroup-Fa and subgroup-Ma, the granulation tissue and fibroblast maturation in wound was enhanced at day 4 (score 1.5 and 1), at day 8 (score 2 for each) and up to day 12 (score, 3 and 2) after

operation. The study of Abramov et al. (2007) supports the findings of this study, it was reported that the maturation of granulation tissue progressively increased in wound of tissue until post-wounding day 12. However, the difference in the score might be due to the different tissues of approaches (that is, flank and midline) and the scoring system described here was found to be reliable and reproducible for flank approach with good inter and intra observer agreement (Beausang et al., 1998).

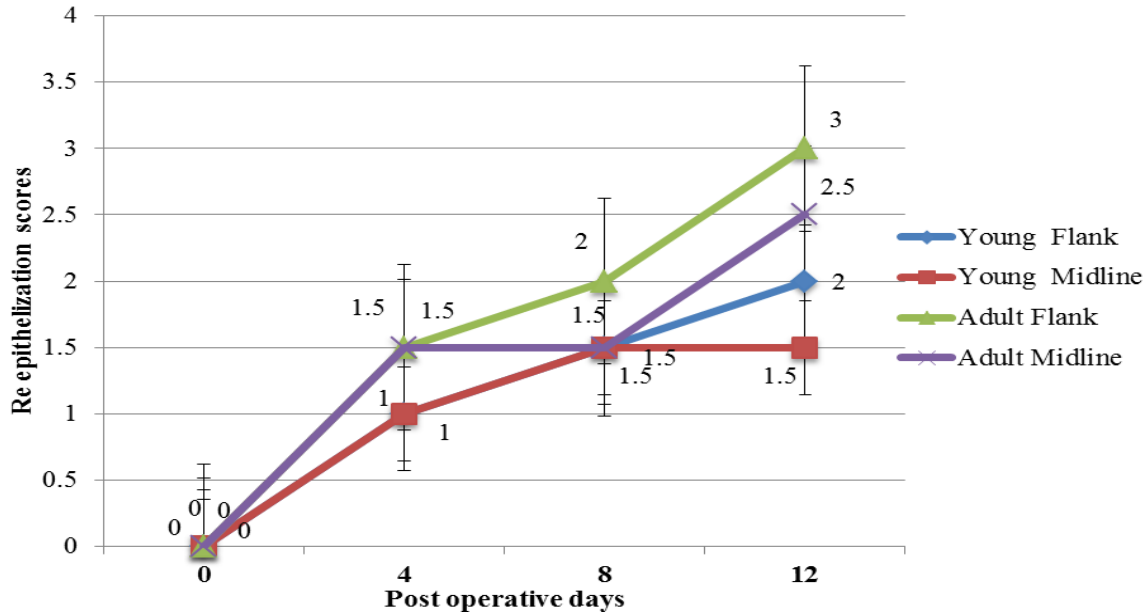


Figure 7. Score for re-epithelization in wound of Group-F and Group-M. Score: 0, None; 1, partial; 2, complete but immature; 3, complete and mature.

The rated score for wound of subgroup-Fy and subgroup-My showed that the collagen deposition started after the operation and was increased day by day (at day 4 score, 1.5 and 1, and at day 8 score, 2 and 1.5) and peaked up to day 12 (score, 2.5 and 2, respectively) after surgery. The collagen deposition in wound of subgroup-Fa and subgroup-Ma was increased and perceived score was 2 and 1.5 after day 4, 3 and 2 after day 8 and 3 and 2.5 respectively after day 12 of operation. Similar to the present findings, collagen deposition in the wound persistently increased until post wounding days, and was also reported by Abramov et al. (2007). Collagen deposition by skin fibroblast has been shown to begin within days 3 to 5 after operation and continue for several weeks, depending on the size of wound (O'kane, 2002).

In the present study, the average score perceived for neovascularization showed that it increased smoothly up to day 12 of post operation. The neovascularization score for subgroup-Fy was observed high (1.5, 2 and 2.5) than those of subgroup-My (1, 1.5 and 2) at days 4, 8 and 12, respectively after operation, while the score for neovascularization in wound of subgroup-Fa perceived more (2, 3 and 3) than those of subgroup-Ma (1.5, 2 and 2.5) at the days 4, 8 and 12, respectively after operation. However, Abramov et al. (2007) reported that the neovascularization score increased significantly after wounding in tissue and peaked at days 4 and 7. Neovascularization is an important component of wound healing process that includes branching and extension of adjacent blood vessels as well as recruitment of endothelial progenitor cells (Carmeliet, 2003).

The re-epithelization score for subgroup-Fy and subgroup-My was 1 up to day 4 and increased as 1.5

after day 8 and 2 and 1.5, respectively up to day 12 of surgery, while the re-epithelization score for subgroup-Fa and subgroup-Ma was 1.5 after day 4 and it was increased after day 8 to 2 for subgroup-Fa, but remained constant for subgroup-Ma (1.5). Score was 3 and 2.5 for subgroup-Fa and subgroup-Ma, respectively after day 12 of operation. These findings are in line with the results of study conducted by Abramov et al. (2007) who reported that the re-epithelization score was increased significantly after wounding in the tissues and it was completed in the tissues by post wounding day 14. Re-epithelialization in dermal tissues was shown to occur within day 4 after wounding when spurs of epithelial cells moved from the wound edges along the cut margins of the dermis, depositing basement membrane components as they moved (Werner et al., 2003). These cells were eventually fused, producing a continuous epithelial layer that closed the wound. In current study, it was observed progressive re-epithelialization after wounding in the flank of adult cats and was completed by post wounding day 12.

CONCLUSIONS AND SUGGESTIONS

This study was carried out to determine the histological characterization of wound healing for ovariohysterectomy in different age groups of cats at Department of Surgery and Obstetrics, Sindh Agriculture University Tandojam during 2013. The parameters studied in histological characterization of wound healing were acute inflammation, chronic inflammation, granulation tissue amount, granulation tissue amount and fibroblast maturation, collagen deposition, re-epithelization and neovascularization. The

results are summarized as under as the following.

The average score rated for the acute inflammation in subgroup-Fy and subgroup-Fa showed that it increased (score, 1.5) up to day 4 after operation and then was resolved on day 8 (1) and 0 on day 12 after operation, while in case of subgroup-My and subgroup-Ma, similarly acute inflammation increased (score, 1.5) up to day 4 and continued up to day 8 (score, 1.5) after operation and then declined to score, 1 and 0.5 respectively on days 12 after operation.

The score for chronic inflammation in subgroup-Fa and subgroup-Ma was perceived to be high as 2.5 and 2 on day 4 and it was decreased to 2 and 1.5 on day 8 and 0 and 0.5, respectively on day 12 after operation, while the chronic inflammation in subgroup-Fy and subgroup-My was increased (Score for each, 1.5) up to day 4 and it remained similar for subgroup-Fy, but reduced for subgroup-My (score, 1) up to day 8 and after day 12 of operation; the chronic inflammation in subgroup-Fy was found to decrease (Score, 0.5).

The granulation tissue amount increased at day 4 (score 1 and 0.5, respectively) and day 8 (score 2.5 and 2, respectively) for subgroup-Fy and subgroup-My, but declined at day 12 (0.5 and 1) after operation. In case of wound of subgroup-Fa and subgroup-Ma, the granulation tissue amount increased more (2 and 1.5 respectively) at day 4 and 3 and 2.5 at day 8, but declined to 0 and 0.5, respectively at day 12 after operation.

The granulation tissue and fibroblast maturation in wound of subgroup-Fy and subgroup-My was increased at day 4 (score 1 for each), at day 8 (score 2 and 2.5) and up to day 12 (score, 2 and 2.5) after operation. In case of subgroup-Fa and subgroup-Ma, the granulation tissue and fibroblast maturation in wound was enhanced at day 4 (score 1.5 and 1), at day 8 (score 2 for each) and up to day 12 (score, 3 and 2) after operation.

The rated score for wound of subgroup-Fy and subgroup-My showed that the collagen deposition started after the operation and was increased day by day at day 4 (score 1.5 and 1) and at day 8 (score 2 and 1.5) and peaked up to day 12 (score 2.5 and 2, respectively) after surgery. The collagen deposition in wound of subgroup-Fa and subgroup-Ma was increased and perceived score was 2 and 1.5 after day 4, 3 and 2 after day 8 and 3 and 2.5, respectively after day 12 of the operation.

The average score perceived for neovascularization showed that it was increased smoothly up to day 12 of post operation. The neovascularization score for subgroup-Fy was observed to be high (1.5, 2 and 2.5) than those of subgroup-My (1, 1.5 and 2) at days of 4, 8 and 12, respectively after operation, while the score for neovascularization in wound of subgroup-Fa perceived more (2, 3 and 3) than those of subgroup-Ma (1.5, 2 and 2.5) at the days 4, 8 and 12, respectively after operation.

The re-epithelization score for subgroup-Fy and subgroup-My was 1 up to day 4 and increased to 1.5 after day 8 and 2 and 1.5, respectively up to day 12 of

surgery, while the re-epithelization score for subgroup-Fa and subgroup-Ma was 1.5 after day 4 and it was increased after day 8 as 2 for subgroup-Fa, but remained constant for subgroup-Ma (1.5). Score was 3 and 2.5 for subgroup-Fa and subgroup-Ma, respectively after day 12 of operation.

It was concluded from this study that wound healing is quicker in flank approach than midline approach. Histological characterization of wound healing manifested better healing through flank approach than the midline. It is suitable to perform ovariohysterectomy in adult cats.

REFERENCES

- Abdalbari AA (2009). Histological study of early events during wound healing. *Bas. J. Vet. Res.* 8(1):130-137.
- Abramov Y, Golden B, Sullivan M, Botros SM, Alshahrour A, Roger P, Peter KS (2007). Histologic characterization of vaginal vs. abdominal surgical wound healing in rabbit model. *Wound Repair Regen.* 15:80-86
- Adrian B (2005). Wound healing. In: *Schwartz's Principles of surgery.* New York. The McGraw - Hill companies Inc. pp. 223-23.
- Bloomberg MS (1996). Surgical neutering and non-surgical alternatives. *J. Am. Vet. Med. Assoc.* 208(4):517-519.
- Beausang E, Floyd H, Dunn KW, Orton CI, Ferguson MW (1998). A new quantitative scale for clinical scar assessment. *Plast. Reconstr. Surg.* 102:1954-61.
- Barbara J, Margaret M (1987). Wound healings dressing and drains. In: *Alexander's care of the patient in surgery, 8th edition.* C.V Mosby Company. P 38.
- Befanis PJ, Peiffer Jr, Brown D (1981). Endothelial repair of the canine cornea. *Am. J. Vet. Res.* 42:590.
- Baum CL, Arpey CJ (2005). Normal cutaneous wound healing. *Clinical correlation with cellular and Molecular events.* *Dermatol. Surg.* 31:674-686.
- Cotran RS, Kumar V, Collin's T (1999). Tissue repair, cellular growth, fibrosis and wound healing. In: *Robin's Pathological Basis of Disease, 6th edition.* Philadelphia, USA, W.B. Saunders. pp. 22-118.
- Carmeliet P (2003). Angiogenesis in health and disease. *Natl. Med.* 9:653-60.
- Edwards LC, Dunphy JE (1958). Wound healing I. Injury and normal repair. *N. Engl. J. Med.* 259:224-233.
- Edwards LC, Dunphy JE (1958). Wound healing II. Injury and abnormal repair. *N. Engl. J. Med.* 259(6):275-285.
- Gohel MS, Taylor M, Earnshaw JJ (2005). Risk factors for delayed healing and recurrence of chronic venous leg ulcers analysis of 1324 legs. *Eur. J. Vasc. Endovasc. Surg.* 29(1):74 -7.
- Gordon RS, Malcom H, David A, Gowan MC (1987). Intraoral incisions and suturing. In: *Killey and Kay's outline of oral surgery part one, 2nd edition.* India. pp. 10-42.
- Greenhalgh DG, Sprugel KH, Murray MJ, Ross R, Fand PD (1990). Stimulated healing in the genetically diabetic mouse. *Am. J. Pathol.* 136:1235-46.
- Horn DL, Sandile DD, Leideman S and Buco PJ (1977). Regeneration capacity of the corneal endothelium in rabbit and cat. *Invest. Ophthalmol.* 16:597.
- Howe LM (1997). Short-term results and complications of pre pubertal gonadectomy in cats and dogs. *J. Ame. Vet. Med. Assoc.* 211(1):57-62.
- Kleinman HK, Weeks BS, Schnaper HW, Kibbey MC, Yamamura K and Grant DS (1993). The laminins. A family of basement membrane glycoproteins important in cell differentiation and tumor metastases. *Vitam. Horm.* 47:161-187.
- Kuhn K (1994). Basement membrane (type IV) collagen. *Matrix Biol.* 14:439-445.
- Ling T, Vannas A, Holden BA (1988). Long-term changes in corneal

- endothelial morphology following wounding in the cat. *Invest. Ophthalmol. Vis. Sci.* 29:1407.
- Levy JK, Gale DW, Gale LA (2003). Evaluation of the effect of a longterm trap-neuter-return and adoption program on a free-roaming cat population. *J. Am. Vet. Med. Assoc.* 222(1):42-46.
- Marinkovich MP, Keene DR, Rimberg CS, Burgeson RE (1993). Cellular origin of the dermal-epidermal basement membrane. *Dev. Dyn.* 197:255-267.
- Mustafa S (1997). Effect of copper salt of Ibuprofen on wound healing in experimental rats. M.Phil, Pathology Thesis, University of Dhaka. P 87.
- Ogita Y, Higuchi S, Kari K, Honda N (1981). Wound healing of the endothelium of the living cat cornea. A specular microscopic study. *Jpn. J. Ophthalmol.* 25:326.
- O'Kane S (2002). Wound remodeling and scarring. *J. Wound Care.* 11(8):296-9.
- Ota Y (1975). Endothelial permeability to fluorescein in corneal grafts and bullous keratopathy. *Jpn. J. Ophthalmol.* 19:286.
- Sawa M, Araie M, Tanishima TA (1983). Fluorophotometric study of the barrier functions in the anterior segment of the eye after intracapsular cataract extraction. *Jpn. J. Ophthalmol.* 27:404.
- Timpl R (1996). Macromolecular organization of basement membranes. *Curr. Opin. Cell Biol.* 8:618-624.
- Uitto J, Pulkkinen L (1996). Molecular complexity of the cutaneous basement membrane zone. *Mol. Biol. Rep.* 23:35-46.
- Valle GR, Marques JAP (1999). Endocrinopathology and hormonal therapy of the estral cycle of the bitch. *Caderno Técnico de Veterinária e Zootecnia. Belo Horiz.* 30:49-74.
- Werner S, Grose R (2003). Regulation of wound healing by growth factors and cytokines. *Phys. Rev.* 83:835-70.
- Walter JB, Israel MS (1987). Wound healing. In: Walter and Israel General Pathology 6th, edition. Longman group U.K limited, Churchill Livingstone. pp. 117-12.
- Watkinson J, Gaze C, Mark N, Wilson JA (2000). Tumors of Major Salivary Glands. In: Stell and Maran's Head and Neck Surgery, 4th edition. Reed Educational and Professional publishing Ltd, India. P 452.
- Zieske JD, Mason VS, Wasson, ME, Meunier SF, Nolte CJ, Fukai N, Olsen BR, Parenteau NL (1994). Basement membrane assembly and differentiation of cultured corneal cells: importance of culture environment and endothelial cell interaction. *Exp. Cell Res.* 214:621-633.