

Case Report

Oral manifestations in progressive systemic sclerosis: Case report

Param Pal Singh^{1*}, Shekar Kapoor² and Saurab Bither²

¹Department Of Oral Medicine And Radiology, Christian Dental College And Hospital, Brown Road, Ludhiana, Punjab. India.

²Oral and Maxillofacial Surgery Department, Christian Dental College and Hospital, Brown Road Ludhiana, Punjab, India.

Accepted 20 July, 2011

Progressive systemic sclerosis is a chronic sclerotic disease which causes diffuse, increased deposition of extra cellular matrix in connective tissue with vascular abnormalities, resulting in tissue hypoxia. Aesthetic and facial dysfunctions are followed by important oral and facial manifestations. Most oral manifestations begin with tongue rigidity and facial skin changes. Bone resorption of mandibular angle and widening of periodontal ligament space on periapical radiographs are important radiological findings. Other systemic changes include the involvement of internal organs which leads to serious complications as well as disorders in the cardiac muscle and Raynaud's phenomenon. The objective of this paper is to report a case of systemic sclerosis in patients with oral and facial manifestations of the disease. A brief review of the literature, focusing on dental alterations is also presented.

Key words: Scleroderma, acro-osteolysis, Raynaud's phenomenon.

INTRODUCTION

Progressive systemic sclerosis (PSS), also known as scleroderma, is a disorder of the connective tissue characterized by fibrosis of the skin, blood vessels and visceral organs and mucosa. Women are affected 3 to 4 times more frequently than men. Black patients have a higher age-specific incidence rate and more severe disease than white patients. The involvement of the skin together with the quality of its mobility, particularly in the distal portions of the extremities is by far the most obvious symptom (Takehara and Sato, 2005). Cutaneous manifestations include thickening of skin, starting with pitting edema and over several months pitting edema is replaced by tightening and hardening of skin (Caplan and Benny, 1978). Raynaud's phenomenon, a paroxysmal vasospasm of fingers which results in change in color of fingertips as a response to cold or emotion and resorption of terminal phalanges is usually the first symptom. Oral and facial tissues are often affected, presenting a

characteristic features. Most clinical manifestations begin with tongue rigidity and classic facial skin hardening, which gives it a classic mask-like appearance. A very limited opening of the oral orifice besides bone resorption at the angle of the mandible are commonly reported feature (Wardrop et al., 1987). The exact mechanism of the fibrotic changes is unknown, but hyper plastic changes of collagen have been documented. Also, inflammatory changes and globulin deposits were found in blood vessel walls, which apparently explain the basis for altered collagen (Marmary et al., 1981). The pathological findings, indicate that fibroblasts are activated to produce excessive amounts of collagen and other components of the cellular matrix (Zhou et al., 2001).

PSS is a fatal, multi-system disease. Prognosis is uncertain. Abnormal motion of mandible and subluxation are other possible dental manifestations. Progressive vascular fibrosis and deficient wound healing make any surgical procedure difficult and hazardous in these patients (Cankaya and Kabasakal, 2001).

This article reports a case with oral and facial manifestations in systemic sclerosis. A brief review of the literature is presented, focusing on dental manifestations.

*Corresponding author. E-mail: parampal@hotmail.com. Tel: 9878123478.

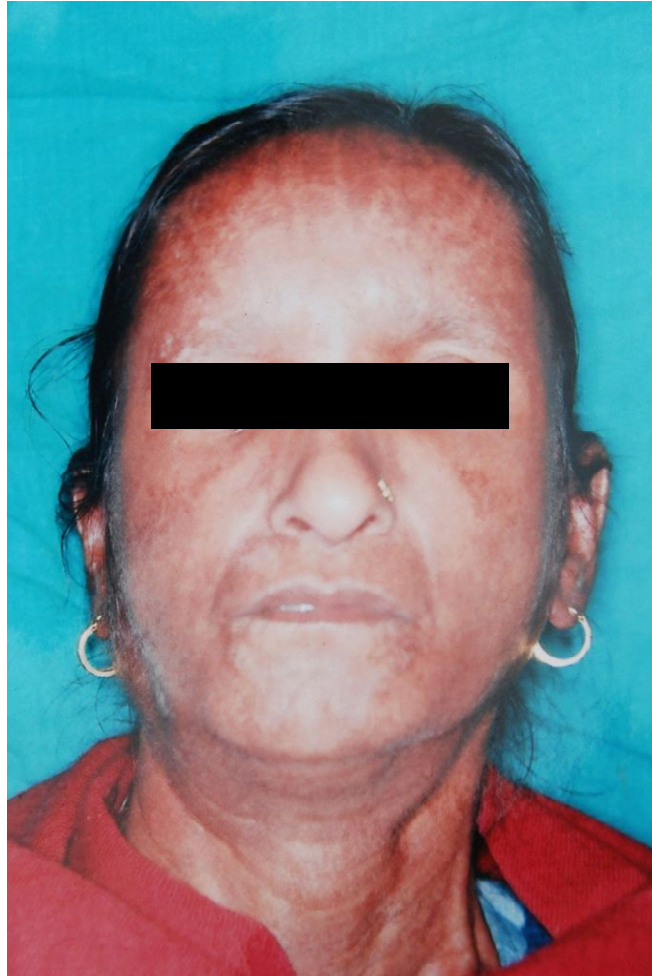

Figure 1. Mask like face of the patient. Note the pinched nose, thinned lips and Hypo pigmented areas on face.

CASE REPORT

A 40-year-old woman was referred to the Department of Oral Medicine and Radiology with chief complaint of mobility of teeth and decreased mouth opening. She gave history of difficulty in chewing due to mobile teeth, reduced mouth opening and decreased salivation. Her past medical history revealed that she had been diagnosed with progressive systemic sclerosis 4 years ago. She had been treated with D- penicillamine for PSS effectively. There was no history of internal organ involvement. Patient gave history of thickening of skin and frequent ulcerations of fingertips of both hands. She also gave history of hypo pigmented areas on skin of her face, neck and arms.

Extra-oral examination showed taut, thickened, mask like facial skin with focal areas of hypo-pigmentation (Figure 1). There was morphologic modification of the angle and body of the jaw, a marked decrease in width of oral orifice (microstomia), and thinned lips. Nasal alae

appeared atrophied giving pinched appearance to nose (Figure 1). Fingers were fixed in a claw-like position with shortening as a result of acro-osteolysis (Figure 2).

Intra-oral examination showed blanching of the mucosa involving buccal mucosa (Figure 3), soft and hard palate. Tongue rigidity and limited movement of tongue was present. There was generalized gingival inflammation, mobility with respect to 17, 18, 26, 46, 47 and carious teeth in relation to 46, 47, 17, and 18.

Intra oral periapical radiographs showed enlargement of periodontal space mainly on maxillary and mandibular incisors (Figures 4a and 4b) and maxillary premolar-molar region (Figure 4c). Panoramic radiograph showed generalized widening of periodontal space particularly with respect to maxillary and mandibular incisors (Figure 5).

Oral prophylaxis was performed followed by restoration of carious teeth. Patient was taught oral hygiene procedures and mouth stretching exercises to improve mouth opening. Artificial salivary substitutes were given to

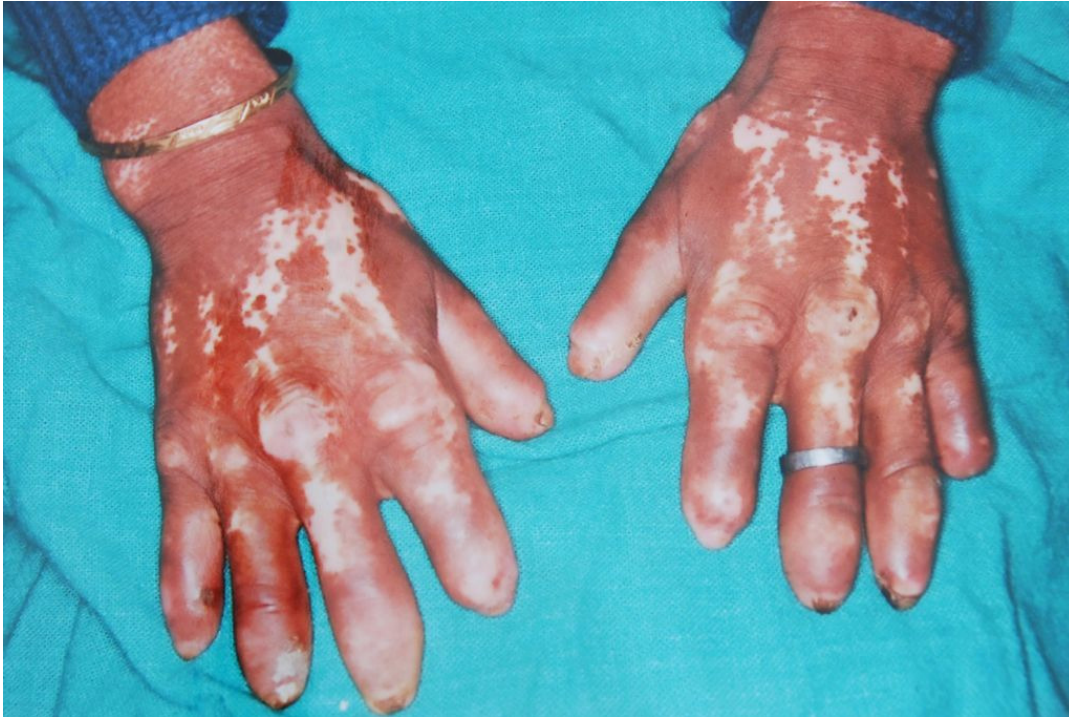

Figure 2. Note the extensive involvement of fingers and hand with resorption of phalanges.

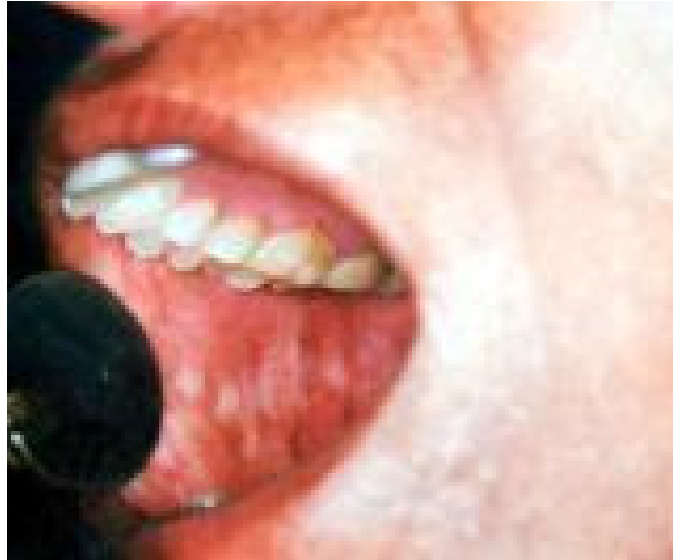

Figure 3. Blanching of oral mucosa seen due to fibrosis.

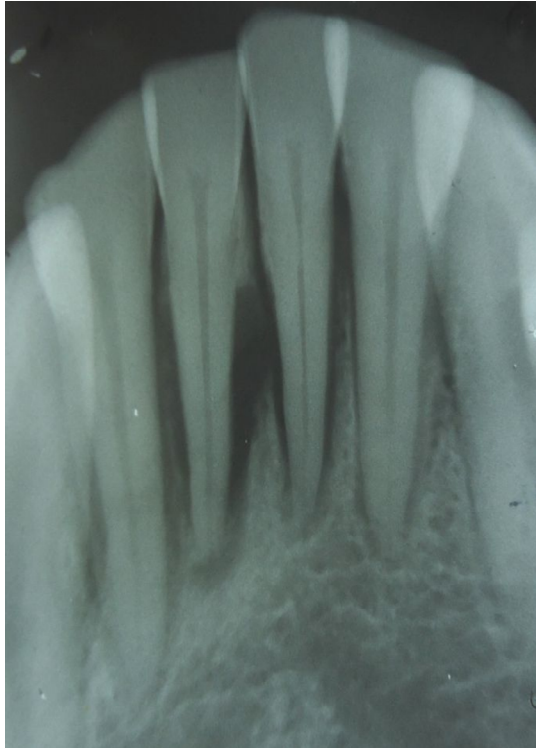
reduce hypo salivation.

DISCUSSION

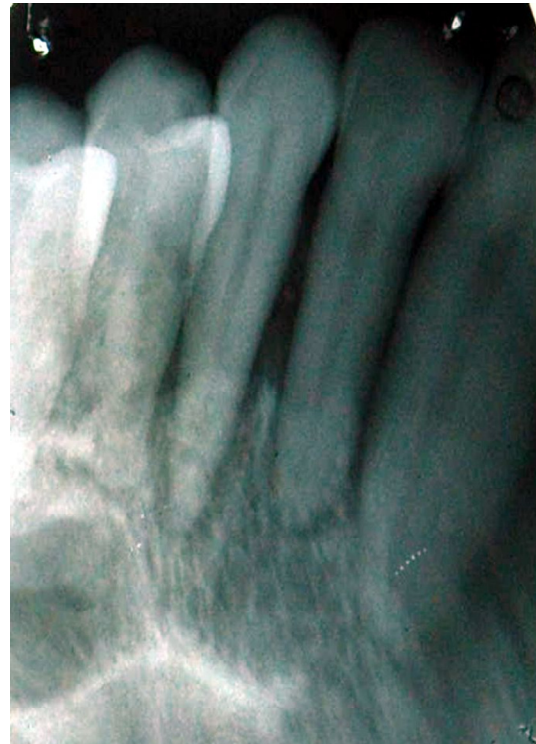Scleroderma or PSS is a rare condition (Nagy et al., 1994). It was first characterized as a single condition in

1752 by Curzio of Naples (Naylor 1982). It generally affects women between 30 and 50 years of age (White et al., 1977).

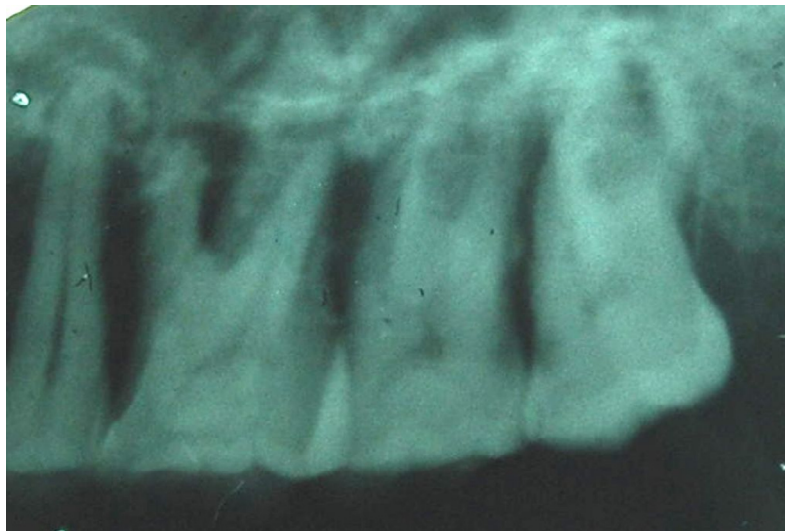
Etiology of PSS is unknown. Immunologic studies suggest that pathogenesis of disease is autoimmune with antibodies directed against endothelium (Cankaya and Kabasakal, 2001).



(a)



(b)



(c)

Figure 4a. Periapical radiographs showing (a) widening of periodontal space on mandibular incisors (b) widening of periodontal space on maxillary incisors (c) widening of periodontal space on maxillary premolar, molar region.

There are two clinical entities of scleroderma: localized scleroderma and PSS. Systemic sclerosis differs from localized scleroderma because it is accompanied by Raynaud's phenomenon, acrosclerosis, and internal organ involvement. PSS often affects oral and perioral

tissues.

The most common oral manifestations are mask like appearance of face due to loss of skin folds around mouth, thinned and rigid lips and tongue rigidity. Rigidity of tongue can make speaking and swallowing difficult

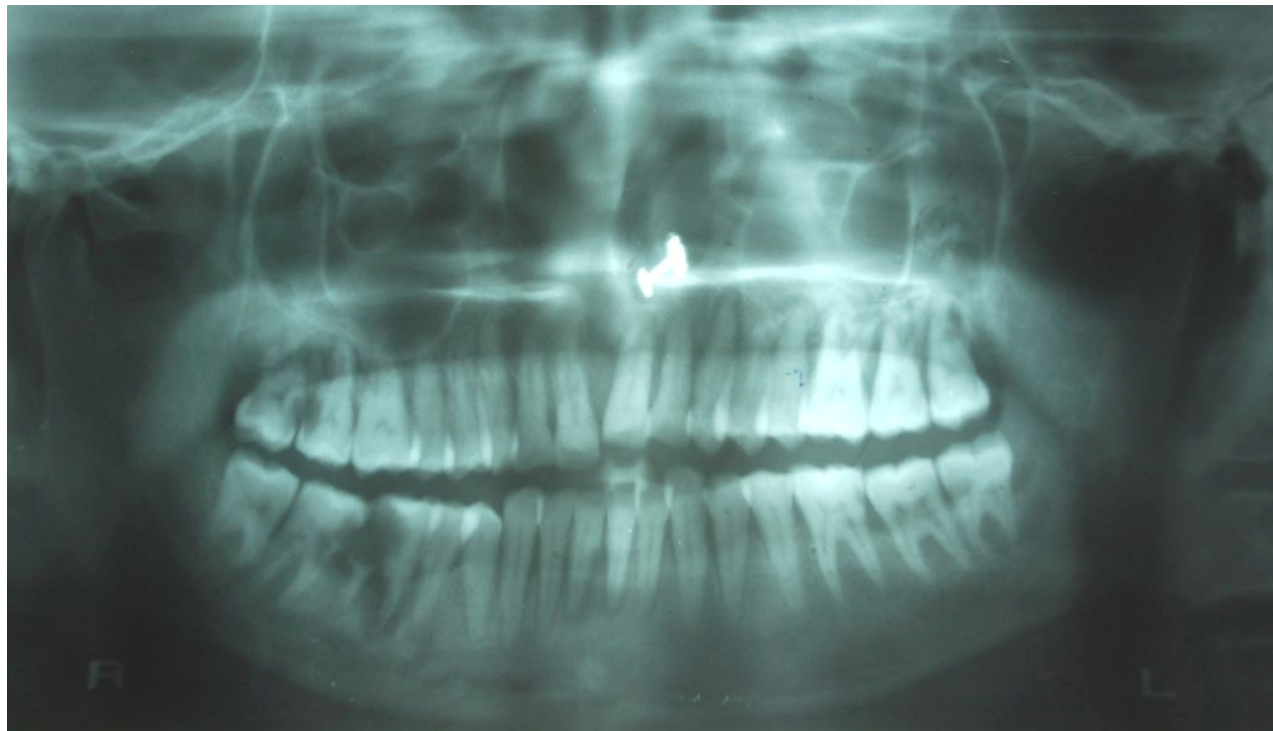


Figure 5. OPG showing generalized widening of periodontal space particularly with respect to maxillary and mandibular incisors.

(Caplan and Benny, 1978; Wardrop et al., 1987; Nagy et al., 1994). The case presented here exhibited most of the facial and oral characteristics of PSS mentioned.

Pressure of the ischemic overlying tissues result in osteolysis mainly in areas of bone prominences covered by thin skin and subcutaneous tissue (Caplan and Benny, 1978; Wardrop et al., 1987). The condyle, the coronoid process, and posterior border of the ascending ramus are frequently involved (Caplan and Benny, 1978; Wardrop et al., 1987; Fischhoff and Sirois, 2000). In some cases there may be mandibular resorption and painful trigeminal neuropathy due to nerve compression (Johns et al., 1998). In PSS, fibrosis of all oral tissues occurs causing limited oral function such as decrease in the maximal oral aperture, impaired healing. The inter-incisal distance is significantly reduced in most of the patients with PSS (Nagy et al., 1994). Limitation of mouth opening and reduced movement of the cheeks and tongue usually leads to deterioration in dental health. Therefore, regular oral examination should be recommended (Cankaya and Kabasakal, 2001). Resorption of terminal phalanges of the hand, radius, ulna, ribs, clavicles and in some cases the mandible have been described (Rubin and Sonfilippo, 1992).

Patients can have salivary hypo function, keratoconjunctivitis sicca or both. Xerostomia can result in increased susceptibility to dental caries, *Candida* infections and periodontal disease. In the present case the patient complained of decreased salivation. Gingival

hyperplasia can result from use of calcium channel blockers (Nagy et al.1994).

Most common dental finding in PSS is widening of periodontal ligament space in absence of significant periodontal disease (White et al., 1977; Rowel and Hopper, 1997).

A radiographic study of PSS patients reveals a great incidence of periodontal ligament space enlargement. Maxilla and mandible are equally involved, and posterior teeth are more frequently involved than anterior teeth (Tai et al. 1993). This feature was observed in this patient who exhibited localized areas with wide periodontal ligament space (Figure 4).

Widening of periodontal ligament space is caused by excess of deposition of collagen fibers and sclerosis of collagen with decrease in number of connective tissue cells (Fullmer and Witte 1962). When the soft tissues around the TMJ are affected, they restrict movement of the mandible (Rowel and Hopper 1997).

Maintenance of existing dentition is important because microstomia and tongue rigidity can make the prosthetic replacement difficult. Oral exercises and stretching of the facial skin and oral musculature may help to maintain oral opening, oral health and mastication (Naylor, 1982). Use of increasing number of tongue blades between the posterior teeth to stretch the facial tissues is an effective technique to increase mouth opening. Patients with extensive resorption of the mandible are at risk for pathologic fractures from dental extractions.

Surgical procedures to enlarge the oral orifice have been described (Johns et al., 1998).

CONCLUSION

Dental practitioners should monitor PSS patients periodically, performing clinical and radiological examinations, so as to follow the course of the disease and prevent poor oral hygiene, loss of teeth, and periodontitis.

REFERENCES

- Cankaya H, Kabasakal Y (2001). Mandibular resorption due to progressive systemic sclerosis: a case report. *J. Oral Maxillofac. Surg.*, 59(5): 565-567.
- Caplan HI, Benny RA (1978). Total osteolysis of the mandibular condyle in progressive systemic sclerosis. *Oral Surg. Oral Med. Oral Pathol.*, 46(3): 362-366.
- Fischhoff DK, Sirois D (2000). Painful trigeminal neuropathy caused by severe mandibular resorption and nerve compression in a patient with systemic sclerosis: case report and literature review. *Oral Surg. Oral Med. Oral Pathol. Oral Radiol. Endod.*, 90(4): 456-459.
- Fullmer HM, Witte WE (1962). Periodontal membrane affected by scleroderma. *Arch. Pathol.*, 73: 184.
- Johns FR, Sandler NA, Ochs MW (1998). The use of a triangular pedicle flap for oral commissuroplasty: Report of a case. *J. Oral Maxillofac. Surg.*, 56(2): 228-231.
- Marmary Y, Glaiss R, Pisanty S (1981). Scleroderma: oral manifestations. *Oral Surg Oral Med. Oral Pathol.*, 52(1):32-7.
- Nagy G, Kovács J, Zeher M, Czirják L (1994). Analysis of the oral manifestations systemic sclerosis. *Oral Surg Oral Med. Oral Pathol.*, 77(2): 141-146.
- Naylor WP (1982). Oral management of the scleroderma patient. *J. Am. Dent. Assoc.*, 105(5): 814-817.
- Rowel NR, Hopper EE (1997). The periodontal membrane in systemic sclerosis. *Br. J. Dermatol.*, 96: 15-20.
- Rubin MM, Sonfilippo RJ (1998). Resorption of mandibular angle in progressive systemic sclerosis: Case report. *J. Oral Maxillofac. Surg.*, 50: 75-77.
- Tai CCE, Zee P, Wood RE (1993). Progressive systemic sclerosis in a child. Case report. *Pediatr. dent.*, 15(4): 275-279.
- Takehara K, Sato S (2005). Localized scleroderma is an autoimmune disorder. *Rheumatology (Oxford)*, 44(3): 274-279.
- Wardrop RW, Heggie AAC (1978). Progressive systemic sclerosis orofacial manifestations: Case report. *Austr. Dent. J.*, 32(4): 258-262.
- White SC, Frey NW, Blaschke DD, Ross MD, Clements PJ, Furst DE (1977). Oral radiographic changes in patients with progressive systemic sclerosis (scleroderma). *J. Am. Dent. Assoc.*, 94(6): 1178-1782.
- Zhou X, Tan FK, Xiong M, Milewicz DM, Feghali CA, Fritzler MJ (2001). Systemic sclerosis (scleroderma): specific autoantigen genes are selectively over expressed in scleroderma fibroblasts. *J. Immunol.*, 67(12): 7126-7133.