

*Full Length Research Paper*

## **Anti-ulcer activity of the 9alpha-bromo analogue of *Beclomethasone dipropionate* against ethanol-induced gastric mucosal injury in rats**

**Kamal A. Ketuly<sup>1\*</sup>, Mahmood A. Abdulla<sup>2</sup>, Hamid A. Hadi<sup>1</sup>, Abdalbasit A. Mariod<sup>3</sup> and Siddig Ibrahim Abdel-Wahab<sup>4</sup>**

<sup>1</sup>Department of Chemistry, Faculty of Science, University of Malaya, 50603, Kuala Lumpur, Malaysia.

<sup>2</sup>Department of Molecular Medicine, Faculty of Medicine, University of Malaya, 50603, Kuala Lumpur, Malaysia.

<sup>3</sup>Department of Food Science and Technology, College of Agricultural Studies, Sudan University of Science and Technology, P. O. Box 71, Khartoum North, Sudan.

<sup>4</sup>Institute of Bioscience, University Putra Malaysia, 43400 UPM Serdang, Selangor, Malaysia.

Accepted 17 November, 2010

The present study was performed to evaluate the anti-ulcer activity of the 9alpha-bromo analogue of *Beclomethasone dipropionate* against ethanol-induced gastric ulcer. Experimental groups were orally pre-treated with different doses of the 9alpha-bromo analogue of *B. dipropionate* in 10% Tween 20 solution. Ulcer control groups were pre-treated with vehicle solution and reference group was orally pre-treated with 20 mg/kg omeprazole. After one hour, all groups received absolute ethanol to generate gastric mucosal injury. After an additional hour, all rats were sacrificed and ulcer areas of gastric walls were determined. Grossly, ulcer control group exhibited severe mucosal injury, whereas pre-treatment with either omeprazole or the 9alpha-bromo analogue of *B. dipropionate* resulted in a significant decrease in acidity of gastric content, protection of gastric mucosal injury and increase in mucus production. Histological studies of gastric wall of ulcer control group revealed severe damage of gastric mucosa, along with edema and leucocyte infiltration of sub-mucosal layer compared to rats pre-treated with either omeprazole or 9alpha-bromo analogue of beclomethasone dipropionate. In conclusion, present finding suggests that the 9alpha-bromo analogue of *B. dipropionate* promotes ulcer protection as ascertained by the comparative decreases in ulcer areas, reduction of edema and leucocyte infiltration of the sub mucosal layer.

**Key words:** Natural products, *Beclomethasone dipropionate* derivatives, ulcer, cytoprotection.

### **INTRODUCTION**

*Beclomethasone dipropionate* (BDP) is a potent

glucocorticoid steroid and has various medicinal applications, such as treatment for the prophylaxis of asthma, rhinitis (e.g. hay fever) and sinusitis (Patton, 1998; Schreiber et al., 2004), severe canker sores, and severe inflammatory skin disorders (e.g. eczema) (Hoare et al., 2000). It is also licenced to treat ulcerative colitis in

\*Corresponding author. E-mail: [kketuly@yahoo.com](mailto:kketuly@yahoo.com). Tel: +6012-3658132. Fax: +603-79674193.

conjunction with doses of 5-aminosalicylates (Salofalk) in the United Kingdom in the form of a gastro-resistant, periodic release tablet marketed under the brand name "Clipper" (Rizzello et al., 2002). Previous studies were undertaken to synthesize and characterize BrBDP (Ketuly et al., 2009; Ketuly, 1988). Omeprazole is a proton pump inhibitor that has been widely used for about 15 years, to inhibit acid secretion in the treatment of disorders related to gastritis (Li et al., 2004). Omeprazole is a substituted benzimidazole that inhibits acid secretion by acting on the hydrogen-potassium pump ( $H^+K^+$ -ATPase) located in the apical plasma membrane of the gastric mucosa (Satoh et al., 1989). Omeprazole is highly selective for the proton pump and undergoes catalyzed conversion into active form within the acid forming space. The active inhibitors react with SH (thiol) group of the proton pump, resulting in inhibition of acid formation (Nagaya et al., 1991). In this study, omeprazole was used as the reference anti-ulcer drug. Absolute ethanol is a simple method used for inducing gastric ulcer in experimental rats resulting in severe gastric mucosal injury. Ethanol shows its harmful effects either through direct generation of reactive metabolites, including free radical species that react with most of the cell components, changing their structures and functions, or promotes enhanced oxidative damage (Kato et al., 1990; Nordmann, 1994). Ethanol damages the gastrointestinal mucosa by micro vascular injury, involving disruption of the vascular endothelium that results in increased vascular permeability, edema formation and epithelial lifting (Szabo et al., 1995). It produces necrotic lesions in the gastric mucosa by its direct toxic effect, reducing the secretion of bicarbonates and production of mucus (Marhuenda et al., 1993). Ethanol is metabolized in the body and releases superoxide anion and hydroperoxyl free radicals which are involved in the mechanism of acute and chronic ulceration in the gastric mucosa. Salim (1990) observed that administration of ethanol caused disturbances in gastric secretion, damage to the gastric mucosa, alterations in permeability, gastric mucus depletion and free radical production.

There are no data available regarding anti-ulcerogenic activity of the 9 $\alpha$ -bromo analogue of *Beclomethasone dipropionate* (BrBDP) in rats. Therefore, the present study was undertaken to evaluate the antiulcerogenic property of the synthesized and characterized BrBDP against ethanol-induced gastric mucosal injury in experimental rats.

## MATERIALS AND METHODS

Omeprazole was obtained from the University Malaya Medical Centre (UMMC) Pharmacy. The drug was dissolved in 10% Tween 20 solution and administered orally to the rats in concentrations of

20 mg/kg body (5 ml/kg) (Pedernera et al., 2006).

## Synthesis of BrBDP

BrBDP was synthesized following previously described method (Ketuly et al., 2009; Ketuly, 1988). In brief: 17 $\alpha$ , 21-Dihydroxy-16 $\beta$ -methylpregna-1,4,9-triene-3,20-dione-dipropionate (5.5 g) was allowed to react with bromodan (1,3-dibromo-5,5-dimethylhydantoin) (4.8 g) to give a yellow product (6.6 g). TLC showed one major product and five minor ones. The major product (3.0 g) was initially recrystallized three times, once from chloroform-methanol (1:2 v/v), and thereafter from hexane-methanol (1:1 v/v). The recovered material (1.8 g) was recrystallized from ethyl acetate-methanol (1:9 v/v) to give a white powder of BrBDP, m.p. 180 to 182°C. The BrBDP was dissolved in 10% Tween 20 solution and administered orally to rats in concentrations of 50, 100, and 200 mg/kg body weight (5 ml/kg body weight) (De Pasquale et al., 1995).

## Experimental animals

Adult male albinos wistar rats were obtained from the animal house, Faculty of Medicine, University of Malaya, Kuala Lumpur. All animals used for study has ethical clearance from the animal user's Committee of the Faculty of Medicine, University Malaya (Ethics No. PM 27/7/2011 MAA (R)). The rats weighed between 200 to 220 g. They were fasted for 48 h before the experiment (Garg et al., 1993), but were allowed free access to drinking water up till 2 h before the experiment. During the fasting period, the rats were placed individually in separate cages with wide-mesh wire bottoms. On the day of the experiment, the rats were randomly divided into 5 groups of 6 rats each. Throughout the experiments, all animals received human care according to the criteria outlined in the "Guide for the Care and Use of Laboratory Animals" prepared by the national academy of sciences and published by the national institute of health.

## Treatment

Gastric ulcer was induced by orogastric intubation of absolute ethanol (5 ml/kg) according to the method described by De Pasquale et al. (1995) with slight modification in adult male Wistar rats. Ulcer control groups were orally administered with vehicle (10% Tween 20). The reference group received oral doses of 20 mg/kg omeprazole in 10% Tween 20 as positive controls. Experimental groups were orally administered with 50, 100, and 200 mg/kg of BrBDP in 10% Tween 20 solution (5 ml/kg), respectively. One hour after this pre-treatment; all groups of rats were gavaged with absolute ethanol (5 ml/kg) in order to induce gastric ulcers.

The rats were euthanized by cervical dislocation 60 minutes later (Paiva et al., 1998) under an overdose of diethyl ether anesthesia and their stomachs were immediately excised.

## Measurement of acid of gastric juice

Each stomach was opened along the greater curvature. Samples of gastric contents were analyzed for hydrogen ion concentration by titration with 0.1 N NaOH solutions using digital pH meter. The acid content was expressed as mEq/l (Tan et al., 2002).

**Table 1.** Observed gastric content, ulcer area and inhibition percentage in rats.

Animal Group	Pre-treatment (5 ml/kg dose)	Mucus content	pH of gastric content	Ulcer area (mm) <sup>2</sup> (Mean ± S.E.M)	Inhibition (%)
1	10% Tween 20 (Ulcer control)	0.32 ± 0.01 <sup>a</sup>	3.99 ± 0.11 <sup>a</sup>	951.67 ± 14.00 <sup>a</sup>	-
2	Omeprazole (20 mg/kg)	0.56 ± 0.02 <sup>b</sup>	6.83 ± 0.03 <sup>b</sup>	181.67 ± 6.41 <sup>b</sup>	80.91
3	BrBDP (50 mg/kg)	0.74 ± 0.02 <sup>c</sup>	6.88 ± 0.16 <sup>b</sup>	270.00 ± 10.65 <sup>c</sup>	71.62
4	BrBDP (100 mg/kg)	0.84 ± 0.01 <sup>d</sup>	7.00 ± 0.06 <sup>b</sup>	145.83 ± 3.04 <sup>b</sup>	84.68
5	BrBDP (200 mg/kg)	0.58 ± 0.02 <sup>b</sup>	6.59 ± 0.10 <sup>b</sup>	80.33 ± 4.46 <sup>d</sup>	91.59

All values are expressed as mean ± standard error mean. Means with different superscripts are significantly different. The mean difference is significant at the  $p < 0.05$  level.

### Measurement of mucus production

Gastric mucus production was measured in the rats that were subjected to absolute ethanol-induced gastric mucosal injury. The gastric mucosa of each rat was gently scraped using a glass slide and the mucus obtained was weighed using a precision electronic balance (Tan et al., 2002).

### Gross gastric lesions evaluation

Any ulcers would be found in the gastric mucosa, appearing as elongated bands of hemorrhagic lesions parallel to the long axis of the stomach. Each gastric mucosa was thus examined for damage. The length (mm) and width (mm) of the ulcer on the gastric mucosa were measured by a planimeter ( $10 \times 10 \text{ mm}^2 = \text{ulcer area}$ ) under dissecting microscope ( $\times 1.8$ ).

The area of each ulcer lesion was measured by counting the number of small squares,  $2 \times 2 \text{ mm}$ , covering the length and width of each ulcer band. The sum of the areas of all lesions for each stomach was applied in the calculation of the ulcer area (UA) wherein the sum of small squares  $\times 4 \times 1.8 = \text{UA mm}^2$  as described by Kauffman and Grossman (1978) with slight modification. The inhibition percentage (I %) was calculated by the following formula as described by Njar et al. (1995) with slight modification.

$$(\%) = [(UA_{\text{control}} - UA_{\text{treated}}) \div UA_{\text{control}}] \times 100\%.$$

### Histological evaluation of gastric lesions

Specimens of the gastric walls from each rat were fixed in 10% buffered formalin and processed in a paraffin tissue processing machine. Sections of the stomach were made at a thickness of 5  $\mu\text{m}$  and stained with hematoxylin and eosin for histological evaluation.

### Statistical analysis

All values were reported as mean ± S.E.M. The statistical significance of differences amongst groups was assessed using one-way ANOVA. A value of  $p < 0.05$  was considered significant.

## RESULTS

### pH of gastric content and mucus production

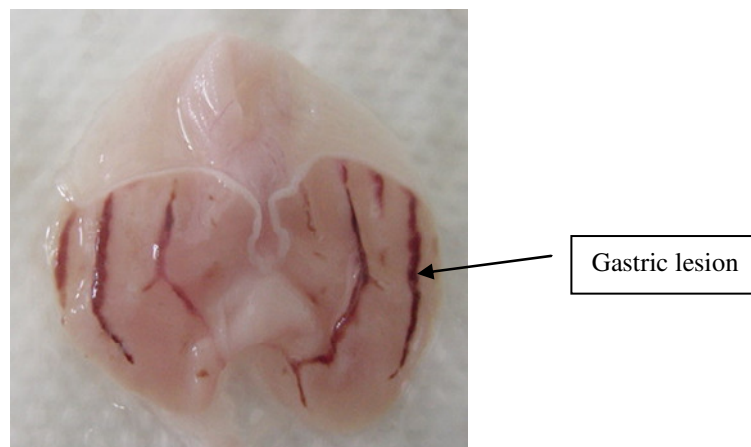
The acidity of gastric content in experimental animals pretreated with BrBDP was decreased significantly compared to that of the ulcer control group. The mucus production of gastric mucosa also increases significantly in animals pretreated with BrBDP compared to the untreated ulcer group (Table 1).

### Gross evaluation of gastric lesions

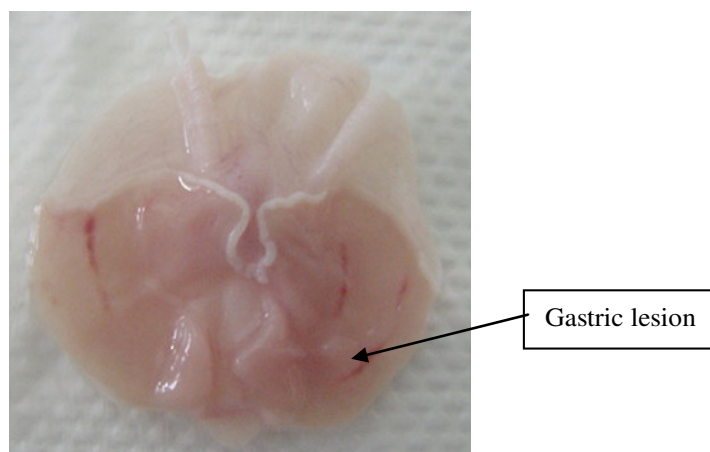
Rats pre-treated with either omeprazole or BrBDP then treated with absolute alcohol, had significantly reduced areas of gastric ulcer formation compared to rats pre-treated with vehicle, 10% Tween 20 solution (ulcer group) (Table 1), (Figure 1a, b and c). Moreover, BrBDP significantly suppressed the formation of the ulcers. It was also observed that protection of gastric mucosa was more prominent in rats pre-treated with 200 mg/kg of BrBDP (Table 1). Besides, ethanol-induced mucosal damage was significantly and dose-dependently reduced in the size and severity by pretreatment of the animals with BrBDP. There is significant inhibition of gastric ulcer in pretreatment with BrBDP as compared with omeprazole which is a standard drug used for curing gastric ulcer. A dose-dependent increase in mucus production was also observed when the BrBDP was given to rats.

### Histological evaluation of gastric lesions

Our microscopic observations of ethanol-induced gastric lesions in ulcer control rats (pre-treated with vehicle, 10% Tween 20), showed marked and extensive damage to the gastric mucosa, and oedema and leucocyte infiltration of the sub mucosal layer (Figure 1d). Rats that received



**Figure 1a.** Gross appearance of the gastric mucosa in a rat pre-treated with 10% Tween 20 solution (ulcer control). Severe injuries are seen in the gastric mucosa.



**Figure 1b.** Gross appearance of the gastric mucosa in a rat pre-treated with 20 mg/kg of omeprazole. Injuries to the gastric mucosa are milder compared to the injuries seen in the negative control rat.

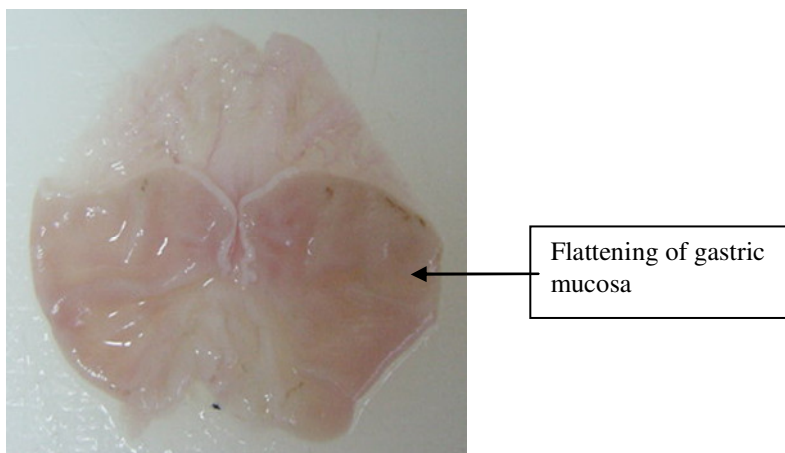
pre-treatment with either omeprazole or BrBDP had comparatively better protection of the gastric mucosa as seen by reduction in ulcerated area, reduced sub mucosal edema and absence of leucocyte infiltration (Figure 1e to f). This shows that BrBDP exerts a cytoprotective effect in a dose-dependant manner.

## DISCUSSION

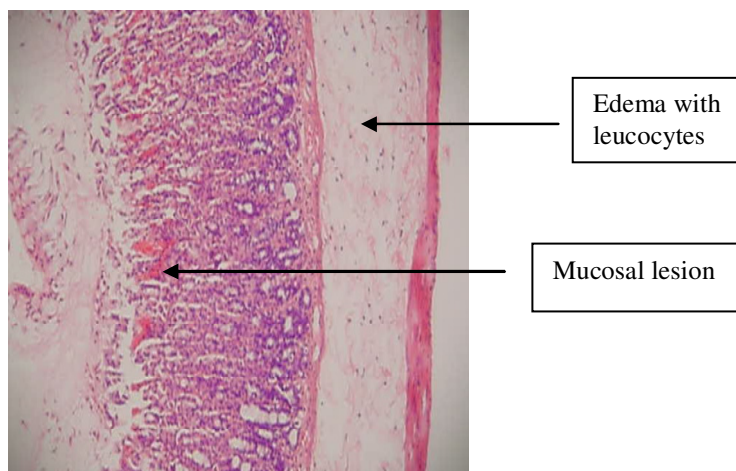
This study investigated the inhibitory effects of BrBDP on gastric ulcer formation induced by ethanol, compared to omeprazole, a drug whose ulcer healing effects have

been extensively studied, and to an ulcer control group (vehicle, 10% Tween 20). The BrBDP was found to have a protective effect on the gastric mucosa similar to that of omeprazole. Omeprazole and BrBDP were both found to be protective in comparison to control group (10% Tween 20). This suggests that BrBDP indeed has a significant anti-ulcer effect.

The main cause of gastric ulcer is destruction of the gastric mucosal barrier which consists of the surface epithelium and mucosal coat. This destruction may be due to either, an increase in gastric acid secretion, a decrease in mucus production or a decrease in mucosal blood flow (Abd El-Dayem and El-Agaimy, 1992).



**Figure 1c.** Gross appearance of the gastric mucosa in a rat pre-treated with 200 mg/kg of BrBDP. No injuries to the gastric mucosa are seen, and showed flattening of gastric mucosa.

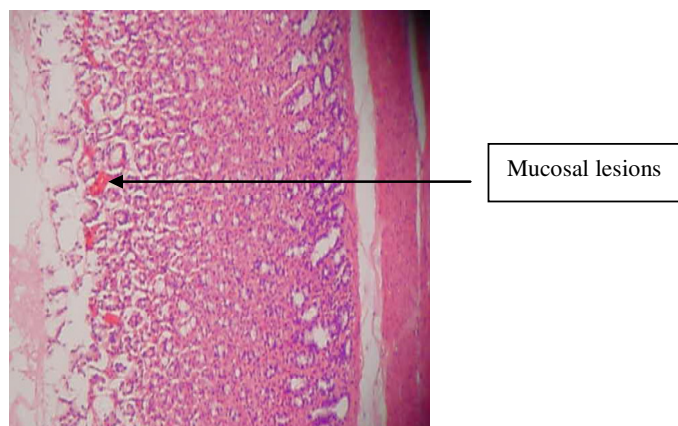


**Figure 1d.** Histological section of gastric mucosa in a rat pre-treated with 10% Tween 20 solution (ulcer control). There is severe disruption to the surface epithelium, and edema of the sub mucosa layer with leucocytes infiltration (H and E stain, 10x).

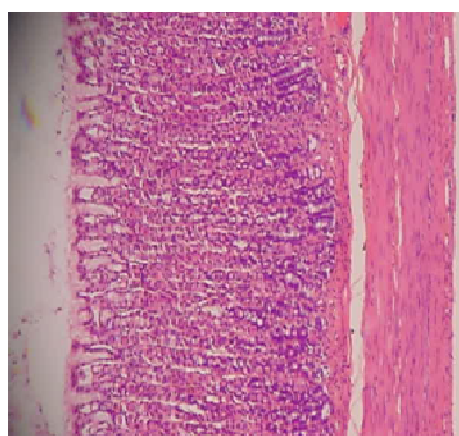
The results show that the BrBDP is capable of providing prophylactic anti-ulcer effects against an irritant substance. The BrBDP is capable of complete inhibiting lesion formation induced by ethanol. The accompanying significant dose-dependent increase in mucus production as a dose of the drug is increased, suggests that the gastric mucosal strengthening mechanism contributes to the anti-irritant potential of the BrBDP. It is evident from the mucus production that increased mucus production must have largely contributed to preventive effect of the BrBDP. Similar findings exist in the literatures, where

plant extracts have been shown to prevent gastric mucosal ulceration in rats (Rujjanawate et al., 2005; Tan et al., 2002). The mucus of the gastric wall is thought to play an important role as a defensive factor against gastrointestinal damage (Davenport, 1968). Pretreatment with BrBDP significantly decreases the acidity of the gastric content and increases the gastric mucus production. This suggests that gastro-protective effect of BrBDP is mediated partly by preservation of gastric mucus secretion.

The result of the present study also revealed protection



**Figure 1e.** Histological section of gastric mucosa in a rat pre-treated with 20 mg/kg of omeprazole. There is mild disruption to the surface epithelium with no edema and no leucocytes infiltration of the sub mucosal layer (H and E stain 10x).



**Figure 1f.** Histological section of gastric mucosa in a rat pre-treated with 200 mg/kg of BrBDP. There is no disruption to the surface epithelium with absence of edema and leucocytes infiltration of the sub mucosal layer (H and E stain 10x).

of gastric mucosa and inhibition of leucocyte infiltration of the gastric wall in rats pretreated with BrBDP. Similarly, Kobayashi et al. (2001) reported that teprenone exerts a protective effect against mucosal lesions through inhibition of neutrophil infiltration in the ulcerated gastric tissue. Shimizu et al. (2000) demonstrated that the reduction of neutrophil infiltration into ulcerated gastric tissue promotes the healing of gastric ulcers in rats. Cheng and Koo (2000) showed that oral administration of plant extract before ethanol administration significantly decreased neutrophil infiltration of gastric mucosa.

Absolute alcohol would extensively damage the gastric mucosa leading to increased neutrophil infiltration into the gastric mucosa. Oxygen free radicals derived from infiltrated neutrophils in ulcerated gastric tissues have an inhibitory effect on gastric ulcer healing in rats (Suzuki et al., 1998). Neutrophils mediate lipid peroxidation through the production of superoxide anions (Zimmerman et al., 1997). Neutrophils are a major source of inflammatory mediators and can release potent reactive oxidants such as superoxide, hydrogen peroxide and myeloperoxidase derived oxidants. These reactive species are highly

cytotoxic and can induce tissue damage (Cheng and Koo, 2000). Furthermore, neutrophil accumulation in gastric mucosa has been shown to induce microcirculatory abnormalities, Bou-Abboud et al. (1988). Suppression of neutrophil infiltration during inflammation was found to enhance gastric ulcer healing (Tsukimi et al., 1996).

## Conclusions

In conclusion it appears that BrBDP may significantly decrease the acid secretion in the gastric chamber and simultaneously protect the gastric mucosa against ethanol-induced injury. Such protection was shown to be dose-dependent as ascertained by the reduction or inhibition of ulcerated areas in the gastric wall as well as the reduction or inhibition of edema and leucocyte infiltration of sub mucosal layers. Protection was most prominent at a dose of 200 mg/kg of the drug substance compound.

## ACKNOWLEDGEMENTS

The authors express their gratitude to the staff of the Faculty of Medicine Animal House for the care and supply of rats, and to the University of Malaya for the financial support UMRG (RG102/09HTM).

## REFERENCES

- Abd El-Dayem A, El-Agaimy M (1992). Non-wood forest products, physico-chemical characteristics and fatty acid composition of three seed oils. *ISHS*, pp. 287-294.
- Bou-Abboud C, Wayland H, Paulsen G, Guth P (1988). Microcirculatory stasis precedes tissue necrosis in ethanol-induced gastric mucosal injury in the rat. *Dig. Dis. Sci.*, 33: 872-877.
- Cheng C, Koo M (2000). Effects of *Centella asiatica* on ethanol induced gastric mucosal lesions in rats. *Life Sci.*, 67: 2647-2653.
- Davenport H (1968). Destruction of the gastric mucosal barrier by detergents and urea. *Gastroenterol.*, 54: 175.
- De Pasquale R, German M, Keita A, Sanogo R, Iauk L (1995). Antiulcer activity of *Pteleopsis suberosa*. *J. ethnopharmacol.*, 47: 55-58.
- Garg G, Nigam S, Ogle C (1993). Gastric antiulcer effects of the leaves of the neem tree. *Planta medica*, 59: 215-215.
- Hoare C, Li W, Williams H (2000). Systematic review of treatments for atopic eczema. *Health technology assessment (Winchester, England)*, 4: 1.
- Kato S, Kawase T, Alderman J, Inatomi N, Lieber C (1990). Role of xanthine oxidase in ethanol-induced lipid peroxidation in rats. *Gastroenterol.*, 98: 203-210.
- Kauffman Jr G, Grossman M (1978). Prostaglandin and cimetidine inhibit the formation of ulcers produced by parenteral salicylates. *Gastroenterol.*, 75: 1099.
- Ketuly K, Aadi A, Ng S (2009). 9-Bromo analog of beclometasone dipropionate monohydrate. *Acta Crystallographica Section E: Structure Reports Online*, 65: o1821.
- Ketuly KA (1988). Glaxo Group Research (now Glaxo Smith Kline). In: *E. Report (Ed.)*, No. WAP/88/007, 1988.
- Kobayashi T, Ohta Y, Yoshino J, Nakazawa S (2001). Teprenone promotes the healing of acetic acid-induced chronic gastric ulcers in rats by inhibiting neutrophil infiltration and lipid peroxidation in ulcerated gastric tissues. *Pharmacol. Res.*, 43: 23-30.
- Li X, Andersson T, Ahlström M, Weidolf L (2004). Comparison of inhibitory effects of the proton pump-inhibiting drugs omeprazole, esomeprazole, lansoprazole, pantoprazole, and rabeprazole on human cytochrome P450 activities. *Drug Metab. Dispos.*, 32: 821.
- Marhuenda E, Martin M, De La A, Lastra C (1993). Antiulcerogenic activity of aescine in different experimental models. *Phytother. Res.*, 7: 13-16.
- Nagaya H, Inatomi N, Nohara A, Satoh H (1991). Effects of the enantiomers of lansoprazole (AG-1749) on (H<sup>+</sup> K<sup>+</sup>)-ATPase activity in canine gastric microsomes and acid formation in isolated canine parietal cells. *Biochem. Pharmacol.*, 42: 1875-1878.
- Njar V, Adesanwo J, Raji Y (1995). Methyl Angolenate: Antiulcer Agent from the Stem Bark of *Entandrophragma angolense*. *Planta Medica.*, 61: 91-91.
- Nordmann R (1994). Alcohol and antioxidant systems. *Alcohol Alcohol.*, 29: 513.
- Paiva L, Rao V, Gramosa N, Silveira E (1998). Gastroprotective effect of *Copaifera langsdorffii* oleo-resin on experimental gastric ulcer models in rats. *J. Ethnopharmacol.*, 62: 73-78.
- Patton J (1998). Breathing life into protein drugs. *Nat. Biotechnol.*, 16: 141-143.
- Pedernera A, Guardia T, Calderón C, Rotelli A, de la Rocha N, Genaro S, Pelzer L (2006). Anti-ulcerogenic and anti-inflammatory activity of the methanolic extract of *Larrea divaricata* Cav. in rat. *J. Ethnopharmacol.*, 105: 415-420.
- Rizzello F, Gionchetti P, D'Arienzo A, Manguso F, Di Matteo G, Annesse V, Valpiani D, Casetti T, Adamo S, Prada A (2002). Oral beclometasone dipropionate in the treatment of active ulcerative colitis: a double blind placebo controlled study. *Aliment. Pharmacol. Ther.*, 16: 1109-1116.
- Rujjanawate C, Kanjanapothi D, Amornlerdpison D, Pojanagaroon S (2005). Anti-gastric ulcer effect of *Kaempferia parviflora*. *J. Ethnopharmacol.*, 102: 120-122.
- Salim A (1990). Removing oxygen-derived free radicals stimulates healing of ethanol-induced erosive gastritis in the rat. *Dig.* 47: 24-28.
- Satoh H, Inatomi N, Nagaya H, Inada I, Nohara A, Nakamura N, Maki Y (1989). Antisecretory and antiulcer activities of a novel proton pump inhibitor AG-1749 in dogs and rats. *J. Pharmacol. Exp. Ther.*, 248: 806.
- Schreiber C, Hutchinson S, Webster C, Ames M, Richardson M, Powers C (2004). Prevalence of migraine in patients with a history of self-reported or physician-diagnosed "sinus" headache. *Arch. Intern. Med.*, 164: 1769.
- Shimizu N, Watanabe T, Arakawa T, Fujiwara Y, Higuchi K, Kuroki T (2000). Pentoxifylline accelerates gastric ulcer healing in rats: roles of tumor necrosis factor alpha and neutrophils during the early phase of ulcer healing. *Dig.*, 61: 157-164.
- Suzuki Y, Ishihara M, Segami T, Ito M (1998). Anti-ulcer effects of antioxidants, quercetin, -tocopherol, nifedipine and tetracycline in rats. *Jpn. J. Pharmacol.*, 78: 435-441.
- Szabo S, Kusstatscher S, Sakoulas G, Sandor Z, Vincze A, Jadus M (1995). Growth factors: new endogenous drugs' for ulcer healing. *Scand. J. Gastroenterol.*, 30: 15-18.
- Tan P, Nyasse B, Dimo T, Mezui C (2002). Gastric cytoprotective anti-ulcer effects of the leaf methanol extract of *Ocimum suave* (Lamiaceae) in rats. *J. Ethnopharmacol.*, 82: 69-74.
- Tsukimi Y, Nozue C, Okabe S (1996). Effects of leminoprazole, omeprazole and sucralfate on indomethacin-induced delayed healing of kissing gastric ulcers in rats. *J. Gastroenterol. Hepatol.*, 11: 335-340.
- Zimmerman J, Ciesielski W, Lewandoski J (1997). Neutrophil-mediated phospholipid peroxidation assessed by gas chromatography-mass spectroscopy. *Am. J. Physiol. Cell Physiol.*, 273: C653.