

Full Length Research Paper

Effects of hydromethanol hypocotyls extract of *Borassus aethiopum* on sperm and gonadal indices of male Wistar rats

Mansur A. Ramalan*, Adamu B. Shuaibu and Abdullahi H. Yaro

Department of Pharmacology and Therapeutics, Faculty of Pharmaceutical Sciences, Bayero University, Kano, Kano State, Nigeria.

Received 14 August, 2021; Accepted 20 October, 2021

Infertility resulting from sperm dysfunction is a serious health problem leading to psychological, economic, and medical implications worldwide. *Borassus aethiopum* is a plant that has been used as an aphrodisiac. This study evaluated the effect of hydromethanol hypocotyls extracts of *B. aethiopum* on the sperm and gonadal indices of male Wistar rats. The extract was prepared and administered orally at doses of (250, 500 and 1000 mg/kg) to 40 male Wistar rats, divided into four groups; three experimental groups and one control group (distilled water). Sperm parameters (count, motility, viability and morphology) and gonadal indices were determined. Testicular tissues were examined histologically for evidence of morphological changes. The extract increased significantly sperm count in a dose-dependent manner across all treatment groups ($p < 0.05$). Sperm viability was significantly increased in the treatment group after 7 days but was unaffected after 28 days of treatment. The histological examination of the testicular tissue showed evidence of increased spermatogenesis. Photomicrograph of the testes showed spermatogonia at different stages of maturation. Some areas of focal necrosis and evidence of spermatogenic arrest in the segment biopsied at the highest dose (1000 mg/kg) after 28 days of extract administration were observed. The results of this study suggest that the extract increases sperm count, motility and spermatogenesis at the doses tested and is likely to be beneficial in the management of male infertility.

Key words: Male infertility, *Borassus aethiopum*, sperm indices, aphrodisiacs.

INTRODUCTION

Infertility, with its attendant psychological, economic, medical implications is a big health problem globally (Elhussein et al., 2019). In our society, a strong emphasis on child-bearing results in stress, particularly to the couple and their immediate family members. The resultant

effect of these pressures is a major cause of psychosocial trauma, marital disharmony and instability (Elhussein et al., 2019). Male related factors are responsible for infertility in about 40 - 50% of cases of infertility (Kumar and Singh, 2015). Sperm dysfunction

*Corresponding author. E-mail: mmramalan@gmail.com. Tel: +2348036783737.

such as low sperm count, autoimmunity (anti-sperm antibodies) immaturity, abnormality and lack of motility have been reported in a previous study to be the main cause of infertility in males (Jarow, 2007).

Although the utilization of medicinal plants for aphrodisiac purposes is almost as old as the man (Chauhan et al. 2014), in recent times, there is still a lot of growing interest in the study of natural products that can enhance reproduction and improve fertility.

Borassus aethiopum (BA) is one of such plants that have been reported by several studies to be used as an Aphrodisiac agent in many parts of Nigeria, Cameroun (Akinniyi et al., 2010; Sabo et al., 2018), some parts of West Africa, Niger and Benin Republics (Bayero, 2015; Gbesso et al., 2016). The hypocotyl is the part of the plant used in Northern Nigeria as an aphrodisiac agent (Bayero, 2015; Sabo et al., 2018). It is a tropical plant whose various parts like roots, shoots, leaves, flowers and fruits have found usefulness in traditional treatment of some disease conditions like viral illnesses, skin diseases, and diarrhea (Gbesso et al. 2016). Scientific studies have reported that the plant possesses anti-inflammatory, (Sakande et al. 2013; Sarkodie et al. 2015), antioxidant, (Sakande et al. 2013; Aduwamai et al., 2020) anti-malarial, antibacterial, hypolipidemic (Peprah, 2017; Aduwamai et al., 2020) and antidiabetic effects (Nwachi, 2012; Larbie et al., 2016). To the best of our knowledge, the effects of *B. aethiopum* on spermatogenesis and sperm parameters have not been established. This study, therefore, aims at evaluating the effect of *B. aethiopum* hypocotyl extract on spermatogenesis and steroidogenesis in Wistar rats.

MATERIALS AND METHODS

Plant material

Samples of fresh hypocotyl of *B. aethiopum* were collected from a farm in Kumbotso local government area, Kano State, in October 2019. They were identified and authenticated at the Department of Plant Sciences of Bayero University, Kano, Nigeria. A voucher specimen (BUKHAN 276) of the plant was deposited at the herbarium of the University.

Preparation of plant material

The plant extract was prepared after detaching fresh shoot of *B. aethiopum* from the seed. The plant was subsequently dried and grounded into a powder with the aid of an electric blender. The powdered plant material was then extracted using seventy percent methanol (70/30 v/v) by cold maceration for two weeks until constant weight was attained. The obtained extract was dissolved in distilled water and administered orally.

Experimental procedure

Forty male Wistar rats (120-170 g body weights) were procured from the animal house of the Department of Pharmacology, Bayero University, Kano. The Experimental animals were kept in clean

cages under controlled laboratory conditions (temperature of 22±2°C and 12/12 h normal light/dark cycle) and allowed free access to food (Vital feed) and water. They were allowed to acclimatize to the laboratory environment for two weeks before the commencement of the experiments.

Ethical clearance was sought for and obtained from the ethical committee of Bayero University College of Health Sciences (Reference number BUK/CHS/REC/120). All experiments and animal handling were carried out according to the Bayero University Kano guidelines for the care and use of laboratory animals.

Experimental design

The animals were randomly divided into 4 groups of 10 rats each; Group 1 to 3 were given 250, 500 and 1000 mg/ kg body weight, respectively, of *B. aethiopum* hypocotyl extract corresponding to (5, 10 and 20%) of the LD₅₀, while group 4 were given 1 ml/kg of distilled water.

After days 7 and 28, five rats were isolated from each group, weighed and sacrificed for blood sample collection and study of the testicular tissues. The extract was administered to the treatment groups orally via an orogastric tube on daily basis for 28 days. The procedure described by Yakubu et al. (2005) was employed in the sacrifice of the animals. The rats were sacrificed after being anaesthetized the abdomen of the animals were incised through a transverse incision made along the ventral wall of each rat. The testes of the rats were carefully identified, excised and fixed in Bouin's fluid in preparation for histological analysis.

Histological procedure for examination of testicular tissue

The testicular tissues were fixed in Bouin's fluid for less than 24 h. The tissues were then processed via the paraffin wax embed method as described by Drury and Wallington (1980), Scheehan and Brapchak (1980) and Tietz (1995). Staining of the testicular tissues was done using H & E dyes (Haematoxylin and Eosin dyes) (Tietz, 1995).

Gonadosomatic index

Gonadosomatic index was calculated based on the body and testicular weight, from the formula:

$$\text{GSI} = [\text{Gonad weight(g)} / \text{Body weight(g)}] * 100 \text{ (Amman, 1970)}$$

Life-death ratio

The life-death ratio was taken as the total number of spermatozoa alive divided by the total number of spermatozoa multiplied by 100.

$$(\text{No. of spermatozoa alive} \div \text{Total No. of spermatozoa}) \times 100 \text{ (World Health Organization, 2010)}$$

Sperm deformity index (SDI)

The sperm deformity index was estimated following the method described by Aziz et al. (1996). It was calculated using the sum of sperm morphological deformities observed and the total numbers of sperm randomly selected and counted in a sperm population.

$$\text{Sperm deformity index} = \frac{\text{Total number of sperm defects}}{\text{Total number of sperm count}}$$

Table 1. Effect of the methanol hypocotyls extract of *B. aethiopum* on testicular indices of male rats.

Treatment groups		Parameter					
		Treatment Day 7			Treatment Day 28		
		TW(g)	FBW(g)	GSI (%)	TW(g)	FBW(g)	GSI(g)
<i>B. aethiopum</i> extract	Control	1.81±0.30	108.00±2.00	3.35±0.7	1.88±0.71	138.00±7.19	2.72±0.10
	250 mg/kg	1.98±0.05*	108.40±1.60	3.65±0.14	1.97±0.14*	118.40±7.19	3.37±0.20
	500 mg/kg	1.84±0.03*	107.20±2.89	3.43±0.10*	2.02±0.04*	119.41±3.87	3.41±0.18*
	1000 mg/kg	1.94±0.04*	112.20±2.29	3.46±0.06*	2.11±0.16*	123.00±5.96	3.56±0.48*

Control (DW), Sildenafil (5 mg/kg). Results expressed in mean±SEM (n=5) *significant p at p<0.05 compared with control after one-way ANOVA and Dunnet Post HOC analysis. Where; TW= Testicular Weight; FBW=Final Body Weight; GSI=Gonadosomatic Index.

Photomicrography

The photomicrographic sections were examined under a Leica DM750 research microscope. A digital camera Leica ICC50 HD attached to the microscope was used to take digital photomicrographs of the sections of the testicular tissue sections at different magnifications.

Data analysis

The software package Statistical Package for Social Sciences (SPSS) for windows version 22.0 (SPSS Inc., Chicago IL, USA) was used for analysis. Quantitative data were presented as Mean ± Standard Error of Mean. Difference in means across groups was measured using the analysis of variance (ANOVA) and statistical significance set at p < 0.05. The significant difference was further evaluated using the Dunnet post hoc test.

RESULTS

Percentage yield of the Plant Material

From 300 g of hypocotyl of *B. aethiopum*, 45 g of methanol extract was obtained. This shows that the percentage yield of the hypocotyl extract with respect to the starting material is 15%.

Effect of methanol hypocotyl extract of *B. aethiopum* on testicular indices of male rats

The administration of the extract in the male rats revealed a significant increase (p < 0.05) in the testicular weight and gonado-somatic indices in the extract-treated group when compared to the control group (distilled water) on both days 7 and 28 (p < 0.05) (Table 1).

Effect of *B. aethiopum* methanol hypocotyl extract on the sperm counts of male rats

The maximum sperm count observed was 40.68±13.05 after 28 days of treatment in a group treated at the dose

of 500 mg/kg. There was a statistically significant increase (p < 0.05) in sperm count of the extract administered groups at a dose of 250 and 500 mg/kg after 7 days of treatment and at all the doses tested at the end of 28 days of extract administration (Tables 2 and 3).

Effect of *B. aethiopum* methanol hypocotyl extract on the motility, viability and morphology of male rats

The motility of the sperm in the extract-treated group was significantly (p < 0.05) higher than the control group after 7 days of extract administration at doses of 250 and 1000 mg/kg, and at all the doses tested after 28 days of extract administration. Similarly, the results showed statistically significant (p < 0.05) increases in the sperm viability of the extract-treated animals when compared to the distilled water treated group (Tables 2 and 3). There was however, no statistically significant difference observed in the mean percentages of the sperm cells with normal morphology in the extract-treated groups when compared to the control group.

Effect of *B. aethiopum* methanol hypocotyl extracts on the testicular histology of male rats

Histological examinations of testicular tissue showed increased density of spermatogenic cells at various stages of maturation after 28 days of administration of the extract. However, at higher doses, (500 and 1000 mg/kg) there was some evidence of mild to moderate necrosis of the seminiferous epithelium in the BA-treated group when compared with the control group (Figure 1A to D).

DISCUSSION

In male reproductive health, sperm analysis including concentration, motility and morphology is accepted as the most reliable markers in evaluating male sexual male reproductive function. Mature sperms are the terminal cells that are incapable to go further division

Table 2. Effect of the methanol extract of *B. aethiopicum* hypocotyl on sperm count, morphology viability and motility of male rats monitored on day 7.

Parameter	Treatment group			
	<i>B. aethiopicum</i>			
	Control	250 mg/kg	500 mg/kg	1000 mg/kg
Sperm motility (%)	66.00±1.92	76.40±3.46*	61.80±2.75	84.00±2.99*
Sperm count (x10 ⁶ /ml)	20.58±1.92	36.32±3.46*	37.14±2.75*	33.12±2.99*
Sperm viability (%)	45.80±0.75	55.00±0.58*	58.60±0.51*	75.00±0.51*
Life-death ratio (%)	86.03±0.91	90.28±1.68	92.86±1.79*	95.44±2.32*
Sperm deformity Index	0.64±0.01	1.52±0.04*	1.64±0.11*	1.05±0.31*
Normal Morphology (%)	64.80±1.47	76.20±6.11	77.40±7.56	68.60±3.32
Abnormal Morphology (%)	35.20±2.41	23.80±2.77	22.60±3.54*	31.40±3.89
Tail defects (%)	16.40±1.16	14.31±1.64	13.89±1.17*	18.80±2.11
Head defects (%)	18.26±1.81	9.22±0.97*	7.73±1.41*	11.23±1.82*

Results expressed in mean±SEM (n=5) *significant p at p<0.05, compared with control after one-way ANOVA and Dunnet Post HOC analysis.

Table 3. Effect of the methanol extract of *B. aethiopicum* hypocotyl on sperm count, morphology viability and motility of male rats monitored on day 28.

Parameter	Treatment group			
	<i>B. aethiopicum</i>			
	Control	250 mg/kg	500 mg/kg	1000 mg/kg
Sperm motility (%)	50.20±1.41	60.80±1.77*	73.60±2.23*	62.00±1.72*
Sperm count (x10 ⁶ /ml)	23.78±3.72	30.30±5.64*	40.68±13.05*	35.78±6.30*
Sperm viability (%)	56.00±0.75	58.30±0.58	56.00±0.51	62.00±0.51*
Life-death ratio (%)	80.25±1.49	95.73±1.34*	93.86±1.33*	91.04±1.66
Sperm deformity index (%)	0.73±0.11	1.20±0.09*	1.64±0.13*	1.11±0.07*
Normal morphology (%)	67.40±1.47	74.80±6.11	75.20±7.56	67.80±3.32
Abnormal morphology (%)	32.60±2.41	25.20±2.77	24.80±3.54*	32.20±3.89*
Tail defects (%)	15.22±1.83	12.48±1.03*	12.39±1.07*	16.18±1.76
Head defects (%)	16.40±1.43	10.67±0.89*	9.83±1.01*	14.53±1.38

Results expressed in mean±SEM (n=5) *significant p at p<0.05, compared with control after one-way ANOVA and Dunnet Post HOC analysis.

or differentiation (Wiwat et al., 2020).

Male infertility is usually the result of deficiencies in the semen, the most common of which are low sperm count or oligospermia, poor sperm motility and abnormal sperm shape or teratozoospermia (Khaleghi et al., 2017; Akomolafe and Oboh, 2018; Wiwat et al., 2020).

Our observation of the increase in sperm count due to the extract administered could be due to the stimulatory activity of the extract on the pituitary gland leading to increases in the secretion of LH and FSH and the resultant effect of the activities of the two hormones on the testicular tissue causing increases in the serum levels of testosterone and increasing spermatogenesis on the Leydig and Sertoli cells respectively (Pavin et al., 2018; Haghmorad et al., 2019).

Sperm motility is the ability of sperm to move efficiently

and this movement is crucial in infertility because sperm needs to move through the reproductive tract of the female to reach and fertilize the ovum. Sperm motility generally reflects the viability of a sperm population and poor sperm motility can be a cause of male factor infertility (El-Desoky et al., 2017).

The present study showed that *B. aethiopicum* extract significantly increased sperm count and motility, however, sperm vitality and morphology were unaffected. Although, it was observed that the motility in the group treated at extract doses of 500 mg/kg was reduced, which it may be due to the fact that the animals in that group had a lower total body weight. Many herbal medicines have been reported to enhance sperm motility. A study on the positive effect of *Tribulus terrestris* extracts on human sperm motility *in vitro* has been reported by Khaleghi et

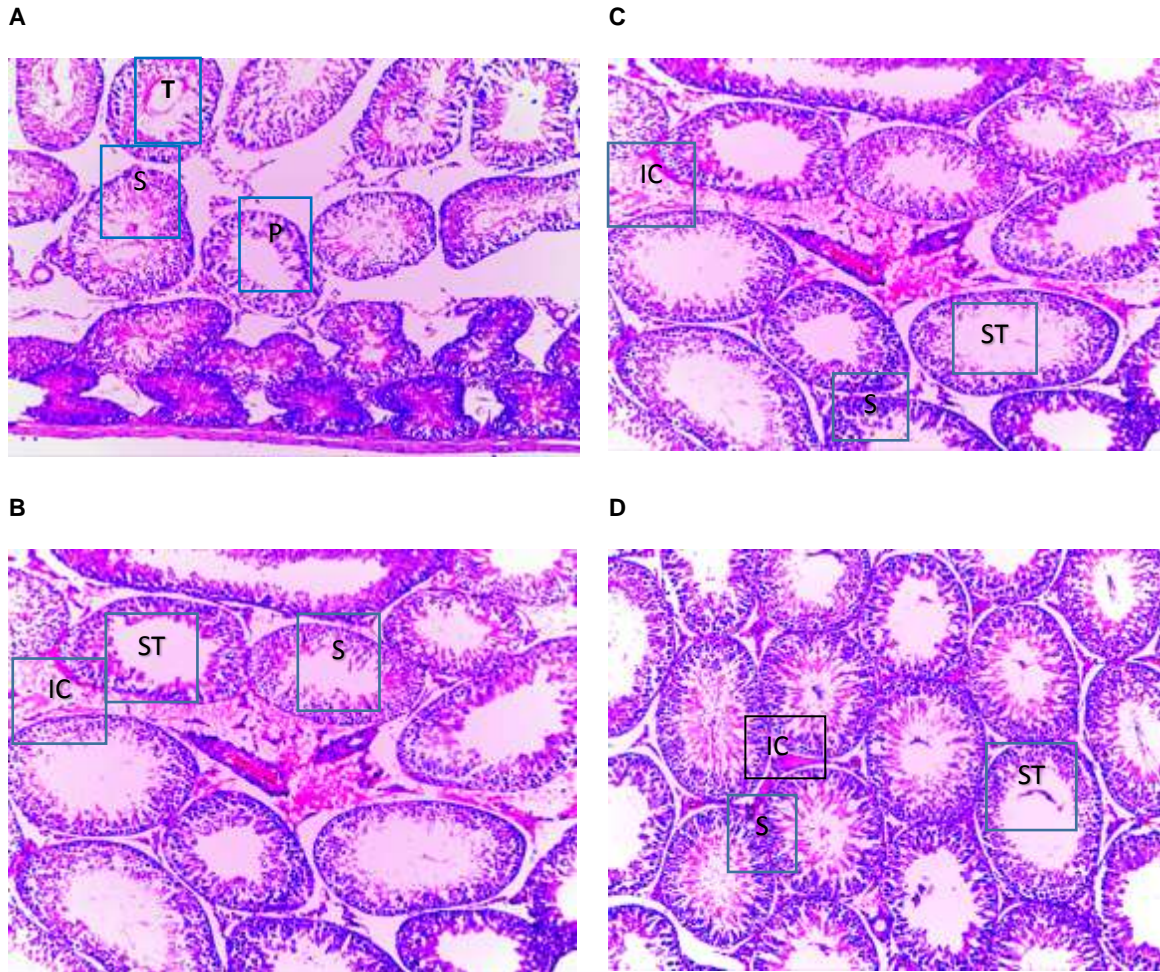


Figure 1. Showing photomicrograph of the testis. **A:** Photomicrograph of the testis in control rats (Treated with DW), showing normal seminiferous tubules (T), seminiferous tubule lumen containing normal primary spermatogonia (P) and secondary spermatogonia (S) (x 250 H&E). **B:** Photomicrograph of the seminiferous tubule in BA 250 mg/kg treated rats showing the seminiferous tubules with interspersed spermatogonia (S). Interstitial cells (IC) of Leydig are well demonstrated (x 250 H&E). **C:** Photomicrograph of testes in the extract-treated group (500mg/kg) shows intact seminiferous tubules (ST) of uniform size with orderly spermatogonia (S) at varying stages of maturation germ cell maturation variable around the tubule, supported by the Sertoli cells. **D:** Photomicrograph of the seminiferous tubule in BA 1000 mg/kg treated rats showing the seminiferous tubules (ST) with maturing spermatozoa and spermatogonia neatly arranged in different stages of maturation. (x 250 H&E).

al. (2017). It has also been shown *in vivo* to significantly increase sperm motility in mice (Khaleghi et al., 2017; Haghmorad et al., 2019; Ros-Santaella and Pintus 2021). Adequate sperm production indicates a lack of toxicity in the testicular tissue. Sperm quality is also used as an important indicator of chemically-induced toxicity on testis (Opuwari and Monsees, 2020; Qiqi et al., 2020).

The sperm deformity index (SDI) score is a novel expression of the quality of sperm morphology, which is a more powerful predictor of male fertility and of *in vitro* fertilization outcome compared with the assessment of the proportion of sperm with normal morphology (Aziz et al., 1996; Luo et al., 2021). The significant decreases in the sperm deformity index due to treatment with the

extract exhibited in this study may be due to the beneficial effect of the extract on sperm quality as previously reported by Adeyina et al. (2017) who showed that *B. aethiopum* can extend the life span of semen of chicken and increases its hatchability (Adeyina et al., 2017).

The absolute and relative weight of the testes in the rats receiving the extract was significantly increased when compared with the normal control group. Gonzales et al. (2001) suggested that any treatment inducing elevation of the weight of the sex organs may have androgenic activity. The finding in this study is similar to that of a previous study that reported the androgenic property of *B. aethiopum* hypocotyl extract (Akinniyi et al.,

2010), and a study on the effect of *Zanthoxylum macrophylla* on male rats (Alphonse et al., 2017). It is in tandem with the reports of the increase of the weight of these androgen-dependent organs (testis and seminal vesicles) following treatment with *Alchornea cordifolia*, in male rats (Ngaha Njila et al., 2019). Testicular organ weights are used as indicators of reproductive toxicity, and a reduction of testicular weight is a sensitive parameter for interpretation of male gonadal toxicity (Görmüş et al., 2020; Iftikar et al., 2021).

Following intake of the *B. aethiopicum* extract, no evidence of testicular injury was observed; instead, it showed normal seminiferous tubules containing an increased concentration of spermatogonia cells and mature spermatozoa with a slight indication of cellular proliferation compared to the control. A possible explanation for this effect could be due to the presence of some phytochemicals like tannins and phytosterols which have been reported to improve male reproductive functions (Nwachi, 2012; Gbesso et al., 2016). Other studies have suggested possible effects of antioxidants in these plants on various aspects of male reproductive functions. Antioxidants have been reported in high amounts in *B. aethiopicum* extract (Aduwamai et al., 2020).

Conclusion

This study showed that methanol hypocotyl extract of *B. aethiopicum* increases sperm count, motility and the gonad-somatic index. Based on the above findings, the plant may be beneficial in improving male reproductive function.

CONFLICT OF INTERESTS

The authors have not declared any conflict of interests.

ACKNOWLEDGEMENTS

This work would not have been completed without the support of the technical staff of the Pharmacology Laboratory, Department of Pharmacology and Therapeutics, Bayero University Kano. This research work is self-funded.

REFERENCES

Adeyina AO, Akanbi AS, Okupke KM, Alli OI, Ogbah OI, Ajao BH (2017). Effects of *Borassus aethiopicum* extract on semen characteristics, fertility and hatchability in chicken. *Journal of Agricultural Research and Development* 15(2):383-393

Aduwamai UH, Mahmud BA, Daniel D (2020). Antioxidant and Antihyperlipidemic Activity of Methanol Extract of *Borassus aethiopicum* Fruit in Triton X-100 Induced Hyperlipidemic Rats 9(2):35-44.

Akinniyi JA, Waziri M, Usman HS (2010). Assessment of the Anabolic Effect of Androgens of the Edible Portion of the Shoot of Giginya Plant (*Borassus aethiopicum* mart). *Journal of Scientific Research* 2(2):362-368.

Akomolafe SF, Oboh G (2018). Walnut leaf extract acts as a fertility agent in male Wistar albino rats – A search for herbal male fertility enhancer. *Journal of Complementary and Integrative Medicine* 15(2):1-14.

Alphonse N, Njila Marie N, Hubert K, Brice Landry K, Lembe Dieudonné M, Emma Fortune B, Paul M, Theophile D (2017). Evaluation of the fertility activity of the aqueous leaves extract of *Zanthoxylum macrophylla* (*Rutaceae*) on male rats. *The Journal of Phytopharmacology* 6(5):277-281.

Aziz N, Buchan I, Taylor C, Kingsland CR, Lewis-Jones I (1996). The sperm deformity index: a reliable predictor of the outcome of oocyte fertilization *in vitro*. *Fertility and Sterility* 66(6):1000-1008.

Bayero B (2015). Pharmacological effects of methanolic extract of *Garcinia kola* (*heckle*) seed on the reproductive profiles of some male experimental animals (July). The University of Jos, pp. 26 -54.

Chauhan NS, Sharma V, Dixit VK, Thakur M (2014). A Review on Plants Used for Improvement of Sexual Performance and Virility. *BioMed Research International* 2014:1-19.

Christopher L, Jeremiah I, Marina T (2016). Anti-diabetic effect of aqueous fruit extract of *Borassus aethiopicum* (*mart.*) In alloxan-induced diabetic rats. *International Journal of Phytomedicine* 8(3):384-397.

Dcunha R, Hussein RS, Ananda H, Kumari S, Adiga SK, Kannan, Zhao Y, Kathur GN (2020). Current Insights and Latest Updates in Sperm Motility and Associated Applications in Assisted Reproduction. *Reproductive Sciences* 7(1):1-19.

El-Desoky NI, Hashem NM, Elkomy A, Abo-elezz ZR (2017). Physiological response and semen quality of rabbit bucks supplemented with Moringa leaves ethanolic extract during summer season. *Animal* 11(9):1549-1557.

Elhusein OG, Ahmed MA, Suliman SO, Yahya LI, Adam I (2019). Epidemiology of infertility and characteristics of infertile couples requesting assisted reproduction in a low-resource setting in Africa, Sudan. *Fertility Research and Practice* 5(1):7-11.

Gbesso F, Adjatin A, Dansi AA (2016). Aphrodisiac Properties of Hypocotyls Extracts of *Borassus aethiopicum* Mart (*Arecaceae*) Collected in Central of Benin Republic. *International Journal of Current Microbiology and Applied Sciences* 5(3):802-814.

Görmüş G, Iğın S, Baysal M, Karaduman AB, Kılıç V, Aydoğan-Kılıç G, Karagöz O, Atlı-Eklioğlu Ö (2021). Risperidone induced reproductive toxicity in male rats targeting leydig cells and hypothalamic-pituitary-gonadal axis by inducing oxidative stress. *Andrologia* 53(1):1-11.

Gonzales GF (2001). Function of seminal vesicles and their role in male fertility. *Asian Journal of Andrology* 3(4):251-258.

Haghmorad D, Mahmoudi MB, Haghghi P, Alidadiani P, Shahvazian E, Tavasolian, Mahmoudi M (2019). Improvement of fertility parameters with *Tribulus Terrestris* and *Anacyclus Pyrethrum* treatment in male rats. *International Brazilian Journal of Urology* 45(5):1043-1054.

Sakande J, Kabre E, Lompo M, Pale E, Nikiema JB, Nacoulma OG, Sawadogo M, Guissou IP (2013). Anti-inflammatory and antioxidant activities of a fraction I1 of male inflorescences of *Borassus aethiopicum* Mart (*Arecaceae*). *American Journal of Biochemistry and Molecular Biology* 3(1):101-109.

Jarow JP (2007). Diagnostic Approach to the Infertile Male Patient. *Endocrinology and Metabolism Clinics of North America* 36(2):297-311.

Khaleghi S, Bakhtiari M, Asadmobini A, Esmaeili F (2017). *Tribulus terrestris* Extract Improves Human Sperm Parameters In Vitro. *Journal of Evidence-Based Complementary and Alternative Medicine* 22(3):407-412.

Khojasteh SMB, Khameneh RJ, Houresfsnd M, Yaldagard E (2016). A review on medicinal plants used for improvement of spermatogenesis. *Biology and Medicine* 8(4):1-7.

Kumar N, Singh A (2015). Trends of male factor infertility, an important cause of infertility: A review of literature. *Journal of Human Reproductive Sciences* 8(4):191-196.

Kumaresan A, das Gupta M, Datta TK, Morrell JM (2020). Sperm DNA Integrity and Male Fertility in Farm Animals: A Review. *Frontiers in*

- Veterinary Science 7(321):1-15.
- Kurkowska W, Bogacz A, Janiszewska M, Gabrys E, Tiszler M, Bellanti F, Kasperszys S, Machon-Grecka A, Dobrakowski M, Kasperczyk A (2020). Oxidative Stress is Associated with Reduced Sperm Motility in Normal Semen. *American Journal of Men's Health* 14(5):1-8. Available at <https://apps.who.int/iris/handle/10665/312342>.
- Luo Y, Wu S, Yuan J, Zhou H, Zhong Y, Zhang M, Li Q, Xu X, Sun X and Zhu D (2021). Evaluation of Prognostic Factors for Clinical Pregnancy Rate Following Artificial Insemination by Husband in the Chinese Population. *Frontiers in Medicine* 10(8):638560.
- Mbemya GT, Vieira LA, Canafistula FG, Pessoa ODL, Rodrigues, APR (2017). Reports on in vivo and in vitro contribution of medicinal plants to improve the female reproductive function. In *Reprodução and Climatério* 32(2):109-119.
- Meistrich ML (1999). Restoration of spermatogenesis by hormone treatment after cytotoxic therapy. *Acta Paediatrica, International Journal of Paediatrics, Supplement* 88(433):19-22.
- Ngaha Njila MI, Massoma Lembè D, Koloko BL, Yong Meng G, Ebrahimi M, Awad EA, Hassan BF, Kenmogne H (2019). Sperm parameters quality and reproductive effects of methanolic extract of *Alchornea cordifolia* leaves on senescent male rats. *Andrologia* 51(9):1-10.
- Nwachi UE. (2012). Effects of *Borassus aethiopium* Mesocarp Extracts in Alloxan-Induced Diabetic Rats [University of Nigeria Nsukka]. Assessed at http://www.unn.edu.ng/publications/files/images/Uche%20Phd%20Project%20_Last%20Final_.pdf
- Opuwari C, Monsees T (2020). Green tea consumption increases sperm concentration and viability in male rats and is safe for reproductive, liver and kidney health. *Scientific Reports* 10(1):1-14.
- Pavin NF, Izaguirry AP, Soares MB, Spiazzi CC, Mendez ASL, Leivas FG, dos Santos DB, Santos CFW (2018). *Tribulus terrestris* Protects against Male Reproductive Damage Induced by Cyclophosphamide in Mice. *Oxidative Medicine and Cellular Longevity* 28(1):1-9.
- Peprah M (2017). The Anti-Lipidemic Effect of *Borassus aethiopium* "Oman Kube" on Individuals with Cardiovascular Disease at the 37 Military Hospital in Accra, Ghana. Master thesis in philosophy, Kwame Nkrumah University of Science and Technology, Kumasi, Ghana.
- Qiqi Z, Xiaoheng L, Ren-Shan G (2020). Toxicological Effects of Cadmium on Mammalian Testis. *Frontiers in Genetics* 11(10):52.
- Ros-Santaella, JL, Pintus E (2021). Plant extracts as alternative additives for sperm preservation. *Antioxidants* 10(5):772.
- Sabo S, Otimenyin S, Uguru M, Bukar B (2018). Ethnobotanical survey of medicinal plants used as aphrodisiacs in Bauchi local government area. *Journal of Complementary and Alternative Medical Research* 4(4):1-13.
- Sarkodie AJ, Squire AS, Kretchy AI, Bekoe OE, Domozoro CYF, Ahiagbe KMJ, Emmanuella A, Edoh DA, Amponsah KI, Sakyiama M, Lamptey K, Affedzi SO, Duncan LJ, Debrah P, Nguessan BB, Nyarko KA (2015). *Borassus aethiopium*, a potential Medicinal Source of antioxidants, anti-inflammatory and antimicrobial agents. *Herbal Medicine* 2(13):1-7.
- Tietz NW. (1995). *Clinical Guide to Laboratory Tests*. (3rd ed., Ed.). W.B. Saunders Company.
- Valverde A, Barquero V, Carvajal V (2021). Applied biotechnology to study of boar semen quality. *Agronomia Mesoamericana* 32(2):662-680.
- Wiwat R, Helena EV, Juho-Antti M, Jorma T (2020). Hypogonadism and cryptorchidism. *Frontiers in Endocrinology* 10(906):1-27.
- World Health Organization (WHO) (2010). WHO laboratory manual for the examination and processing of human semen, 5th ed. World Health Organization. Available at <https://apps.who.int/iris/handle/10665/44261>
- Yumei L, Shunhong W, Jingru Y, Hua Z, Yufang Z, Mimi Z, Qing L, Xia X, Xiaofang S, Detu Z (2021). Evaluation of Prognostic Factors for Clinical Pregnancy Rate Following Artificial Insemination by Husband in the Chinese Population. *Frontiers in Medicine* 8(475):1-8.