

Full Length Research Paper

Screening of aerial parts of *Abutilon bidentatum* for hepatoprotective activity in rabbits

Sammia Yasmin^{1*}, Muhammad Akram Kashmiri² and Kalsoom Anwar³

¹School of Science and Technology, University of Management and Technology, Lahore, Pakistan.

²Chairman, Board of Intermediate and Secondary Education, Lahore, Pakistan.

³Center for Plant Product Research, Department of Chemistry, GC University, Lahore, Pakistan.

Accepted 30 August, 2010

The objective of this investigation was to study the hepatoprotective activity of aqueous methanolic extracts of aerial parts of *Abutilon bidentatum* on carbon tetra chloride (CCl₄) and paracetamol induced liver damage in rabbits. The extracts at different dosages, administered orally for three days, significantly decrease serum enzymes; Serum Glutamate Pyruvate Transaminase (SGPT), Serum Glutamate Oxaloacetate (SGOT), Alkaline Phosphate (ALKP), and direct bilirubin. Silymarin was used as a standard hepatoprotective agent. The biochemical observations were supplemented with histopathological examination of rabbit liver sections. The results of this study strongly indicated that aerial parts of *A. bidentatum* had potent hepatoprotective action against CCl₄ and paracetamol induced hepatic damage in rabbits. These findings revealed *A. bidentatum* an indigenous plant to be a potentially valuable herb for liver diseases.

Key words: *Abutilon bidentatum*, hepatoprotective activity, histopathology, paracetamol, CCl₄, silymarin.

INTRODUCTION

The utilization of bioassays for monitoring extracts, fractions, and compounds obtained from plants is frequently incorporated in phytochemical research. To explore the possibility of using the traditional medicine with proper chemical and pharmacological profiles, there has been a large volume of work aimed at scientific validation of efficacy of herbal drugs used in the traditional medicine (Fabricant et al., 2001). Modern medicine does not have suitable answers for many conditions such as liver disorder, asthma, cardiovascular disorder and other major ailments, whereas most important representative are of phytochemicals (Handa et al., 1989).

Malvaceae is a cosmopolitan family with 88 genera and more than 2300 species distributed in tropical, subtropical, and temperate regions. *Abutilon* is one of the important genres of this family (Nasir et al., 1979).

Various species of the genus *Abutilon* find use in indigenous medicines for the treatment of various ailments (Bagi et al., 1985; Rahuman et al., 2008). Among this, *Abutilon bidentatum*, *A. Rich* is an under shrub and distributed in India, Pakistan, Tropical Africa, China and Arabia. The only reference available in the literature on this species describes the presence of cholestane derivative (Jain et al., 1996). No information in the literature was found concerning its possible hepatoprotective effects. However, some experiments have shown hepatoprotective activities on some other species of genus *Abutilon* (Prochezian et al., 2005). The present study was conducted to evaluate the hepatoprotective effect of aqueous methanolic extract of aerial parts (leaves and flowers) of *A. bidentatum* in rabbits. As a control, its effects were compared to the known hepatoprotective agent, silymarin.

MATERIALS AND METHODS

Reagents Paracetamol (acetaminophen, 4-hydroxy acetanilide), carbon tetrachloride (CCl₄), silymarin, standard kits of serum

*Corresponding author. E-mail: sammiasamin@yahoo.com.
Tel: 0092-3008864139.

glutamate pyruvate transaminase (SGPT), Serum Glutamate Oxaloacetate (SGOT), alkaline phosphate (ALKP) and direct bilirubin (D.Bil) were purchased from Aldrich Chemicals Co. (Gill Ingham, Dorset, UK). All other reagents and solvents were analytical grade and purchased from either Sigma or Merck.

Plant materials

The aerial parts (leaves and flowers) of *A. bidentatum* collected from the district Lahore of province Punjab, Pakistan, in September 2008. The samples were authenticated by Dr. Zaheer-ud-Din Khan, Head of the department of Botany, GC University, Lahore, Pakistan. A voucher specimen (*A. bidentatum*; GC. Herb. Bot. 160) was deposited at Dr. Sultan Ahmad Herbarium, GC University, Lahore, Pakistan. Cleaned, shade dried and pulverized plant materials were soaked in 80% aq MeOH for 7, 5 and 3 days respectively at 25 - 30°C and filtered. The solution evaporated in vacuo gave a greenish brown semi solid extract (yield; 20.7%).

Animals

Rabbits of either sex (weighing 600-900g), obtained from PCSIR Laboratories Complex, Lahore Pakistan, were used for the study. The animals were housed at the animal house of the Department of Parasitology, University of Veterinary and Animal Sciences, Lahore, on a 12-h light/dark cycle under conditions of controlled temperature (25±1°C) and humidity (50±5°C). They were fed with standard diet and water *ad libitum* (National Institute of Health, 1985). Animals were acclimatized to their environment for one week prior to experimentation. All the experiments were performed according NIH guide lines for the care and use of the laboratory animals (National Institute of Health, 1985).

Phytochemical studies

All the extracts were evaluated for presence of various phytoconstituents by performing different qualitative chemical tests reported (Khandelwal et al., 2005).

Preliminary acute toxicity studies

Rabbits were divided into groups of six animals each. The control group received saline and other groups received 100 to 2000 mg/kg of test extract. Immediate after dosing, the animals were observed continuously for the first four hours and were observed for 48 h after extract administration to record the mortality (Jeyasekar et al., 1997).

Carbon tetrachloride induced hepatotoxicity

Thirty six healthy rabbits used in the study were divided into six groups (n=6 in each group). Group I (control) animals were administered with distilled water (1 ml/Kg) three times at 12 h intervals. Group II (CCl₄) received distilled water (1 ml/Kg) three times at 12 h intervals and received CCl₄, liquid paraffin (1:1, 0.5 ml/Kg) after 48 h of last dose of vehicle. Group III received standard drug silymarin (100 mg/kg) orally three times at 12 h interval. Test group animals (group IV-VI) were administered orally doses of 150, 300 and 500 mg/kg of aq MeOH extract, respectively, in the form of aqueous suspension, three times at 12 h interval. The group III-VI was administered simultaneously CCl₄: liquid paraffin (1:1, 0.5 ml/kg) after 48 h of administration of silymarin and extracts. Animals were sacrificed 36 h after the last treatment. Blood was collected,

allowed to clot and serum was separated by centrifugation at 2500 rpm at 37°C for 15 min and analyzed for various biochemical parameters (Prochezian et al., 2005).

Paracetamol induced hepatotoxicity

Thirty six healthy rabbits used in the study were randomly divided into six groups (n = 6 in each group). Group I (control) animals were administered with distilled water (1 ml/Kg) daily for three days. Group II (paracetamol) received distilled water (1 ml/Kg) once daily for three days and received paracetamol (2 g/kg) on day 3. Group III received standard drug silymarin (100 mg/kg) orally once daily for three days. Test group animals (group IV-VI) were administered orally doses of 150, 300 and 500 mg/kg of aq MeOH extract, respectively, in the form of aq suspension, once daily for three days. Groups III-VI was simultaneously administered paracetamol: distilled water (1:1, 2 g/kg) on day three after 30 min of administration of silymarin and extracts. Animals were sacrificed 48 h after the last treatment. Blood was collected, allowed to clot and serum was separated by centrifugation at 2500 rpm at 37°C for 15 min and analyzed for various biochemical parameters (Prochezian et al., 2005).

Biochemical determinations

The biochemical parameters like Serum Glutamate Oxaloacetate transaminase, Serum Glutamate Pyruvate Transaminase (Reitman et al., 1957), alkaline phosphate (Kind et al., 1954) and direct bilirubin (Mally et al., 1937) were assayed using standard assay kits.

Histopathological studies

One animal from the treated group showing maximal activity as indicated by improved biochemical parameters from each group were utilized for this purpose. The animals were sacrificed and the abdomen was cut open to removal the liver. The livers were quickly preserved in neutral buffered formalin. Histological liver sections were prepared as described previously by Luna et al., 1968. 5 mm thick pieces of the liver were fixed in different concentrations of EtOH, then embedded in paraffin, and stained, using haematoxylin eosin dye and finally observed under microscope for histopathological changes in liver architecture and their photographs were taken to check the inflammation and necrosis of hepatocytes.

Data analysis

All data are expressed as means ± SD. ANOVA was used to evaluate the difference between multiple groups. P < 0.05 was considered to be significant.

RESULTS

Phytochemical study

Extracts subjected for phytochemical study showed the presence of flavonoids, alkaloids, carbohydrates, proteins, amino acids, phenolic compounds and glycosides.

Acute toxicity studies

Aqueous methanolic extract of *A. bidentatum* did not

Table 1. Effect of *A. bidentatum* extracts and silymarin pre treatment on biochemical parameters of the rabbits intoxicated with CCl₄.

Group	Design of treatment	SGOT (U/L)	SGPT (U/L)	ALKP (U/L)	D. Bil (mg/dL)
I	Control	61.05 ± 1.85	57.55 ± 2.49	138.31 ± 4.57	0.91 ± 0.03
II	CCl ₄	216.04 ± 5.74	116.70 ± 4.04	446.39 ± 6.58	1.47 ± 0.05
III	Silymarin + CCl ₄	89.49 ± 3.09	56.26 ± 3.62	139.94 ± 2.36	0.49 ± 0.03
IV	<i>A. bidentatum</i> (150 mg/kg) + CCl ₄	121.15 ± 4.61	106.79 ± 4.94	159.86 ± 2.59	1.46 ± 0.11
V	<i>A. bidentatum</i> (300 mg/kg) + CCl ₄	90.79 ± 2.13	93.42 ± 1.58	192.41 ± 2.51	1.08 ± 0.07
VI	<i>A. bidentatum</i> (500 mg/kg) + CCl ₄	72.37 ± 2.56	79.11 ± 4.04	164.35 ± 4.33	0.84 ± 0.02

Table 2. Effect of *A. bidentatum* extract and silymarin pre treatment on bio-chemical parameters of the rabbits, intoxicated with paracetamol.

Group	Design of treatment	SGOT U/L	SGPT U/L	ALKP U/L	D. Bil mg/dL
I	control	67.1 ± 3.15	50.46 ± 1.58	96.62 ± 3.39	0.86 ± 0.02
II	Paracetamol	109.61 ± 5.12	160.43 ± 8.60	363.50 ± 6.56	3.27 ± 1.11
III	Silymarin + Paracetamol	67.85 ± 3.22	46.45 ± 2.34	121.70 ± 3.06	0.53 ± 0.09
IV	<i>A. bidentatum</i> (150 mg/kg) + Paracetamol	93.36 ± 1.79	102.39 ± 6.03	179.31 ± 4.41	1.53 ± 0.05
V	<i>A. bidentatum</i> (300 mg/kg) + Paracetamol	85.16 ± 2.01	86.74 ± 4.80	170.13 ± 2.11	0.70 ± 0.04
VI	<i>A. bidentatum</i> (500 mg/kg) + Paracetamol	72.70 ± 3.22	60.29 ± 3.83	126.89 ± 4.65	0.58 ± 0.04

show any sign and symptoms of toxicity and mortality up to 2000 mg/kg dose. These results indicate that *A. bidentatum*, when consumed in quantities below 2000 mg/kg, will not effect the liver, an indication that the LD50 of the plant is higher than 2000 mg/kg as no mortality was recorded in any group of experimental rabbits.

Biochemical observations

In biochemical analysis tests were performed to assess hepatocellular membrane integrity and liver injury and the results were given in Table 1 and 2. It is well known that carbon tetrachloride is used as a hepatotoxic agent on various animals (Johnson et al., 1998; Recknagel et al., 1983). Administration of CCl₄ to rabbits produced hepatotoxicity showed by significant increase in the serum levels of SGOT, SGPT, ALKP and D.Bil in comparison to control group. The aqueous methanolic extract of *A. bidentatum* showed a significant decrease in the serum enzymes when compared to the CCl₄ compared control groups. Standard drug, silymarin (100 mg/kg) also exhibited similar results. The rabbits treated with aq methanolic extract of *A. bidentatum* showed (Table 2) significant reduction in all the biochemical parameters elevated by paracetamol. This reduction in biochemical parameters is similar to silymarin. CCl₄ produces more toxic effects on liver than paracetamol. There was also a significant dose-dependent difference in the activities of the high-dose and the low-dose groups. The elevations in liver function parameters as found in this work are not such that should discourage or indicates

its non-hepatotoxic effect.

Histopathological observations

The histopathological profile of the rabbits treated with aq methanolic extract showed no visible changes, confirming the safety of the extract at selected dose (Figure 1). The control group (group I) also showed normal cellular architecture with well brought out central vein, well presented cytoplasm and prominent nucleus (Figure 2). The liver sections of paracetamol and CCl₄ treated animals showed hepatic cells with severe toxicity characterized by disarrangement and degeneration of normal hepatic cells with intense centrilobular necrosis (Figures 3 - 4). Rabbits treated with silymarin and intoxicated with CCl₄ and paracetamol showed less disarrangement and degeneration of hepatocytes, indicating marked regeneration activity (Figure 4).

DISCUSSION

Liver injury can be caused by toxic chemicals, drugs, and viral infiltration from infection by ingestion. It is well known that carbon tetrachloride is used as a hepatotoxic agent on various animals (Recknagel et al., 1983, 1989). The most remarkable pathological characteristic of CCl₄-induced hepatotoxicity are fatty liver, cirrhosis and necrosis which are formed due to the free radical CCl₃. metabolized by the mixed function cytochrome p450 in the endoplasmic reticulum (Recknagel et al., 1989). Paracetamol an analgesic and antipyretic is assumed to

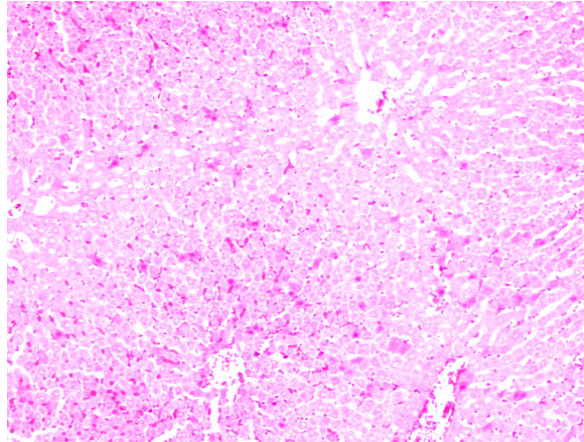


Figure 1. Liver of rabbit treated with aq methanolic extract of *A. bidentatum*.

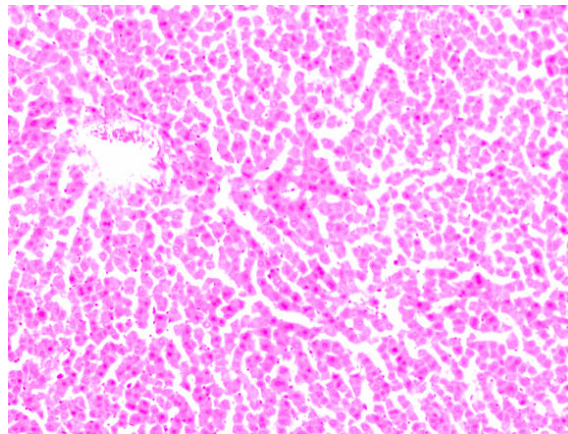


Figure 2. Liver of rabbit treated with normal diet.

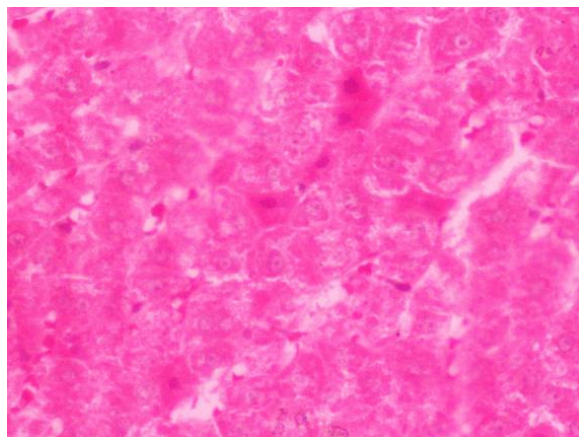


Figure 3. Liver of rabbit treated with paracetamol.

be safe in low doses. Small doses are eliminated by conjugation followed by excretion but increased doses produce liver necrosis (Dahlin et al., 1984). Liver injury

induced by paracetamol is the best characterized system of xenobiotics induced hepatotoxicity in human beings. Both CCl₄ and paracetamol intoxication in normal rabbits

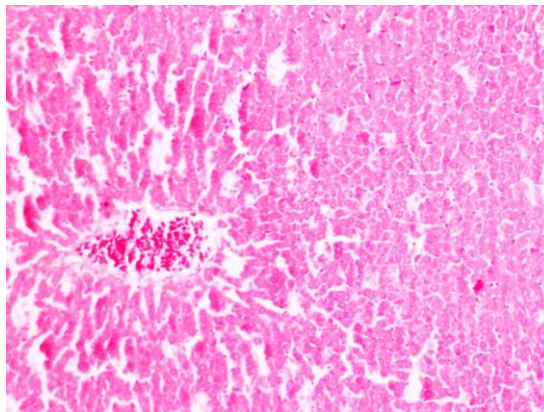


Figure 4. Liver of rabbit treated with CCl₄.

elevated the levels of SGPT, SGOT, ALKP and D.Bil significantly, indicating acute centrilobular necrosis. The rabbits treated with aqueous methanolic extract of *A. bidentatum* showed (Tables 1 and 2) significant reduction in all the biochemical parameters elevated by CCl₄ and paracetamol. This reduction in biochemical parameters is similar when compared with that of silymarin. Since the phytochemical analysis of the extracts had shown the presence of flavonoids and phenolic compounds, which had been known for their antioxidant and hepatoprotective activities (Carlo et al., 1999), thus it can be concluded that possible mechanism of hepatoprotective activity may be due to the presence of flavonoids and phenolic compounds in the extracts. More work needs to be conducted to elucidate viable potentials of *A. bidentatum*.

ACKNOWLEDGEMENTS

The authors are grateful to Higher Education Commission of Pakistan for research grant No. 042-121289-PS2-212, to the plant taxonomist, Dr. Zaheer-ud-Din Khan (Department of Botany, GC University, Lahore, Pakistan) for the collection of plant material and to Dr Tipu of the WTO Department of University of Veterinary and Animal Sciences, Lahore, Pakistan for providing all possible facilities to carry out studies on animals.

REFERENCES

- Bagi MK, Kalyani GA, Denis TJ, Kumar KA, Kakrani HK (1985). A preliminary pharmacological screening of *Abutilon indicum*: II Analgesic activity. *Fitoterapia*, 56: 169-171.
- Clawson GA (1989). Mechanism of carbon tetrachloride hepatotoxicity. *Pathol. Immunopathol Res.*, 8: 104-112.
- Dahlin DC, Miwa GT, Lu AY, Nelson SD (1984). N-acetyl-p-benzoquinone imine: a cytochrome P-450 mediated oxidation product of acetaminophen. *Proc. Natl. Acad. Sci.*, 81: 1327-1331.
- Di Carlo G, Mascolo N, Izzo AA, Capasso F (1999). Flavonoids: old and new aspects of a class of natural therapeutic drugs. *Life Sci.*, 65: 337-353.
- Fabricant DS, Farnsworth NR (2001). The value of plants used in traditional medicine for drug discovery. *Environ. Health Perspect.*, 109: 69-75.
- Handa SS, Kapoor VK (1989). *International book of Pharmacognosy*, New Delhi, Vallabh Prakashan, p. 125.
- Jain R, Jain SC, Arora R (1996). A new cholestane derivative of *Abutilon bidentatum* Hochst. and its bioactivity. *Pharmazie*, 51: 253.
- Jeyasekar P, Mohanan PV, Rathinak K (1997). Hepatoprotective activity of ethyl acetate extract of *Acacia catechu*. *Indian J. Pharmacol.*, 29: 426-428.
- Johnson DE, Kroening C (1998). Mechanism of early carbon tetrachloride toxicity in cultured rat hepatocytes. *Pharmacol. Toxicol.*, 83: 231-239.
- Khandelwal KR (2005). *Practical Pharmacognosy*, XIV ed. Nirali Prakashan, Pune, pp. 149-153.
- Kind PRN, King EJ (1954). Estimation of plasma phosphatase by determination of hydrolysed phenol with amino-antipyrine. *J. Clin. Pathol.*, 7: 322-326.
- Luna LG (1968). *Manual of Histology, Staining Methods of Armed Forces*, Institute of Pathology, 3rd ed., McGraw Hill Book Co., New York, p. 43.
- Mally HT, Evelyn KA (1937). Estimation of serum bilirubin level. *J. Biol. Chem.*, 119: 481.
- Nasir E, Ali SI (1979). *Flora of West Pakistan, Malvaceae*, Department of Botany, University of Karachi, 130: 69-72.
- National Institute of health (1985). *Guide for the care and use of laboratory animals*. NIH contact no. NOI-RR-2-2135. NIH, Bethesda, MD, pp. 11-28.
- Prochezian E, Ansari SH (2005). Hepatoprotective activity of *Abutilon indicum* on experimental liver damage in rats. *Phytomed.*, 12: 62-64.
- Rahuman A, Gopalakrishnan G, Venkatesan P, Geeta K (2008). Isolation and identification of mosquito larvicidal compound from *Abutilon indicum* (Linn.) sweet. *Parasitol. Res.*, 102: 981-988.
- Recknagel RO, Glende EA, Jr Dolak JA, Waller RL (1989). Mechanism of carbon tetrachloride toxicity. *Pharmacol. Ther.*, 43: 139-154.
- Recknagel RO (1983). A new direction in the study of carbon tetrachloride hepatotoxicity. *Life Sci.*, 33: 401-408.
- Reitman S, Frankel S (1957). In vitro determination of transaminase activity in serum. *Am. J. Clin. Pathol.*, 28: 56-63.