

*Full Length Research Paper*

# **Amazonian andiroba oil (*Carapa guianensis* Aubl.) minimizes the formation of postoperative adhesions in the uterus and ovaries of sheep**

**Francisco Monteiro<sup>1\*</sup>, Adriana Barbosa<sup>2</sup>, Gabriela Santos<sup>2</sup>, Daniella Bezerra<sup>2</sup>, Luisa Borges<sup>2</sup>, Luciana Siqueira<sup>2</sup>, Kayan Rossy<sup>2</sup>, Rodrigo Albuquerque<sup>2</sup>, Thiago Cardoso<sup>2</sup>, Carolina João<sup>2</sup> and Pedro Paulo Teixeira<sup>2</sup>**

<sup>1</sup>IFTO/Campus Araguatins, Brazil.

<sup>2</sup>Institute of Veterinary Medicine, Federal University of Pará (UFPA), Castanhal Campus Brazil.

Received 7 November, 2022; Accepted 6 February, 2023

**Postoperative adhesions (POA) are postsurgical fibrinolytic connections that can cause complications, and alternative materials have drawn attention to their prevention. The aim of this study is to evaluate the effect of andiroba oil in preventing POA in the uterus and ovaries of sheep. Sixteen female Santa Inês adult sheep were randomly divided into two groups, a control group (CCG) with eight of them submitted to surgical trauma caused by bipolar diathermy in the uterine horn and right ovary without treatment to prevent POA and another group (AAG) with another eight ewes that underwent the same trauma, but were treated with the application of andiroba oil on the traumatized surfaces. Fifteen days after surgical trauma, the occurrence of POA and laparoscopic adhesiolysis were evaluated. The bipolar diathermy was able to cause POA in 75% of the sheep. Bipolar diathermy caused POA in 100% of the CCG ewes and 50% of the AAG ewes. In CCG animals with adherence, in 25% of them, it was possible to perform adhesiolysis partially. Andiroba oil did not completely prevent the formation of postoperative adhesions in the uterus and ovaries of sheep, but it did prevent the formation of dense adhesions, facilitating laparoscopic adhesiolysis.**

**Key words:** Postoperative adhesiogenesis, laparoscopic adhesiolysis, reproductive tract, video surgery.

## **INTRODUCTION**

Postoperative adhesions (POA) are fibrinolytic connections that form between tissue surfaces, as a natural consequence of trauma and postsurgical scarring (Penzias et al., 2019; Hassanabad et al., 2021). They are complications that can cause pain, obstructions and infertility (Moris et al., 2017). Preventing these adhesions requires strategies that target less damage, less tissue

manipulation, and less physical contact between traumatized surfaces (De Wilde et al., 2017; Park et al., 2020). The use of an animal model in research with regard to the prevention of POA is common, and has generated promising results in animals of the sheep species (Vediappan et al., 2020). Amazonian ethnobotanical research can provide successful scientific discoveries

\*Corresponding author. E-mail: [deciomonteiro@ifto.edu.br](mailto:deciomonteiro@ifto.edu.br).

due to the wide phytotherapeutic diversity that in this biome (Araújo et al., 2018).

Andiroba oil is an Amazonian herbal medicine extracted from the seed of *Carapa guianensis* Aubl. (Meliaceae) with medicinal, therapeutic, and pharmacological properties (Oliveira et al., 2018; Soares et al., 2021). This oil is rich in fatty acids, especially oleic, palmitic, linoleic, and stearic acids with a significant antioxidant and anti-inflammatory action (Araujo-Lima et al., 2018; Kheilnezhad and Hadjizadeh, 2021).

As andiroba oil has important non-sticky properties, it is widely used in the Amazon and has low cost. The aim of this study was to evaluate the effect of andiroba oil in preventing POA in the uterus and ovaries of sheep submitted to tissue trauma by bipolar diathermy.

## MATERIALS AND METHODS

### Ethical approval

The research was approved by the Ethics Committee on the Use of Animals at the Universidade de Federal do Pará (CEUA/UFPA No. 7816250216). Therefore, it complied with the recommendations of the National Council for the Control of Animal Experiments in Brazil (CONCEA), and was in accordance with the Brazilian legislation that regulated the use of animals in animal research. The procedures performed on the sheep did not cause pain or suffering to the animals, as they were performed on anesthetized animals, complying with all the requirements of the Animal Use Ethics Council and regulations, based on the principles of the 3Rs (Clark, 2018; Strech and Dirnagl, 2019).

### Origin and chemical analysis of andiroba oil

The sterile andiroba oil used was purchased from a commercial representative of the brand (Amazon oil industry, Ananindeua, Pará, Brazil) and subjected to chemical analysis at the Department of Chemistry of the Federal University of Pará by the method of gas chromatography, coupled with a flame ionization detector (Gas Chromatography with Flame Ionization Detector – GC-FID) to determine the lipid profile.

The oil sample was processed in the GC 2010-Plus equipment (Shimadzu, Kyoto, Japan) equipped with a split/splitless injector, AOC 20-1 auto injector, and flame ionization detector (FID). The analyses were performed using a column, CP-Sill 88, 100 m long, with 0.25 mm and 0.2 µm film thickness, for Faster Adoption and Manufacturing of Hybrid and Electric vehicle (FAME) (Agilent Technologies, Santa Clara, CA, USA), under the following operating conditions: FID at 270°C, with temperature at 220°C for 5 min, followed by 220 to 240°C for 10 min, with a linear velocity of H<sub>2</sub> at 23.6 cm/s, and a split mode injection.

### Animals and study groups

Sixteen female Santa Inês adult sheep, multiparous, aged between two and five years, healthy, body weight from 30 to 40 kg, and mean body condition score of 3, considering a scale of 1-5 were used (Tamponi et al., 2021). The animals were kept on the premises of the Veterinary Hospital of the Institute of Veterinary Medicine, Federal University of Pará (IMEV/UFPA), in 16 m<sup>2</sup> collective pens, pre-adapted for 30 days, where they received grass cut from *Pennisetum purpureum* Schumacher (Poaceae) daily, the

variety was Cameron, balanced feed (Ovimax Campo, Qualy Nutrição Animal, SP, Brazil), ready-made mineral supplementation (Top Line Ovino, Matsuda, GO, Brazil), and water *ad libitum*.

The sheep were randomly divided into two groups, a control group with eight of them submitted to surgical trauma caused by bipolar diathermy in the uterine horn and right ovary without treatment to prevent POA (CCG, n = 8) and another group with another eight ewes that underwent the same trauma, but were treated with the application of andiroba oil on the traumatized surfaces (AAG, n = 8).

### Model for induction of postoperative adhesion in sheep uterus and ovaries

The sheep were subjected to water and food fasting for 36 h before the procedure, with an anti-inflammatory drug, flunixin meglumine 50 mg/mL (Flunixinamine®, Zoetis, SP, Brazil), at a dose of 1 mg/kg BID (Bis in die), being administered during this period. Pre-anesthesia was performed with 1% acepromazine maleate (Acepromazin 1%®, Syntec, SP, Brazil) in a single dose of 0.05 mg/kg, intramuscularly. Anesthetic induction was performed 10 min after the pre-anesthetic medication with 1% propofol (Propovan®, Cristalia, SP, Brazil) at a single dose of 6 mg/kg, intravenously. Orotracheal intubation was performed for anesthetic maintenance by inhalation in a closed circuit with isoflurane (Isoforine®, Cristalia, SP, Brazil) and 100% oxygen.

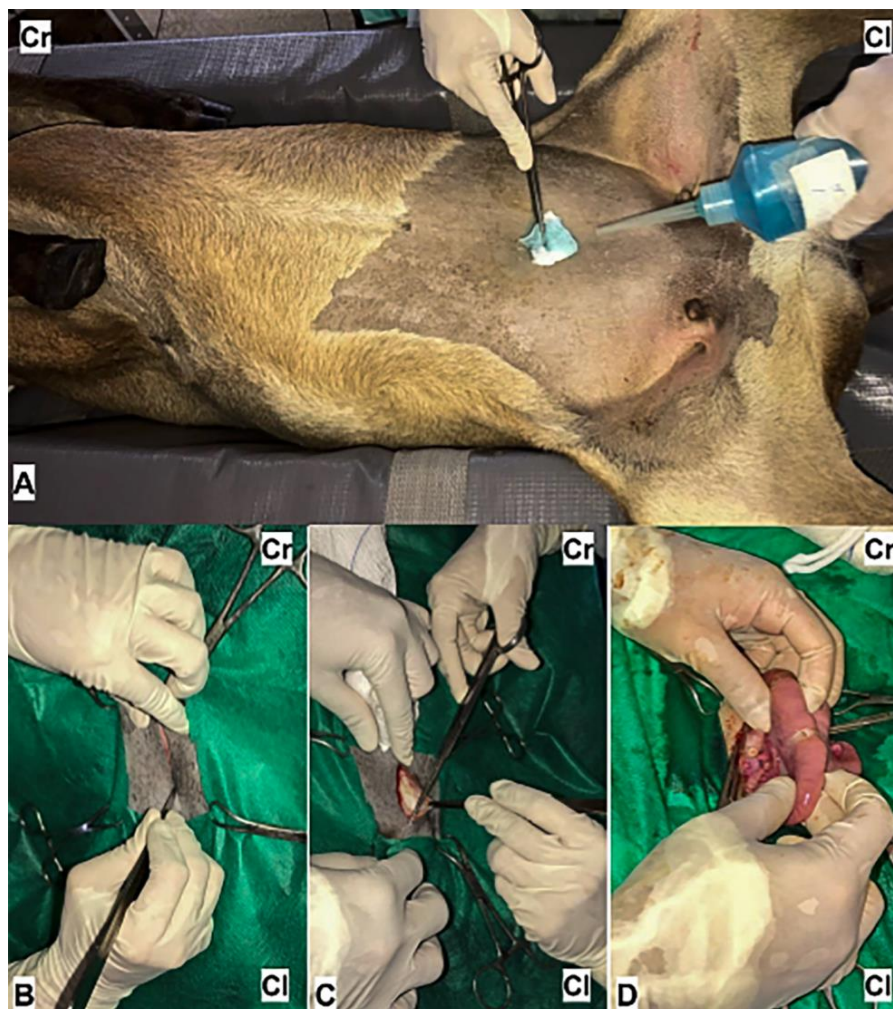The sheep were placed in a dorsal decubitus position with subsequent wide aseptic preparation of the ventral region of the abdomen and midline, with trichotomy and antisepsis with topical antiseptic, and degerming with alcoholic 2 and 0.5% chlorhexidine diglyconate, respectively (Riohex®, Rioquímica, SP, Brazil), as also subsequent placement of the surgical field.

Laparotomy was performed in the ventral region of the abdomen through a cutaneous, muscular, and peritoneal incision in the midline, between the inguinal regions, to a length of 10 cm, in order to access and exteriorize the uterine horn and ovary (Figure 1). In these organs, after extra-abdominal exteriorization, tissue trauma was performed by cauterization, using bipolar diathermy at three points on the serosa of the right uterine horn, and three points on the right ovary (Figure 2). In sheep from AAG, three drops of andiroba oil were administered at each point of cauterization by bipolar diathermy. This amount of oil was administered because it was the amount capable of covering the injured area. After these procedures, the exteriorized organs were gently repositioned in the abdominal cavity.

The abdominorrhaphy started with suturing the peritoneum and muscle with sultan stitches and reducing the subcutaneous space with simple continuous stitches using 2-0 polyglactin 910 thread (Shalon medical, SP, Brazil). The demorrhaphy was performed with a Wolff suture pattern, with 2-0 nylon (Nylon 2.0 Bioline®, Brazil). The postoperative dressing was performed by cleaning the surgical wound with chlorhexidine diliconate (Riohex 2%®, Rioquímica, Brazil) and topical application of an ointment (Ointment Plus®, Pearson, Brazil). After full anesthetic recovery, the animals were housed in pens, clinically monitored, with measurement and analysis of the heart and respiratory rate, body temperature, color of mucous membranes, capillary filling time, and observation of complications for 10 days, with subsequent removal of the suture stitches after healing of the surgical wound.

### Diagnostic evaluation of postoperative uterus/ovarian adhesions and laparoscopic adhesiolysis

The evaluation and laparoscopic adhesiolysis to diagnose POA in the uterus and ovary, with trauma caused by cauterization through bipolar diathermy, was performed 15 days after the surgical



**Figure 1.** Ventral laparotomy for access and exteriorization of the uterus and ovary (Cr: cranial; Cl: caudal). 1-A Demonstrates laparotomy location, patient position, and surgical field antiseptics (Cr: cranial; Cl: caudal). 1-B Skin incision (Cr: cranial; Cl: caudal). 1-C Surgical division of the subcutaneous tissue (Cr: cranial; Cl: caudal). 1-D Exteriorization of the uterine horn (Cr: cranial; Cl: caudal). Source: Authors

procedure by the same operator. Thus, all ewes underwent video-assisted laparoscopy through three portals (one laparoscopic and two with instruments) established in the ventral region of the abdomen, with the animals in Trendelenburg position, using the same anesthetic protocol and antiseptic procedures described for ventral laparotomy (Figure 3).

The laparoscopic portal was the first one established, after an 8 mm cutaneous and muscular incision in the midline, 5-10 cm caudal to the umbilical scar. A 10-mm trocar with an inflation valve was introduced blindly and cautiously into the incision, initially at a 45° angle, with a gradual change in angulation of up to 90° in relation to the abdominal wall, and a circular movement with moderate and careful force during its introduction.

When the first trocar was introduced, its obturator was removed and the cannula was maintained to access the abdominal cavity. A 10-mm laparoscope with an attached camera was inserted through this access, and the image of the cavity was visualized on the monitor and a satisfactory position of the cannula in the abdominal cavity was confirmed. A carbon dioxide (CO<sub>2</sub>) insufflator hose was

connected to the insufflation valve of this trocar, and a pneumoperitoneum was established with CO<sub>2</sub> insufflation into the abdominal cavity (speed of 5 L/min), maintained at a pressure of 5 mmHg.

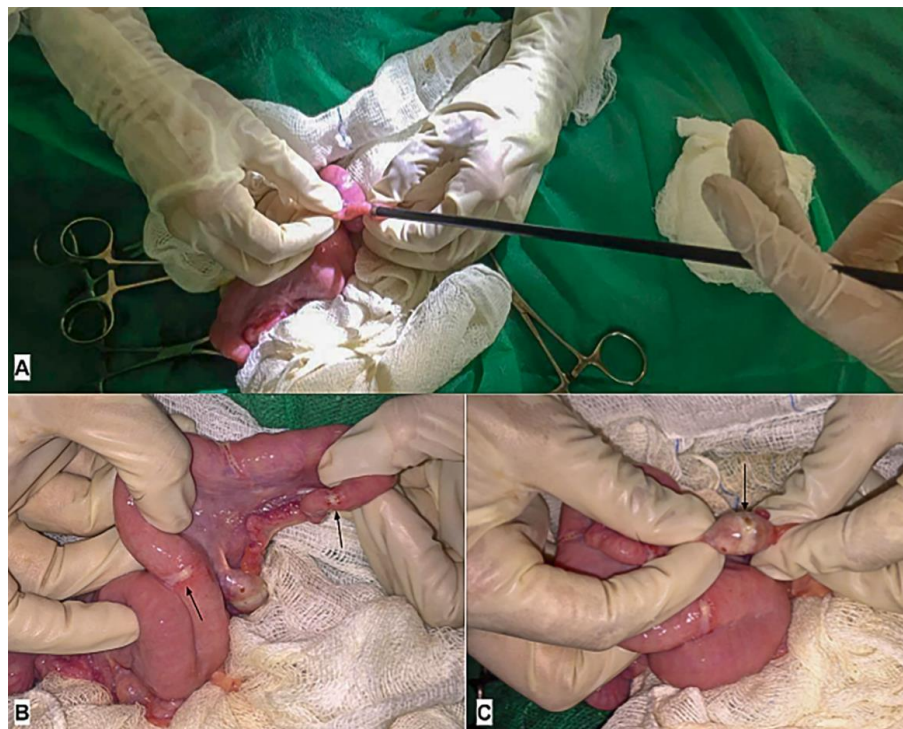
The two instrument ports were established 10 cm caudal to the laparoscopic port, and 5 cm lateral to the midline, in contralateral positions. Both were inserted in an assisted manner and with the same care adopted for the introduction of the first trocar. Through these portals, a 05 mm Babcock Laparoscopic Grasping Forceps (EDLO, SP, Brazil) was inserted and Maryland 05 mm dissector (EDLO, SP, Brazil) was used for manipulation and adhesiolysis of the uterus and ovary, respectively.

After establishing access by laparoscopic and instrument portals, the uterus and ovaries, traumatized by cauterization at three points, were evaluated. This assessment consisted of identifying the adhesions with classification and quantification in absolute values with regard to the number of adhesions observed per animal, according to the adhesion score scale (Table 1) and verification of the feasibility of adhesiolysis by laparoscopy, performed with

**Table 1** - Classification criteria of postoperative adhesions.

Score	Characteristics of injuries
0	Absence of adhesions.
1	Presence of a very thin, single adhesion, located at or near the injury site.
2	Presence of very thin localized adhesions at the lesion site, involving only uterine segments or ovaries in an ovarian bursa
3	Presence of thin adhesions, located between the lesion site and the peritoneum and/or involving the uterus, ovary, and fallopian tube
4	Presence of dense adhesions, located between the lesion site and the peritoneum and/or adhesions involving the uterus and ovary in other adjacent organs or tissues (Intestine, Bladder, Peritoneum)

Source: Authors



**Figure 2.** Performing tissue trauma in the uterine horn and ovary by electrocautery, using bipolar diathermy. 2-A Traumatized uterine horn (arrows). 2-B Traumatized ovary (arrow). Source: Authors

visualization and manipulation of the traumatized organs and surrounding tissues, using the laparoscope and grasping and dissection forceps.

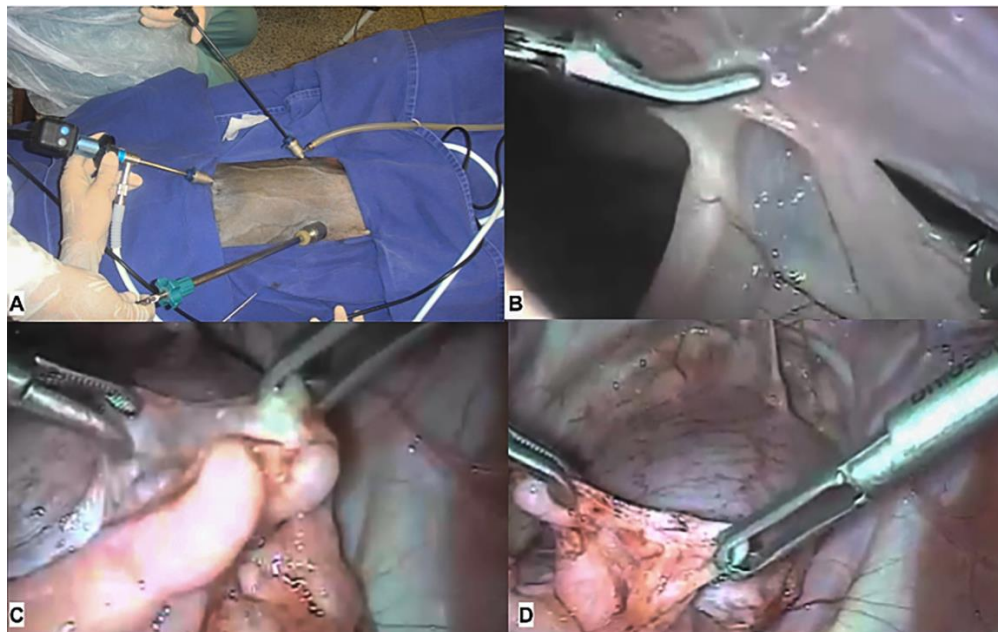
### Statistical analyses

The number and proportion of animals that presented with POA were compared by the Fisher's exact test considering the two groups (CCG and AAG). The number of adhesions observed in each animal was analyzed by the Mann-Whitney test. The

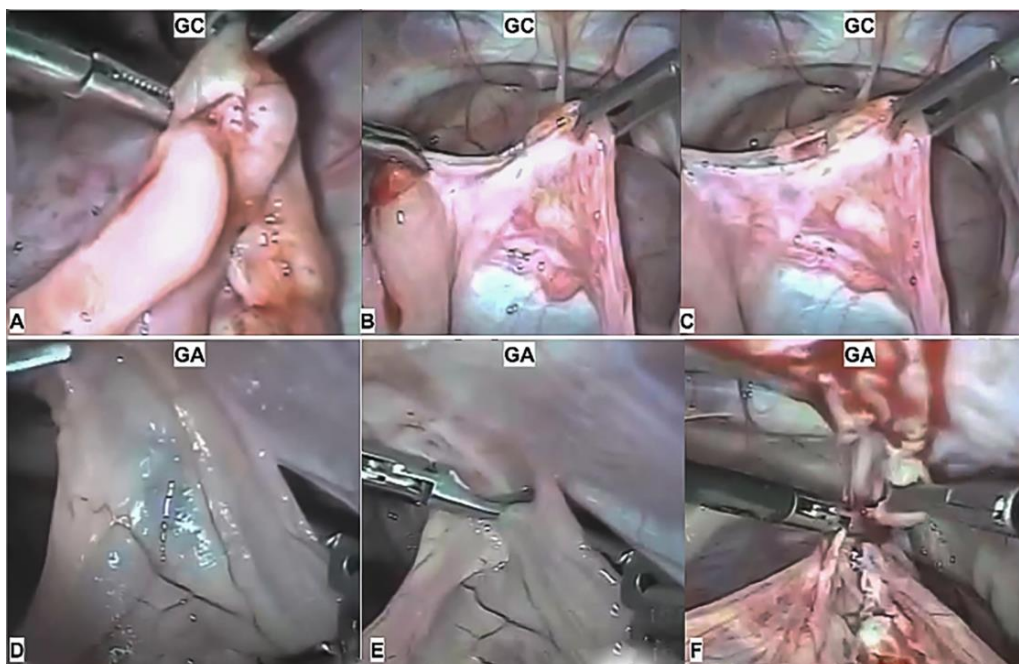
significance level considered was 5% ( $p > 0.05$ ). The feasibility of adhesiolysis by laparoscopy was performed descriptive. All statistical analyses were performed with BioEstat 5.3 software® (Mamirauá Institute, AM, Brazil).

### RESULTS

Gas chromatography coupled with a flame ionization detector (Gas Chromatography with Flame Ionization



**Figure 3.** Diagnosis and laparoscopic adhesiolysis of POA. 3-A Position of the three laparoscopic portals in the ventral region of the abdomen, to access the sheep's uterus and ovary. 3-B Intra-abdominal identification of a thin peritoneal adhesion. 3-C Intra-abdominal identification of dense adhesions involving reproductive organs and adjacent tissues by laparoscopic inspection. 3-D Demonstrates the performance of laparoscopic adhesiolysis. Source: Authors



**Figure 4.** Laparoscopic adhesiolysis and macroscopic characteristics of adhesions in CCG and AAG. 4-A Dense adhesions involving the uterus, ovary, fallopian tube, and adjacent tissues. 4-B A dense adhesion in the early laparoscopic adhesiolysis process. 4-C A dense adhesion in the terminal process of laparoscopic adhesiolysis. 4-D A thin adhesion involving the peritoneum. 4-E A dense adhesion in the early laparoscopic adhesiolysis process. 4-F A dense adhesion in the terminal process of laparoscopic adhesiolysis. Source: Authors

Detector – GC-FID) allowed the determination of the lipid profile of andiroba oil. The analysis showed an oil, rich in fatty acids, composed mainly of palmitic (27.5%), stearic (19.8%), oleic (20.1%), linolenic (20.9%), linoleic (20.4%), myristic (15.9%), arachidic (1.6%), palmitoleic (0.9%), behenic (0.8%), lignoceric (0.5%), lauric (0.2%), and margaric (0.1%) acids.

A sample of 16 animals divided into two groups, containing eight treated with andiroba oil and eight untreated (AAG and CCG) were submitted to trauma by bipolar diathermy in the uterus and ovaries and kept under research conditions. They were allowed to evaluate the occurrence of POA in these organs and the feasibility of laparoscopic adhesiolysis.

The ventral laparotomy allowed access and exposure of the sheep's uterus and ovaries, enabling tissue trauma by cauterization in three points by bipolar diathermy, which was able to cause POA in 75% of the sheep (12/16). Bipolar diathermy caused POA in 100% (8/8) of the CCG ewes and 50% (4/4) of the AAG ewes (Figure 4). As for the amount of adhesions, the number of adhesions per animal in the AAG was an average of  $1.2 \pm 1.2$ , whereas in the CCG this average was  $3.7 \pm 1.2$  ( $p = 0.04$ ). Regarding the classification of the score, the AAG animals had a mean score of  $1.5 \pm 1.7$  and in the CCG a score of  $3 \pm 1.0$  ( $p = 0.2$ ).

In all animals from AAG that presented POA, it was possible to perform adhesiolysis (100%, 4/4). In CCG animals with adherence, in 25% (2/8) of them it was possible to perform adhesiolysis partially, and in 75% (6/8) it was not possible. One animal from the CCG presented with fistula formation after adhesiolysis, between the uterus and intestinal loop, and died due to postoperative complications two days later.

## DISCUSSION

Fatty acids act as important immunomodulators in an immune response, as also in healing, with functions related to vascular contraction, chemotaxis, adhesion, diapedesis, activation, and cell death, with linolenic and linoleic acids being significant in increasing these responses, favoring the entry of factors of cell growth and production of adenosine triphosphate (ATP) by oxidation (McDaniel et al., 2008; Milhomem-Paixão et al., 2016).

In addition to the anti-inflammatory action of fatty acids, andiroba oil contains different tetraterpenoids (6 $\alpha$ -acetoxypedunin 7-desacetoxy-7-oxo gedunine, andirobin, gedunin, and methyl angolensate), which also have marked anti-inflammatory properties (Henriques and Penido, 2014). The anti-inflammatory properties and the mechanical barrier provided by andiroba oil may explain the lower occurrence of POA and the formation of these with lower cohesion strength in the animals of the AAG, as they may have reduced the physical contact between the traumatized surfaces and also reduced the local

inflammatory response, thereby, reducing the occurrence of and facilitating adhesiolysis.

Andiroba oil is routinely used in the Amazon region as a therapy in veterinary medicine, in various conditions, with therapeutic action, helping in wound healing, anthelmintic, antifungal, and anti-inflammatory cases, among others, related to the effects of fatty acids and tetraterpenoids present in the oil (Souza et al., 2017; Amorim et al., 2021). We believe that these components may be related to the reduction of POA in AAG ewes, due to their anti-inflammatory actions.

Another property that we consider relevant is the possibility of andiroba oil forming a physical barrier on the damaged surface during the initial days after tissue injury, allowing re-epithelialization without contact with other tissues. Other oils such as argan oil, soy oil, and olive oil have already been researched for the prevention of POA, and they have been shown to be effective and readily available for preventing these adhesions, with the barrier effect being considered significant in this process (Aydin et al., 2018).

The establishment of study models for the induction of POA into the genitourinary system of sheep can provide complementary and promising results related to the formation and prevention of these adhesions. The model performed in this research may be a viable alternative for this purpose, as it has been able to induce adhesions in the uterus and ovaries from tissue damage caused by bipolar diathermy in these organs. As we can see in the research related to the incidence and severity of POA and preventive methods, adhesion-inducing models in animals make it possible to obtain and refine promising results in this field of research, which requires effective POA induction models that meet the bioethical principles (Charboneau et al., 2018; Stapleton et al., 2019).

The formation of adhesions in all ewes in the CCG and half of the ewes in the AAG (50%, 4/4) showed us a certain efficiency of andiroba oil in preventing this pathology, as its incidence and severity is lower in the AAG, when compared with the CCG. The amount and score of the POA showed us the severity of this pathology, which progresses with more intense fibrinolytic formation in the initial days. To prevent or alleviate this, the use of bioactive mediators needs to continue on the injured surface for seven days and be further degraded, avoiding future complications (Hassanabad et al., 2021; Kheilnezhad and Hadjizadeh, 2021). In order to elucidate the period of action and bioavailability of andiroba oil under these conditions, research along these lines should be carried out.

The use of laparoscopy for the diagnosis of adhesions in cavities has been shown to be effective and very promising for this purpose, presenting results superior to ultrasonography, allowing to confirm or modify the diagnosis, as it provides an enlarged view of the cavity, and allows cautious tissue manipulation, with good specificity (Robert et al., 2016; Tabibian et al., 2017).

Ventral laparoscopy through three portals has allowed us to explore beyond the injured organs, intestinal loops, and adjacent tissues that can be adhered and hidden. It may enable an accurate diagnosis of adhesions and adequate therapy in clinical situations motivated by these adhesions.

Laparoscopy also proved to be a viable method for adhesiolysis, as it was possible to remove adhesions more easily and with less tissue trauma from the animals of the AAG, which presented a number of adhesions and a lower score, when compared with the animals of the CCG. In the very thin adhesions, mainly present in the animals of AAG, laparoscopic adhesiolysis was performed with greater ease and efficiency in all animals, whereas, for the denser adhesions involving other tissues, present in the animals of the CCG, only laparoscopic adhesiolysis was performed; it was possible in 75% of these animals. Minimally invasive video-surgical resources and principles can guarantee successful and promising interventions related to the therapy and prevention of POA (Diamond, 2016; Gomel and Koninckx, 2016; Krielen et al., 2020).

Andiroba oil in the proposed experiment did not completely prevent adhesions, but some parameters had to be taken into account, such as, the degree of damage to the uterine tissue, amount of oil used, concentration of fatty acids present in the sample used, as well as endogenous mechanisms of adhesiolysis peculiar to each species (Hassanabad et al., 2021). The availability and time of action of a biomaterial on the traumatized surface, wettability, electrostatic charges, chain mobility, and roughness, profoundly influenced the non-stick action of cells and tissues, and were important characteristics of substances that acted as a physical barrier in the prevention of adhesions (Kheilnezhad and Hadjizadeh, 2021; Heekyung et al., 2020).

## Conclusion

Andiroba oil did not completely prevent the formation of postoperative adhesions in the uterus and ovaries of sheep, but it did prevent the formation of dense adhesions with involvement of other tissues, facilitating laparoscopic adhesiolysis.

## CONFLICT OF INTERESTS

The authors declare that they have no known competing financial interests.

## REFERENCES

Amorim SL, Oliveira ACP, Peixoto RM, Pereira MAFM, Bastos LS, Rocha C, Athayde ACR, Silva WW, Medeiros MC (2021). Anthelmintic activity of the ethanolic extract of *Carapa guianensis* (Meliaceae) on gastrointestinal nematodes of sheep in the Western Amazon.

- Semina: Ciências Agrárias 42(4):2371-2388. <https://doi.org/10.5433/1679-0359.2021v42n4p2371>
- Araújo KA, Miranda IPA, Camargo C, Repetto M (2018). Knowledge of medicinal plants used by residents in two peripheral districts of Boa Vista, Roraima, Northern Brazilian Amazon: Phytotherapy as a new strategy in collective health. *Journal of Medicinal Plants Research* 12(26):435-447. <https://doi.org/10.5897/JMPR2018.6634>
- Araujo-Lima CF, Fernandes AS, Gomes EM, Oliveira LL, Macedo AF, Antoniassi R, Wilhelm AE, Aiub CAF, Felzenszwalb I (2018). Antioxidant Activity and Genotoxic Assessment of Crabwood (*Andiroba, Carapa guianensis* Aublet) Seed Oils. *Oxidative medicine and Cellular Longevity* 3246719. <https://doi.org/10.1155/2018/3246719>
- Aydin OU, Karakas DO, Hazer B, Dandin O, Yilmaz I (2018). Anti-adhesive effects of argan oil on postoperative peritoneal adhesions. *International Medical Journal* 7(3):557-560. <https://doi.org/10.5455/medscience.2018.07.8767>
- Charboneau AJ, Delaney JP, Beilman G (2018). Fucoidans inhibit the formation of post-operative abdominal adhesions in a rat model. *PLoS One* 14(1):e0211371. <https://doi.org/10.1371/journal.pone.0211371>
- Clark JM (2018). The 3Rs in research: a contemporary approach to replacement, reduction and refinement. *British Journal of Nutrition* 120(S1):S1-S7. <https://doi.org/10.1017/S0007114517002227>
- De Wilde RL, Alvarez J, Brölmann H, Campo R, Cheong Y, Sardo ADS, Koninckx PR, Lundorff P, Pawelczyk L, Roman H, La Roche LAT, Wallwiener M (2017). Prevention of Adhesions in Gynecological Surgery: The 2016 Experts Recommendations on Adhesion Prophylaxis. *Obstetrics and Gynecology* 7(2):1-4. <https://doi.org/10.4172/2161-0932.1000428>
- Diamond MP (2016). Reduction of postoperative adhesion development. *Fertility and Sterility* 106(5):994-997. <https://doi.org/10.1016/j.fertnstert.2016.08.029>
- Gomel V, Koninckx PR (2016). Microsurgical principles and postoperative adhesions: lessons from the past. *Fertility and Sterility* 106(5):1025-1031. <https://doi.org/10.1016/j.fertnstert.2016.08.040>
- Hassanabad AF, Zarzycki AN, Jeon K, Deniset JF, Fedak PWM (2021). Post-Operative Adhesions: A Comprehensive Review of Mechanisms. *Biomedicines* 9(8):867. <https://doi.org/10.3390/biomedicines9080867>
- Heekyung P, Baek S, Kang H, Lee D (2020). Biomaterials to Prevent Post-Operative Adhesion. *Materials* 13(14):3056. <https://doi.org/10.3390/ma13143056>
- Henriques MD, Penido C (2014). The therapeutic properties of *Carapa guianensis*. *Curr. Pharm. Des* 20(6):850-856. <https://doi.org/10.2174/13816128113199990048>
- Kheilnezhad B, Hadjizadeh A (2021). A review: progress in preventing tissue adhesions from a biomaterial perspective. *Biomaterials Science* 9:2850-2873. <https://doi.org/10.1039/d0bm02023k>
- Krielen P, Stommel MWJ, Pargmae P, Bouvy ND, Bakkum EA, Ellis H, Parker MC, Griffiths EA, Goor HV, Ten Broek RPG (2020). Adhesion-related readmissions after open and laparoscopic surgery: a retrospective cohort study (SCAR update). *Lancet* 395(10217):33-41. [https://doi.org/10.1016/s0140-6736\(19\)32636-4](https://doi.org/10.1016/s0140-6736(19)32636-4)
- McDaniel JC, Belury M, Ahijevych K, Blakely W (2008). Omega-3 fatty acids effect on wound healing. *Wound Repair and Regeneration* 16(3):337-345. <https://doi.org/10.1111/j.1524-475X.2008.00388.x>
- Moris D, Chakedis J, Rahnama-Azar AA, Wilson A, Hennessy MM, Athanasiou A, Beal EW, Argyrou C, Felekouras E, Pawlik TM (2017). Postoperative Abdominal Adhesions: Clinical Significance and Advances in Prevention and Management. *Journal of Gastrointestinal Surgery* 21(10):1713-1722. <https://doi.org/10.1007/s11605-017-3488-9>
- Milhomem-Paixão SSR, Fascineli ML, Roll MM, Longo JPF, Azevedo RB, Pieczarka JC, Salgado HLC, Santos AS, Grisolia CK (2016). The lipidome, genotoxicity, hematotoxicity and antioxidant properties of andiroba oil from the Brazilian Amazon. *Genetics and Molecular Biology* 39(2):248-256. <https://doi.org/10.1590/1678-4685-GMB-2015-0098>
- Oliveira ISS, Tellis CJM, Chagas MSS, Behrens MD, Calabrese KS, Abreu-Silva AL, Almeida-Souza F (2018). *Carapa guianensis* Aublet (*Andiroba*) Seed Oil: Chemical Composition and Antileishmanial

- Activity of Limonoid-Rich Fractions. *Biomed Research International* 5032816. <https://doi.org/10.1155/2018/5032816>
- Lee D (2020). Biomaterials to Prevent Post-Operative Adhesion. *Materials* 13(14):3056. <https://doi.org/10.3390/ma13143056>
- Penzias A, Bendikson K, Falcone T, Gitlin S, Gracia C, Hansen K, Tanrikut C (2019). Postoperative adhesions in gynecologic surgery: a committee opinion. *Fertility and Sterility* 112(3):458-463. <https://doi.org/10.1016/j.fertnstert.2019.06.027>
- Robert M, Touzot-Jourde G, Nikolayenkova-Topie O, Cesbron N, Fellah B, Tessier C, Gauthier O (2016). Laparoscopic Evaluation of Umbilical Disorders in Calves. *Veterinary Surgery* 45(8):1041-1048. <https://doi.org/10.1111/vsu.12559>
- Soares AS, Wanzeler AMV, Cavalcante GHS, Barros EMS, Carneiro RCM, Tuji FM (2021). Therapeutic effects of andiroba (*Carapa guianensis* Aubl) oil, compared to low power laser, on oral mucositis in children underwent chemotherapy: A clinical study. *Journal of Ethnopharmacology* 113365. <https://doi.org/10.1016/j.jep.2020.113365>
- Souza BAA, Braga LA, Lopes LRO, Ribeiro Júnior RFG, Nascimento LNS, Cavalcante LCC, Monteiro AM, Couteiro RP, Yasojima EY, Hamoy M (2017). Effects of Andiroba oil (*Carapa guianensis*) on wound healing in alloxan-diabetic rats. *International Archives of Medicine* 10. <https://doi.org/10.3823/2533>
- Stapleton LM, Steele AN, Wang H, Lopez Hernandez H, Yu AC, Paulsen MJ, Smith AAA, Roth GA, Thakore AD, Lucian HJ, Tothorow KP, Baker SW, Tada Y, Farry JM, Eskandari A, Hironaka CE, Jaatinen KJ, Williams KM, Bergamasco H, Marschel C, Chadwick B, Grady F, Ma M, Appel EA, Woo YJ (2019). Use of a supramolecular polymeric hydrogel as an effective post-operative pericardial adhesion barrier. *Nature Biomedical Engineering* 3(8):611-620. doi:10.1038/s41551-019-0442-z
- Strech D, Dirnagl U (2019). 3Rs missing: animal research without scientific value is unethical. *BMJ Open* 3:e000035. <https://doi.org/10.1136/bmjopen-2018-000048>
- Tabibian N, Swehli E, Boyd A, Umbreen A, Tabibian JH (2017). Abdominal adhesions: A practical review of an often overlooked entity. *Annals of Medicine and Surgery* 15:9-13. <https://doi.org/10.1016/j.amsu.2017.01.021>
- Tamponi C, Dessì G, Varcasia A, Knoll S, Meloni L, Scala A (2021). Preliminary Assessment of Body Condition Score as a Possible Marker for the Targeted Selective Treatment of Dairy Sheep Against Gastrointestinal Nematodes. *Acta Parasitologica* 67(1):362-368. <https://doi.org/10.1007/s11686-021-00470-9>
- Vediappan RS, Mascarenhas A, Nguyen-Hoang A, Anne Fong S, Jukes A, Richter K, Bassiouni A, Patel S, Chryssidis S, Otto S, Moratti S, Psaltis AJ, Vreugde S, Wormald P (2020). Prevention of peridural adhesions in spinal surgery: Assessing safety and efficacy of Chitogel with Deferiprone in a sheep model. *Journal of Clinical Neuroscience* 72:378-385. <https://doi.org/10.1016/j.jocn.2019.12.042>