

*Full length Research paper*

# The study of 24 h post treatment effects of the aqueous extract of *Rosmarinus officinalis* after renal ischemia/reperfusion in rat

Marzieh Zohrabi<sup>1</sup>, Saeed Changizi Ashtiyani<sup>1\*</sup>, Saeed Hajhashemi<sup>1</sup>, Akbar Hassanpoor<sup>2</sup> and Nasser Hosseini<sup>3</sup>

<sup>1</sup>Department of Physiology, Arak University of Medical Sciences, Arak, Iran.

<sup>2</sup>Department of Pathology, Arak University of Medical Sciences, Arak, Iran.

<sup>3</sup>Department of Medicinal Plants, Arak University, Arak, Iran.

Accepted 10 February, 2012

Ischemia/reperfusion (I/R) induced acute renal failure (ARF), causes renal functional and histological disorders. This study investigated the effect of oral Rosemary extract on ARF disorders in rat. Forty male Sprague-Dawley rats were used in 4 groups (n=10) as control, sham, I/R with gavage feeding normal saline, and I/R with gavage feeding of 8% aqueous extract of Rosemary (10 ml/kg/day). ARF was induced by bilateral renal artery and vein occlusion for 30 min. Reperfusion period was continued for 24 h. Blood pressure and renal blood flow of rats were measured using a power lab system (AD instruments). After placing the rats into metabolic cages, urine sampling was done. Plasma samples were obtained and after removing both kidneys and staining kidney sections, histological studies were performed. Data were analyzed using SPSS software version 11.5. The comparison between Rosemary and vehicle groups indicated significant reduction in  $[Cr]_p$  ( $P < 0.001$ ),  $[BUN]_p$  ( $P < 0.01$ ),  $U_{Na}V$  ( $P < 0.001$ ), and significant increase in  $U_KV$  ( $P < 0.001$ ) in the Rosemary group. Oxidative stress studies indicated the ability of the aqueous extract of Rosemary to decrease malondialdehyde (MDA) and increase ferric reducing antioxidant power (FRAP) in comparison with the I/R group. Histopathological analyses indicated significant decreases in vessels congestion, tubules disorder, and space of Bowman's capsule in the Rosemary group in comparison with the vehicle groups. Post treatment with Rosemary aqueous extract protects the rats against histological injury and functional impairment induced by 24 h I/R.

**Key words:** Acute renal failure, ischemia/reperfusion, Kidney, rat, *Rosmarinus officinalis*.

## INTRODUCTION

Acute renal failure (ARF) is defined as a clinical syndrome characterized by a rapid decline in the ability of kidney to remove waste products, disturbance in acid-base balance, water homeostasis, and rapid reduction in glomerular filtration rate (GFR) (Bagshaw and Bellomo, 2007).

Renal ischemia activates several mechanisms, which lead to endothelial dysfunction, increased vascular permeability, tissue congestion, and the rise of inflammatory factors such as cytokines (Abuelo, 2007).

With reperfusion, the interaction between leukocytes and endothelial cells causes more damage due to inflammatory response, release of cytokines and proteases, and induction of oxidative stress in endothelial cells (Kramer et al., 1999; Kenji, 2004). Imbalance in the production of reactive oxygen species (ROS) and antioxidant enzymes may lead to tissue damage. ROS can severely compromise cell survival by weakening the structure and function of plasma and intracellular membranes (Ashtiyani et al., 2008). Since common medical treatments have side effects due to their long-term usage and high financial burdens, tendency towards alternative and traditional treatments is increasing. A lot of research has been done on herbs to improve disorders

\*Corresponding author. E-mail: [dr.ashtiyani@arakmu.ac.ir](mailto:dr.ashtiyani@arakmu.ac.ir).

caused by acute renal failure.

Rosemary plant with the scientific name of *Rosmarinus officinalis* belongs to the Lamiaceae family. Four main categories of compounds found in Rosemary include flavonoids, phenols, volatile oil, and terpenoids (Barnes et al., 2007). This plant also has antioxidant properties due to the presence of carnosic, carnosol, rosmanol, epirosmenol, and rosmarinic acids in it (Haraguchi et al., 1995). Studies have shown that Rosemary plant due to its dilatory properties can increase blood flow and its external use has vasodilatory effects on the skin (Frishman, 2004). In addition, this plant has antispasmodic properties due to its alpha- and beta-pinenes as Ach antagonists (Taddei et al., 1988; Hosseinzadeh and Nourbakhsh, 1989). Noticing the vasodilatory, antispasmodic, and antioxidant properties of the aqueous extract of Rosemary (*R. officinalis*) and the mechanisms of tissue damage in ARF, we decided to study the effect of aqueous extract of this plant on disruptions in the improvement of various aspects of ARF for the first time.

## MATERIALS AND METHODS

This experimental study was done on 40 male Sprague-Dawley rats weighing 250-300 g provided from the Experimental Animals Breeding Center of Arak University of Medical Sciences. These animals were placed in controlled conditions of temperature ( $23 \pm 2^\circ\text{C}$ ) and light (light: 12 h, dark: 12 h). They were provided with standard food and water *ad libitum*. Animal care and handling were performed according to the guidelines set by Iranian Ministry of Health and Medical Education.

The rats were anesthetized with an intraperitoneal injection (i.p) of sodium pentobarbital (60 mg/kg; Sigma, UK). Ischemic-reperfusion (I/R) was used as model of acute renal failure. After shaving the abdominal hair, a longitudinal incision was made. Renal ischemia was induced by bilateral renal artery and vein occlusion for 30 min by using a special clamp. Immediately after 30 min of obstruction, the surgical area was sutured with 3-zero silk. The experiment was assorted into 4 groups and animals were randomly allocated (10 rats in each group):

- A) Control group (n =10): The rats did not receive any vehicle or drugs and had access to standard feed and water.
- B) Sham group (n =10): The rats were anesthetized and renal arteries and veins were exposed without clamping. They received the vehicle of Rosemary extract through gavage for 24 h.
- C) The 24-h post-treatment group (n =10) + vehicle: After induction of ARF by I/R during the first 24-h, vehicle of Rosemary extract (normal saline) was given through gavage.
- D) The 24-h post-treatment group (n =10) + Rosemary extract: After induction of ARF by I/R during the first 24 h, Rosemary extract was given through gavage.

In all groups, the rats were kept in metabolic cages and urine sample were collected after induction of ARF and measured by Gravimetric method. The rats were anesthetized and blood pressure was measured by power lab system (AD Instruments, Australia). Left kidney artery was separated from the vein and RBF was measured as ml/min using flow meter with a special probe (T402, USA). Blood sampling from the aorta was done by heparin cold syringe and plasma separation was done by centrifugation.

After separating and weighing both kidneys, one of them was kept in 10% formalin for histological studies and the other was frozen in liquid nitrogen and kept in  $-20^\circ\text{C}$  for measuring biochemical parameters and antioxidant properties determined by Ferric Reducing Antioxidant Power (FRAP) and Malondialdehyde (MDA). Sodium, potassium, creatinine, and BUN concentrations were measured in blood and urine samples. In order to determine renal function, absolute excretion of sodium and potassium ( $U_{\text{Na}}V^0$  and  $U_{\text{K}}V^0$ ) and also fractional excretion of sodium and potassium ( $FE_{\text{Na}}$  and  $FE_{\text{K}}$ ) were calculated. Creatinine clearance was calculated for determination of GFR.

## Rosemary extraction method

Rosemary plant was provided from Arak University Herb Farm. The air dried leaves were coarsely powdered. Eight grams of the powder dissolved in 100 ml of distilled water was boiled for 5 min and infused for 10 min. After cooling and passing through filter paper, a clear solution was obtained. During 24 h, 10 ml/kg/day of the extract was given to the rats by gavage (Haloui et al., 2000).

## Measurement of biochemical parameters

### Malondialdehyde (MDA)

Injury due to oxidative stress which results from lipid peroxidation was assessed by measuring MDA level. Ohkawa method was used for determination of MDA level in kidney tissues. In short, after separation of the kidney and weighing, phosphate buffer was added at 1 to 10 ratio (W/V) and, then, homogenized by homogenizer to form a homogenate. Acetic acid (20%), TBA (0.8%), and SDS (8.1%) were added to all tubes. Test tubes containing the suspension were heated inside water bath (DUBNOFF-USA) at  $95^\circ\text{C}$  for 60 min. After MDA reaction, a pink complex was formed that was extracted with n-butanol. Absorption was measured at 532 nm by spectrophotometry. The results obtained from these samples were compared by tetraethoxy-propane and the numeric amounts were reported as micromole per gram kidney weight ( $\mu\text{mol/gKW}$ ). (Moosavi et al., 2011).

### Ferric reducing antioxidant power (FRAP)

Measurement of FRAP has been considered as one of the most common methods for evaluation of total antioxidant activity since 1996. This method is based on the ability of tissue fluid to reduce ferric ( $\text{Fe}^{+3}$ ) to ferrous ( $\text{Fe}^{+2}$ ) in the presence of Tripyridyl-S-Triazine (TPTZ). The ability of tissue fluid reduction was assessed by concentration of blue TPTZ- $\text{Fe}^{+2}$  complex measured by spectrophotometry. FRAP indicator was prepared as a mixture of acetate buffer, ferric chloride, TPTZ and, distilled water. Tissue extract (50  $\mu\text{l}$ ) and FRAP indicator (1.5 ml) were mixed in cuvettes and, after 4 min, absorption was measured at 593 nm and read against blank. The results were compared to the standard curve and plasma concentrations of the samples were measured. After constructing the standard curve, the FRAP levels of tissue samples were expressed as mmol/gKW (Moosavi et al., 2010).

## Histopathological studies

Overall, kidneys were processed for light microscopy examination. The kidneys were fixed in the buffered 10% formaldehyde (Merck, NJ, USA) and embedded in paraffin, and 5  $\mu\text{m}$  sections were stained with hematoxylin and eosin. Histopathological changes were analyzed in cortex sections, inner section and outer sections of medulla separately. Sections of cortex were analyzed for obtaining the number of RBCs inside glomerule, tubular epithelial

**Table 1.** The comparison of hemodynamic changes in plasma and kidney excretory function parameters due to renal I/R and the effect of Rosemary on them.

Group	Parameter							
	[Cr] <sub>p</sub> (mg dl-1)	[BUN] <sub>p</sub> (mg dl-1)	U <sub>Na</sub> V <sup>0</sup> (mmol/m in per kg)	U <sub>K</sub> V <sup>0</sup> (mmol/min per kg)	[OSM] <sub>u</sub> (mOsm kgH <sub>2</sub> O <sup>-1</sup> )	C <sub>cr</sub> (ml min-1 kg-1)	Mean flow (mlit/min)	P <sub>sys</sub> (mmHg)
Control	0.67 ± 0.04	18.25 ± 0.7	0.56 ± 0.03	1.6 ± 0.15	1515 ± 67.7	1.64 ± 14.28	7.58 ± 0.47	94.5 ± 5.19
Sham	0.84 ± 0.05	25.12 ± 1.7	0.71 ± 0.1	1.56 ± 0.11	1475 ± 57	13.93 ± 1.29	8.67 ± 0.42	82.96 ± 7.07
I/R+V	3.27 ± 0.32***	99.9 ± 15.9***	3.14 ± 0.3***	1 ± 0.1*	810 ± 48.4***	2.71 ± 0.25***	4.81 ± 0.61***	89.21 ± 8.88
I/R+D	1.49 ± 0.16*†††	58.25 ± 7.5*††	0.77 ± 0.08†††	2.04 ± 0.25†††	1069 ± 34.4***††	0.96 ± 10.15*†††	7.6 ± 0.69††	85.05 ± 5.77

\* $P < 0.05$ , \*\* $P < 0.01$ , \*\*\* $P < 0.001$  for comparison with Sham group, † $P < 0.05$ , †† $P < 0.01$ , ††† $P < 0.001$  for comparison between I/R+ vehicle and I/R+ Rosemary group.

cells necrosis, and tubular injury, inner and outer of medulla for epithelial cell necrosis, proteinaceous casts, and medullary vessels congestion. The degree of impairments was graded as follows: without impairments: grade 0, 1-20%: grade 1, 40-21%: grade 2, 41-60%: grade 3, 61-80%: grade 4, and 81-100%: grade 5 (Moosavi et al., 2009).

### Statistical analysis

The results were expressed as mean and standard error of mean by SPSS software (version 11.5). Statistical comparisons between the groups were performed by one-way ANOVA and Duncan test. The differences were considered to be statistically significant at  $P \leq 0.05$ . Kruskal-Wallis multiple comparison test was used for tissue analysis.

## RESULTS

After 30 min of bilateral renal obstruction and 24 h of reperfusion, plasma and urine factors in the ischemia group presented significant differences in comparison with control and sham groups (Table 1). In the I/R group, there were significant increases in [Cr]<sub>p</sub> (290%), [BUN]<sub>p</sub> (200%), U<sub>Na</sub>V (340%), FE<sub>Na</sub> (2730%), and FE<sub>K</sub> (240%) in comparison with the sham group. Significant decreases were observed in blood flow (45%), creatinine clearance (C<sub>cr</sub>) (80%), urine osmolarity

[OSM]<sub>u</sub> (45%), and U<sub>K</sub>V<sup>0</sup> (35%) in comparison with the sham group. In I/R + Rosemary group, in comparison with the I/R group, significant reductions were observed in [Cr]<sub>p</sub> (50%)<sub>p</sub>, [BUN]<sub>p</sub> (40%), U<sub>Na</sub>V (75%), FE<sub>Na</sub> (90%), and FE<sub>K</sub> (40%) (Figure 1 a,b). There were increases in mean blood flow (60%), U<sub>K</sub>V (100%), and [OSM]<sub>u</sub> (30%) in comparison with the I/R group (Figure 2).. There was no significant difference in systolic blood pressure between different groups.

Histological examination of the kidneys of the rats in the sham group revealed entirely normal histological features (grade 0) as illustrated in Figures 3a<sub>1</sub>-3a<sub>4</sub>. In the I/R group, Bowman's space (grade 2) increased but the number of RBCs decreased significantly in the cortex (Figure 3c<sub>1</sub>). Proximal tubular cells had vacuoles (grade 2), exfoliated cells were observed in the lumens of tubule (grade 4). Significant vascular congestion (grade 5) was also seen in this group (Figure 3c<sub>2</sub>). In addition, a great number of proteinaceous casts (grade 4) was observed in this region in comparison with sham group.

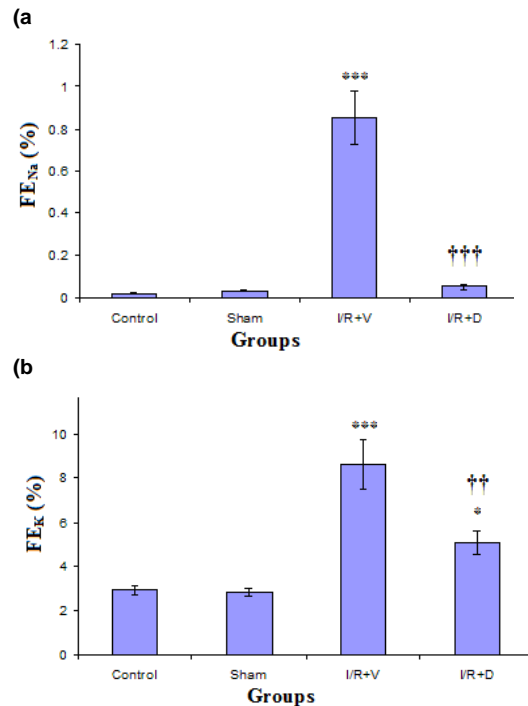
In the I/R+ Rosemary group, significant decrease was found in Bowman's space (grade 1) (Figure 3b<sub>1</sub>) and a small numbers of proteinaceous casts (grade 2) and vascular congestion (grade 2) without any vacuoles (grade

0) were reported (Figure 3b<sub>2</sub>) in comparison with the I/R group. In the I/R group, in the outer medulla, significant amounts of vascular congestion (grade 3) and proteinaceous casts (grade 4) were seen in comparison with sham group (Figure 3c<sub>3</sub>). In the S3 section and TAL, the greatest amount of necrosis (grade 4) was manifested, which improved to a great extent (grade 2) in the I/R+Rosemary group. In the I/R group, all thin ascending Henle and collective tubules were reported normal (grade 0).

The mean levels of creatinine plasma ([Cr]<sub>p</sub>), blood urea nitrogen (NUB), sodium absolute excretion (U<sub>Na</sub>V), potassium absolute excretion (U<sub>K</sub>V), urine osmolarity (OSM<sub>u</sub>), creatinine clearance (C<sub>cr</sub>), Renal blood flow (RBF), and systolic pressure (P<sub>sys</sub>) during 24 h after 30 min of bilateral obstruction in rats subjected to sham-operation (sham group), or to ischemia/reperfusion that received saline (I/R group), or Rosemary (I/R+D group). Data were given as mean ± SEM.

## DISCUSSION AND CONCLUSION

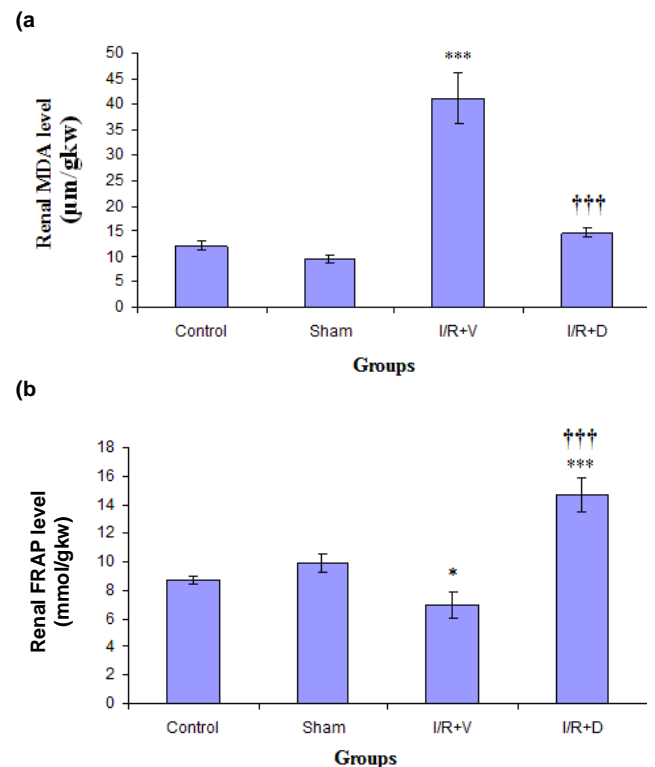
This study investigated the effects of the oral aqueous extract of Rosemary on the improvement



**Figure 1.** The comparison of mean levels of **(a)** sodium fractional excretion ( $FE_{Na}$ ) and **(b)** potassium fractional excretion ( $FE_K$ ) during 24 h of reperfusion after 30 min of bilateral obstruction in rats receiving oral Rosemary (10 ml/kg/day) in I/R+ Rosemary (I/R+D), normal saline in the I/R group (I/R+V), or normal saline in the sham group (sham group) and control group, (Data presented as mean  $\pm$  SEM). \* $P < 0.05$ , \*\* $P < 0.01$ , \*\*\* $P < 0.001$  for comparison of each group with Sham group,  $^{\dagger}P < 0.05$ ,  $^{\dagger\dagger}P < 0.01$ ,  $^{\dagger\dagger\dagger}P < 0.001$  for comparison between I/R+V and I/R+D groups.

of renal damage in the first 24 h following I/R. Systolic blood pressure values in different groups did not reveal any significant differences which indicates that changes in renal function parameters in different groups have not been practically due to changes in arterial blood pressure (Table 1). The findings of this study indicated a significant decrease in  $C_{Cr}$  due to ischemia in the I/R group which can be attributed to decreased RBF, increased pressure in Bowman's capsule, or returned leakage. In addition, reduction in RBF and in the number of intraglomerular red globules in the I/R group (Table 1, Figure 3C<sub>1</sub>) can be due to two independent variables, such as increase in vasoconstriction and vascular congestion in medulla that by attachment of red and white globules and platelets to the arterial wall and increased resistance and creation of a physical barrier result in a decrease in RBF and somehow the decrease in  $C_{Cr}$  during I/R.

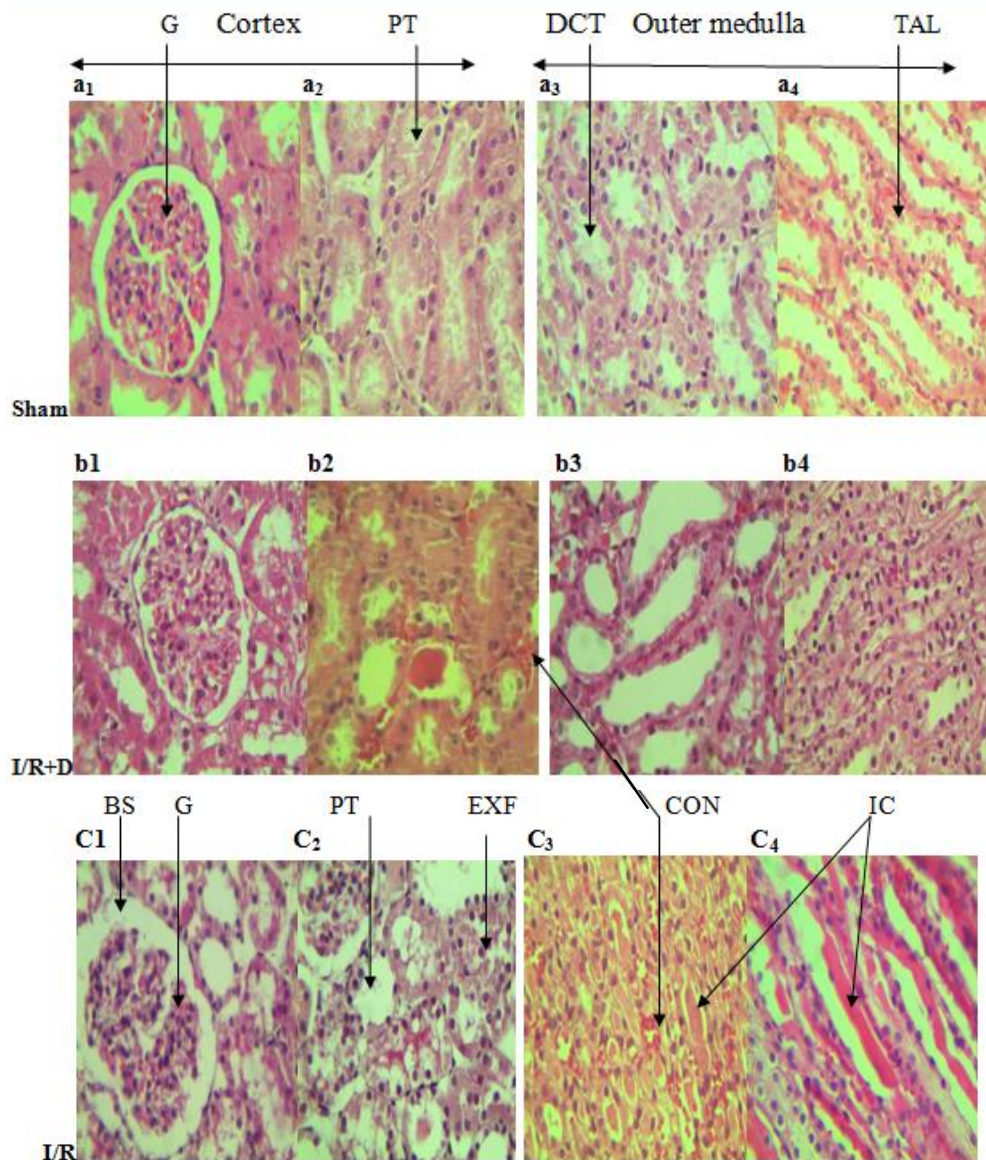
In the present study, following Rosemary consumption, a significant increase in RBF was observed in comparison with the I/R group (Table 1). The study by Naemura et al. (2008) demonstrated the acute



**Figure 2.** The comparison of mean levels of **(a)** malondialdehyde (MDA) and **(b)** Ferric Reducing Antioxidant Power (FRAP) during 24 h of reperfusion after 30 min of bilateral obstruction in rats receiving oral Rosemary (10 ml/kg/day) in I/R+ Rosemary (I/R+D), normal saline in the I/R group (I/R+V), or normal saline in the sham group (sham group) and control group, (Data presented as mean  $\pm$  SEM). \* $P < 0.05$ , \*\* $P < 0.01$ , \*\*\* $P < 0.001$  for comparison of each group with Sham group,  $^{\dagger}P < 0.05$ ,  $^{\dagger\dagger}P < 0.01$ ,  $^{\dagger\dagger\dagger}P < 0.001$  for comparison between I/R+V and I/R+D groups.

administration of Rosemary (nearly 5%) significantly inhibits the formation of arterial thrombosis that its mechanism of effect has been attributed to the inhibition of the platelets activity and endothelial stimulation in increased production of vasodilatory mediators because of the presence of flavonoid in it.

William showed that Rosemary possesses vasodilatory properties of essential oils and anti-spasmodic properties of alpha- and beta-pinene which enhance blood flow (Frishman et al., 2004; Taddei et al., 1988; Hosseinzadeh and Nourbakhsh, 1987). In addition, Juhas in his study, demonstrated that the high concentration of Rosemary (5000 ppm) can result in inhibition of acetylcholinesterase and, as a result, vasodilation. In this study, it was shown that cineole as one of the compounds present in Rosemary at 1250 ppm dose, has anti-inflammatory effects which significantly inhibit the production of cytokines in lymphocytes and monocytes (Juhas et al., 2009). In this study, RBF values presented a significant increase in the group receiving Rosemary, which can be



**Figure 3.** Microphotographic representation of the left kidney from cortex ( $a_1$ ,  $a_2$ ) and outer medulla ( $a_3$ ,  $a_4$ ) in the sham group and cortex ( $b_1$ ,  $b_2$ ) and outer medulla ( $b_3$ ,  $b_4$ ) in the I/R group with hematoxylin-eosin staining (at  $\times 400$ ). BS=Bowman's space; DCT= distal convoluted tubule; Exf= exfoliated cells; G=glomerulus; IC= intratubular cast; PT= proximal tubule; TAL= thick ascending limb of Henle's loop; CON=congestion.

attributed to the vasodilatory, anti-spasmodic, and anti-inflammatory effects of Rosemary (Table 1).

Carnosic acid and carnosol are responsible for nearly 90% of the anti-oxidant effects of Rosemary plant (Zegura et al., 2011; Posadas et al., 2009). Doolaee showed the bioavailability to carnosic acid after 360 min to be approximately 40.1% which is excreted from the body 24 h after oral administration (Doolaee et al., 2011). Therefore, Rosemary administration immediately after removing the obstruction in the first 24 h following I/R seems to be within the appropriate bioavailability

range for providing the right concentration for manifestation of its pharmacologic effects.

The findings of this study indicate that RBF in the first 24 h following I/R showed a 44% decrease in comparison with the sham group where  $C_{Cr}$  showed a 79% decrease under similar conditions which can probably due to oxidative changes in epithelial cells which disturb the balance in vasoactive factors, such as  $PGE_2$ , NO, ET-1, thromboxane  $A_2$ , and angiotensin II. In this situation, vasoconstrictive factors, such as endothelin, suppress vasodilatory factors and this leads to congestion,

decreased blood flow, and, eventually, decreased urine output and urine clearance (Conger, 1997). Due to these strong antioxidant properties, probably through inhibition of free radicals and increasing the anti-oxidant defense, Rosemary prevents RBF decrease (Table 1).

In the I/R group reduction of  $C_{Cr}$  was also accompanied by increase of  $[Cr]_p$  which indicated a reverse relationship between decrease of  $C_{Cr}$  and increase of plasma creatinine (Table 1). In the study by Moosavi et al., it was shown that following the 30-min obstruction of renal arteries, a 76% decrease was observed in  $C_{Cr}$  which was said to have been caused by intra-renal vasoconstrictors, tubular obstruction, and glomerule back leak due to loss of tight junctions in damaged tubular cells following I/R (Moosavi et al., 2004).

In the I/R group  $U_{Na}V$  showed significant increases in comparison with the sham group (Table 1) which is indicated decrease of tubular reabsorption. On the other hand,  $FE_{Na}$  increase despite  $C_{Cr}$  decrease also shows the increase in the degree of proximal tubule damage which its main cause is known to be the increased production of ROS (Figures 1a & 2a,b). (Bayrak et al., 2008; Chatterjee et al., 2000a).

Several studies have shown that the main sources of ROS production during I/R are endothelial cells since they possess a hypoxanthine/xanthine oxidase system which enables them to activate notrophiles (Mashiach et al., 2001). Other studies have also shown that proximal tubule cells show a 7-time increase in ROS production following I/R (Rasoulilian et al., 2008). Chatterjee et al. (2000b) showed that after 45 min of renal arteries obstruction, GFR significantly decreased while  $FE_{Na}$  increased which were respectively due to disturbance in the glomerule and proximal tubules function. It was also indicated that biochemical indicators of renal dysfunction depend on the reperfusion time (Chatterjee et al., 2000b). Histopathological evidence in the I/R group demonstrated that brush borders exfoliation the apical membrane, separation of normal cells which by decreasing the mucous layer of urinary tubules epithelium are major factors in reduction of reabsorption of substances following renal ischemia (Figure 3C<sub>2</sub>). Other researchers indicated apoptosis and necrosis of epithelial cells and, therefore, reduction in functional cells among other important factors in reduction of sodium reabsorption and its dependent substances. In addition, renal hemodynamic changes through affecting the physical forces of arteries around tubules intensified these reabsorption disturbances (Basile et al., 2011; Spurgeon-Pechman et al., 2007; Pechman et al., 2009).

In the I/R group,  $U_KV$  presented a significant decrease in comparison with the sham group while  $FE_K$  presented a significant increase which is, on the one hand, attributed to GFR decrease and, on the other hand, to decreased potassium reabsorption or increased potassium secretion (Han et al., 2007). Researchers indicated tubular damage to the proximal tubule and TAL,

resulting in decrease of potassium reabsorption in these areas, as one of the major probable causes of progressive  $FE_K$  increase (Figure 1b). (Gimelreich et al., 2001). Since the amount of urea excretion through urine to a great extent depends on GFR, decreases in GFR in the I/R group lead to reduction in urea excretion and  $[BUN]_p$  increased just as  $C_{Cr}$  improvement in the group receiving Rosemary resulted in the significant decrease in  $[BUN]_p$  in comparison with the I/R group (Table 1).

Several studies on ARF induced by ischemia have referred to the deficiency of kidneys in urine concentration. The most important cause of this condition is disruption in the countercurrent multiplier mechanism. Damage to tubular cells, particularly TAL (Figure 3C<sub>4</sub>), and their decreased ability in reabsorption of minerals together with severe GFR reduction drop, and change in the distribution of renal RBF following ischemia are responsible for disturbance in the countercurrent multiplier mechanism which leads to reduction in or destruction of the hyperosmolarity of the interstitial tissue and, eventually, great decrease in urine osmolarity (Vallon et al., 2006) (Table 1).

Gong's study identified S3 segment of proximal tubule and TAL as the main regions affected by I/R. Moreover, the expression of AQP-1, AQP-2, and AQP-3 in these two regions and collecting channels significantly decreased in response to I/R. In this study, it was suggested that reduction in AQP-1 can play an important role in disturbing urine concentration during ARF that can be seen as another reason for decreased osmolarity during I/R (Gong et al., 2004). The positive effects of Rosemary on the improvement of tubular damages to TAL and, eventually, prevention of disturbance in reabsorption of minerals probably resulted in maintaining the hyperosmolarity of medulla, and, therefore, the concentration capability which result in the significant difference in urinary osmolarity in comparison with the I/R group (Figure 3b<sub>4</sub>, Table 1).

The findings of the present study showed that MDA, which is used in evaluating oxidative stress, increased as much as 295% in the I/R group in comparison with the corresponding sham group. This indicates that the increase in ROS production and decreased activity of the antioxidant defense mechanism in kidneys during I/R probably due to of oxidative stress (Figure 2).

Using the aqueous extract of Rosemary as a drug with strong antioxidant properties that eliminated the generated free radicals and reinforced the anti-oxidant system and prevented oxidative stress. This was verified by the increase in FRAP value and prevention of MDA increase in the group receiving Rosemary (Figure 2). The study by Posadas showed that Rosemary plant significantly decreases MDA levels of cortex and hippocamp tissues in the 21-month-old rats treated with 0.2% doses of Rosemary in comparison with the control groups (Posadas et al., 2009). Zaouali et al. (2010) investigated the antioxidant effects of different com-

pounds of Rosemary through FRAP method and found out that Rosemary possesses strong anti-oxidant properties and different compounds of this plant are highly diverse in terms of anti-oxidant properties depending on the genetic and morphologic characteristics of its different species. Therefore, based on the findings of the present study, it can be concluded that using the aqueous extract of Rosemary plant in the early stages following I/R can, probably due to all its anti-oxidant, anti-spasmodic, and vasodilatory effects, be effective in decreasing renal histopathologic damage and preventing renal hemodynamic and functional disturbances in rats.

## AKNOWLEDGMENTS

This article was part of the research project No.531 of the Research Committee and Ethics Committee No.89-97-3 of Arak University of Medical Sciences, Arak, Iran. The authors would like to thank the moral and financial support provided by the Vice-presidency of Research of Arak University of Medical Sciences, the laboratory staff at Amir-Al-Momenin Hospital, Arak, and Ms Ghadamiyan, histopathology expert of the Faculty of Medicine, Arak University of Medical Sciences.

## REFERENCES

- Abuelo JG (2007). Normotensive ischemic acute renal failure. *N. Engl. J. Med.*, 357: 797-805.
- Ashtiyani SC, Moosavi SMS, Hosseinkhani S, Shirazi M (2008). The effects of vitamin-E on oxidative stress and metabolic imbalance induced by acute unilateral ureteral obstruction in anaesthetized rats. *Tehran University Med. J.*, 66: 617-624.
- Bagshaw SM, Bellomo R (2007). Acute renal failure. *Surgery*, 25: 391-398.
- Barnes J, Anderson LA, Phillipson JD (2007). *Textbook of Herbal Medicines*, 3rd edn. Pharmaceutical Press, London, Chicago.
- Basile DP, Friedrich JL, Spahic J, Nripe N, Mang H, Leonard EC, Changizi-Ashtiyani S, Bacallao RL, Molitoris BA, Sutton TA (2011). Impaired endothelial proliferation and mesenchymal transition contribute to vascular rarefaction following acute kidney injury. *Am. J. Physiol. Renal. Physiol.*, 300: 721-33.
- Bayrak O, Bavbek N, Karatas OF, Bayrak R, Catal F, Cimentepe E, Akbas A, Yildirim E, Unal D, Akcay A (2008). *Nigella sativa* protects against ischaemia/reperfusion injury in rat kidneys. *Nephrol. Dial. Transplant*, 23: 2206-2212.
- Chatterjee PK, Cuzzocrea S, Brown PA, Zacharowski K, Stewart KN, Mota-Filipe H, Thiernemann C (2000a). Tempol, a membrane-permeable radical scavenger, reduces oxidant stress-mediated renal dysfunction and injury in the rat. *Kidney. Int.* 58: 658-673.
- Chatterjee PK, Zacharowski K, Cuzzocrea S, Otto M, Thiernemann C (2000b). Inhibitors of poly (ADP-ribose) synthetase reduce renal ischemia-reperfusion injury in the anesthetized rat *in vivo*. *FASEB J.*, 14: 641-51.
- Conger J (1997). Hemodynamic factors in acute renal failure. *Adv. Ren. Replace. Ther.*, 4: 25-37.
- Doolaege EHA, Raes DK, Vos FD, Verhe R, Smet SD (2011). Absorption, distribution and elimination of carnosic acid, a natural antioxidant from *Rosmarinus officinalis* in rats. *Plant. Foods. Hum. Nutr.*, 66: 196-202.
- Frishman WH, Sinatra ST, Moizuddin M (2004). The use of herbs for treating cardiovascular disease. *Semin. Integr. Med.*, 2: 23-35.
- Gimelreich D, Popovtzer MM, Wald H, Pizov G, Berlatzky Y, Rubinger D (2001). Regulation of ROMK and channel-inducing factor (CHIF) in acute renal failure due to ischemic reperfusion injury. *Kidney Int.*, 59: 1812-1820.
- Gong H, Wang W, Kwon TH, Jonassen T, Li C, Ring T, Frokler J, Nielsen S (2004). EPO and a-MSH prevent ischemia/reperfusion-induced down-regulation of AQP2 and sodium transporters in rat kidney. *Kidney Int.*, 66: 683-695.
- Haloui M, Louedec L, Michel JB, Lyoussi B (2000). Experimental diuretic effects of *Rosmarinus officinalis* and *Centaureum erythraea*. *J. Ethnopharmacol.*, 71: 465-472.
- Han KH, Kim HY, Croker BP, Reungjui S, Lee SY, Kim J, Handlogten ME, Adin CA, Weiner ID (2007). Effects of ischemia-reperfusion injury on renal ammonia metabolism and the collecting duct. *Am. J. Physiol. Renal. Physiol.*, 293: 1342-1354.
- Haraguchi H, Saito T, Okamura N, Yagi A (1995). Inhibition of lipid peroxidation and superoxide generation by diterpenoids from *Rosmarinus officinalis*. *Planta Med.*, 61: 333-336.
- Hosseinzadeh H, Nourbakhsh M (1989). Negative inotropic action of Rosemary oil, 1,8-cineole and bornyl acetate. *Planta Med.*, 55: 106-107.
- Juhas S, Bukovska A, Cikos S, Czikkova S, Fabian D, Koppel J (2009). Anti-inflammatory effects of *Rosmarinus officinalis* essential oil in mice. *Acta Vet. Brno.*, 78: 121-127.
- Kenji O (2004). Prevention of endothelial cell injury by activated protein C: the molecular mechanism (s) and therapeutic implications. *Curr. Vasc. Pharmacol.*, 2: 125-133.
- Kramer AA, Postler G, Salhab KF, Mendez C, Carey LC, Rabb H (1999). Renal ischemia/reperfusion leads to macrophage-mediated increase in pulmonary vascular permeability. *Kidney Int.*, 55: 2362-2367.
- Mashiach E, Sela S, Weinstein T, Cohen HI, Shasha SM, Kristal B (2001). Mesna: A novel renoprotective antioxidant in ischaemic acute renal failure. *Nephrol. Dial. Transplant*, 16: 542-551.
- Moosavi SMS, Ashtiyani SC, Hosseinkhani S (2011). L-Carnitine Improves Oxidative Stress and Suppressed Energy Metabolism but Not Renal Dysfunction Following Release of Acute Unilateral Ureteral Obstruction in Rat. *NeuroUrol. Urodyn.*, 30: 480-487.
- Moosavi SMS, Ashtiyani SC, Hosseinkhani S (2010). Comparison of the effects of L-Carnitine and alpha-tocopherol on acute ureteral obstruction-induced renal oxidative imbalance and altered energy metabolism in rats. *J. Urol. Res.*, 38: 187-194.
- Moosavi SMS, Bayat G, Owji SM, Panjehshahin MR (2009). Early renal post-ischaemic tissue damage and dysfunction with contribution of A1-adenosine receptor activation in rat. *Nephrology*, 14: 179-188.
- Moosavi SMS, Barmaki B, Geramizadeh B, Fallahzadeh MH, Johns EJ (2004). Effect of Endothelin-A Receptor Blockade on the Early Phase of Ischemia/Reperfusion- Induced Acute Renal Failure in Anesthetized Rats. *Iranian J. Med. Sci.*, 29: 14-20.
- Naemura A, Ura M, Yamashita T, Arai R, Yamamoto J (2008). Long-term intake of Rosemary and common thyme herbs inhibits experimental thrombosis without prolongation of bleeding time. *Thromb. Res.*, 122: 517-522.
- Pechman KR, De Miguel C, Lund H, Leonard EC, Basile DP, Mattson DL (2009). Recovery from renal ischemia-reperfusion injury is associated with altered renal hemodynamics, blunted pressure natriuresis, and sodium-sensitive hypertension. *Am. J. Physiol. Regul. Integr. Comp. Physiol.*, 297: 1358-1363.
- Posadas SJ, Caz V, Largo C, De la Gándara B, Matallanas B, Reglero G, De Miguel E (2009). Protective effect of supercritical fluid Rosemary extract, *Rosmarinus officinalis*, on antioxidants of major organs of aged rats. *Exp. Gerontol.* 44: 383-389.
- Rasoulalian B, Jafari M, Noroozadeh A, Mehrani H, Wahhab-Aghai H, Hashemi-Madani SMH, Ghani E, Esmaili M, Asgari A, Khosbaten A (2008). Effects of ischemia-reperfusion on rat renal tissue antioxidant systems and lipid peroxidation. *Acta. Med. Iran.* 46: 353-436.
- Spurgeon-Pechman KR, Donohoe DL, Mattson DL, Lund H, James L, Basile DP (2007). Recovery from acute renal failure predisposes hypertension and secondary renal disease in response to elevated sodium. *Am. J. Physiol. Renal. Physiol.*, 293: 269-78.
- Taddei I, Giachetti D, Taddei E, Mantovani P, Bianchi E (1988). Spasmodic activity of peppermint, sage and Rosemary essences and their major constituents. *Fitoterapia*, 59: 463-8.

- Vallon V, Mühlbauer B, Osswald H (2006). Adenosine and kidney function. *Physiol. Rev.*, 86: 901.
- Zaouali Y, Bouzaine T, Boussaid M (2010). Essential oils composition in two *Rosmarinus officinalis* L. varieties and incidence for antimicrobial and antioxidant activities. *Food. Chem. Toxicol.*, 48: 3144-3152.
- Zegura B, Dobnik D, Niderl MH, Filipic M (2011). Antioxidant and antigenotoxic effects of Rosemary (*Rosmarinus officinalis* L.) extracts in Salmonella typhimurium TA98 and HepG2 cells. *Environ. Toxicol. Pharmacol.*, 32: 296-305.