

Full Length Research Paper

Hepatoprotective effects of the decoction and macerated leaves of *Rhamnus alaternus* L. on rats exposed to carbon tetrachloride

Abdelkrim Berroukche*, Khaled Kahloula, Miloud Slimani, Imane Denai and Kheira Ammour

Laboratory of Biochemistry, Biology Department, Faculty of Sciences, Dr. Tahar Moulay University, Saida 20000, Algeria.

Received 28 August 2015; Accepted 2 October 2015

The plant of *Rhamnus alaternus* L. (Rhamnaceae) has been object of many therapeutic indications for traditional medicine. Many studies have showed a hepatoprotective activity of *R. alaternus* L. The objective of this study was to compare the hepatoprotective activities of decoction and macerated *R. Alaternus* L. leaves extracts on rats initially exposed to carbon tetrachloride CCl_4 (1 ml/kg). The macerated leaves (250 mg/kg body weight) showed a highly significant hepatoprotective activity ($p < 0.01$) expressed by a significant decrease in enzymatic biochemical markers such as total bilirubin, alkaline phosphatase (ALP) and transaminases (GOT and GPT). Mean serum biochemical marker levels were 4.5 ± 0.9 mg/dL, 143 ± 3.7 , 43.5 ± 9.2 and 32.2 ± 5.1 U/L, respectively. These results illustrate the dominance of the hepatoprotective pharmacological activity of macerated *R. alaternus* L. leaves.

Key words: Rhamnaceae, traditional medicine, hepatoprotective activity, biochemical markers, alkaline phosphatase.

INTRODUCTION

Liver diseases have a multifactorial etiology including infectious factor. High mortality rate has been correlated with two types of liver diseases namely, jaundice and hepatitis. (Pang et al., 1992). Hepatitis, has been associated with the drinking of contaminated water and poor hygiene (WHO, 2005). Jaundice which is common in children has been characterized by yellow skin because of an excess of bilirubin (Sourabie et al., 2012). Hepatoprotective effects of drugs and plant extracts have

been studied by using carbon tetrachloride (CCl_4) induced hepatotoxicity in animal models (Suja et al., 2002). Studies have shown toxicity of CCl_4 which leads to free radicals in tissues such as liver, kidney, heart, lung, testis, brain and blood (Kumar et al., 2005; Khan and Ahmed, 2009). Research in herbal medicine has been an alternative therapy for liver disease (Pramyothin et al., 2005). Plant drugs have been known for their role in the management of hepatic diseases.

*Corresponding author. E-mail: kerroum1967@yahoo.fr. Tel: 00213798520868.



Figure 1. The shrub of *Rhamnus alaternus* L.
Source: Rameau et al. (2008).

Medicinal plants have been an important source of bioactive molecules, used in the food industry, cosmetics and pharmacy.

These molecules include coumarins, alkaloids, phenolic acids, tannins, flavonoids and terpenes (Baharun et al., 1996). Polyphenols have therapeutic virtues, mainly against cancer and cardiovascular disease. These molecules are involved in the protection of plants against microbial attacks (Bruneton, 1999). Different medicinal plants species such as *Tinospora bakis*, *Cochlospermum tinctoria*, *Nauclea latifolia* and *Argemone mexicana*, have been used in traditional medicine for the therapy of jaundice (Sourabie et al., 2012). Through a rich literature on the phototherapy, it has been found that *Rhamnus alaternus* L. known by populations of different areas of Algeria for its therapeutic activities against jaundice (Figure 1). Important works on the chemistry of *R. alaternus* L. have been carried out and significant pharmacological properties have been reported by studies in Algeria and Tunisia (Ben Ammar et al., 2008; Chemli et al., 2006). Therapeutic properties of this species have been demonstrated *in vitro* because of their active compounds (Ben Ammar et al., 2008). The present study aimed to compare the hepatoprotective effects of the decoction and macerated leaves of *R. alaternus* L. on

rats exposed to CCl_4 .

MATERIALS AND METHODS

Description of plant

Leaves of *R. alaternus* have been collected during the month of October, 2013 in rural areas of Mohammedia, located in North-West of Algeria (Figure 2). *R. alaternus* L. is a sun-loving plant, growing in Mediterranean areas. It is a shrub of 5 m high with non spiny leaves and fruits (Chemli et al., 2006; Rameau et al., 2008). The leaves are oval or lance-shaped with slightly toothed edges, buckthorn, short-stalked, thick and leathery. The fruits appear in late fall. There are small red and black berries, grouped in compact clusters. Identification of the plant was made by M. Terras, researcher and team member of Laboratory of water sources and environment Biology Department at the University of Saida (Algeria). Dried leaves have been transformed into powder using an electric mill (Moulinex model D5001). Powders have been used to prepare aqueous decoction and macerated extract of the leaves.

Preparation of extract

To prepare an aqueous decoction, two hundred fifty grams (250 g) of powder leaves of *R. alaternus* have been used in a flask containing 1000 ml of distilled water. Decoction has been maintained under continuous reflux for 2 h at 80°C (Belhattab et al.,

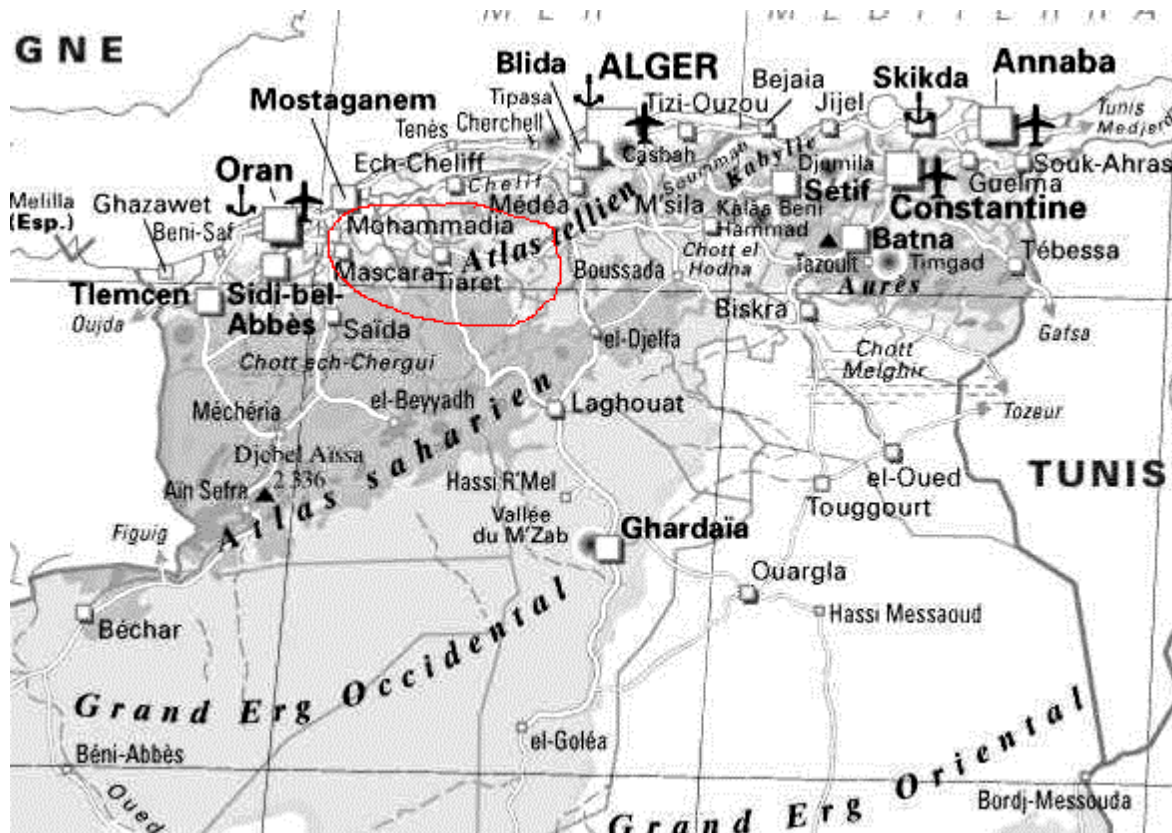


Figure 2. Geographical map of Mohammadia, located in North- West of Algeria. (Diagram tourism development of the department of Mascara, 2015).

2004). Decoction has been filtered through a funnel containing cotton wool and then centrifuged at 2500 rpm for 5 min. Aqueous macerated extract of the leaves was obtained in the same conditions as the decoction with the only difference that it has made macerated extract (cold extraction) without any heating process of the test portion (250 g).

Preparation of animals

Forty (40) male adult Wistar rats, 2 months old and weighing about (180 to 200 g) from the central animal house of the Department of Biology of Saida University, were used in this study. They were kept under standard environmental conditions at 25°C with 12:12 h light-dark cycle in ventilated plastic cages. The rats were fed with standard feed livestock and water ad libitum. The animals were divided into 4 groups (10 rats per group) as follow:

Group 1: served as normal controls (NC) and rats received a tap water daily for 7 days orally.

Group 2: served as toxic control and the rats were injected intraperitoneal with carbon tetrachloride (CCl₄) (1 ml/kg body weight) daily for the same period (7 days).

Group 3: (CCl₄ + decoction of *R. alaternus* leaves): the rats were injected intraperitoneal with CCl₄ (1 ml/kg body weight) and treated orally with the decoction of *R. alaternus* leaves (250 mg/kg body

weight) daily for the same period.

Group 4: (CCl₄ + macerated *R. alaternus* leaves): the rats were injected intraperitoneal with CCl₄ (1 ml/kg body weight) and treated orally with the macerated *R. alaternus* leaves (250 mg/kg body weight) daily for the same period (Sourabie et al., 2012).

Biochemical study

At the end of the experiments, all animals were sacrificed and the blood from each animal was taken into haemolysis tubes (5 mL). The blood samples were centrifuged at 2500 rpm for 10 to 15 min and the sera isolated were used for estimation of the serum biochemical markers of liver; as serum glutamic oxaloacetic transaminase (GOT), serum glutamic pyruvic transaminase (GPT), alkaline phosphatase (ALP) and total bilirubin.

Histopathology

The animals were dissected to isolate liver tissues. After draining the blood, liver samples were excised, washed with normal saline and processed separately for histological observations. Initially, the materials were fixed in 10% buffered neutral formalin for 48 h and then with bovine solution for 6 h. Paraffin sections were taken at 5 mm thickness, processed in alcohol-xylene series and were stained

Table 1. Effects of decoction and macerated *Rhamnus alatenus* leaves on serum hepatic parameters in groups of control rats and exposed to CCl₄.

Groups of rats (n = 40)	Total bilirubin (mg/dL)	ALP (U/L)	SGOT (U/L)	SGPT (U/L)
Group 1 (NC)				
Mean ± SD	1.49 ± 0.03	130.25 ± 4.4	26.5 ± 4	26 ± 4.6
Min-Max	1.41 - 1.56	120 - 139	17 - 36	19 - 39
Mean CI (95%)	1.47 - 1.50	128.09 - 132.4	24.53 - 28.46	17 - 28.2
Group 2 (CCl₄)				
Mean ± SD	**11.0 ± 0.94	**185.5 ± 5.95	**88.25 ± 6.96	**69.25 ± 2.92
Min-Max	9.88 - 13.74	169 - 197	69 - 99	66 - 78
Mean CI (95%)	10.53 - 11.46	182.58 - 188.41	84.83 - 91.66	67.81 - 70.68
Group 3 (CCl₄ + D)				
Mean ± SD	10.00 ± 1.07	161.5 ± 8.7	49 ± 1.08	61.5 ± 3.77
Min - Max	7.13 - 12.04	145 - 186	46 - 51	55 - 69
Mean CI (95%)	9.47 - 10.52	157.23 - 165.76	48 - 57	59.65 - 63.34
Group 4 (CCl₄ + M)				
Mean ± SD	4.51 ± 0.45	135.25 ± 0.85	30.75 ± 3.54	34.5 ± 2.21
Min - Max	3.33 - 5.33	133 - 137	22 - 37	29 - 39
Mean CI (95%)	4.28 ± 4.73	134.83 - 135.66	29.01 - 32.48	33.47 - 35.58

NC: Normal control; D: Decoction, M: Maceration; SD: Standard deviation; Min: Minimum; Max: Maximum; CI: Confidence interval; ALP: Alkaline phosphatase; GOT: Glutamic oxaloacetic transaminase; GPT: Glutamic pyruvic transaminase; P**: Highly significant (< 0.001).

with alum haematoxylin and eosin (Galigher et Koyloff, 1971). The sections were examined microscopically for histopathological changes.

Statistical analysis

Data are expressed as mean ± SD, with a value of $p < 0.05$ considered statistically significant. Statistical evaluation was performed by one way analysis of variance (ANOVA) followed by the Tukey's t-test for multiple comparisons. All analysis was made with the statistical software Sigmaplot (version 11.0).

RESULTS

As shown in Table 1 and Figure 3, body weight of rats exposed to CCl₄ (Group 2) was highly decreased significantly ($p^{**} < 0.01$) compared with normal control rats (Group 1). The median body weight in group of rats administered CCl₄ was lower (174.57 ± 5.2 g) compared to normal control rats (Group1) which showed a higher mean body weight (224.28 ± 6.6 g). Whereas the body weight of rats (Groups 3 and 4) has not showed a significant difference. Their mean body weights were 179.85 ± 1.68 and 196.28 ± 1.63 g, respectively.

The administration of carbon tetrachloride CCl₄ (1 ml/kg

body weight) developed a significant increase in serum enzymatic markers ($p^{**} < 0.01$), especially serum transaminase (GOT and GPT) and alkaline phosphatase (ALP). Similarly, it was observed concomitantly, a significant increase in serum total bilirubin ($p^{**} < 0.01$) (Table 1). This phenomenon was particularly observed in rats of Group 2 which were administrated CCl₄, in comparison with the normal control rats of Group 1 as shown in Figures 4, 5, 6, 7.

The aqueous extracts (decoction and macerated) administered at the same dose (250 mg/kg) developed a significant decrease in serum enzymes (GOT and GPT) ($p^{**} < 0.01$) and a decrease in the serum total bilirubin concentration as compared to animals which were administered CCl₄ (Group 2) (Figures 4, 5, 6, 7). The effect of different treatments (decoction and macerated) on serum enzyme markers and serum total bilirubin is reported in Figures 4, 5, 6, 7. From the perspective of pharmacological activity, the decrease of biological parameters observed in the test Groups 3 and 4 is a clear sign and an illustration of the ability of these extracts to reduce the hepatotoxicity induced by the administration of toxic organochlorine (CCl₄, 1 ml/ kg B.W). Histopathologies of various groups are shown in Figure 8. In Group 1 (normal control rats), liver tissue section

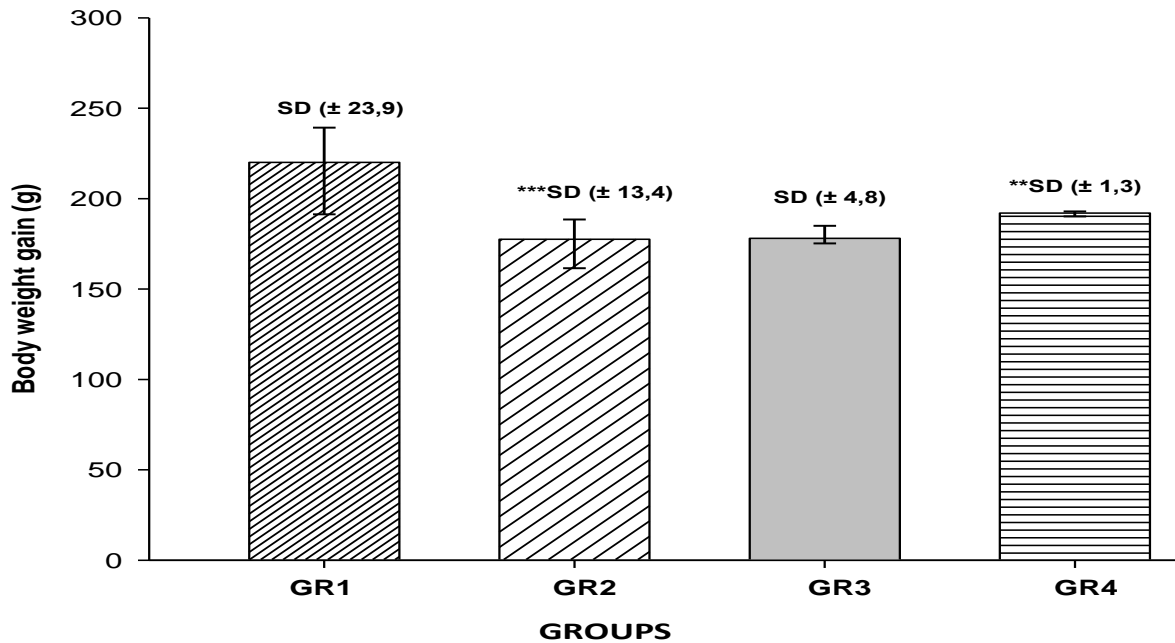


Figure 3. Variation of body weight in groups of animals. GR1 (NC): Group 1 of normal control rats; GR2 (CC1₄): Group 2 of treated rats with CCl₄; GR3 (CC1₄-D): Group 3 of treated rats with CCl₄ and decoction *Rhamnus alaternus* leaves; GR4 (CC1₄-M): Group 4 of treated rats with CCl₄ and macerated *Rhamnus alaternus* leaves; SD: standard deviation; ** (p < 0.01): statistically significant difference between the groups of animals.

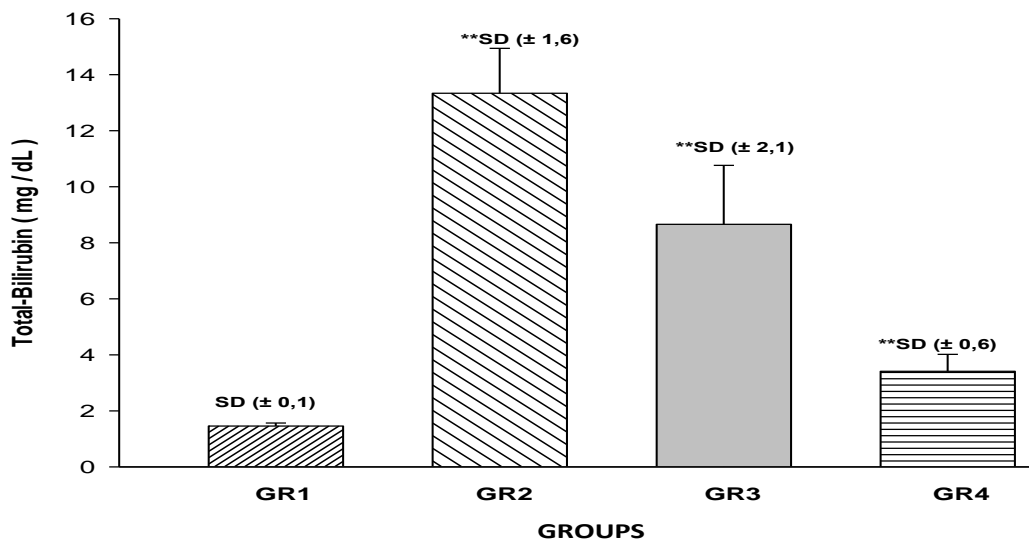


Figure 4. Effects of decoction and macerated *Rhamnus alaternus* leaves on serum total-bilirubine in groups of animals exposed to CCl₄.

(Figure 8A) shows a normal architecture of liver cells. Hepatocyte, hepatic sinusoids, portal tract, shows normal size and Shape. The nuclei are round and are uniform

with little variation in size.

In Group 2 (Rats treated with CCl₄), liver tissue section (Figure 8B) shows extreme degeneration of hepatic

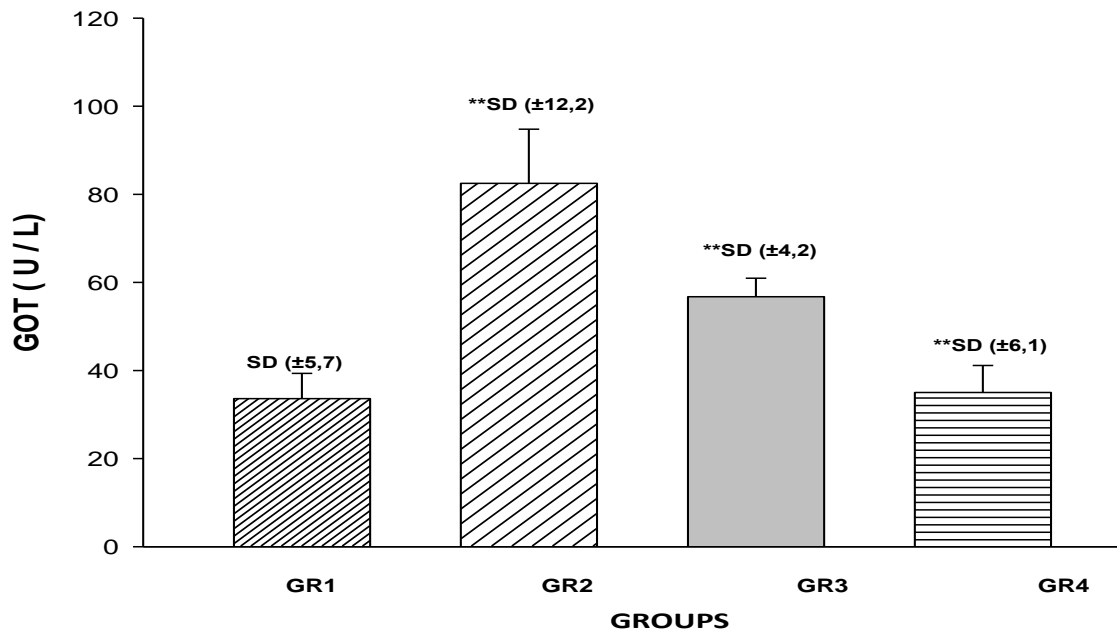


Figure 5. Effects of decoction and macerated *Rhamnus alatenus* leaves on serum glutamic oxaloacetic transaminase (GOT) in groups of animals exposed to CCl₄.

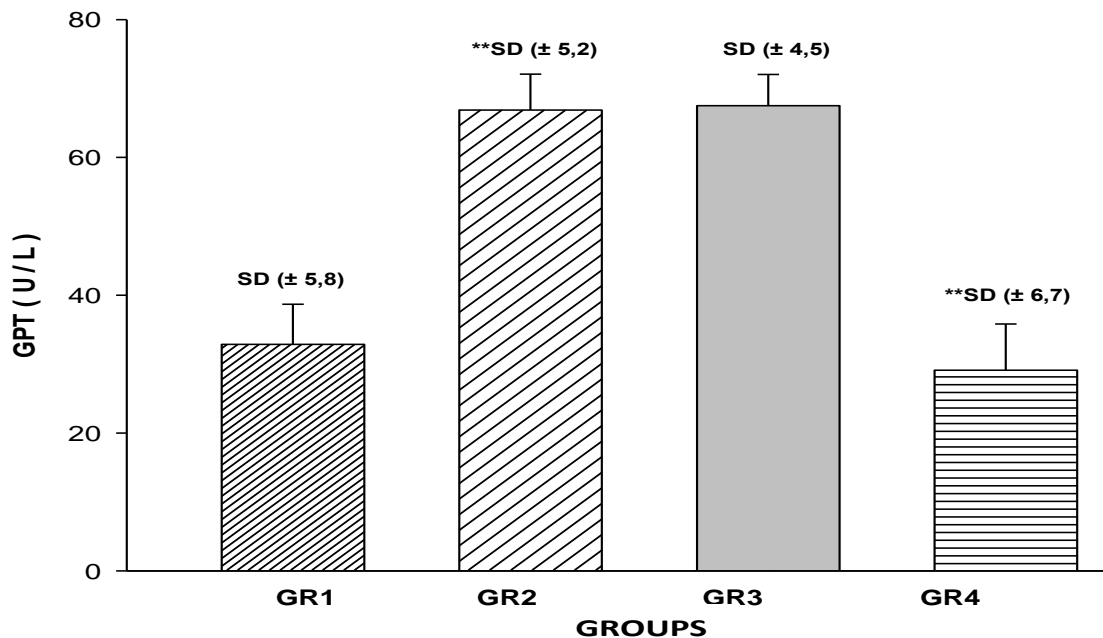


Figure 6. Effects of decoction and macerated *Rhamnus alatenus* leaves on serum glutamic pyruvic transaminase (GPT) in groups of animals exposed to CCl₄.

architecture by necrosis, foci of haemorrhage, fatty changes and vein crowding. Hepatocyte are arranged like

disks and shows a typical proliferation. In Group 3 (Rats treated with CCl₄ and decoction of *R. alaternus* leaves),

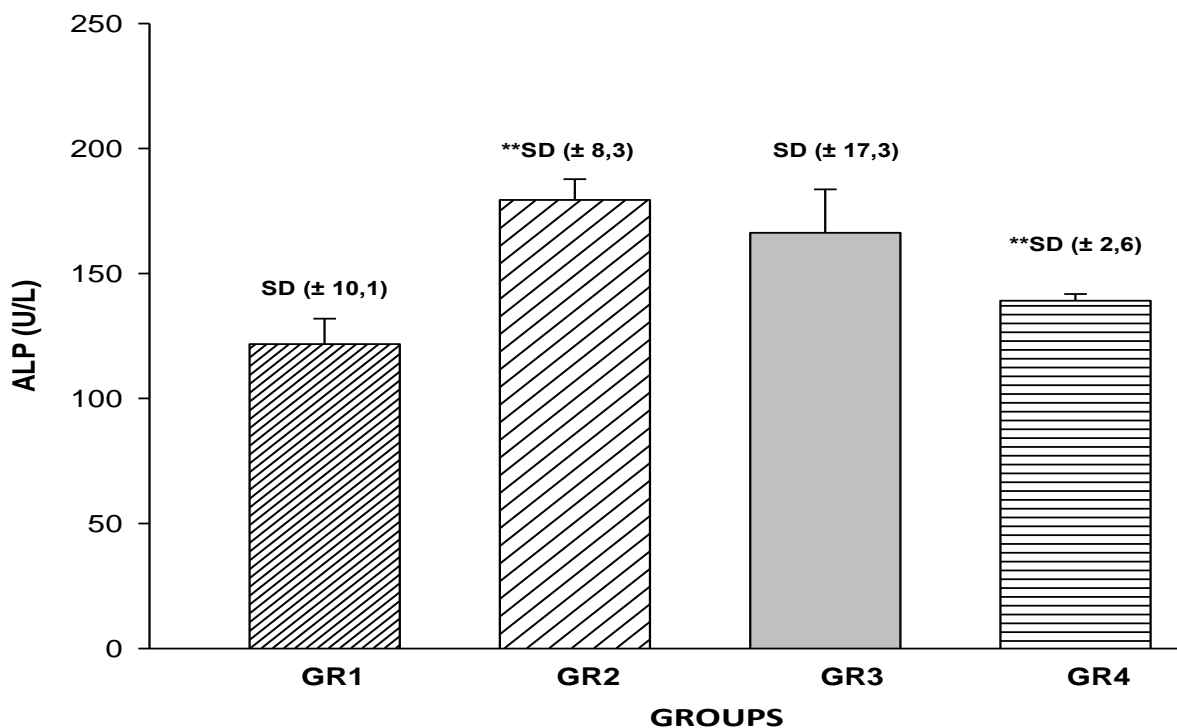


Figure 7. Effects of decoction and macerated *R. alaternus* leaves on serum alkaline phosphatase (ALP) in groups of animals exposed to CCl_4 .

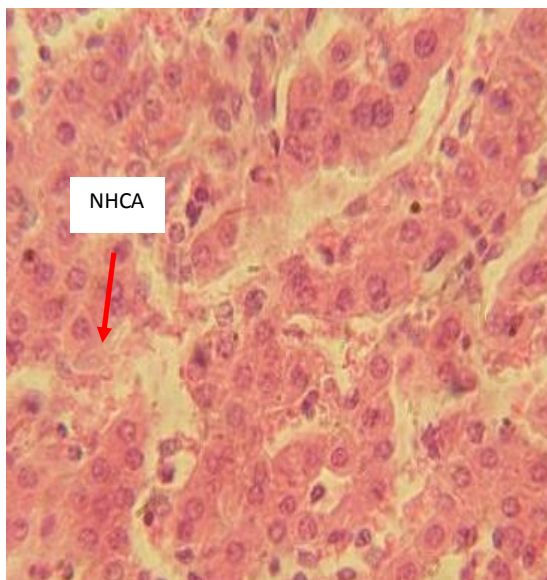
liver tissue section (Figure 8C) shows mild degree of liver necrosis. Hepatocytes are compact. Hepatic sinusoids appear normal. The Hepatocytes are well arranged like clusters. In Group 4 (rats treated with CCl_4 and the macerated *R. alaternus* leaves), liver tissue section (Figure 8D) shows that hepatocytes were regenerative and showed no visible changes and prominent nuclei, reduced score of necrosis and no fatty changes. Thus, confirming the safety of the extract.

DISCUSSION

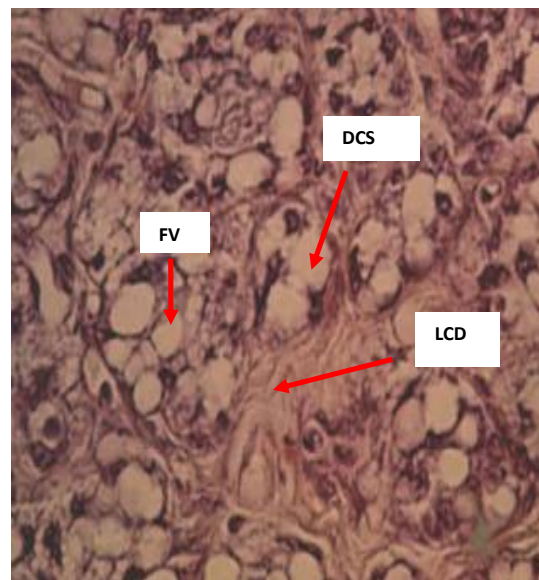
CCl_4 has been used in this present study for its liver toxicity and tropism for hepatocytes. Cell mechanism of CCl_4 , has been previously described in different studies (Sarada et al., 2012; Letteron et al., 1990), showing alteration and necrosis of liver cells. Hepatic metabolism of CCl_4 has been initiated by transforming it into its primary metabolites (trichloromethyl and trichloromethyl peroxyde) through the hepatic cytochrome P450 oxidase and main enzymatic system involved into redox reactions of xenobiotics in the liver. Trichloromethyl peroxide is highly reactive free radicals that will initiate a lipid peroxidation (Sourabie et al., 2012). Free radicals have

caused an important flow of GOT and GPT from hepatocyte membranes into blood medium (Sourabie et al., 2012). Results of this present study showed that a dose of CCl_4 (250 ml/kg) have caused severe hepatocellular injury as indicated by the massive elevations of GPT, GOT, ALP and total bilirubin levels in rats intoxicated with CCl_4 (Group 2) when compared with normal control animals (Group 1).

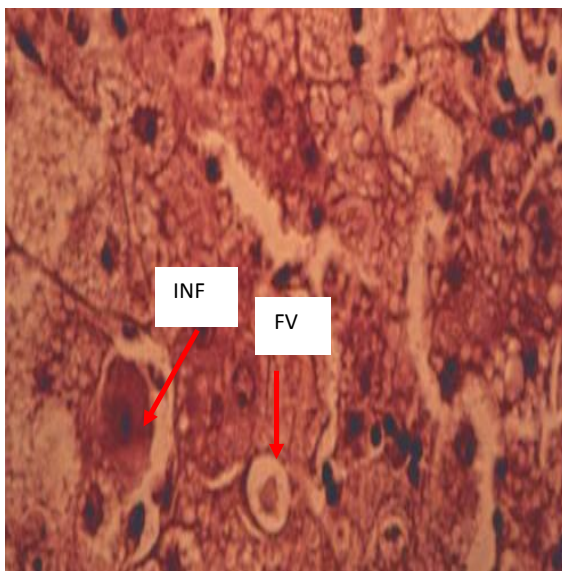
Treated rats (Groups 3, 4) have preserved the integrity of liver cells and significantly decreased elevated enzymatic parameters (GOT, GPT and ALP) and total bilirubin levels. Dose (250 mg/kg) of aqueous extract *R. alaternus* leaves has been used in the present study based on some published studies demonstrating the hepatoprotective activity of this dose (Gopal et al., 2008). In this present study, decoction and specially macerated leaves treated groups (Groups 3 and 4) have exhibited lower levels of GPT, GOT, ALP and bilirubin as compared to CCl_4 treated group (Group 1). Reduction of these parameters is an indication of the stabilization of cell membranes as well as repair of hepatic tissue damage caused by CCl_4 (Lin et al., 2008). The stabilization of serum bilirubin, GPT, GOT, and ALP levels by decoction and macerated plant leaves is a clear indication of the improvement of the functional status of



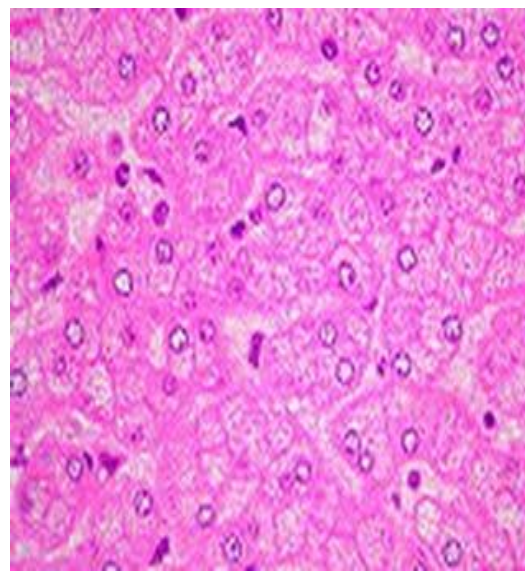
(A): Photographic image of liver tissue shows a normal hepatic cellular arrangements (NHCA) in Group 1 of normal control rats. (Hematoxyline-Eosine $\times 40$).



(B) : In Group 2 (CCl₄). Showing liver cell degeneration (LCD), with fatty vacuols (FV) and degenerative cellular swelling (DCS) (H-E $\times 40$).



(C) : In Group 3 (CCl₄ + decoction leaves). Less cellular necrosis associated with inflammation (INF) and low presence of fatty vacuoles (FV) (H-E $\times 40$).



(D) : In Group 4 (CCl₄ + macerated leaves). Absence of fatty vacuoles and inflammation and normal cell arrangements (H-E $\times 40$).

Figure 8. Histopathologies of various groups.

the liver cells. This indicates the anti-lipid peroxidation of aqueous extract of *R. alaternus* leaves which acted against the damaging effects of free radicals produced by

CCl₄.

Histopathological examination clearly reveals that the hepatic cells, central vein and portal triad are almost

normal in decoction and macerated *R. alaternus* leaves treated group (250 mg/kg) in contrast to group which received CCl₄. Thus, decoction and macerated *R. alaternus* leaves can be considered to be an effective hepatoprotective agent as it ameliorated almost to normalcy the damage caused by CCl₄ to hepatic function. In literature, it has been suggested that administration of extract of *R. alaternus* increased enzymatic parameters (GOT, GPT and ALP) and total bilirubin level and it may be due to the presence of active constituents such as flavonoids and alkaloids (Ben Ammar et al., 2009). Studies have shown that phenolic compounds had an antioxidant activity as scavenging free radicals (Seyoum et al., 2006).

Phenolic compounds can also act as antioxidants by chelating metal ions, preventing radical formation and improving the antioxidant endogenous system (Al-Azzawie et al., 2006). These compounds are known to act as antioxidants not only because of their ability to donate hydrogen or electrons but also because they are stable radical intermediates. Probably the most important natural phenolics are flavonoids because of their broad spectrum of chemical and biological activities, including antioxidant and free radical scavenging properties (Kahkonen et al., 1999). In fact, flavonoids have been reported as antioxidants, scavengers of a wide range of reactive oxygen species and inhibitors of lipid peroxidation (Williams et al., 2004).

CONCLUSION

Both decoction and macerated *R. alaternus* L. leaves have exhibited a potent hepato-ameliorating and antioxidant effects in rats exposed to CCl₄. But hepato-ameliorating and antioxidant effects of macerated *R. alaternus* L. leaves were found to be better than those of decoction plant leaves. In two cases, the hepatoprotective qualities of aqueous extract of *R. alaternus* L. leaves need to be addressed by isolating and characterizing the active principle(s) responsible for hepatoprotective activity.

ABBREVIATIONS

(NC): Normal control; **(GOT):** Glutamic oxaloacetic transaminase; **(GPT):** Glutamic pyruvic transaminase; **(ALP):** Alkaline phosphatase; **(SD):** Standard deviation; **(ANOVA):** analysis of variance.

Authors' contributions

All authors read and approved the final manuscript.

ACKNOWLEDGEMENT

Our thanks to Dr. M. Terras, member of the Laboratory of Water Resources and Environment of the Saida University and Dr. S. Amara. We also thank technicians of THE Para medical team of Laboratory of Biology Analysis led by Dr. Z. Haddi.

Conflicts of interest

The authors declare that they have no competing interests.

REFERENCES

- Al-Azzawie HF, Mohamed-Saiel SA (2006). Hypoglycemic and antioxidant effect of oleuropein in alloxan-diabetic rabbits. *Life Sci.* 78:1371–1377.
- Bahorun T, Gressier B, Trotin F, Brunet C, Dine T, Luyckx M, Vasseur J, Cazin M, Cazin JC, Pinkas M (1996). Oxygen species scavenging activity of phenolic extracts from hawthorn fresh plant organs and pharmaceutical preparations. *Arznei. Forschung* 46:1086-1089.
- Belhattab R, Larous L, Kalantzakis G, Bouskou D, Exarchou V (2004). Antifungal properties of *Origanum glandulosum* Desf. extracts. *Food, Agric. Environ.* 2:63-69
- Ben Ammar R, Ben Sghaeir M, Boubaker J, Bhouri W, Naffeti A, Skandrani I, Bouhlel I, Kilani S, Ghedira K, Chekir-Ghedira L (2008). Antioxidant activity and inhibition of aflatoxin B1-, nifuroxaside-, and sodium azide-induced mutagenicity by extracts from *Rhamnus alaternus* L. *Chim. Biol. Interact.* 174:1-10.
- Ben Ammar R, Bhouri W, Ben Sghaeir M, Boubaker J, Skandrani I, Naffeti A, Bouhlel I, Kilani S, Mariotte AM, Chekir-Ghedira L, Dijoux-Franca MG, Ghedira K (2009). Antioxidant and free radical-scavenging properties of three flavonoids isolated from the leaves of *Rhamnus alaternus* L. (Rhamnaceae): A structure-activity relationship study. *Food Chem.* 116: 258–264.
- Bruneton J (1999). Pharmacognosy, phytochemistry, medicinal plants. Ed. International Medical. Technical Editions & Documentation, Cachan S1 : 647-673.
- Chemli R, Dahmen M, Khaldi A (2006). Guides of medicinal and aromatic plants. pp. 13-116.
- Diagram tourism development of the Wilaya of Mascara. In: Project selected tourist development plan. Report No. 3, CENEAP 2012. <https://fr.scribd.com/doc/101586413/Report-mascara-Final-doc>. Accessed 10 April 2015.
- Galigher AE, Koyloff EN (1971). Essential of practical microtechnique. 2nd ed. Lea and Febiger: Philadelphia.
- Gopal N, Sengottuvelu S (2008). Hepatoprotective activity of *Clerodendrum inerme* against CCl₄ induced hepatic injury in rats. *Fitoterapia* 79:24-26.
- Kahkonen MP, Hopia AI, Vuorela HJ, Rauha JP, Pihlaja K, Kujala TS, Heinonen M (1999). Antioxidant activity of plant extracts containing phenolic compounds. *J. Agric. Food Chem.* 47:3954–3962.
- Khan MR, Ahmed D (2009). Protective effects of *Digera muricata* (L.) Mart. on testis against oxidative stress of carbon tetrachloride in rat. *Food Chem. Toxicol.* 47:1393-1399.
- Kumar G, Banu GS, Pandian MR (2005). Evaluation of the antioxidant activity of *Trianthema portulacastrum* L. *Ind. J. Pharmacol.* 37:331–333.
- Lettéron P, Labbe G, Degott C, Berson A, Fromenty B, Delaforge M, Larrey D, Pessayre D (1990). "Mechanism for the protective effects of silymarin against carbon tetrachloride-induced lipid peroxidation and hepatotoxicity in mice: evidence that silymarin acts both as an

- inhibitor of metabolic activation and as a chain-breaking antioxidant." *Biochem. Pharmacol.* 39(12):2027-2034.
- Lin HM, Tseng HC, Wang CJ, Lin JJ, Lo CW, Chou FP (2008). Hepatoprotective effects of *Solanum nigrum* Linn extract against CCl₄-induced oxidative damage in rats. *Chem. Biol. Interact.* 171:283-293.
- Pang S, Xin X, Spierre MV (1992). Determinants of Metabolic Disposition. *Ann. Rev. Pharmacol. Toxicol.* 32:625-626.
- Pramyothin P, Chirdchupunsare H, Rungsipipat A, Chaichantipiyuth C (2005). Hepatoprotective activity of *Thunbergia laurifolia* Linn extract in rats treated with ethanol: *In vitro* and *in-vivo* studies. *J. Ethnopharmacol.* 102:408-411.
- Rameau D, Mansion G, Dumé C (2008). Flore forestière française, guide écologique illustré, région méditerranéenne, ministère de l'agriculture et de la pêche. P 2426.
- Sarada K, Jothibai MR, Mohan VR (2012). Hepatoprotective and antioxidant activity of ethanol extracts of *Naringi crenulata* (Roxb) Nicolson against CCl₄ induced hepatotoxicity in rats. *Int. J. Pharm. Sci. Res.* 3:874-880.
- Seyoum A, Asres K, El-Fiky FK (2006). Structure–radical scavenging activity relationships of flavonoids. *Phytochemistry* 67:2058–2070.
- silymarin against carbon tetrachloride induced lipid peroxidation and hepatotoxicity in mice. Evidence that silymarin acts both as an inhibitor of metabolic activation and as a chainbreaking antioxidant. *Biochem. Pharmacol.* 39:2027-2034.
- Sourabie TS, Nikiema JB, Guissou IP, Nacoulma OG (2012). Comparative study of anti-hepatotoxic effects of extracts of *Argemone mexicana* L. (Papaveraceae), a plant used in traditional treatment of jaundice in Burkina Faso. *Int. J. Bio. Chem. Sci.* 6: 1139-1147.
- Suja SR, Latha PG, Pushpangadan P, Rajasekharan S (2002). Aphrodisiac property of *Helminthostachys zeylanica* in mice. *J. Trop. Med. Plants* 3:191-195.
- WHO guidelines for the safe use of wastewater, excreta and greywater (2005). Volume VI: The use of excreta and greywater in agriculture. World Health Organization, PNU.
- Williams RJ, Spencer JP, Rice-Evans C (2004). Flavonoids: Antioxidants or signalling molecules? *Free Rad. Biol. Med.* 36:838-849.